

# Histopathological Evaluation of Diffusion Weighted Magnetic Resonance Imaging in Differentiation between Benign and Malignant Thyroid Nodules

Ammar Yasser Mohamed <sup>1</sup>\*M.B.B.Ch; Amr Mahmoud Zayed <sup>1</sup>MD and  
Mohamed Salah El-Deen Abdelbaqy <sup>1</sup>MD.

## \*Corresponding Author:

Ammar Yasser Mohamed

[Ammar\\_yasser\\_gb@azhar.edu.eg](mailto:Ammar_yasser_gb@azhar.edu.eg)

Received for publication June 01, 2022; Accepted November 22, 2022;  
Published online November 22, 2022.

doi: 10.21608/aimj.2022.142400.1965

**Citation:** Ammar Y. , Amr M. and Mohamed S. Histopathological Evaluation of Diffusion Weighted Magnetic Resonance Imaging in Differentiation between Benign and Malignant Thyroid Nodules. AIMJ. 2022; Vol.3-Issue11 : 148-153.

<sup>1</sup>Radiodiagnosis Department, Faculty of Medicine, Al-Azhar University, Cairo , Egypt.

## ABSTRACT

**Background:** Nodules are the most frequent lesion in thyroid gland. They are discovered clinically on self-examination by the patient, during a clinical examination or accidentally during a radiologic procedure; with applying different imaging modalities in recent years, thyroid nodules are being more frequently accidentally discovered.

**Aim of The Work:** Establishing the precision of Diffusion-Weighted Imaging (DWI) and Apparent Diffusion Coefficient (ADC) values in diagnosing benign and malignant nodules, considering histopathology as the highest diagnostic modality.

**Patients and Methods:** Diffusion was measured both intuitively and quantitatively using trace images and the apparent diffusion coefficient (ADC) parameter. On the trace image, malignant tissues with restricted diffusion were bright, and on the ADC map, they were hypo-intense, with much lower ADC values than benign thyroid nodules.

**Results:** All of the patients had their thyroid nodules histopathologically examined, and the results revealed that there were 26 benign nodules (76.5%) and 8 malignant nodules (23.5%), respectively. The results of histopathological examinations were compared to DWI and ADC values derived by magnetic resonance imaging (MRI). All subjects underwent DW-MRI with a b value of 600 s/ mm<sup>2</sup>. Thyroid nodule mean ADC values were determined.

**Conclusion:** Quantitative DWI could be a reliable imaging method for thyroid nodule detection because it is found to have high specificity and sensitivity. The ADC values seem to be able to discriminate benign from malignant thyroid lesions.

**Keywords:** Histopathological; DWI; ADC mapping; MRI; Thyroid Nodules.

**Disclosure:** The authors have no financial interest to declare in relation to the content of this article. The Article Processing Charge was paid for by the authors.

**Authorship:** All authors have a substantial contribution to the article.

**Copyright** The Authors published by Al-Azhar University, Faculty of Medicine, Cairo, Egypt. Users have the right to read, download, copy, distribute, print, search, or link to the full texts of articles under the following conditions: Creative Commons Attribution-Share Alike 4.0 International Public License (CC BY-SA 4.0).

## INTRODUCTION

Hepatocellular carcinoma (HCC) is more frequent in Thyroid nodules are usually palpable and sonographically distinct from the thyroid parenchyma surrounding them. They are the most frequent pathology of thyroid gland. About 5% of newly detected nodules are diagnosed to be cancerous, a rate that has increased in the last 30 years.<sup>1</sup>

Benign and malignant thyroid nodules must be differentiated in order to accurately and effectively treat patients with this pathology. Although ultrasonography has been used to evaluate these nodules as a first step, no one US feature has been found to definitely identify benign from malignant nodules.<sup>2</sup>

Conventional T1 and T2 pulse sequences cannot distinguish benign from malignant nodules or determine thyroid nodule physiologic state, hence their value in thyroid nodule assessment is restricted.<sup>4</sup>

Diffusion weighted MRI is an evolving technique that detects changes in tissue structural organization that affects the diffusion of water particles. The apparent diffusion coefficient (ADC) is a numerical indicator that can elaborate malignant and benign thyroid nodules.<sup>5</sup>

DWI has been established in several studies to be a differentiating tool that detects benign as well as malignant thyroid lesions. These investigations, however, had small sample size and yielded equivocal outcomes.<sup>2</sup>

Using histopathology as the highest standard, in order to establish the diagnostic power of Diffusion-Weighted Imaging (DWI) and Apparent Diffusion Coefficient (ADC) values in identifying benign and malignant thyroid nodules.

## PATIENTS AND METHODS

**Patients:** The study was performed in the Diagnostic and Interventional Radiology Unit at Sayed Galal University Hospital on 34 individuals who were diagnosed with thyroid nodules by ultrasound. The individuals of the study were recommended to the

radiology department by the surgical department over 7-months (September 2021 - April 2022), and their ages ranged from 25 to 70 (median 47); 28 patients were females and 6 were males.

**Exclusion criteria:** Patients known to have Contraindications to MRI (pacemaker, metallic foreign body in the eye, cochlear implant, cerebral aneurysm clips, claustrophobia).

**All cases underwent the following:** a thorough medical history, a thorough clinical examination, and an MR imaging evaluation.

The study was performed at the Department of Radiodiagnosis of Sayed Galal University Hospital with 1.5-Tesla scanner unit (Philips) using a neurovascular neck coil. Our standard MR protocol for nodule assessment included the following pulse sequences: T1 and T2 pulse sequences with no contrast in the axial plane, DWI was performed with axial thyroid gland imaging sequence, the system software was used to create ADC maps with a b value of 600 s/mm<sup>2</sup> and an average value for the three diffusion sensitization directions, image analysis: Thyroid nodules were identified on T1 and T2 pulse sequences, inspected for restricted diffusion on DWI images and ADC value of selected ROI centered in soft tissue nodules or in soft tissue parts of complex nodules was calculated and results were revised by more than one expert radiologist.

All cases underwent histopathologic examination and results were studied in correlation with imaging results.

**Statistical Analysis:** The data entered into the computer was examined using the IBM SPSS software version 20.0. (Armonk, NY: IBM Corporation) To describe qualitative data, we utilized the terms number and percent. To ensure that the distribution was normal, the Kolmogorov-Smirnov test was used. The range (minimum and maximum), mean, standard deviation, median, and interquartile range (IQR) were used to characterize quantitative data. At a 5% level of

significance, the acquired data was considered to be significant.

**The following tests were used:**

**Chi-square test:** used to compare categorical variables between groups.

**Monte Carlo correction:** When more than 20% of the cells have an estimated count of less than 5, Monte Carlo correction is used.

**Student t-test:** Use the student t-test to compare two groups with normally distributed quantitative variables.

**F-test (ANOVA):** For pairwise comparisons, the Post Hoc test (Tukey) is used for normally distributed quantitative variables.

**Receiver operating characteristic curve (ROC):** This curve is designed by setting sensitivity (TP) on the Y axis against specificity (FP) on the X axis at various cutoff levels. The area under the ROC curve is used to assess a test's diagnostic performance. A score of more than 50% is considered acceptable, while a score of more than 100% is considered the best for the test.

**Sensitivity:** if the test can accurately discover affected persons among "TRUE POSITIVES". The sensitivity increases as the frequency of unrecognized cases, or "false negatives", decreases.

**Specificity:** The ability of a test to appropriately eliminate those who do not have the disease "TRUE NEGATIVES". There will be fewer "false positives" if the specificity is higher.

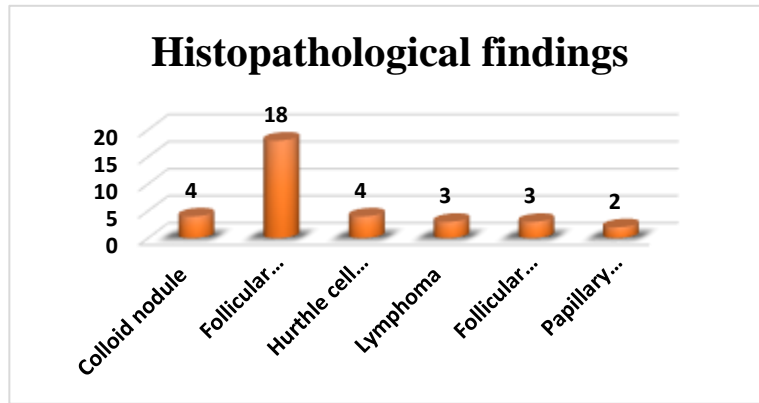**Positive Predictive value (PPV):** The likelihood that the pathology will be in people who have a positive diagnostic test result.

**Negative Predictive value (NPV):** The likelihood that the pathology did not exist in those who had negative diagnostic test results.

## RESULTS

Histopathological findings		No.	%
Benign	Colloid nodule	4	11.8
	Follicular adenoma	18	52.9
	Hurthle cell adenoma	4	11.8
Malignant	Lymphoma	3	8.8
	Follicular carcinoma	3	8.8
	Papillary carcinoma	2	5.9
Total		34	100.0

**Table 1:** The studied cases were distributed according to histopathological findings (n = 34)



**Fig. 2:** The studied cases were distributed according to histopathological findings (n = 34)

ADC value×10 <sup>-3</sup>	Histopathological findings		Mann-Whitney U	
	Negative (n = 2 <sup>1</sup> )	Positive (n= 8)	U	P-value
Range	0.40 - 2.40	0.50 - 0.93	16.5	0.000**
Mean ±SD	1.61 ± 0.53	0.75 ± 0.18		

\*\*p-value < 0.001 highly statistically significant

**Table 2:** comparison between patients' Histopathological findings results as regards ADC value.

Histopathological findings	No.	%
Positive	8	23.5
Negative	26	76.5
<b>Total</b>	<b>34</b>	<b>100.0</b>

**Table 3:** The studied cases were distributed according to histopathological findings.

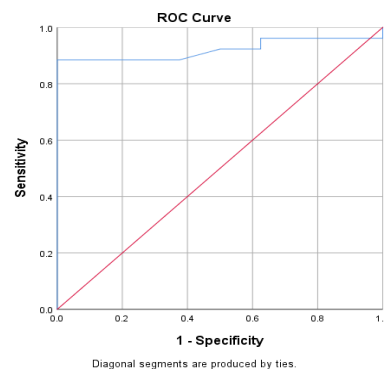
ADC*10 <sup>-3</sup>	AUC	P-value	95% Confidence Interval		Cut off Value	Sensitivity	Specificity	PPV	NPV
			Lower Bound	Upper Bound					
	0.921	0.000**	0.826	1.000	≤0.93	100%	92.3%	80%	100%

AUC: Area Under a Curve      p-value: Probability value

NPV: Negative predictive value      PPV: Positive predictive value

\*: Statistically significant at p ≤ 0.05      \*\*: Statistically highly significant at p ≤ 0.001

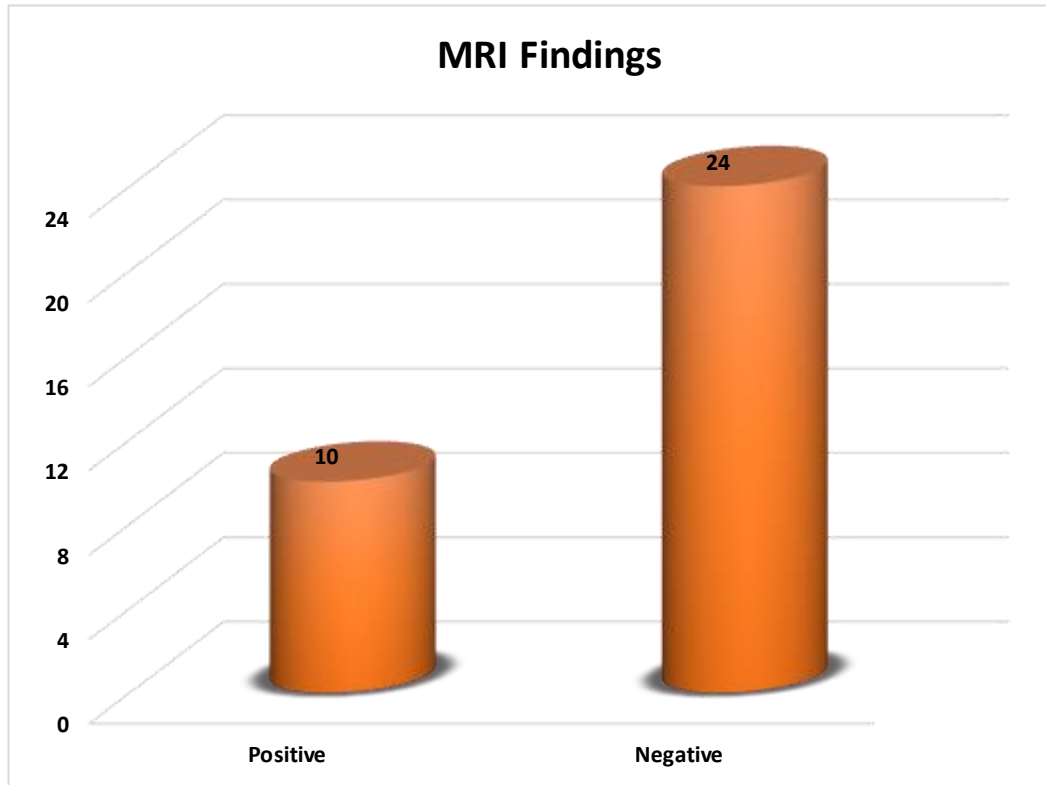
**Table 4:** Curve of receiver operating characteristic (ROC) and diagnostic indices of ADC value 10-3 for thyroid cancer prediction.



**Fig. 3:** ROC curve for ADC for prediction of thyroid malignancy

MRI Findings	No.	%
Positive (ADC value $\times 10^{-3} \leq 0.93$ )	10	29.4
Negative (ADC value $\times 10^{-3} > 0.93$ )	24	70.6
Total	34	100.0

**Table 5:** Distribution of the studied cases according to MRI Findings



**Fig. 4:** Distribution of the studied cases according to MRI Findings

MRI	Histopathological findings				Sensitivity	Specificity	PPV	NPV	Accuracy
	Negative (n = 26)		Positive (n = 8)						
	No.	%	No.	%					
Negative (n = 23)	24	92.3	0	0.0	100%	92.3%	80%	100%	96.2%
Positive (n = 11)	2	7.7	8	100					
$\chi^2(p)$	25.08(0.000**)								

X2: Chi Square test PPV: Positive predictive value NPV: Negative predictive value \*\* Highly statistically significant  $p \leq 0.001$

**Table 6:** Association (sensitivity, specificity and accuracy) for MRI.

MRI	Histopathological findings				Sensitivity	Specificity	PPV	NPV	Accuracy
	Negative (n = 26)		Positive (n = 8)						
	No.	%	No.	%					
Negative (n = 23)	24	92.3	0	0.0	100%	92.3%	80%	100%	%96.2
Positive (n = 11)	2	7.7	8	100					
$\kappa(p)$	0.850 (0.000**)								
Level of agreement	Substantial agreement								

K: Kappa test PPV: Positive predictive value NPV: Negative predictive value \*\*Highly Statistically significant  $p \leq 0.001$

**Table 7:** Agreement (sensitivity, specificity and accuracy) for MRI.

Kappa	Interpretation
< 0	Poor agreement
0.0 – 0.20	Slight agreement
0.21 – 0.40	Fair agreement
0.41 – 0.60	Moderate agreement
0.61 – 0.80	Substantial agreement
0.81 – 1.00	Almost perfect agreement

## DISCUSSION

Thyroid nodules are common and might be difficult to treat clinically. Malignant nodules have atypical nuclei, atypical parenchyma, and high cellular numbers than benign thyroid nodules, resulting in crowded cells and subsequently decreased extracellular space.<sup>2</sup>

According to research, routine imaging studies result in a high rate of incidental thyroid nodule discovery. Thyroid nodules percentage have raised from 20% to 67% in some groups of individuals as a result of the extensive use of sonography in clinical practice.<sup>1</sup>

The initial modality employed in order to diagnose a thyroid enlargement is ultrasound. It is, however, ineffective at distinguishing benign from malignant tumors.<sup>4</sup>

The use of FNAB to discriminate such lesions is common and very successful. Even with expert hands, however, 28 percent of patients were found to be inconclusive. A novel non-invasive pre-surgical diagnostic tool is needed to reduce the risk of unnecessary surgery.<sup>4</sup>

However, FNAC have some limitations in thyroid nodules such as insufficient samples, unspecified cell shapes, sampling mistakes, the possibility of hemorrhage, pain, and not differentiating between benign follicular adenomas and adenocarcinomas. In those nodules, confirmatory results rely on permanent post-surgical histopathological examination results.<sup>4</sup>

An MRI technique that can be used to assess the nature of a thyroid nodules is diffusion weighted imaging.<sup>5</sup>

The flow of water in intracellular and extracellular regions, as well as intravascular areas, produces a diffusion weighted signal. The MRI image appears based on the degree of cellularity. The extracellular gaps in malignant tumors have decreased, resulting in a decrease in the apparent diffusion coefficient.<sup>5</sup>

Thyroid lesions' MRI signal intensity criteria may help in differentiation between various types of thyroid pathologies, thereby enhancing therapeutic care. DWI has been used in some trials to elaborate malignant thyroid lesions. Malignant lesions are found to have lower ADC rates than benign thyroid nodules.<sup>1</sup>

Although T1 weighted images were ineffective in elaboration of malignant and benign thyroid lesions, it might be useful in detection of bleeding or fat inside the nodules when combined with T2 weighted images.<sup>1</sup>

Water diffusion is restricted in malignant tumors because of hypercellularity and increased nuclei, according to research. Low ADC values are caused by an increase in cell counts, a restriction of intracellular spaces, and diffusion of water.<sup>4</sup>

In this study, a total of 34 people with 34 thyroid nodules were enrolled. Among them 28 females (82.4%) and 6 males (17.6%). They were between the ages of 25 and 70. The maximum diameter of the nodules sized from 14 to 62 mm (mean diameter of 31.29 mm). The left lobe of the thyroid gland had 23 nodules, whereas the right lobe had 11 lesions.

There was no statistical difference in the size of the nodule, its location, the ages, or the sexes of the individuals studied. Thyroid lesions were more common in females than males, regardless of malignancy, which is consistent with.<sup>1,4,5</sup>

In this research, DW MRI was done for all individuals at b value of 600 s/mm<sup>2</sup>. Thyroid nodule mean ADC values were determined. Thyroid nodule ADC values calculated 0.40 to 2.40 x 10<sup>-3</sup> mm<sup>2</sup>/s in benign nodules (mean: 1.61, SD: 0.53). Thyroid nodule ADC values in the malignant group calculated 0.50 to 0.93 x 10<sup>-3</sup> mm<sup>2</sup>/s (mean: 0.75, SD: 0.18).

ADC values differs significantly from benign and malignant thyroid nodules (p-value=0.000\*\*). DWI and ADC mapping revealed 24 nodules to be benign with ADC rates greater than 0.93 x 10<sup>-3</sup> mm<sup>2</sup>/s while 10 nodules to be malignant with ADC rates lower than 0.921 x 10<sup>-3</sup> mm<sup>2</sup>/s.

According to histopathological results, the ADC value for three nodules calculated 0.93 x 10<sup>-3</sup> mm<sup>2</sup>/s, with two of them being malignant and one being benign (area of overlap).

The results of the histopathological examination were used as the highest standard for malignancy in this investigation. All of the nodules were histopathologically examined, and the results yielded that 26 nodules were benign (76.5%) and 8 nodules were malignant (23.5%), respectively.

The results of histopathologic examinations were compared to DWI and ADC values derived by MR Imaging.

In order to distinguish benign from malignant thyroid lesions, an ADC of 0.9 10<sup>-3</sup> mm<sup>2</sup>/s was chosen as a cutoff rate from the ROC curve. For the b value 600 s/mm<sup>2</sup>, the sensitivity, specificity, PPV, NPV, and p value were 100, 92.3, 80, 100, and = 0.000\*\*, respectively.

Sensitivity was found to be 100% as the ADC rate of all benign nodules were ranging from 0.40 and 2.40 x 10<sup>-3</sup> mm<sup>2</sup>/s in other words no false negative results for malignancy were detected.

According to histopathological data, the specificity was 92.3%, with ADC rates of 0.32 and 0.35 x 10<sup>-3</sup> mm<sup>2</sup>/s for two benign lesions, respectively. In other words, out of 26 benign nodules, two false positive results for malignancy were detected.

Our findings were similar to those of Mutlu H. et al.<sup>6</sup>, who discovered that the specificity, sensitivity, NPV, PPV, and accuracy rates for ADC values in distinguishing between benign and malignant thyroid lesions were calculated as 97%, 80%, 96%, and 97% respectively, for b values 50, 400, and 1000 s/mm<sup>2</sup> when using a cut off value of 1.0 x 10<sup>-3</sup>.<sup>4</sup>

Our findings differed from those of Abdel-Rahman et al.<sup>4</sup> study, who chose a higher ADC rates of 1.5 x 10<sup>-3</sup> mm<sup>2</sup>/s as a cutoff rate for distinguishing benign from malignant solitary thyroid nodules. For b value of 1000 s/mm<sup>2</sup>, the specificity, sensitivity, NPV, PPV and p value were 100%, 100%, 100%, 100%, 100, and 0.001, respectively. Similarly; Nakahira et al.<sup>8</sup> discovered that for P value 1000 s/mm<sup>2</sup>, a higher cutoff value of 1.61 x 10<sup>-3</sup> mm<sup>2</sup>/s resulted in specificity and sensitivity of 82.60%, 94.73% respectively, and accuracy of 88.09%, for malignant nodules.<sup>4</sup>

In 2014, a meta-analysis of seven identical studies on the use of diffusion weighted imaging to distinguish malignant and benign nodules was published, with the conclusion that DWI can be used as an evolving technique to elaborate pathologically different thyroid lesions (benign or malignant) by calculating the ADC rates. In a further meta-analysis published in 2016, eight additional references were added that were not included in the previous one. It addressed at the technical elements of DWI as well as its potential for tumor characterization. According to this finding, DWI is a reliable approach for identifying malignant thyroid lesions.<sup>2</sup>

Due to the differences in MRI systems, coils, and pulse sequences, the specific threshold rate for detecting thyroid cancer should be determined by each MRI device.<sup>4</sup>

here are some inherent limitations to our study that should be noted when interpreting our findings. To begin with, this study was retrospective as well as with a small sample size, which could have resulted in selection bias, which is a problem in diagnostic studies because it can lead to an overestimation of diagnostic accuracy. To validate our quantitative findings, more clinical investigations are needed. Second, the microcystic component of thyroid nodules may alter our end results, despite the fact that we carefully escaped cystic parts of thyroid nodules in signal intensity assessments. Third, even if they are uncommon, alternative histologic types should be studied in future trials. Finally, case follow-up is challenging because, currently, the first line of treatment is usually total surgical thyroidectomy, and some investigations have shown that benign thyroid nodules can include concealed thyroid cancer.<sup>1;2</sup>

### CONCLUSION

Quantitative DWI has a significant sensitivity and specificity, suggesting that it could be a reliable, painless, and non-radiating imaging approach for thyroid nodule elaboration. The ADC readings appear to have the power to distinguish between

nodules of benign nature and those of malignant nature. So, adding to thyroid US as well as US guided-FNAC for visualization of thyroid nodules cellular structure, DWI appears to have considerable utility as a diagnostic modality, and these data may potentially play a part in determination of nodules that will need FNAC. Diffusion-weighted MRI might be included in the usual modalities used for elaborating malignant and benign thyroid nodules, but more research is needed.

Conflict of interest : none

### REFERENCES

1. Noda Y., Kanematsu M. Goshima S. et al, 'MRI of the Thyroid for Differential Diagnosis of Benign Thyroid Nodules and Papillary Carcinomas.', *AJR*. 2015; 204; W332–W35.
2. Chen L., Xu J., Bao J., et al ; 'Diffusion-Weighted Mri in Differentiating Malignant from Benign Thyroid Nodules: A Meta-Analysis', *BMJ Open*. 2016; 6(e008413).
3. Wu Y., Yue X., Shen W., Du Y., Yuan Y., Tao X. and Tang C. Y., 'Diagnostic Value of Diffusion-Weighted MR Imaging in Thyroid Disease: Application in Differentiating Benign from Malignant Disease', *BMC Medical Imaging*. 2013; 13:23
4. Abdel-Rahman H.M., Abowarda M.H. and Abdel-Aal S.M, 'Diffusion-Weighted MRI and Apparent Diffusion Coefficient in Differentiation of Benign from Malignant Solitary Thyroid Nodule.', *The Egyptian Journal of Radiology and Nuclear Medicine*. 2016; 45: 1385-90
5. Abd El Aziz L.A., Hamisa M. and Badwy M.E., 'Differentiation of Thyroid Nodules Using Diffusion-Weighted MRI', *Alexandria. Journal of Medicine*. 2015; 51:305–9
6. Mutlu H., Sivrioglu A. and Sonmez G., 'Role of Apparent Diffusion Coefficient Values and Diffusion-Weighted Magnetic Resonance Imaging in Differentiation between Benign and Malignant Thyroid Nodules', *Clin Imag*. 2011; 36(1):1-7
7. Abdel Razeq A.A.K., Sadek A.G., Kombar O.R., Elmahdy T.E. el al., 'Role of Apparent Diffusion Coefficient Values in Differentiation between Malignant and Benign Solitary Thyroid Nodules', *AJNR Am J Neuroradiol*. 2008; 29:563–8
8. Nakahira M., Saito N. and Murata S. I., 'Quantitative Diffusionweighted Magnetic Resonance Imaging as a Powerful Adjunct to Fine Needle Aspiration Cytology for Assessment of Thyroid Nodules', *Am J Otolaryngol*. 2012; 33(4):408-16
9. Schueller-Weidekamm C., Kaserer K., Schueller G., Scheuba C., et al, 'Can Quantitative Diffusion-Weighted MR Imaging Differentiate Benign and Malignantcold Thyroid Nodules? Initial Results in 25 Patients', *AJNR Am J Neuroradiol*. 2009; 30:417–22