

## Radiological Interventional and Imaging procedures in management of patient with Malignant Obstructive Jaundice

Mohammed Nagah Abdelghafar Salim <sup>1</sup>\*M.B.B.Ch; Tarek Mohammed Al ziat <sup>2</sup>MD and Mohammed Salah Elfeshawy <sup>2</sup>MD.

### \*Corresponding Author:

Mohammed Nagah Abdelghafar Salim  
[mohammednagahsalim@gmail.com](mailto:mohammednagahsalim@gmail.com)

Received for publication May 24, 2022; Accepted November 22, 2022; Published online November 22, 2022.

doi: 10.21608/aimj.2022.140605.1954

**Citation:** Mohammed N. , Tarek M. and Mohammed S. Radiological Interventional and Imaging procedures in management of patient with Malignant Obstructive Jaundice. AIMJ. 2022; Vol.3-Issue11 : 154-159.

<sup>1</sup>Resident of Radiodiagnosis Department, Tanta Cancer Center, Egypt.

<sup>2</sup>Radiodiagnosis Department, Faculty of Medicine, Al-Azhar University, Cairo , Egypt.

### ABSTRACT

**Background:** Malignant biliary obstruction has a bad prognosis and adverse effect on the quality of life, with most of those patients are inoperable at time of diagnosis.

**Aim of The Work:** To evaluate the efficacy of different modalities of interventional radiological and imaging procedures as Percutaneous Transhepatic cholangiography (PTC), Percutaneous Transhepatic drainage (PTD) and biliary stenting in management of patients with malignant obstructive jaundice.

**Patients and Methods:** This study included 30 patients already diagnosed with malignant obstructive jaundice attending to Tanta Cancer Center (TCC) from MARCH 2021 to SEPTEMBER 2021.

**Results:** the highest rate of complication was among the percutaneous drainage group and the commonest occurring complication in the study was hemobillia. Among different groups in our study the lowest mean total bilirubin level 15 days after drainage was achieved with metallic stenting (3.8 mg/ml), while the highest mean total bilirubin level 15 days after drainage was seen in percutaneous external drainage (10 mg/dl).

**Conclusion:** Interventional radiology offers a great benefit for patients with malignant biliary obstruction in the term of symptomatic relief thus improving the quality of life.

**Keywords:** Cholangiography; Complication; Interventional; Percutaneous Transhepatic drainage.

**Disclosure:** The authors have no financial interest to declare in relation to the content of this article. The Article Processing Charge was paid for by the authors.

**Authorship:** All authors have a substantial contribution to the article.

**Copyright** The Authors published by Al-Azhar University, Faculty of Medicine, Cairo, Egypt. Users have the right to read, download, copy, distribute, print, search, or link to the full texts of articles under the following conditions: Creative Commons Attribution-Share Alike 4.0 International Public License (CC BY-SA 4.0).

### INTRODUCTION

The biliary system consists of organs and ducts (bile ducts, gallbladder, and associated structures) that are involved in the production and transportation of bile.<sup>1</sup>

There are multiple causes of biliary obstruction as gall stones, malignant obstruction by hepatic, pancreatic or common bile duct tumors, also inflammation of bile ducts may cause biliary obstruction.<sup>2, 3</sup>

Diagnosis of obstruction is achieved by non-invasive and invasive procedures: Non-invasive procedures include ultrasonography and MRCP; the invasive procedures include ERCP and PTC which has diagnostic and therapeutic role.<sup>4</sup>

Malignant biliary tract obstruction (MBTO) is a frequent cause of jaundice. Primary pancreatobiliary tract cancers and other local cancers that can cause compression of the biliary tract (e.g., liver, gallbladder) account for approximately 80,000 new cancer cases MBTO can also arise from gallbladder, duodenal, and ampullary cancers; metastatic cancers; or malignant lymphadenopathy.<sup>5</sup>

PTC is predominantly now performed as a therapeutic technique. There are less invasive means of imaging the biliary tree including transabdominal ultrasound.<sup>6</sup>

Additionally, self-expanding metal stents can be placed across malignant biliary strictures to allow palliative drainage. Percutaneous placement of metal stents can be utilized when therapeutic ERCP has been unsuccessful; two types of biliary stent are used as metal and plastic types.<sup>7, 8</sup>

The purpose of the study was to evaluate the efficacy of different modalities of interventional radiological and imaging procedures as Percutaneous Transhepatic cholangiography (PTC), Percutaneous Transhepatic drainage (PTD) and biliary stenting in management of patients with malignant obstructive jaundice.

### PATIENTS AND METHODS

This study included 30 patients already diagnosed with malignant obstructive jaundice attending to Tanta Cancer Center (TCC) from MARCH 2021 to SEPTEMBER 2021.

They were 19 male and 11 females. Their ages ranged from 37 to 75 years.

**Inclusion criteria:** Failed ERCP, Inoperable patients as patients with irresectable tumor, patients with

cardiac dysfunction or renal impairment, Pre-operative for patients with malignant obstructive jaundice fit for operation and post-operative for management of complications, Patients with malignant obstructive jaundice who refused surgical operation.

**Exclusion criteria:** Patients with bleeding disorders, pregnancy (as there is high risk of radiation exposure).

**Patients were subjected to the following:**

**Clinical assessment:** History taking including: Patient's age, patient's complaint such as; yellowish discoloration of the skin and sclera, dark urine, abdominal pain, abdominal swelling, fever, rigors ... etc and history of; operations, primary tumor, previous biliary interventions. General examination: Patients were examined searching for; fever, cachexia, anemia ... etc. Abdominal examination: Local abdominal examination was performed searching for; hepatomegaly splenomegaly, ascites, abdominal masses, palpable gallbladder etc.

**Laboratory assessment:** All patients were assessed by laboratory investigations including; total and direct serum bilirubin, alkaline phosphatase, serum liver enzymes including serum glutamic pyruvic transaminase (SGPT) and serum glutamic oxaloacetic transaminase (SGOT), prothrombin time and concentration.


**Radiological assessment:** All the patients were subjected to: Recent abdominal ultrasound: to confirm the patient's status, Triphasic CT study in cases of hepatic tumors, MRCP for detection of degree and levels of biliary obstruction (not for all) and direct cholangiography just before drainage through percutaneous approach.

**Preprocedures preparation:** Coagulation profile was assessed especially prior to biliary drainage procedures, prothrombin time was ascertained to be within suitable limits (No more than 4 seconds greater than the control) and platelet count not less than 80,000/mm<sup>3</sup>, otherwise they were corrected by administration of vitamin K, platelets and fresh frozen plasma, patients were fasting for 6-8 hours, procedures were explained to the patient, informed consent was signed by the patient or his/her relatives. Pulse oxymeter was available for patient monitoring. Oxygen supply was available for use. Aseptic conditions were ascertained, intravenous cannula was inserted, in patients prepared for biliary drainage: Prophylactic broad spectrum antibiotics were given 1 hour before the procedure and intravenous fluid infusion started just before the procedure and continued during it.

**Percutaneous Transhepatic Cholangiography (PTC):** PTC was done for all patients to confirm the diagnosis and as a primary step before percutaneous interventional techniques.

**Interventional Radiological Techniques:** The following different interventional radiological techniques were done to our patients guided by their diagnosis, clinical state and strategy of management: External biliary drainage, internal- external biliary drainage, biliary endoprosthesis: Metallic stent and plastic stent and combined percutaneous and endoscopic technique.

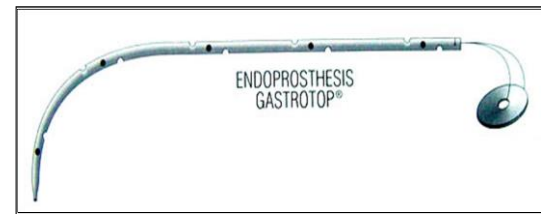
**Percutaneous External Biliary Drainage:** was done to drain the obstructed biliary system. The used catheters were: Pigtail catheters 8-12 F. and Femoral catheter 6-8 F.



**Fig. 1:** Percutaneous External Drainage pigtail catheter

**Percutaneous Internal- External Biliary Drainage:** This method was used to internally drain patients in case of duodenal infiltration which was a contraindication for endoprosthesis and if dilatation of the liver track to large size to be fit for stent caliber carried a high risk of bleeding or intolerable by the patient. Pigtail catheters were used (of 10 and 12 F caliber).

**Endoprosthesis: Metallic:** When GW can bypass the obstruction in these patients, 5F catheter is used to traverse the stricture over it. A memotherm self-expandable stent was introduced along the strictured segment. **Plastic:** In these patients the tract was dilated by serial dilators to the diameter of the stent. Plastic stent was inserted over the GW and inner 7-8 F catheter of stiffer and pushed by pusher which is of the same caliber of the stent.



**Fig. 2:** Percutaneous plastic Carey Coons stent

**IV: Combined Endoscopic & Percutaneous Drainage Technique (Rendez-Vous)**

It was done when cannulation with ERCP was difficult and the GW passed through the obstructed segment Percutaneously.

**Post-drainage care**

Bed rest for 24 hrs, antibiotics are continued for 2 days after the procedure, daily flushing of the catheter by sterile saline (in patients with external and internal- external drainage), cholangiography was done 3 days after the procedure, when the bile flow decreases visibly (in patients with external and internal- external drainage) and the following parameters were studied: Clinical response to drainage, laboratory response to drainage and frequency of complications.

**Statistical Methodology:** Analysis of the data was performed by: Statistical program of Social Science (SPSS) windows version (8) on IBM Computer, Description of quantitative variables in the form of mean and standard deviation (SD), Description of qualitative variables in the form of number and percentage. Comparison of quantitative variables was

confirmed by using paired t test to compare data in the same group. One way ANOVA (Analysis of

variants) test to compare more than two groups as regard quantitative variable.

**RESULTS**

Type of tumor	N	%
Cancer head of pancreas	12	40 %
Cholangiocarcinoma	8	26.6%
Periampullary carcinoma	4	13.3%
Hepatic metastasis	4	13.3%
enlarged porta hepatis lymph node	2	6.6 %

**Table 1:** Causes of malignant obstructive jaundice among study groups:

Cancer head of pancreas was the commonest cause (40%) of malignant obstructive jaundice in our study.

	N = 30	%
Percutaneous external drainage (Group 1)	12 patients	40.0%
Internal & external drainage (Group 2)	10 patients	33.3%
Percutaneous Metallic stent (Group 3)	4 patients	13.3%
Percutaneous Plastic stent (Group 4)	2 patients	6.7%
Rendez vous (Group 5)	2 patients	6.7%

**Table 2:** Frequency of interventional procedures for study groups:

Follow up of the patients after the procedure was done by laboratory investigation (total bilirubin level). We chose the 15 day total bilirubin level as an indicator of therapeutic success. Among different groups in our study the lowest mean total bilirubin level 15 days after drainage was achieved with metallic stenting (3.8 mg/ml), while the highest mean total bilirubin level 15 days after drainage was seen in percutaneous external drainage (10 mg/dl).

	Total Bilirubin Before		Total Bilirubin After		t-test	P-value
	Mean (mg/dl)	(SD)	Mean (mg/dl)	(SD)		
Group (1) N = 12	24.5	(5.3)	10	(3.1)	12	P<0.05*
Group (2) N = 10	17.02	(2.7)	3.8	(1.09)	14.5	P<0.01**
Group (3) N = 4	18.3	(4.1)	4.9	(3.8)	4.5	P<0.05*
Group (4) N = 2	16.4	(3.2)	6.2	(4.3)	10.7	P<0.01**
Group (5) N = 2	15.3	(4.5)	6.2	(4.4)	10.2	P<0.01**

**Table 3:** Comparison of total bilirubin before and after procedure among different study groups

Procedure	N	%	Complications
Percutaneous external drainage N = 12			
+ ve	3	25.0%	- Hemobillia.
- ve	9	75.0%	- Sub capsular leakage.
			- Dislodgement.
Internal & external Drainage N = 10			
+ ve	1	10.0%	- Cholangitis
- ve	9	90.0%	
Percutaneous Metallic stent N = 2			
+ ve	0	0%	
- ve	2	100 %	
Percutaneous Plastic stent N = 2			
+ ve	1	50 %	- Stent occlusion.
			- Hemobillia.
- ve	1	50 %	
Rendez vous technique N = 2			
+ ve	0	0%	
- ve	2	100%	

\*\* +ve □ complications

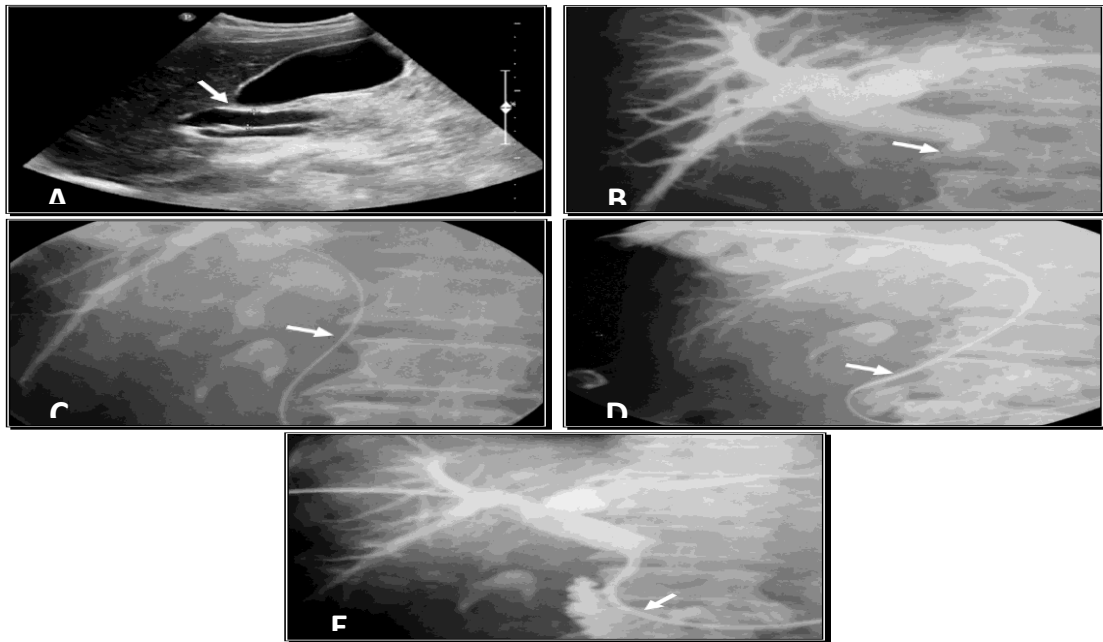
\*\* - ve ◊ No complications

**Table 4:** Frequency of complications among different procedures

The highest rate of complication was among the percutaneous drainage group and the commonest occurring complication in the study was hemobillia.

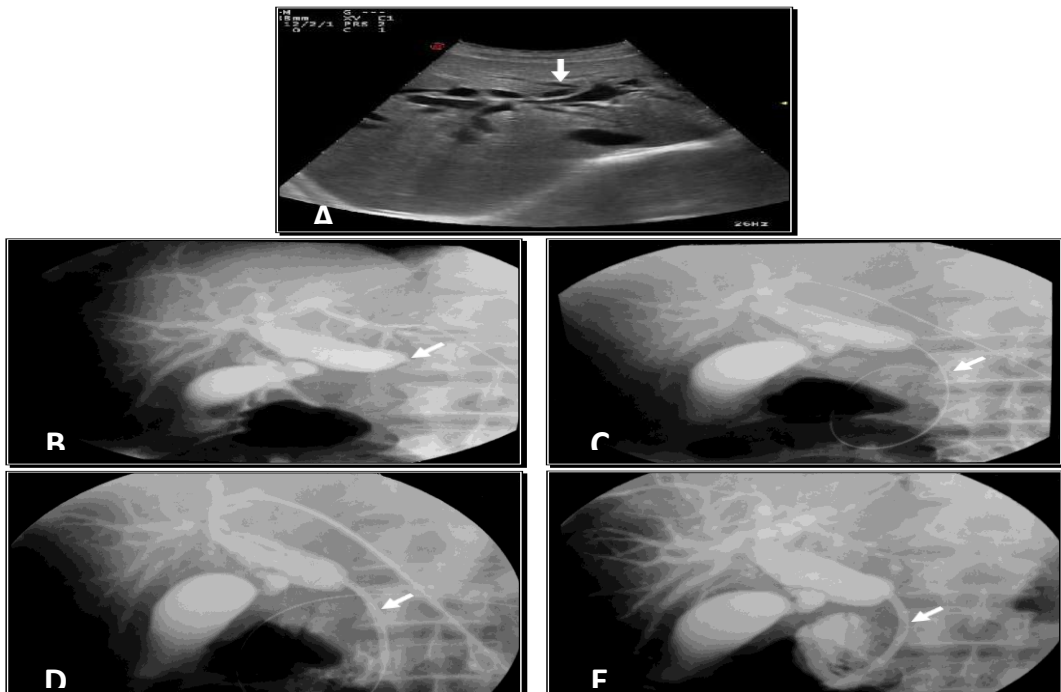
## Case No. (1)

Male patient aged 64 years old diagnosed to have periampullary carcinoma. Total bilirubin level reached 19 mg/dl. Internal-External drainage was done.



**Fig. 3:** (A): Ultrasound showed dilated CBD caliber reaching 11mm (arrow) with no detectable masses or stones inside its lumen. (B): PTC showed dilated IHBR and CBD till a tight obstructing stricture is seen (arrow). (C): A guide wire succeeded to cross the stricture into the duodenum (arrow). (D): A catheter passed through the stricture over the guide wire (arrow). (E): Inserted internal –external pigtail catheter with free contrast flow into the duodenum (arrow).

Case No. (2): Male patient aged 73 years old diagnosed to have distal CBD cholangiocarcinoma. Total bilirubin level reaches 23 mg/dl. Percutaneous plastic stent was inserted through left duct approach.



**Fig. 5:** (A): Ultrasound showed intrahepatic biliary radicles dilatation (arrow) more evident at the left side. (B): PTC through left duct puncture revealed dilated IHBR and CBD till its distal part where tight stricture was seen (arrow) with no detected contrast in the duodenum. (C): A guide wire was succeeded to cross the stricture into the

duodenum (arrow). (D): A dilator introduced over the guide wire crossed the stricture to the duodenum (arrow). (E): A percutaneous plastic stent was inserted with free flow of contrast into the duodenum (arrow).

### DISCUSSION

The biliary system consists of the organs and ducts (bile ducts, gallbladder, and associated structures) that are involved in the production and transportation of bile.<sup>9</sup>

This prospective study conducted between March 2021 to September 2021 on thirty patients already diagnosed with malignant obstructive jaundice who referred to Radiodiagnosis department at Tanta Cancer Center (TCC), including 19 male patients representing 63.3 % and 11 females representing 37.6 % of the patients.

In a study by Dawoud et al.,<sup>10</sup> there were 30 patients (19 males and 11 females) with mean age of 56 years, 28 of 30 patients (93.3%) are non-operable and the other 2 of 30 patients (6.7%) operated patients for choledochojunostomy stenosis were subjected to intervention techniques

This study showed that Cancer head of pancreas was the commonest cause (40%) of malignant obstructive jaundice in our study.

Dawoud et al.,<sup>10</sup> showed that patients were already diagnosed with obstructive jaundice due to malignant cause, 12 of them were diagnosed to have pancreatic head cancer representing 40% of the patients, 8 of them were diagnosed with cholangiocarcinoma (central and peripheral types) 26.6%, 4 were diagnosed with periampullary carcinoma 13.3%, 4 with enlarged porta hepatis lymph node 13.3% and the last two were diagnosed with hepatic metastasis 6.6%

In agreement with our results, Dawoud et al.,<sup>10</sup> showed that Patients underwent different interventional techniques: 1- Percutaneous transhepatic external biliary drainage: Was done in 10 patients: • Failure to bypass biliary stricture in 6 patients. • Pre-operative for symptomatic relief in 2 patients who underwent whipple operation. • Lack of financial support or patient's refusal to complete the procedure in 2 patients. 2- Percutaneous metallic stenting: Was done in 8 patients: • Six patients of them were unfit for operation. • The other 2 with post-operative (whipple operation) choledochojunostomy stricture. 3- Percutaneous plastic stenting: Was done in 7 patients. 4- Internal-external drainage: Was done in 3 patients. 5- Rendez vous technique: Was done in 2 patients.

This result is higher than that mentioned in the study of Pinol et al.,<sup>11</sup> who reported technical success rate of 75% for percutaneous metallic stenting.

On the other hand, Schoder et al.,<sup>12</sup> and Inal et al.,<sup>13</sup> reported 100% technical success rate for percutaneous metallic stenting. This difference may be due to the variability of personal experience or the degree of tightness of biliary obstruction and tumour infiltration.

Our study showed that among different groups in our study the lowest mean total bilirubin level 15 days after drainage was achieved with metallic stenting

(3.8 mg/ml), while the highest mean total bilirubin level 15 days after drainage was seen in percutaneous external drainage (10 mg/dl).

Our results are in accordance with Pinol et al.,<sup>11</sup> who found that the mean total bilirubin 15 days after drainage was 7.8mg/dl for the endoscopic group and 5.2mg/dl for the percutaneous metallic stent group. In 30 patients underwent biliary drainage, complications occurred in 6 patients (20%). This percentage is lower than that reported by Indar et al.,<sup>14</sup> who found that early overall complications occurred in 30% of patients.

Our results are in accordance with Pinol et al.,<sup>11</sup> who found that the mean total bilirubin 15 days after drainage was 7.8mg/dl for the endoscopic group and 5.2mg/dl for the percutaneous metallic stent group

This study showed that the highest rate of complication was among the percutaneous drainage group and the commonest occurring complication in the study was hemobilia.

Dawoud et al.,<sup>10</sup> showed that the highest rate of complications was among the percutaneous drainage group and the commonest occurring complication in the study was hemobilia

There were significant clinical advantages for the metallic stents over plastic stents. Less occlusion occurs in metallic stents with wider caliber, so; despite the higher initial expense of the metallic stent, a cost benefit advantage results from the reduced need for subsequent intervention.

This is the same conclusion reached by many investigators like Carr-Locke et al.,<sup>15</sup> Schmassmann et al.,<sup>16</sup> and Kaassis et al.,<sup>17</sup>. This advantage of metallic over plastic stent is valuable only when the patient is expected to survive for a relatively long period (6 months). Conio et al.,<sup>18</sup> mentioned several prognostic factors as absence of liver metastasis, tumour size less than 3cm, stricture less than 2cm and bilirubin less than 3.2mg/dl. These parameters should be considered when thinking to insert a metallic stent.

The study has three limitations. First, the limited numbers of patients involved in this study. Second, lack of financial support altered the decision for some cases and the last one was technical in two cases who intubation of the dilated biliary radical failed because of repeated trails.

### CONCLUSION

We can say that interventional radiology offers a great benefit for patients with malignant biliary obstruction in the term of symptomatic relief thus improving the quality of life.

Conflict of interest : none

### REFERENCES

1. Benjamin J. Biliary tract interventions. *Tech Vasc Interv Radiol.* 2009; 12(2):162–70.



2. Kirsten K, Bert van R, Thomas L, Marc G, Dirk J, Tom K, et al. Acute cholecystitis in high risk surgical patients: percutaneous cholecystostomy versus laparoscopic cholecystectomy (CHOCOLATE trial): study protocol for a randomized controlled trial, 2012.
3. Stoeckel D, Pelton A, Duerig T. Selfexpanding nitinol stents: material and design considerations. *Eur Radiol.* 2010; 14(2):292–301.
4. Gwon DI, Shim HJ, Kwak BK. Retrievable biliary stent-graft in the treatment of benign biliary strictures. *J Vasc Interv Radiol.* 2008; 19(9):1328–35.
5. Ginat D, Saad WE. Cholecystostomy and transcholecystic biliary access. *Tech Vasc Interv Radiol.* 2008; 11(1):2–13.
6. Fernanda P, Melissa P, Monica R, Timothy S, Michel K. Biliary leak in post-liver- transplant patients: is there any place for metal stent? *HPB Surgery.* 2012.
7. Moreels TG. Altered anatomy: enteroscopy and ERCP procedure. *Best Pract Res Clin Gastroenterol.* 2012; 26(3):347–57.
8. Judah JR, Draganov PV. Intraductal biliary and pancreatic endoscopy: an expanding scope of possibility. *World J Gastroenterol.* 2008; 14(20):3129–36.
9. Rawat, T. K. Modelling and analysis of bile flow in human biliary system, 2020.
10. Dawoud A, Radiological Intervention and Imaging Procedures in Management of Patients with Malignant Obstructive Jaundice. *The Medical Journal of Cairo University.* 2019; 87. 2791-800. 10.21608/mjcu.2019.59308.
11. Pinol V, Castells A, Bordas Jm. Percutaneous self-expanding metal stents versus endoscopic polyethylene endoprosthesis for treating malignant biliary obstruction: *Randomized clinical trial. Radiology.* 2012; 225: 27-34.
12. Schoder M, Rossi P, Uflacker P. Malignant Biliary Obstruction: Treatment with ePTFE-FE Pcovered Endoprosthesis-Initial Technical and Clinical Experiences in a Multicenter Trial, *Radiology.* 2002; 225: 35- 42.
13. Inal M, Akgul E, Aksungur E. Percutaneous self-expandable uncovered metallic stents in malignant biliary obstruction. Complications, follow-up and re intervention in 154 patients. *Acta Radiol.* 2003; 44: 139-46.
14. Indar A, Lobo D, Gilliam Ad. Percutaneous biliary metal wall stenting in malignant obstructive jaundice. *Eur. J. Gastroenterol. Hepatol.* 2003; 15: 915-9.
15. Carr-Locke D, Ball T. And Connors P. Multicenter randomized trial of Wallstent biliary endoprosthesis versus plastic stents, *Gastrointest. Endosc.* 2010; 39: 310.
16. Schmassmann A, Von Gunten E, Knuchel J, Scheurer U, Fehr HF, HALTER F. Wallstents versus plastic stents in malignant biliary obstruction: Effects of stent patency of the first and second stent on patient compliance and survival. *Am. J. Gastroenterol.* 2008; 91: 654-9.
17. Kaassis M, Boyer J, Dumas R. Plastic or metal stents for malignant stricture of the common bile duct? Results of a randomized prospective study. *Gastrointest. Endosc.* 2003; 57 (2): 178-82.
18. Conio M, Demarquay J, Deluca L, Marchi S, Dumas R. Endoscopic treatment of pancreaticobiliary malignancies, *Oncology Hematology.* 2011; 37: 127-35.