

## Role of CT-Virtual Bronchoscopy in Haemoptysis

Emad El-Dien Othman Abdel-Galiel Saad El-Dien <sup>1</sup>\*M.B.B.Ch; Ahmed Abdel-Fattah Abou-Rashed <sup>1</sup>MD ;  
Mohammed Salah El-Feshawy <sup>1</sup>MD and Faried Shawky Basyon <sup>1</sup>MD.

**\*Corresponding Author:**

Emad El-Dien Othman Abdel-Galiel  
Saad El-Dien  
[emad.osman233@gmail.com](mailto:emad.osman233@gmail.com)

Received for publication July 07, 2022; Accepted November 22, 2022;  
Published online November 22, 2022.

doi: 10.21608/aimj.2022.148053.2036

**Citation:** Islam M. , Mostafa F. and Ahmed M. Role of CT-Virtual Bronchoscopy in Haemoptysis. AIMJ. 2022; Vol.3-Issue10 : 167-173.

<sup>1</sup>Radiodiagnosis Department, Faculty of Medicine, Al-Azhar University, Cairo , Egypt.

**ABSTRACT**

**Background:** For tracheobronchial diseases, fiberoptic bronchoscopy (FOB) continues to be the gold standard diagnosing technique. It is a rather secure diagnostic and therapeutic method. Because of its excellent sensitivity, fiberoptic bronchoscopy is now the primary diagnostic method for assessing tracheobronchial endoluminal and mucosal diseases.

**Aim of The Work:** To compare virtual bronchoscopy with fiberoptic bronchoscopy as the gold standard tool in diagnosis of cases of hemoptysis and identifying tracheobronchial disorders in patients having clinical and/or radiological reasons for bronchoscopy.

**Patients and Methods:** Patients having hemoptysis with or without CXR or conventional CT abnormalities. Patients with high creatinine level, lactating and pregnant women were excluded from the study.

**Results:** For the research, 50 patients were qualified. There were 50 research participants, 36 of whom were men (72%) and 14 of them were women (28%). The research group's average age was 59, with a standard deviation  $\pm 14$ . Of the 50 patients, 42 patients had tracheobronchial abnormalities on fiberoptic bronchoscopic examination, and virtual bronchoscopic examination confirmed the same abnormality in 37 (88%) patients and did not reveal any abnormality in 5 (12%) patients. an 8 of the 50 patients had no tracheobronchial abnormalities by either diagnostic method. The majority of lesions were obstructive (59.5%), nonobstructive lesions accounted for 23.8%, and partially obstructive lesions accounted for only 16.6%. Regarding the ability to bypass the lesion, out of 42 patients in whom FOB showed a positive lesion, only 15 lesions (35.8%) could be bypassed, while 100% of the lesions detected with VB could be bypassed. Based on the data collected and analysed, the sensitivity of virtual bronchoscopic examination was estimated to be 88% and the specificity was 100%. The PPV and NPV were calculated to be 100% and 61.5%, respectively, and the overall accuracy was estimated to be 90%.

**Conclusion:** Virtual bronchoscopy is an innovative, non-invasive, accurate and uncomplicated diagnostic modality in the diagnosis of tracheobronchial diseases. In particular situations, VB could be the modality of choice, as in the assessment of the airways distal to strictures or stenosis.

**Keywords:** CT-Virtual; Bronchoscopy; Haemoptysis.

**Disclosure:** The authors have no financial interest to declare in relation to the content of this article. The Article Processing Charge was paid for by the authors.

**Authorship:** All authors have a substantial contribution to the article.

**Copyright:** The Authors published by Al-Azhar University, Faculty of Medicine, Cairo, Egypt. Users have the right to read, download, copy, distribute, print, search, or link to the full texts of articles under the following conditions: Creative Commons Attribution-Share Alike 4.0 International Public License (CC BY-SA 4.0).

**INTRODUCTION**

The term "hemoptysis" (plural: hemoptysis) describes the bloody coughing. Generally, it looks bright red in color in contrast to blood from the gastrointestinal system which appears dark red. It is seen as a worrying indicator of a major underlying cause.<sup>1</sup>

A correct diagnosis is necessary for effective therapy of airway illness. Usually necessary for these invasive treatments. The "gold standard" for tracheobronchial pathology identification and diagnosis is rigid or fiberoptic bronchoscopy (FOB). FOB is a procedure that is generally safe, although it can have negative effects, particularly in patients who are at greater risk.<sup>2</sup>

Fiberoptic bronchoscopy enables direct assessment of the respiratory tract's endoluminal and mucosal lesions and may direct biopsies for histological examination. However, traditional bronchoscopy has certain drawbacks, including the inability to pass through severely constricted airways, its limited ability to reveal the amount of extraluminal illness, and some patients' inability to tolerate it. Therefore, it is important to continually develop and improve non-invasive procedures that enable airway examination.<sup>2</sup>

Virtual bronchoscopy has significantly improved in quality and diagnostic capability with the advent of multislice CT scanners into clinical practice. However, it is not well established in the diagnoses of tracheal and bronchial problems, and no enough research has been done on its potential.<sup>3</sup>

The computer-guided bronchoscopy simulation known as virtual bronchoscopy (VB) enables non-

invasive intraluminal examination of the tracheobronchial tree by offering the same view, angles, and zoom setting as actual bronchoscopy. As it is derived from imaging sources not from the direct examination by bronchoscope itself, the term virtual is given.<sup>4</sup>

The quality of CT pictures of thoracic structures, particularly the airways, was significantly enhanced with the introduction of spiral CT to the clinical setting. The quality of 2-D and 3-D reformatted images has significantly improved since the introduction of spiral CT, which has a short scan time and produces a single volumetric data set in a single breath hold. The old conventional "stop and shoot" CT scanners were slow to scan and required multiple breath holds. However, the comparatively lengthy breath-holding intervals of 25 to 30 seconds for standard thick slices and considerably longer scanning times for thin slice pictures still placed a restriction on this technique. Volumetric isotropic voxel imaging was later made possible by multi-detector computed tomography equipment, and further advancements in post-processing software also made three-dimensional (3-D) viewing possible. As a consequence, tracheobronchial diseases may now be diagnosed and interventional operations including bronchoscopy, stent implantation, surgery, and subsequent follow-up can be planned with the use of airway imaging.<sup>5</sup>

Quantitative measures of a lesion's size, its connection to nearby structures, the length of a stenosis, and the width of a bronchus are all possible using VB.<sup>6</sup>

### PATIENTS AND METHODS

**Study Design:** This research was conducted at Al Azhar University Hospitals departments of radiology and chest. The trial was open to 50 participants having hemoptysis and/or any radiological reason hemoptysis. According to inclusion criteria, cases for the research were chosen at random without regard to age or gender. The ethics committee, Faculty of medicine, Al-Azhar University gave the research its approval.

**Inclusion criteria:** Patients having hemoptysis and indicated for bronchoscopy due to a clinical and/ or radiological reason. During the clinical evaluation, the clinical indications were persistent or recurring pulmonary infections, dyspnea, hemoptysis, stridor, and abnormal breathing sounds. The radiological indications were chest X-ray or conventional CT chest abnormalities.

**Exclusion criteria:** Patients with contraindication for VB as; women who were expecting to be pregnant or lactating and those with high blood creatinine levels who weren't receiving regular dialysis. Patients with contraindication for FOB as; people with recent myocardial infarction, unstable angina, severe arrhythmias, CO<sub>2</sub> retention, low PO<sub>2</sub>, coagulation malfunction, and uncontrollable asthma.

All the patients enrolled in the study were subjected to: a written consent, medical history taking (History taking was done with stress on: occupation, smoking, presence of dyspnea, cough, expectoration, chest

pain, hemoptysis, chest wheeze, history of foreign body aspiration, loss of weight dysphagia, hoarseness of voice or any other systemic manifestation denoting distant malignant metastasis), clinical examination (General examination including vital signs, built, nutrition, lymph nodes, edema lower limb, clubbing of the fingers, neck veins, and complete abdominal, neurological, heart and chest examination) and routine laboratory tests: CBC, ESR, bleeding profile, kidney function tests and liver function tests.

**Radiological analysis:** plain chest x-ray: Postero-anterior and lateral views and Multi-slice CT scan of the chest: All patients underwent CT scan of the chest, by MDCT ( Toshiba Prime Aquilion, 160 slices) in the radiology department, Al- Azhar University hospitals. CT scans were done with intravenous, contrast injection for some patients. Coronal and sagittal reformatting was done in all cases.

**Virtual bronchoscopy:** All patients included in the study were evaluated by MDCT (Toshiba Toshiba Prime Aquilion, 160 slices) in the radiology department, Al-Azhar University hospitals. With the following technical parameters: 120 Kvp, 250-300 mAs, with 16×0.75 collimation and 1.00 pitch. The rotation time was 0.42 and the slice thickness and interval was 1 mm each.

Patients scanned in the supine position at suspended full inspiration beginning from the base of the skull down to the upper abdomen including the adrenal glands. Patients were examined with or without IV contrast administration according to the clinical examination and laboratory investigation results. For the cases underwent contrast media injection, they were injected with 50ml of non-ionic contrast media ( ultravist or omnipaque) injected at a rate of 3-5 ml/second.

The images of the selected patients (who had been approved to participate in our study) were transferred to a work station for computer post processing. The post processing was including multi-planar reformatting in the sagittal and coronal planes as well as the minimum intensity projection, volume rendering technique, and a fly through examination of the virtual lumen using an internal rendering technique through Vitrea® software that gives three dimensional view of the airways lumens.

**Image interpretation and recording:** Reports were written for every case after examining both the CT images and the virtual bronchoscopy. Images were evaluated for the presence of an endobronchial mass lesion and its size and location, presence of extraluminal compression, presence of airway stenosis, its site and extent, associated segmental or lobar collapse or parenchymal infiltration, evidence of mediastinal invasion, associated pleural effusion, presence of pulmonary nodules and hilar or mediastinal lymph nodes enlargement.

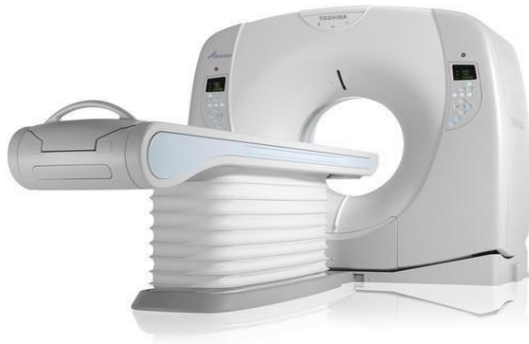

Figure (1): Toshiba Prime Aquilion 160 slice CT

Fiberoptic bronchoscopic examination: All patients included in the research were referred to the bronchoscopy unit of the Chest department, Al-Azhar University hospitals to undergo fiberoptic bronchoscopic examination with in 24 h after the CT examination using Olympus BF- 1T60 fiberoptic bronchoscope (figure 2). The route of introduction was either transnasal or transtracheal (via endotracheal tube). All patients with detected endoluminal lesions were subjected to biopsy for histopathological diagnosis.

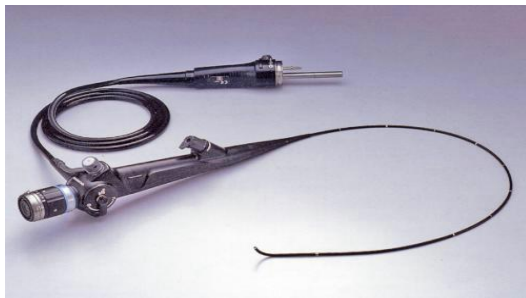


Figure (2): Olympus BF-1T60 fiberoptic bronchoscope

Performing fiberoptic bronchoscopy procedure: A well-equipped facility, skilled staff, pre-procedure examination, and monitoring were all used throughout the operation. After administering topical anesthesia (xylocaine 10 %), conscious sedation with midazolam (planning to start an IV line and titrating midazolam 1mg at a time, watching the patient's response), and administering atropine sulphate, skilled bronchoscopists performed flexible bronchoscopy via the transnasal approach (0.6 milligrams administered intramuscularly 30 minutes before the operation). Close monitoring of oxygen saturation, blood pressure, pulse, and degree of awareness was done throughout the process. To identify any severe endobronchial anomalies, the whole tracheobronchial tree was thoroughly examined. Endobronchial procedures (brushing, biopsy, lavage, transbronchial lung biopsy, or transbronchial needle aspiration) were carried out based on the radiological or

endoscopic results. All specimens were transferred for histopathological examination and diagnosis. Reports were written for every case with a comment on sharpness of carina, evaluation of the whole bronchial segments on each side, presence of any foreign bodies or external compression on the trachea and lastly the diagnostic or therapeutic maneuver which was done. All patients were observed strictly for 90-120 minutes following the bronchoscopy. Post procedure instructions were given to the patients; Not to eat or drink for another two hours, anticipate mild haemoptysis, and call if a fever, shortness of breath, severe haemoptysis or chest pain develops.

Later on, the findings of the virtual bronchoscopy were compared to the findings of fiberoptic bronchoscopy regarding: the presence of intra luminal masses or extra luminal compression, bronchial stenosis sites, extent and the ability of bypassing the stenosis and bronchial obstruction. Results from the virtual bronchoscopy were assessed blinded and separately from those from the fiberoptic endoscope.

**Statistical analysis:** Utilizing version 23 of the Statistical Package for Social Sciences (SPSS), data management and statistical analysis were carried out. Utilizing means and standard deviations, numerical data were summarized. Numbers and proportions were employed to represent a categorical set of data. With the fiber-optic bronchoscope serving as the gold standard, established diagnostic indices such as sensitivity, specificity, positive predictive value (PPV), and negative predictive value (NPV) were determined for the virtual bronchoscope.

The terms true-positive, true-negative, false-positive, and false-negative findings were used to describe the qualitative findings in the description of tracheobronchial abnormalities with VB. In contrast, a true-negative result was described as the lack of airway abnormalities in each of the two testing modalities. A true-positive finding was characterized as an abnormality found in both modalities (FOB and VB). A tracheobronchial segment that was detected as abnormal on VB but normal on FOB was referred to as a false-positive result. A tracheobronchial segment that showed normal on VB but abnormal on FOB was referred to be a false-negative result. These calculations for sensitivity, specificity, and accuracy were made: Accuracy (percent) =  $100 \frac{\text{true-positive} + \text{true-negative}}{\text{true-positive} + \text{false-positive} + \text{true-negative} + \text{false-negative}}$ ; sensitivity:  $\frac{\text{true-positive}}{\text{true-positive} + \text{false-negative}}$ ; specificity:  $\frac{\text{true-negative}}{\text{false-positive} + \text{true-negative}}$ . The following formulas were used to determine the positive and negative predictive values (PPV and NPV). PPV is for  $\frac{\text{true-positive}}{\text{true-positive} + \text{false-positive}}$ , whereas NPV stands for  $\frac{\text{true-negative}}{\text{true-negative} + \text{false-negative}}$ .

## RESULTS

**Descriptive statistics:** The Radiology and the Chest Departments at Al-Azhar University Hospital were the sites of this research. By using virtual bronchoscopy and fiberoptic endoscopy, fifty patients were qualified for the trial.

Out of the 50 patients included in the research, 14 patients (28%) were males and 36 patients (72%) were females. The research group's average age was 59, with a standard deviation  $\pm 14$ .

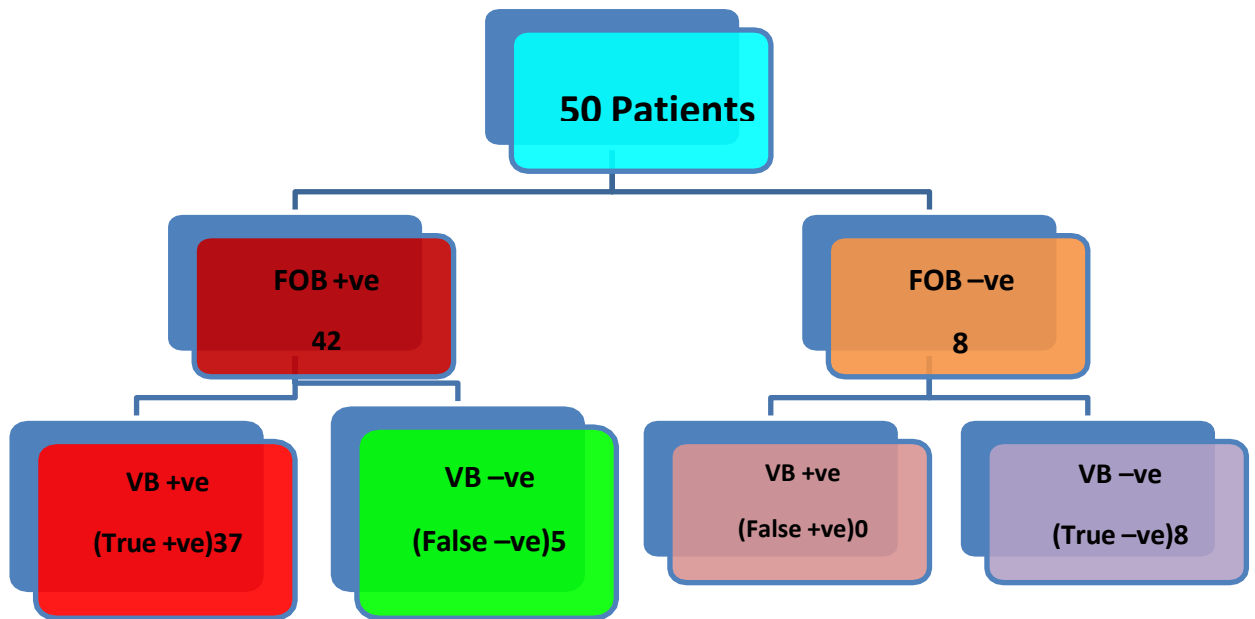
		N	%
Age	Mean ± SD	59 ±14	
Sex	Male	36	72
	Female	14	28
<b>Total</b>		50	

**Table 1:** Distribution of cases according to age

Cause of referral	No	%
clinical	17	34
clinical & radiological	33	66

**Table 2:** Distribution of cases according to the indication for FOB

Majority of patients were referred to the examination because of clinical and radiological causes (66%), (34%) were referred for only clinical indications (Table 1, 2).



**Figure 3:** Flow chart indicating diagnostic indices of VB using FOB as a gold standard

Of the 50 patients who underwent assessment using both diagnostic modalities, 42 patients displayed tracheobronchial abnormalities by fiberoptic endoscopic investigation, 37 (88%) patients had the same abnormalities proven by virtual bronchoscopic examination, and 5 (11.9%) patients had no abnormalities detected. In neither of the two diagnostic modalities, 8 out of the 50 patients lacked tracheobronchial abnormalities. (Figure 3)

	No	%
Rt. upper lobe	15	35.7
Lt. main bronchus	6	14.2
Lt. upper lobe	5	11.9
Rt. lower lobe	4	9.5
Lt. lower lobe	4	9.5
Bronchus intermedius	3	7.1
Trachea	2	4.7
Rt. main bronchus	1	2.3
Rt. middle lobe	1	2.3
Carina	1	2.3

**Table 3:** Sites of detected lesions during examination (Total no: 42) patients

Sites of lesions: Most frequent site was Rt. upper lobe bronchus (35.7% of patients) followed by Lt. main bronchus (14.2%), while the least frequent sites were Rt. Main bronchus, Rt. middle lobe bronchus and carina (2.3% for each) (Table 3)

Airway obstruction: The most of lesions (59.5%) were obstructive; non-obstructive lesions made up 23.8%; and slightly obstructive lesions made up 16.6%.

<b>Types of the lesions</b>	<b>Obstructing</b>	<b>25</b>	<b>59.50%</b>
	Non obstructing	10	23.80%
	Partially obstructing	7	16.60%
<b>Total</b>		<b>42</b>	
<b>Lesion-bypass by FOB</b>			
	<b>Yes</b>	<b>15</b>	<b>35.7 %</b>
	No	27	64.3 %
<b>Total</b>		<b>42</b>	
<b>Lesion-bypass by VB</b>			
	Yes	37	100 %
	No	0	0

**Table 4:** Characteristics of the detected lesions FOB detected 42 positive patients VB detected 37 Positive patients

Regarding the capability of bypassing lesions, only 15 lesions (35.6%) of the 42 patients with positive lesions by FOB were bypassed by it, but all lesions found by VB were completely bypassed by it. (Table 4).

Patient diagnosis: Histopathological analysis revealed that the majority of patients (18 patients) had squamous cell carcinoma (42.8%), followed by adenocarcinoma (23.8% - 10 patients), infection (TB) (9.5% - 4 patients), and carcinoid tumor (7.1 percent - 3 patients). Atypical cells, bronchial adenoma, and inflammatory pseudo-tumor were the least common diagnoses.

<b>Diagnosis</b>	<b>No</b>	<b>%</b>
<b>Squamous cell carcinoma</b>	18	42.8
<b>Adenocarcinoma</b>	10	23.8
<b>Infection (TB)</b>	4	9.5
<b>Carcinoid tumor</b>	3	7.1
<b>Small cell carcinoma</b>	1	2.3
<b>Tracheal adenoma</b>	2	4.7
<b>Atypical cells</b>	2	4.7
<b>Bronchial adenoma</b>	1	2.3
<b>Inflammatory pseudo- tumor</b>	1	2.3

**Table 5:** Pathological diagnosis of studied patients

Diagnostic indices of VB compared to FOB: The sensitivity of the virtual bronchoscopic examination was evaluated to be 88 percent while the specificity was determined to be 100% based on the data gathered and analyzed. The PPV and NPV were determined as 100% and 61.50%, respectively, with an estimated overall accuracy of 90%.

		<b>FOB</b>				
		Positive (n = 42)		Negative (n= 8)		Total
		No.	%	No.	%	
<b>VB</b>	Positive	37	88	0	0	37
	Negative	5	12	8	100	13

**Table 6:** Diagnostic indices of VB using FOB as a gold standard

Sensitivity = 88 % Specificity = 100 % PPV= 100 %

NPV = 61.5 %

## DISCUSSION

Hemoptysis is a worrying clinical sign with a wide range of possible diagnoses. The use of CT has become a crucial noninvasive technique in the assessment of patients with hemoptysis.<sup>7</sup>

The laryngotracheobronchial airway is affected by a wide range of diseases, and imaging is essential for assessing these anomalies. The location, scope, and type of these lesions may be determined with great accuracy using computed tomography with virtual bronchoscopy, which is why it is being used more often on patients who are ineligible for fiberoptic bronchoscopy and laryngoscopy. By utilizing low-dose multidetector computed tomography and hybrid

iterative reconstruction methods, ionizing radiation associated with virtual bronchoscopy may be reduced. Additionally, extra costs and radiation are removed when a virtual bronchoscopy is constructed retroactively from a collection of normally recorded computed tomography data. Future advancements in navigational methods and virtual bronchoscopy will expand the range of diagnostic and treatment options.<sup>1</sup>

A new technological advancement, multidetector computed tomography-generated virtual bronchoscopy (VB), enables the vision of the lumen and wall of the trachea as well as the proximal portion of the bronchial tree. It creates a dynamic view similar to what is observed during fiberoptic bronchoscopy (FOB). The

right diagnosis is crucial for effective therapy of airway illness. Patients with suspected airway illness often go through a diagnostic assessment that includes chest radiographs, CT scans, and fiberoptic bronchoscopy.<sup>8</sup>

A revolutionary computed tomography (CT)-based imaging approach called virtual bronchoscopy (VB) enables noninvasive intraluminal examination of the tracheobronchial tree. According to several studies, VB can properly depict the trachea's width and lumen as well as the left and right main stem bronchi and the bronchial tree down to the fourth order of orifices and branches. Accurate evaluation of the carina's morphology is possible, and the pictures closely resemble those obtained with fiberoptic bronchoscopy (FB).<sup>9</sup>

We discovered that in individuals with hemoptysis, the VB approach can see the central airways and identify the reasons. 95 percent of the central airways could be seen. The VB sensitivity for the detection of the cause of hemoptysis was 80% using consensus values. When compared to the similar traditional bronchoscopic pictures, the VB images' fidelity is startling. Additional advantages of VB over FOB include assessing stenosis length and observing airways beyond constricted stenoses, as well as seeing additional stenosis within a specific bronchus. Based on these results, VB may be used as a prebronchoscopy test to determine if any airways are aberrant, to track changes over time or in response to therapy, or to treat children or adults who are too unwell to endure traditional bronchoscopy.<sup>10</sup>

For tracheobronchial diseases, traditional fiberoptic endoscopy continues to be the gold standard diagnostic technique. It is a rather secure diagnostic and treatment method. The exceptional sensitivity of fiberoptic endoscopy makes it the primary diagnostic method for tracheobronchial endoluminal and mucosal disorders. It also makes it possible to obtain biopsies for histological analysis. In addition to its negative effects, fiberoptic bronchoscopy also carries a small but real risk of morbidity and mortality (about 0.8 percent), particularly in higher risk patients with more severe intrathoracic pathologies. Also, it is a time-consuming procedure and may cause cardiac arrhythmias or arrest.<sup>7</sup>

The tracheobronchial tree may be evaluated non-invasively during virtual bronchoscopy (VB), a computer-guided bronchoscopy simulation that offers the same view, angles, and zoom settings as actual bronchoscopy. The word "virtual" is used since it derives from image sources other than the actual inspection via bronchoscope itself.<sup>4</sup>

Through the use of a computer-generated post-processing technique that produces high resolution images of the airways and provides endotracheal and endobronchial views that simulate the true surfing view offered by conventional fiberoptic bronchoscopy,

virtual bronchoscopy provides a realistic three-dimensional view of the airway's lumen.<sup>6</sup>

This research intends to highlight the potential utility and the diagnostic value of virtual bronchoscopy in tracheobronchial evaluation, by comparing it with the conventional fiberoptic bronchoscopy as a reference, which is the effective diagnostic method for investigating patients with suspected tracheobronchial pathologies.<sup>11</sup>

Histopathologically, squamous cell carcinoma was identified in 18 individuals (42.8%), followed by adenocarcinoma in 10 patients (23.8%), infection (TB) in four patients (9.5%), and carcinoid tumor in three patients (7.1 percent). Inflammatory pseudo-tumor and bronchial adenoma were the least common diagnoses (2.3 percent for each).

The mean age of the patients and their gender may give explanation for that the most detected diagnosis was malignancy, this was also noticed before by Akl YM et al.<sup>12</sup>, who showed in their group study that the sex distribution of bronchogenic carcinoma cases, shows that 82.2% of cases were males and 17.8% of cases were females, and the age distribution shows that, the highest incidence of bronchogenic carcinoma was in the sixth decade of life.

The sensitivity of virtual bronchoscopic examination was evaluated in our research to be 88 percent while the specificity was determined to be 100% based on the data gathered and analyzed. The PPV and NPV were determined as 100% and 61.50%, respectively, with an estimated overall accuracy of 90%. These results were similar to that detected by Tenneti Poornima et al.<sup>3</sup>, who determined PPV and NPV to be 89 and 33 percent, respectively, while sensitivity and specificity were computed as 89 and 33 percent, respectively. The accuracy rate was 81%. based on the ultimate diagnosis determined by histological findings and observations obtained after therapy.

The majority of lesions in our study were obstructing (59.5%- 25 patient), the non obstructing lesions represented 23.8% (10 patients) while partially obstructing lesions represented 16.6% (7 patients). Regarding the capability to bypass lesions, only 15 lesions (35.6%) of the 42 individuals with positive lesions by FOB were able to do so, compared to 100% of lesions discovered by VB. These results are harmonious with Tenneti Poornima et al.<sup>3</sup> who concluded that the benefit of virtual bronchoscopy is that it may access the open airway beyond areas of severe stenoses, according to FOB.

We should not deal with fiberoptic endoscopy and virtual bronchoscopy as two competitive diagnostic modalities, that should be compared regarding diagnostic performance, but they can be complementary ones. Virtual bronchoscopy gives a wider scope on the tracheobronchial tree, and may be even used for all the patients indicated for fiberoptic endoscopy before performing the procedure, as it will allow better and more efficient procedure

performance. Also, it gives the opportunity to examine the tracheobronchial tree in patients who can not undergo examination by the invasive fiberoptic bronchoscopy.<sup>7</sup>

### CONCLUSION

Virtual bronchoscopy is an innovative, non-invasive, accurate and uncomplicated diagnostic modality in the diagnosis of tracheobronchial diseases. In particular situations, VB could be the modality of choice, as in the assessment of the airways distal to strictures or stenosis.

Conflict of interest : none

### REFERENCES

- 1- Daniel J Bell. Hemoptysis Radiopaedia. *Radiopaedia* .2021. <https://doi.org/10.53347/rID-73913>
- 2- Sakina, S., & Syafa'ah, I, The Role of Bronchoscopy in Hemoptysis. *Jurnal Respirasi*. 2020; 6(2), 55-60.
- 3- Poornima, T., Silla, M., & Swaroop, U. S. A, Role of CT scan chest and fiber optic bronchoscopy in evaluating patients with hemoptysis and normal chest radiograph. *Indian Journal of Immunology and Respiratory Medicine*. 2017; 2(3), 82-5.
- 4- Khan, K. A., Nardelli, P., Jaeger, A., O'Shea, C., Cantillon- Murphy, P., & Kennedy, M. P, Navigational bronchoscopy for early lung cancer: a road to therapy. *Advances in therapy*. 2016; 33(4), 580-96.
- 5- Mohamed, S. A., Mousa, E. M., Hamed, A. M., Amin, S. E., & Aziz, N. M. A, Utility of multidetector row computed tomography and virtual bronchoscopy in evaluation of hemoptysis due to lung cancer. *Egyptian Journal of Chest Diseases and Tuberculosis*. 2016; 65(1), 279-87.
- 6- Nabil A. Shallik , Abbas H. Moustafa & Marco A. E. Marcus, Virtual Endoscopy and 3D Reconstruction in the Airways *Springer Nature Switzerland ISBN*. 2019; 978-3-030-23252-8
- 7- Marquis, K. M., Raptis, C. A., Rajput, M. Z., Steinbrecher, K. L., Henry, T. S., Rossi, S. E., & Bhalla, S, CT for Evaluation of Hemoptysis. *Radiographics*. 2021; 41(3), 742-61.
- 8- Marwa Ali, Emam M Abd-Elaziz, & Aliaa A ELNaggar, Role of multislice computed tomography and virtual bronchoscopy in evaluation of pulmonary masses. *Sci J Al-Azhar Med Fac Girls*. 2021; 5:177-81
- 9- Kandathil, A., Kay, F., Batra, K., Saboo, S. S., & Rajiah, P, Advances in Computed Tomography in Thoracic Imaging. *In Seminars in Roentgenology*. 2018; (Vol. 53, No. 2, pp. 157-170).
- 10- Das, K. M., Lababidi, H., Al Dandan, S., Raja, S, Computed tomography virtual bronchoscopy: normal variants, pitfalls, and spectrum of common and rare pathology. *Canadian Association of Radiologists Journal*. 2015; 66(1), 58-70.
- 11- Adachi, T., Machida, H., Nishikawa, M, Improved delineation of CT virtual bronchoscopy by ultrahigh-resolution CT: comparison among different reconstruction parameters. *Jpn J Radiol*. 2020; 38, 884-9
- 12- Akl, Y. M., Emam, R. H., Sabry, I. M., & Ali, A. A, Clinico-pathological profile of bronchogenic carcinoma cases presented to Chest Department, Cairo University in the last 10 years. *Egyptian Journal of Chest Diseases and Tuberculosis*. 2013; 62(4), 705-12.