

Dermoscopic evaluation of the efficacy of combination of topical spironolactone 5% and minoxidil 5% solutions in the treatment of androgenetic alopecia, comparative study

Ahmed Abdelnaby Mohamed,^{1*} M.B.B.Ch, Ahmed Rashad Mohamed Elshahid,¹ MD, Amr Mohammad Ahmed Mahmoud Ammar,¹ MD and , Hamdy Abdou Mansour Abdel-Dayem,² MD.

* Corresponding Author:

Ahmed Abdelnaby Mohamed
ahmed.abdelnaby682021@gmail.com

Received for publication May 08, 2022; Accepted November 22, 2022; Published online November 22, 2022.

doi: 10.21608/aimj.2022.137262.1935

Citation: Ahmed A., Ahmed R. and Amr M. Dermoscopic evaluation of the efficacy of combination of topical spironolactone 5% and minoxidil 5% solutions in the treatment of androgenetic alopecia, comparative study. AIMJ. 2022; Vol.3-Issue11 :174-184.

¹Dermatology, Venereology And Andrology Department, Faculty of Medicine, Al-Azhar University, Cairo, Egypt.

²Pharmacology Department, Faculty of Medicine, Al-Azhar University, Cairo, Egypt.

ABSTRACT

Background: Androgenetic alopecia (AGA) is a common chronic dermatological illness that affects both men and women.

Aim of the study: The objective of the research was to assess and compare dermoscopically the impact of a combination of topical minoxidil solution (5%) and topical spironolactone solution (5%) in treating AGA in both sexes.

Patients and Methods: This was a cross-sectional comparative study. From February 2021 to March 2022, cases have been collected from al-Azhar University Hospital's dermatology outpatient clinic. Patients divided into three groups, each group is composed of 40 patients as: Group A was given a 5% topical Minoxidil solution. Group B was given a 5% topical spironolactone solution. Group C was given a 5% topical spironolactone solution and a 5% topical Minoxidil solution.

Results: There was no statistically significant difference between (yellow dots, peripilar sign, and honeycomb hyperpigmentation) before, during, & after three months of treatment in group C. The difference between (hair shaft diversity, vellus hair, follicular unit with only one emerging hair, and upright re-growing hair) is statistically significant before, during, & after three months of treatment in group C.

Conclusion: Both spironolactone as a 5% topical solution and minoxidil as a 5% topical solution might be used safely in a twice-daily dosage to treat AGA in both genders. Furthermore, combining them in a single topical dose form can boost efficacy and yield greater advantages.

Keywords: Dermoscopic; Efficacy; Topical Spironolactone; Minoxidil; Treatment; Androgenetic Alopecia.

Disclosure: The authors have no financial interest to declare in relation to the content of this article. The Article Processing Charge was paid for by the authors.

Authorship: All authors have a substantial contribution to the article.

Copyright The Authors published by Al-Azhar University, Faculty of Medicine, Cairo, Egypt. Users have the right to read, download, copy, distribute, print, search, or link to the full texts of articles under the following conditions: Creative Commons Attribution-Share Alike 4.0 International Public License (CC BY-SA 4.0).

INTRODUCTION

Androgenetic alopecia (AGA) is a common chronic dermatological illness that affects both men and women.¹ Throughout their lives, it impacts up to 80% of men and 50% of women.²

It is characterized by gradual thinning, miniaturization, and hair loss at the afflicted locations. The extent and intensity of hair loss vary greatly between frontotemporal recession and residual occipital band, and patients may go through several stages in between.³

AGA has a multifactorial and polygenetic etiology. It's apparent that it's an androgen-dependent disorder. There is evidence of a hereditary predisposition.⁴

Topical minoxidil solution or foam in men and minoxidil solution or foam in women is regarded as standard therapy for AGA⁵. By causing telogen hairs

to enter the anagen stage and extending the anagen period, minoxidil increases hair growth.⁶

According to current research, using spironolactone as a topical therapy leads to significant medication penetration to the active site while limiting the undesired side effects of oral spironolactone⁷

Dermoscopy provides for the visualization of morphologic structures that aren't visible with the naked eye, such as perifollicular and interfollicular characteristics, and also alterations in hair shaft thickness and form. The term "trichoscopy" was first introduced in 2006 for the usage of dermoscopy in hair and scalp disorder diagnosis, and it is currently commonly adopted. Trichoscopy is an easy, non-invasive, in-office approach for determining the proper diagnosis in patients suffering from hair loss as well as inflammatory hair problems.⁸

The study's objective was to assess and compare dermoscopically the efficacy of a combination of topical minoxidil solution (5%) and topical spironolactone solution (5%) in treating androgenetic alopecia in both men and women.

PATIENTS AND METHODS

This was a cross-sectional, comparative study. From February 2021 to March 2022, cases have been obtained from al-Azhar University Hospital's dermatology outpatient clinic. Patients are divided into three groups; each group is composed of 40 patients, as: **Group A** was given a 5% topical Minoxidil solution. **Group B** was given a 5% topical spironolactone solution. **Group C** received a 5% topical spironolactone solution mixed with a 5% topical Minoxidil solution.

Inclusion criteria: Age: 20–50 years old. Patients have had no treatment in the last 3 months for AGA, and all patients are given a diagnosis of AGA based on their history and clinical examination, with varying levels of hair loss according to the Norwood-Hamilton scale for men's pattern baldness and the Ludwig scale for women's pattern loss of hair.

Exclusion criteria: Patients with alopecia other than AGA, autoimmune diseases causing hair loss, male patients with a history of sexual dysfunction and infertility, pregnant and lactating women, patients with anuria, acute renal insufficiency, acute renal failure, Addison's disease and hypersensitivity to spironolactone and patients with cardiovascular disorders.

All patients will be subjected to the following: Thorough history taking with emphasis on sexual and CVS history. General examination, blood pressure, pulse, and heart rate monitoring, and full scalp examination.

The patients have been asked to apply the solution twice a day in a dose of 1 ml, gently massaging their scalps.

Dermoscopic evaluation (DermLite DL4) and imaging every two weeks for three months for the detection of signs of hair regrowth and a decrease in AGA activity.

Method of preparation of solutions:

Preparation of spironolactone 5% solution: One gram of active ingredient spironolactone is dissolved in 20 ml of isopropylalcohol to get 5% solution. Clear solution occurred after shaking; gentle heating over waterbath 45-50 c, closure and labeling then solution is kept in room temperature for further use.

Preparation of mixture of minoxidil 5% solution and spironolactone 5% solution: 5ml of minoxidil (5%) is mixed with 5ml of spironolactone (5%). The solution is shaken for 10 minutes and put in a waterbath for 20 minutes until a clear solution is obtained, then closed, labeled and kept at room temperature for further use.

Data collection: All participants in this study were recruited from the Al Hussein and Sayed Galal University Hospitals' dermatology and venereology outpatient clinics at Al-Azhar University in Cairo.

Ethical Approval: Before beginning this research, approval from Al-Azhar University's medical ethics committee will be obtained.

The study procedures will be explained to all patients, and their written consent will be obtained.

Evaluation:

Quartile grading scale for improvement: Two independent blinded dermatologists were asked to compare digital images taken three months after therapy with baseline photos of hair condition using a quartile grading scale as follows: poor improvements (0–24%), mild improvements (25–50%), moderate improvements (51–75%), and great improvements (76–100%).

Patient satisfaction: The patients were requested to evaluate their own level of satisfaction by giving themselves a score of 0–3 points as follows: poor satisfaction equals 0, mild satisfaction equals 1, moderate satisfaction equals 2, and high satisfaction equals 3.

Statistical analysis: The Statistical Program for Social Science (SPSS) version 26 has been employed to analyze the data.

RESULTS

		Group A (N = 40)	Group B (N = 40)	Group C (N = 40)	F	P-value
Age (years)	Mean ±SD	30.45 ± 9.20	33.45 ± 8.22	30.8 ± 7.16	1.586	0.209
	Median	27.50	32.00	30.50		
Duration (years)	Mean ±SD	2.88 ± 1.11	3.00 ± 1.11	2.88 ± 0.97	0.184	0.832
	Median	3.00	3.00	3.00		

F: One way Anva Test.

NS: p-value > 0.05 is regarded as non-significant.

Table 1: Comparison of the studied groups in terms of age & duration

There have been no statistically significant differences (p-value > 0.05) between the examined groups in terms of age and duration of disease. Table (1)

		Group A (N = 40)		Group B (N = 40)		Group C (N = 40)		X ²	P-value
Sex	Female	30	75.0%	30	75.0%	34	85.0%	1.57	0.456
	Male	10	25.0%	10	25.0%	6	15.0%		
Onset	Acute	0	0%	0	0%	0	0%	----	----
	Gradual	40	100%	40	100%	40	76.7%		
Course	Regressive	0	0%	0	0%	0	0%	----	----
	Progressive	40	100%	40	100%	40	100%		

X2: Chi square Test.

NS: p-value > 0.05 is regarded as non-significant.

Table 2: Comparison of the studied groups in terms of sex, onset & course

There have been no statistically significant differences (p-value > 0.05) between the examined groups in terms of sex, onset, & course. Table (2)

Dermoscopy After one month and half		Group A (N = 40)	Group B (N = 40)	Group C (N = 40)	F	P-value
Hair shaft diversity	Mean ±SD	30.80 ± 4.63	30.30 ± 4.32	30.00 ± 4.43	0.329	0.721
	Median	31	30	28		
Yellow dots	Mean ±SD	1.05 ± 2.21	1.00 ± 1.82	1.20 ± 1.96	0.108	0.897
	Median	0.0	0.0	0.0		
Peripilar sign	Mean ±SD	29.75 ± 14.89	31.5 ± 22.70	30.50 ± 21.48	0.077	0.926
	Median	30	30	30		
Vellus hair	Mean ±SD	23.20 ± 6.76	21.75 ± 4.14	20.25 ± 3.43	3.500	0.033
	Median	24.00	22.00	18.00		
Honeycomb hyperpigmentation	Mean ±SD	1.15 ± 0.36	1.15 ± 0.36	1.20 ± 0.41	0.00	1.00
	Median	1.00	1.00	1.00		
Follicular unit with only one emerging hair	Mean ±SD	37.45 ± 6.16	38.70 ± 3.48	36.70 ± 7.43	1.177	0.312
	Median	36.50	37.50	34.00		
Upright regrowing hair	Mean ±SD	1.05 ± 0.99	1.25 ± 0.89	0.80 ± 0.82	2.483	1.088
	Median	1.00	1.00	1.0		

F: One way Anva Test.

NS: p-value > 0.05 is regarded as non-significant.

HS: p-value < 0.05 is regarded as highly significant.

Table 3: Comparison of the studied groups in terms of dermoscopic features (After one month and half)

There have been no statistically significant differences (p-value > 0.05) between the examined groups in terms of dermoscopic features after one month and half treatment (hair shaft diversity, yellow dots , peripilar sign, honeycomb hyperpigmentation, follicular unit with only one emerging hair & upright regrowing hair). There have been statistically significant differences (p-value < 0.05) between the examined groups in terms of dermoscopic features after one month and half treatment (vellus hair). Table (3)

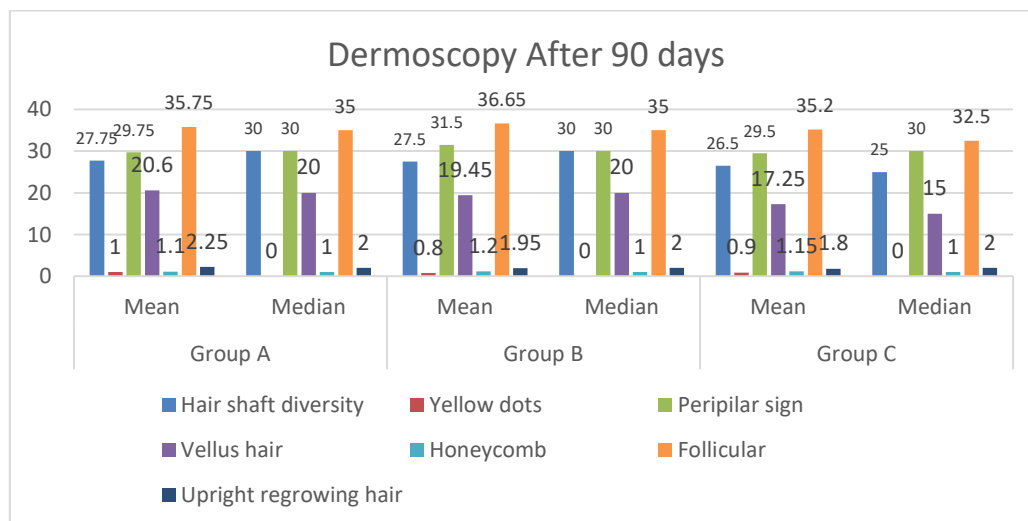


Fig. 1: Comparison of examined groups in terms of diversity of hair shaft, yellow dots, peripilar sign, Vellus hair, honeycomb hyperpigmentation, follicular unit with only one emerging hair and upright regrowing hair (After three months)

There have been statistically significant differences (p -value < 0.05) between the examined groups in terms of dermoscopic features after three months of treatment (vellus hair). There have been no statistically significant differences (p -value > 0.05) between the examined groups in terms of dermoscopic features after three months of treatment (hair shaft diversity, yellow dots, peripilar sign, honeycomb hyperpigmentation, follicular unit with only one emerging hair & upright regrowing hair). Figure (1)

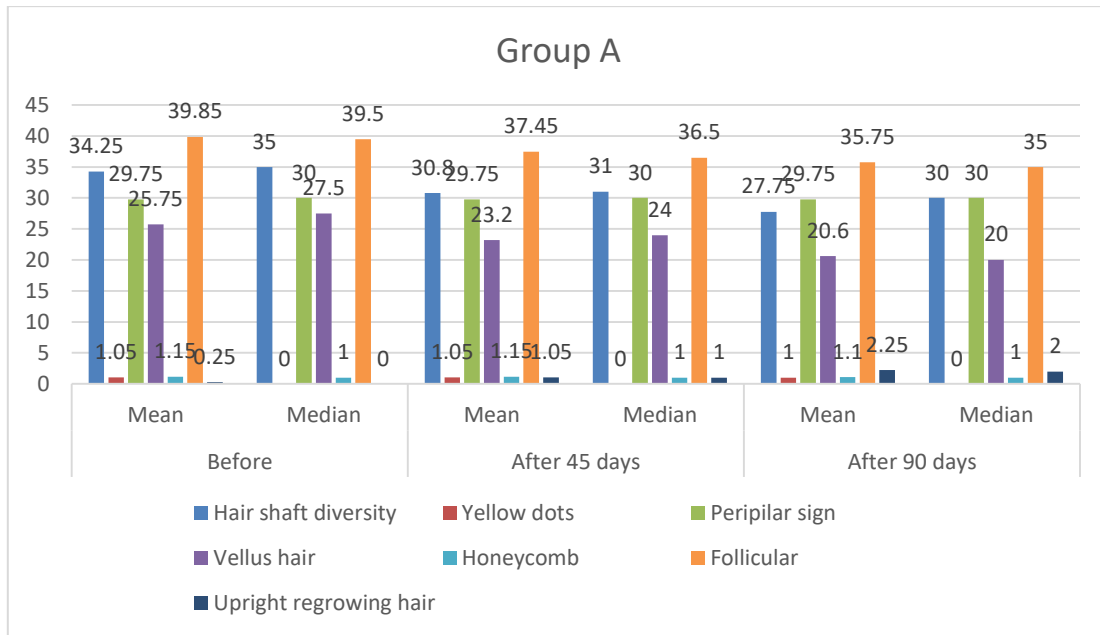


Fig. 2: Comparison between the diversity of hair shafts, yellow dots, peripilar sign, Vellus hair, honeycomb hyperpigmentation, follicular unit with only one emerging hair and upright regrowing hair (before, after one month, and half & after three months) in group A

There have been no statistically significant differences (p -value > 0.05) among (yellow dots, peripilar sign, and honeycomb hyperpigmentation) before, after one month, and half & after three months of treatment in group A. There have been statistically significant differences (p -value < 0.001) among (hair shaft diversity, vellus hair, follicular unit with only one emerging hair & upright regrowing hair) before, after one month, and half & after three months of treatment in group A. Figure (2)

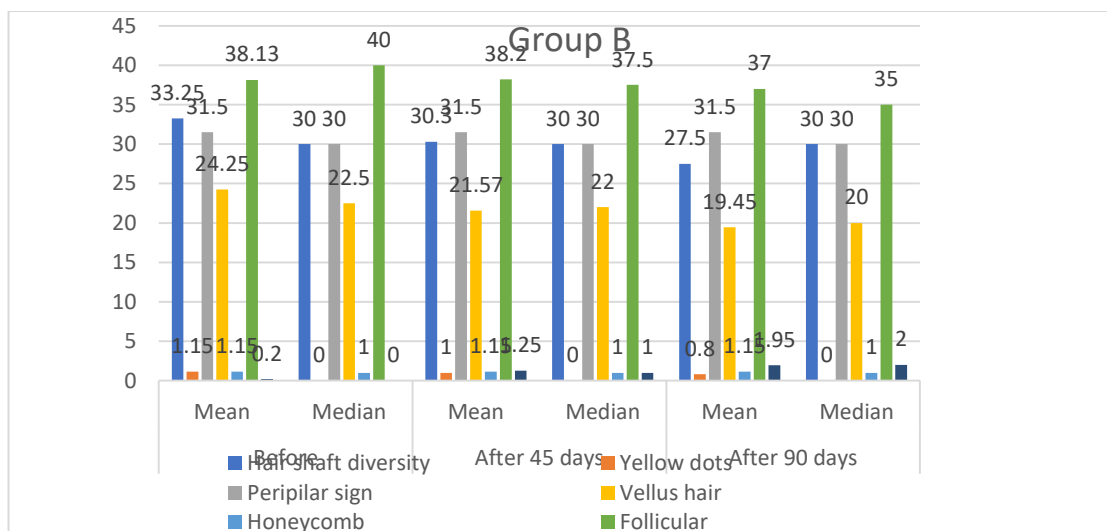


Fig. 3: Comparison between diversity of hair shaft, yellow dots, Peripilar sign, Vellus hair, honeycomb hyperpigmentation, follicular unit with only one emerging hair and upright regrowing hair (before, after one month, and half & after three months) in group B.

There have been no statistically significant differences (p -value > 0.05) among (yellow dots, peripilar sign, honeycomb hyperpigmentation, and follicular unit with only one emerging hair) before, after one month, and half & after three months of treatment in group B. There have been statistically significant differences (p -value < 0.001) among (diversity of hair shaft, vellus hair, and upright regrowing hair) before, after one month, and a half, & after three months of treatment in group B. Figure (3)

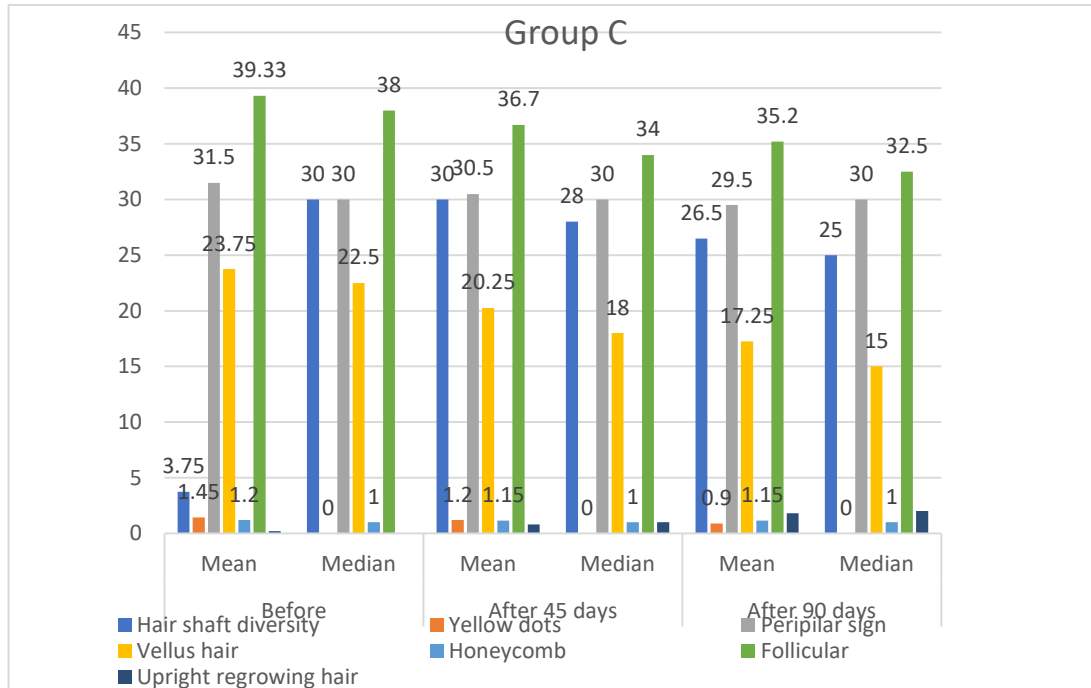


Fig. 4: comparison between the diversity of hair shaft, yellow dots, peripilar sign, Vellus hair, honeycomb hyperpigmentation, follicular unit with only one emerging hair and upright regrowing hair (before, after one month, and half & after three months) in group C.

There have been no statistically significant differences (p-value > 0.05) among (yellow dots, peripilar sign, and honeycomb hyperpigmentation) before, after one month, and half & after three months of treatment in group C. There have been statistically significant differences (p-value < 0.001) among (hair shaft diversity, vellus hair, follicular unit with only one emerging hair & upright regrowing hair), before, after one month and a half, & after three months of treatment in group C. Figure (4)

		Group A (N = 40)	Group B (N = 40)	Group C (N = 40)	X ²	P-value
Improvement	Poor	14	18	0	26.17	0.001 H S
	Mild	6	4	4		
	Moderate	12	8	21		
	high	8	10	15		
Total		40	40	40		

X2: Chi square Test. HS: p-value > 0.001 is regarded as non-significant.

Table 4: Comparison of the studied groups in terms of the Quartile grading scale for improvement:

There have been statistically significant differences between the examined groups in terms of the degree of Quartile grading scale for improvement. Table (4)

		Group A (N = 40)	Group B (N = 40)	Group C (N = 40)	X ²	P-value
patient satisfaction	poor	11	16	0	24.19	0.001 H S
	mild	8	6	6		
	moderate	14	10	15		
	high	7	8	19		
Total		40	40	40		

X2: Chi square Test. HS: p-value > 0.001 is regarded as non-significant.

Table 5: comparison between studied groups as to patient's satisfaction

There have been statistically significant differences between the examined groups in terms of patient satisfaction. Table (5)

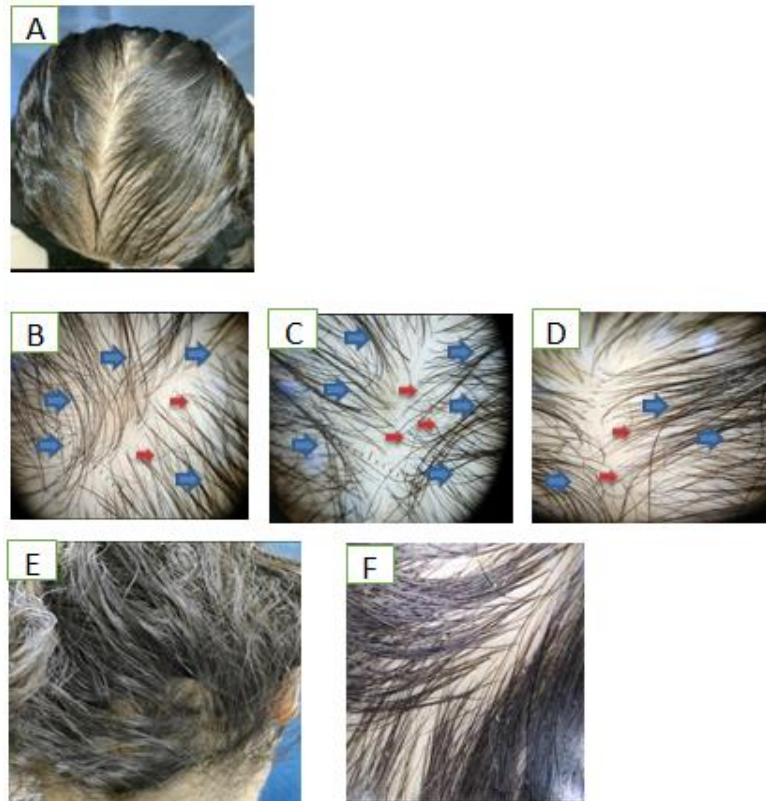

Fig. 5: A female patient, 39 years old, complained of 3 years of diffuse loss of hair. The clinical image (A) indicates diffuse hair thinning in the frontal, middle, and temporoparietal areas of the scalp, but the frontal hair line is retained (as per Ludwig's FPHL classification, grade II). The first visit's dermoscopy (B, C, D) reveals the diversity of hair shafts (blue arrows) and vellus hairs (red arrows), which is suggestive of androgenic alopecia. In comparison to the occipital area, which is seen in E (clinical photo), F (dermoscopic photo)

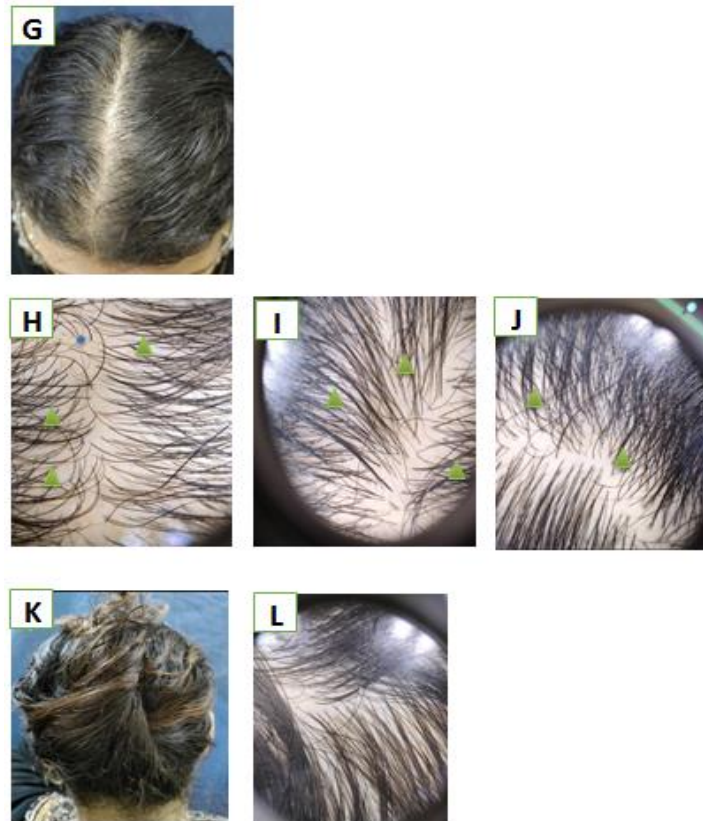

Fig. 6: represents group (B) after treatment and follow-up for three months. Clinical photos (G) showed moderate improvement. Dermoscopy (H, I, J) showed an increase in hair shaft diameter and a reduction in hair shaft

diversity (green triangle), decreased vellus hairs, and the appearance of upright regrowing hair (blue dot). In comparison to the occipital area, which is seen in K (clinical photo), and L (dermoscopic photo).

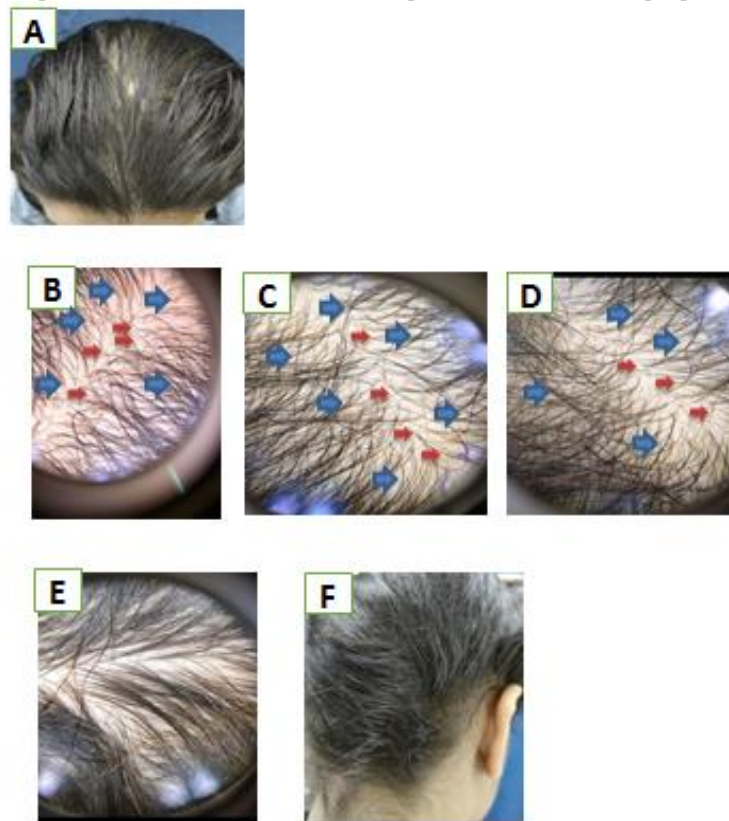


Fig. 7: A female patient, 24 years old, with a year's worth of diffuse hair loss. The clinical image (A) indicates diffuse hair thinning in the frontal and middle areas of the scalp, but the frontal hair line is retained (as per Ludwig's FPHL classification, grade II). First visit dermoscopy (B, C, D) reveals hair shaft diversity (blue arrows) and vellus hairs (red arrows), which is suggestive of androgenic alopecia. In comparison to the occipital area, which is seen in E (clinical photo), F (dermoscopic photo).

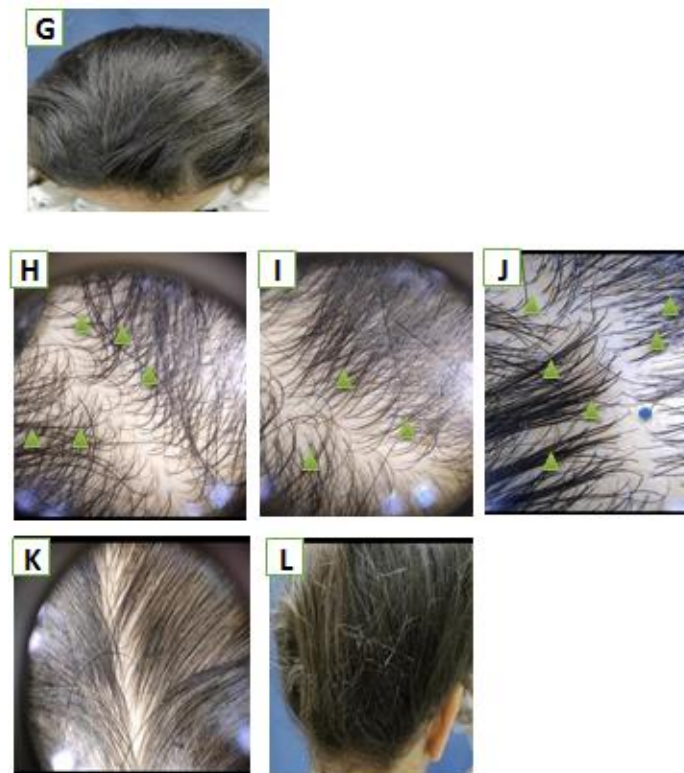


Fig. 8: represents group (A) after treatment and follow-up for three months.

Clinical photos (G) showed moderate improvement. Dermoscopy (H, I, J) showed an increased hair shaft diameter, a reduction in hair shaft diversity (green triangle), decreased vellus hairs, and the appearance of upright regrowing hair (blue dot). In comparison to the occipital area, which is seen in K (clinical photo), L (dermoscopic photo).

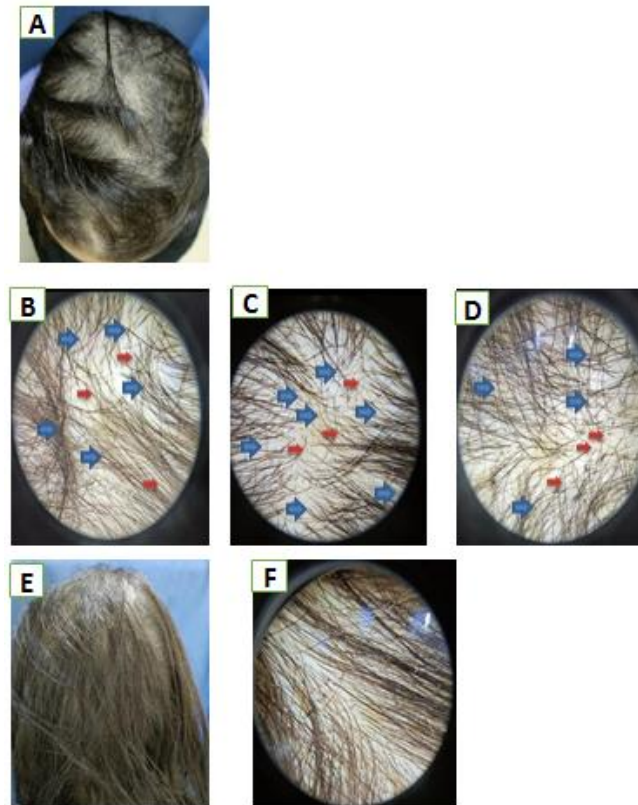


Fig. 9: A female patient, 37 years old, complained of 3 years of diffuse loss of hair. The clinical image (A) indicates diffuse hair thinning in the frontal, middle, and temporoparietal areas of the scalp, but the frontal hair line is retained (as per Ludwig's FPHL classification, grade II). The first visit's dermoscopy (B, C, D) reveals the diversity of hair shafts (blue arrows), vellus hairs (red arrows), which is suggestive of androgenic alopecia. In comparison to the occipital area, which is seen in E (clinical photo), F (dermoscopic photo).

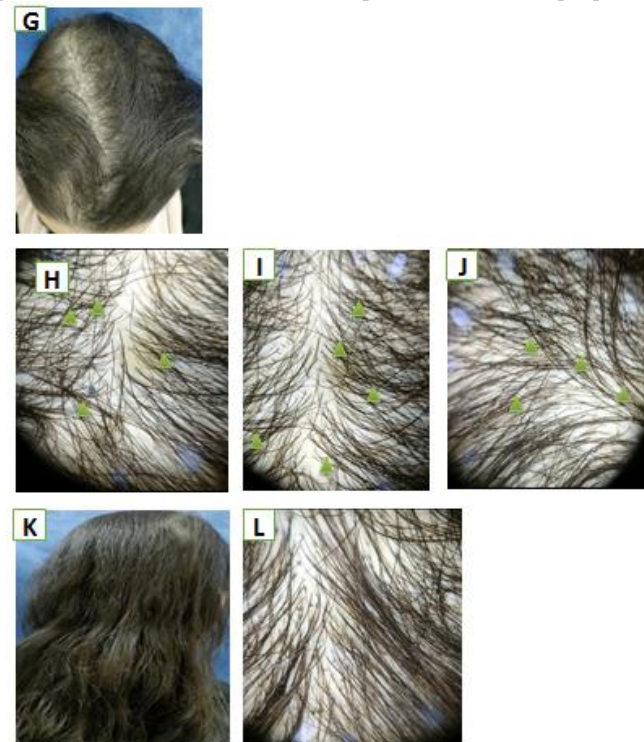


Fig. 10: represents group (C) after treatment and follow-up for three months. Clinical photos (G) showed high improvement. Dermoscopy (H, I, J) showed an increased hair shaft diameter, a reduction in hair shaft diversity

(green triangle), a decrease in vellus hairs, and the appearance of upright regrowing hair (blue dot). In comparison to the occipital area, which is seen in K (clinical photo), L (dermoscopic photo).

DISCUSSION

Androgenetic alopecia (AGA) is a common chronic dermatological illness that affects both men and women. Males and females are visibly burdened by it, but females are more distressed. Throughout their lives, it impacts up to 80% of men and 50% of women. It is characterized by gradual hair thinning, miniaturization, and loss at the afflicted locations. The severity and extent of hair loss vary greatly between frontotemporal recession and residual occipital band, and patients can go through several phases in between⁹

In this research, we discovered no statistically significant differences (p -value > 0.05) between the studied groups as regards age and duration of disease.

Abdel Raouf et al.¹⁰ found that demographic characteristics of the 3 groups at baseline in respect to age, period, and extent had been nonsignificant ($P = .973, .907, \text{ and } .242$, respectively) in a study that included 60 patients given a diagnosis with AGA; (Group I): managed with topical minoxidil gel 5%; (Group II): managed with topical spironolactone gel 1%; and (Group III) managed with a combination minoxidil 5% and spironolactone 1% gel.

Shin et al.,¹¹ found that there were no significant differences in the patients' age in the two groups (39.3 ± 4.2 years for the test group versus 40.2 ± 4.8 years for the control group) in their study to assess the effectiveness of 5% Minoxidil vs. Combined 5% Minoxidil and 0.01% Tretinoin for Male Pattern Hair Loss.

Ghonemy et al.¹² found that patient demographic characteristics were nearly the same between the groups to be comparable in a study to evaluate the effectiveness and safety of a novel 10% topical minoxidil vs 5% topical minoxidil and placebo in the therapy of androgenetic alopecia for men.

In this research, we discovered that male patients in groups A and B have a statistically significant (p -value < 0.001) higher age than female patients.

Salman et al.,¹³ found that both sexes' AGA incidence and intensity were strongly connected with age ($p = 0, 0001$). AGA was found in 94% of males over the age of 70, while it was found in only 43.2% of men aged 17 to 29, 71.1% of males aged 30 to 39, 77.2% of males aged 40 to 49, 83.3% of males aged 50 to 59, and 92.9% of males aged 60 to 69. AGA was found in 50% of women over the age of 70, 8.7% of women aged 17 to 29, 20.3% of women aged 30 to 39, 29.2% of women aged 40 to 49, 43.3% of women aged 50 to 59, and 68.3% of women aged 60 to 69.

Alomaish et al.,¹⁴ found that there were significant differences in gender and age among patients who reported hair loss as well as those who did not report the disease ($P < 0.05$). Males (74.5%) were more likely to report hair loss than females (41.9%) over the age of 30.

In the study in our hands, in regards to grades, we found no statistically significant differences ($p >$

0.05) among the groups examined (for male pattern baldness, the Norwood-Hamilton scale, and for female pattern hair loss, the Ludwig scale).

Abdel-Raouf et al.,¹⁰ found that there was an insignificant difference between the Minoxidil group, Spironolactone group, and Spironolactone plus Minoxidil group as regards the grading of the disease ($p = 0.242$).

In regards to hair loss pattern (Hamilton-Norwood scale), Ghonemy et al.¹² found insignificant differences among the three groups tested.

In regards to hair loss pattern (Hamilton-Norwood scale), Olsen et al.¹⁵ found insignificant differences among the three groups tested ($p = 0.58$).

We demonstrated in this research that there had been no statistically significant differences ($p > 0.05$) in dermoscopic features before therapy between the tested groups.

Abdel-Raouf et al.,¹⁰ found that there was insignificant difference between Minoxidil group, Spironolactone group and Spironolactone + minoxidil group as regards clinical assessment at baseline ($p = 0.45$).

Ahmed et al.,¹⁶ showed that there had been no statistically significant differences in trichoscopy data baseline among males using Finasteride and Spironolactone groups.

Olsen et al.¹⁵ found that there had been insignificant differences among the three tested groups as regards baseline dermoscopic features.

Shin et al.,¹¹ found that there was no significant difference between the two groups in overall hair number, non-vellus hair number, anagen hair ratio, linear hair rate of growth, and mean hair diameter prior to therapy.

In this research, we illustrated that there were statistically significant differences ($p < 0.05$) among the studied groups as regards dermoscopic features after one month and half treatment (vellus hair).

Gajjar et al.,¹⁷ found that at the conclusion of one month, the difference in hair shaft diameter variation among the two groups was significant ($P = 0.04$)

Azam et al.,¹⁸ found that prior to therapy, the mean vellus hair percentage in both groups was significantly greater than the control ($P < 0.01$). The average values of vellus hair percentages following therapy in both groups are significantly lower than the values prior to therapy ($P < 0.01$). However, the mean value following therapy in the minoxidil 2% administered via point-to-point technique group is significantly lower than that of the local applications of the topical minoxidil 2% group (P value < 0.01).

All dermoscopic parameters like hair shaft diameter variation, follicular units containing single and multiple hairs, yellow spots, and perifollicular halo did not indicate any significant differences among the groups at all points of time, according to Gajjar et al.,¹⁷ with the exception of the first month, when the differences in hair shaft diameter variation across the two groups became 0.04.

In this study, we discovered a statistically significant difference ($p < 0.001$) between (hair shaft diversity, vellus hair, and follicular unit with only one emerging hair & upright regrowing hair) before, after one month, and half & after three months of treatment in group A.

Abdel-Raouf et al.,¹⁰ discovered that anagen hair increased significantly after 12 months of therapy, from 9.10 ± 2.132 to 12.10 ± 4.332 ($P = .000$). Both telogen and vellus hairs, on the other hand, were significantly reduced ($P = .000$), whereas the T/V ratios were significantly raised ($P = .000$).

Ghonemy et al.,¹² found a highly statistically significant difference in total hair number across the 3 groups, with the difference being highly significant among the minoxidil 5% group and the other groups, while statistically non-significant among the minoxidil 5% and 10% groups.

Badran et al.,¹⁹ found that the minoxidil group had a percent increase in terminal hair count as well as diameter. However, when both groups were compared together, significant difference was noted in favor of minoxidil group in terms of percent increase in hair diameter.

We illustrated in this research that there had been a statistically significant difference (p-value 0.001) between (variety of hair shafts, vellus hair, and upright hair regrowth) before, after one month, and half & after three months of treatment in group B.

In a case report by Hoedemaker et al.,²⁰ found that there was an enhancement in hair regrowth following 12 months of spironolactone 200 mg therapy.

Ahmed et al.,¹⁶ found that there had been statistically significant differences ($p < 0.001$) among dermoscopic features after three months of Spironolactone treatment. In which spironolactone slows the progression of hair loss while maintaining a favourable long-term safety profile.

Abdel-Raouf et al.,¹⁰ discovered that after 12 months of therapy, anagen hair increased significantly in group II, from 7.80 ± 2.898 to 10.10 ± 3.604 ($P = .003$). Both telogen and vellus hairs, on the other hand, were significantly reduced ($P = .002$, $.005$, respectively), whereas the T/V ratios were significantly raised ($P = .025$).

In this research, we discovered a statistically significant difference ($p < 0.001$) between (hair shaft diversity, vellus hair, and follicular unit with only one emerging hair & upright regrowing hair) before, after one month, and half & after three months of treatment in group C.

The findings are consistent with those of Hoedemaker et al.,²⁰ who utilized systemic spironolactone and topical minoxidil 5% to treat AGA. This finding supports the theory that combination therapy has an additive impact. This was the first time this combination has been explored in AGA treatment.

Abdel-Raouf et al.,¹⁰ discovered that after 12 months of therapy, there had been a significant rise in anagen hair from 4.70 ± 0.675 to 9.70 ± 3.713 ($P = .000$) in group III. Both telogen and vellus hairs, on the other hand, were significantly reduced ($P = .000$), whereas the T/V ratios were significantly raised ($P = .000$).

This study had some limitations, including a small sample size, which may have affected our results, so more research with a bigger sample size and a lengthier follow-up time is indicated to confirm our results. Despite the fact that effective therapy choices are limited, AGA continues to be a field where ongoing research is providing more data about pathogenesis and newer treatment options are being developed in response.

CONCLUSION

Finally, spironolactone as a 5% topical solution and minoxidil as a 5% topical solution may be administered safely twice daily and be effective in the therapy of AGA in both genders. Furthermore, combining them in a single topical dose form can improve efficacy and yield greater advantages. Long-term investigations with a greater number of individuals are needed to confirm these findings and thoroughly assess their safety and efficacy.

Conflict of interest : none

REFERENCES

- Blume-Peytavi U, Blumeyer A, Tosti A, Finner A, Marmol V, Trakatelli M, et al. S1 guideline for diagnostic evaluation in androgenetic alopecia in men, women and adolescents. *Br J Dermatol*. 2011; 164(1): 5–15.
- Piraccini BM, Alessandrini A. Androgenetic alopecia. *G ItalDermatolVenereol* 2014; 149:15–24.
- Gupta M, Mysore V. Classifications of patterned hair loss: a review. *J CutanAesthetSurg*. 2016; 9:3-12.
- Yip L, Rufaut N, Sinclair RD. Role of genetics and sex steroid hormones in male androgenetic alopecia and female pattern hair loss: an update of what we now know. *Australas J Dermatol*. 2011; 52:81–8.
- Adil A and Godwin M. The effectiveness of treatments for androgenetic alopecia: a systematic review and meta-analysis. *J Am AcadDermatol*. 2017; 77:136-41.
- Anja B, Antonella T, Andrew M, Pascal R, Veronique D, Phyllis S, et al. Evidence-based (S3) guideline for the treatment of androgenetic alopecia in women and in men. *J DtschDermatolGes*. 2011; 6:S1–57.
- Kelidari H, Saeedi M, Hajheydari Z, Akbari J, Morteza-Semnani K, Akhtari J. Spironolactone loaded nanostructured lipid carrier gel for effective treatment of mild and moderate acne vulgaris: a randomized, double-blind, prospective trial. *Colloids Surf B Biointerfaces*. 2016; 146:47–535.
- Lacarrubba F, Micali G, Tosti A. Scalp dermoscopy or trichoscopy. *CurrProblDermatol*. 2015; 47:21–32.
- Gupta, S, Goyal, I, & Mahendra, A. Quality of life assessment in patients with androgenetic alopecia. *International journal of trichology*. 2019; 11(4), 147.
- Abdel-Raouf H, Aly UF, Medhat W, Ahmed SS, Abdel-Aziz RT. A novel topical combination of minoxidil and spironolactone for androgenetic alopecia: Clinical, histopathological, and physicochemical study. *Dermatologic Therapy*. 2021; 34(1), e14678.

11. Shin HS, Won CH, Lee SH, Kwon OS, Kim KH, Eun HC. Efficacy of 5% minoxidil versus combined 5% minoxidil and 0.01% tretinoin for male pattern hair loss. *American journal of clinical dermatology*. 2007; 8(5), 285-90.
12. Ghonemy, S, Alarawi, A, & Bessar, H. Efficacy and safety of a new 10% topical minoxidil versus 5% topical minoxidil and placebo in the treatment of male androgenetic alopecia: a trichoscopic evaluation. *Journal of Dermatological Treatment*. 2021; 32(2), 236-41.
13. Salman KE, Altunay IK, Kucukunal NA, Cerman AA. Frequency, severity and related factors of androgenetic alopecia in dermatology outpatient clinic: hospital-based cross-sectional study in Turkey. *Anais brasileiros de dermatologia*. 2017; 92, 35-40.
14. Alomaish AR, Gosadi IM, Dallak FH, Durayb AA, Dallak AH, Hakami JA, et al. Prevalence of alopecia and its contributing factors among primary healthcare attendees in the Jazan region, Saudi Arabia. *Journal of Family Medicine and Primary Care*. 2021; 10(10), 3851.
15. Olsen EA, Dunlap FE, Funicella T, Koperski JA, Swinehart J. M, Tschen EH, et al. A randomized clinical trial of 5% topical minoxidil versus 2% topical minoxidil and placebo in the treatment of androgenetic alopecia in men. *Journal of the American Academy of Dermatology*. 2002; 47(3), 377-85.
16. AHMED, S. A, AYMAN, E. Y, & Mousa, A. S. Topical Finasteride versus Topical Spironolactone in the Treatment of Androgenetic Alopecia. *The Medical Journal of Cairo University*. 2020; 88(June), 1017-22.
17. Gajjar, P. C, Mehta, H. H, Barvaliya, M, & Sonagra, B. Comparative study between mesotherapy and topical 5% minoxidil by dermoscopic evaluation for androgenic alopecia in male: A randomized controlled trial. *International journal of trichology*. 2019; 11(2), 58.
18. Azam, M. H, & Morsi, H. M. Comparative study between 2% minoxidil topical spray vs. intradermal injection (Mesotherapy) for treatment of androgenetic alopecia in female patients: A controlled, 4-month randomized trial. *Egypt Dermatol Online J*. 2010; 6(2), 5.
19. Badran FK, Abd El Maksoud RE, Moawad MI. The efficacy of topical minoxidil 2% versus topical botanically derived inhibitors of 5 alpha reductase in treatment of female pattern hair loss by trichoscopy. *Journal of the Egyptian Women's Dermatologic Society*. 2019; 16(3), 184.
20. Hoedemaker C, Van Egmond S, Sinclair R. Treatment of female pattern hair loss with a combination of spironolactone and minoxidil. *Australasian journal of dermatology*. 2007; 48(1), 43-5.