

Outcome of Posterior Fossa Decompression with Duraplasty by Different Types of Graft in Patients with Chiari Malformation Type I

Mostafa M. Aboelkhir ¹MD ; Mostafa S. Elmaghraby ¹MD ; Ahmed I. Rewehy ¹MD .

*Corresponding Author:

Mostafa M. Aboelkhir

mostafaaboeelkhir_81@gmail.com

Received for publication October 01, 2022; Accepted November 22, 2022; Published online November 22, 2022.

doi: 10.21608/aimj.2022.166219.2218

Citation: Mostafa M. Mostafa S. and Ahmed I. . Outcome of Posterior Fossa Decompression with Duraplasty by Different Types of Graft in Patients with Chiari Malformation Type I. AIMJ. 2022; Vol.3-Issue11 : 185-190.

¹Neurosurgery Department, Faculty of Medicine, Al-Azhar University, Cairo , Egypt.

ABSTRACT

Background: Chiari malformation type I (CM-I) is treated surgically by suboccipital craniectomy with or without duraplasty. Duraplasty may be performed using a variety of dural grafts, including autologous pericranium, allografts, xenografts, and synthetic substitutes.

Aim of the work: To assess outcome and CSF leakage incidence according to type of dural graft in CM-I patients.

Patients and methods: This study included twenty-eight patients with Chiari malformation type I who underwent posterior fossa decompression with duroplasty were randomly assigned into two equal groups: Group A (N=14): patients were treated with a dural substitute Engineered collagen matrix grafts (DuraGen). Group-B (N=14): patients were treated with free tissue fascia lata graft. All patients had neurological assessment and basal laboratory investigations. Magnetic resonance imaging (MRI) of the brain and craniocervical junction as well as computed tomography (CT) of the brain were done preoperatively..

Results: Regarding clinical outcome, fascia lata group showed higher significant excellent rate (92.9%) than DuraGen group (57.1%) (p=0.032). Also, one patient showed good outcome and none showed poor outcome in patients with fascia lata graft while there were four patients with good outcome, two with poor outcome in DuraGen graft patients without significance. Considering postoperative complications, only one patient (7.1%) in fascia lata group showed tight bandage while DuraGen group showed eight patients (57.1%) with CSF leakage (p=0.001), four patients (28.6%) needed reoperations (p=0.033), two cases (14.3%) with Aseptic meningitis and ten cases (71.4%) with tight bandage (p < 0.001).

Conclusion: CM-I decompression surgery with duraplasty by fascia lata graft has a better outcome and lower significant rate of CSF leakage and other postoperative complications than engineered collagen graft (DuraGen).

Keywords: Chiari Malformation Type I; Posterior Fossa Decompression; Duraplasty.

Disclosure: The author has no financial interest to declare in relation to the content of this article. The Article Processing Charge was paid for by the author.

Authorship: The author has a substantial contribution to the article.

Copyright: The Author published by Al-Azhar University, Faculty of Medicine, Cairo, Egypt. Users have the right to read, download, copy, distribute, print, search, or link to the full texts of articles under the following conditions: Creative Commons Attribution-Share Alike 4.0 International Public License (CC BY-SA 4.0).

INTRODUCTION

Chiari malformation type I (CM-I) defined by descend of caudal end of the cerebellar tonsil and crowding of craniocervical junction ¹. About half to seventy percent of CM-I cases are accompanied by syringomyelia (SM), which may progressively develop to chronic and often irreversible myelopathy ^{2,3}. Although many people with CM-I are asymptomatic, some symptoms may be present as headache, cerebellar ataxia, ocular abnormalities, spasticity or lower cranial nerve involvement ⁴.

Suboccipital craniectomy with or without expansile duraplasty, arachnoid dissection, and tonsillar reduction are among the surgical options. Leakage of cerebrospinal fluid (CSF) is a frequent side effect of duraplasty. Incidence of CSF leak following duraplasty varies between 2% and 11.7% ⁵.

Duraplasty may be performed using a variety of dural grafts, including autologous pericranium, allografts, xenografts, and synthetic substitutes. It is yet unknown if any of these materials are related with

greater rates of CSF leakage or other adverse effects ⁶. Our rational was assess outcome and CSF leakage incidence according to type of dural graft in CM-I patients who managed by posterior fossa decompression and duraplasty.

PATIENTS AND METHODS

An interventional randomized study conducted at Department of Neurosurgery Surgery, Faculty of Medicine, Al-Azhar University during the period from 1 January 2020 to 1 December 2021. The study was accepted by Al-Azhar University's Ethics Board, and each subject signed an informed written permission form.

This study included twenty-eight patients with CM-I who underwent posterior fossa decompression with duroplasty were allocated in a simple randomised method without stratification in a 1:1 ratio to two equal groups: Group A "collagen matrix graft group": (N=14): patients were treated with a dural substitute Engineered collagen matrix grafts (DuraGen; Integra Neurosciences, Plainsboro, NJ,

USA). Group-B “fascia lata graft group”: (N=14): patients were treated with free tissue fascia lata graft. Asymptomatic patients and prior operation on the posterior cranial fossa were excluded.

All patients had complete history, neurological assessment and basal laboratory investigations. Magnetic resonance imaging (MRI) of the brain and craniocervical junction as well as computed tomography (CT) of the brain were done preoperatively.

We performed a midline suboccipital craniectomy, a y-shaped durotomy, a bipolar electrocautery method to shrink the cerebellar tonsils, and duroplasty either by DuraGen or fascia lata graft, watertight closure.

Clinical outcomes after surgery are classified as excellent, good, and poor ⁷. If all of the patient's preoperative neurological problems have been

alleviated and he is able to resume his usual daily activities, the results were rated excellent. Partial enhancement in preoperative symptoms is good, as long as the patient can resume to his regular routine while poor outcomes are characterised as deterioration of the patient's neurological state and consciousness, or even death. We continue follow-up till 12 months.

Statistical analysis:

All data analyzed using statistical package for social sciences (SPSS) version 22 (SPSS Inc, Chicago, USA). For qualitative data, frequency and percent distributions was calculated. For quantitative data, mean, standard deviation (Sd) was calculated. significance was defined as P value < 0.05. The following tests were used; Mann-Whitney U test and Chi-Square test.

RESULTS

A total of twenty-eight patients with CM-I underwent posterior fossa decompression with duroplasty either by DuraGen graft or Fascia lata graft, their mean of age was 30.71 +7.96 and 33.64 +11.27 years, respectively. The majority in both groups were females 64.3% and 57.1%, respectively. There was no significance between both groups regarding age and sex (Table 1).

Regarding symptoms in DuraGen and Fascia lata group, the most prominent symptoms in both groups was occipital pain which presented in all patients followed by neck pain which presented in 78.6% and 71.4%, respectively without significance among both groups (Table 2).

Regarding clinical outcome, fascia lata group showed higher significant excellent rate (92.9%) than DuraGen group (57.1%) (p=0.032) Figure 1. Also, one patient showed good outcome and none showed poor outcome in patients with fascia lata graft while there were four patients with good outcome, two with poor outcome in DuraGen graft patients without significance (Table 3) Figure 2.

Considering postoperative complications, only one patient (7.1%) in fascia lata group showed tight bandage while DuraGen group showed eight patients (57.1%) with CSF leakage (p=0.001), four patients (28.6%) needed reoperations (p=0.033), Figure 3 two cases (14.3%) with Aseptic meningitis and ten cases (71.4%) with tight bandage (p < 0.001) (Table 4).

The majority of both groups showed marked reduction in size of syrinx (64.3% and 78.6%) without significance (Table 5).

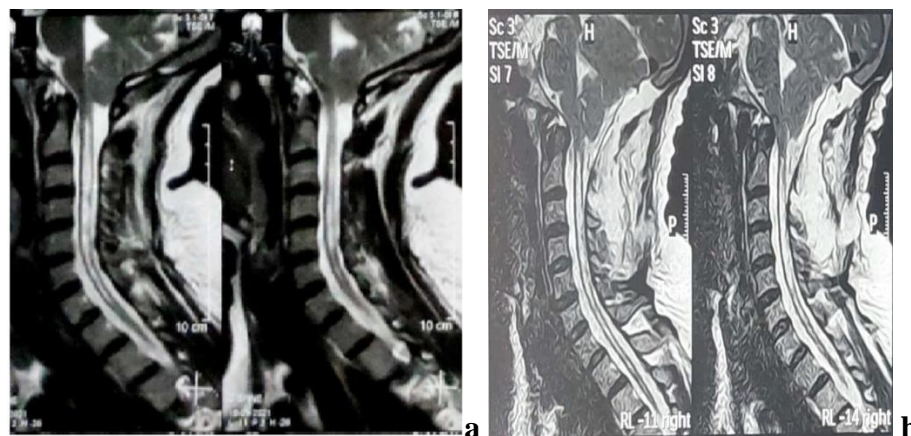

Fig. 1: a) MRI preoperative chiari type I b) postoperative using fascia lata

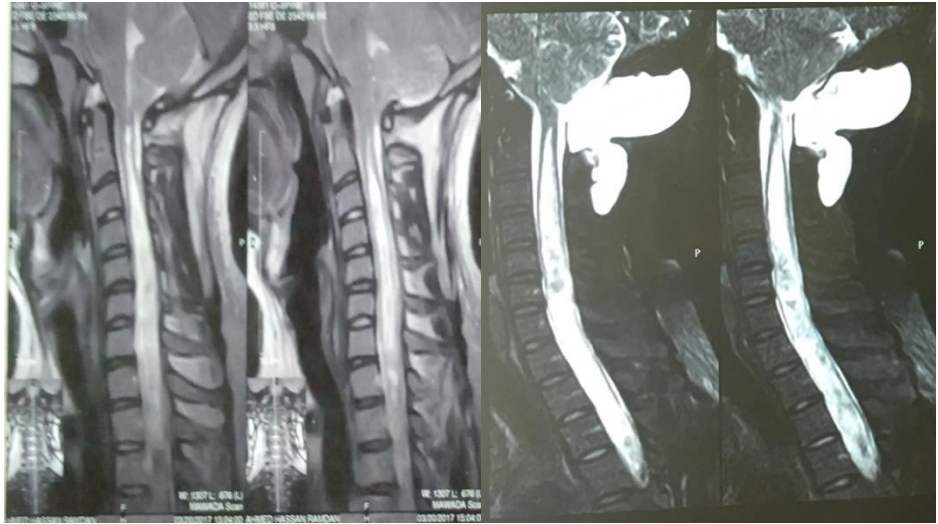

Fig. 2 : a) MRI preoperative chiari type I b) postoperative using dura Gen

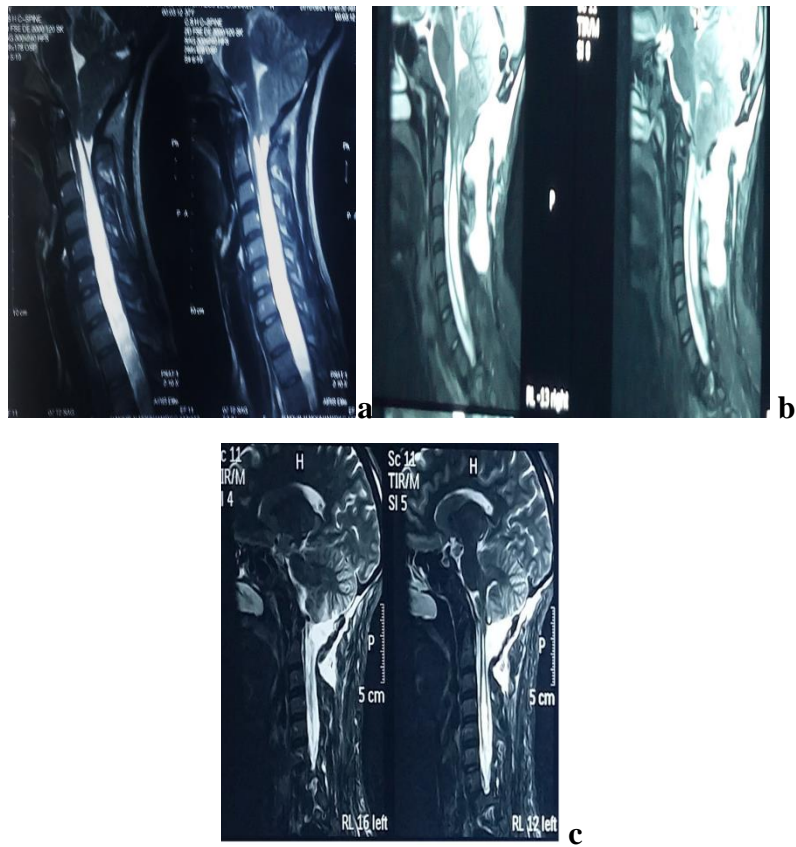


Fig. 3: a) MRI preoperative chiari type I b) postoperative using duragen c) after repair using fascia lata

		DuraGen graft (n=14)	Facia lata graft (n=14)	Test value	P value
Age (year)	Mean ±SD	30.71 ±7.96	33.64 ±11.27	0.795	0.434
	Range	18 - 41	20 - 52		
Gender	Male	5 (35.7%)	6 (42.9%)	0.147	0.702
	Female	9 (64.3%)	8 (57.1%)		

Table 1: Demographic data of studied patients

	DuraGen graft (n=14)	Facia lata graft (n=14)	Test value	P value
	No (%)	No (%)		
Neck pain	11 (78.6%)	10 (71.4%)	0.187	0.665
Occipital pain	14 (100%)	14 (100%)	0.000	1.000
Numbness and parasthesia	8 (57.1%)	8 (57.1%)	0.000	1.000
Weakness	8 (57.1%)	6 (42.9%)	0.544	0.461
Sphincteric dysfunction	2 (14.3%)	1 (7.1%)	0.366	0.545
Cerebellar manifestations	0 (0%)	1 (7.1%)	0.994	0.318

Table 2: Distribution of symptoms in studied patients

	DuraGen graft (n=14)	Facia lata graft (n=14)	Test value	P value
	No (%)	No (%)		
Excellent	8 (57.1%)	13 (92.9%)	4.614	0.032*
Good	4 (28.6%)	1 (7.1%)	2.128	0.145
Poor	2 (14.3%)	0 (0%)	2.079	0.149

*p value was significant

Table 3: Clinical outcome after surgery

	DuraGen graft (n=14)	Facia lata graft (n=14)	Test value	P value
	No (%)	No (%)		
CSF leak	8 (57.1%)	0 (0%)	10.789	0.001*
Reoperation	4 (28.6%)	0 (0%)	4.505	0.033*
Aseptic meningitis	2 (14.3%)	0 (0%)	2.079	0.149
Tight bandage	10 (71.4%)	1 (7.1%)	11.704	< 0.001*

*p value was significant

Table 4: Postoperative complications in studied patients

	DuraGen graft (n=14)	Facia lata graft (n=14)	Test value	P value
	No (%)	No (%)		
Marked reduction	9 (64.3%)	11 (78.6%)	0.677	0.441
Mild reduction	4 (28.6%)	2 (14.3%)	0.819	0.365
No change	1 (7.1%)	1 (7.1%)	0.000	1.000

Table 5: Size of syrinx after surgery

DISCUSSION

Using an expansile duroplasty after CMI decompression is expected to reduce foramen magnum crowding while also aiding the return of more normal CSF flow phenomena. However, the most frequent consequence is pseudomeningocele development if a CSF leak is not prevented during duroplasty closure⁸.

Materials and techniques for repairing a dural defect are numerous. Avascular grafts comprise autologous grafts and engineered collagen grafts. Autologous grafts involve fat, fascia, bone, cartilage, and free mucosa grafts taken from patients. Engineered collagen grafts (i.e., DuraGen), thought to act as scaffolding for the growth of indigenous cells can be used suturelessly, but post-operative complications may predispose the patients^{9,10}.

The goal of this research was to establish if the kind of dura graft used in patients with CM-I affects the outcome and/or minimises the occurrence of problems in these individuals. To our knowledge, this is a novel study which compare fascia lata graft with engineered collagen graft.

In short-term follow-up, Klekamp found that posterior fossa decompression with duraplasty improved clinical outcomes in patients by 73.6%, irrespective to type of the graft whether an autologous or nonautologous. Additionally, he found that 14.3% of patients within 5 years and 15.4% of patients within 10 years had substantial neurological impairment, with a much greater recurrence rate when the autologous graft was applied¹¹.

The two study groups, exhibited comparable demographic parameters. Also, the most prominent complaint in both groups was occipital pain which presented in all participants followed by neck pain which presented in 78.6% and 71.4%, respectively without significant difference between groups. These results are comparable to the findings of the research, in which headache happened in 100% of individuals and neck ache occurred in 89% of cases, respectively¹².

Regarding clinical outcome, fascia lata group showed higher significant excellent rate (92.9%) than DuraGen group (57.1%) (p=0.032). Also, one patient showed good outcome and none showed poor outcome in patients with fascia lata graft while in DuraGen graft patients, there were four patients with

good outcome, two with poor outcome and one with incapacitated outcome without significance.

In the same line, a study by Elsaïd et al.⁷ who used fascia lata graft duraplasty reported at the end of follow up for one year that excellent clinical outcome was noted in twelve patients (75%), the rate of good outcome was 12.5% (two patients), fair outcome in one patient (6%) and poor outcome in one patient (6%).

Another study done by Elkatatny et al.¹³ who used fascia lata graft showed that 18 (60%) cases showed a significant postoperative enhancement, 6 (20%) showed fair enhancement & 6 (20%) were poor.

On the other hand, a study by Chotai and Medhkour¹⁴, who involved ten patients and used artificial dura graft for duraplasty and reported that six patients have excellent outcome, two patients with both good and poor outcome.

Some materials, such as nonautologous grafts, appear to predispose cases to specific complications, such as aseptic meningitis and bacterial infections¹⁵. In our study, there were two patient (14.3%) had aseptic meningitis in DuraGen group.

Our study revealed that CSF leakage observed in 8 patients (57.1%) in DuraGen group while none in fascia lata group showed a leakage. Vanaclocha *et al.*¹⁶ found that nonautologous grafts (Polytetrafluoroethylene) resulted in leaking of CSF fluid by 15% following duraplasty, whereas pericranium did not. After a duraplasty with pericranium, Attenello *et al.*¹⁷ found a greater incidence of CSF leakage. A recent multi-center research conducted by Yahanda *et al.*¹⁸ found that autografts and nonautologous grafts had a similar overall complication rate (p=0.12), with greater incidence of pseudomeningocele (p=0.04) associated with the use of the nonautologous graft which was similar to our results. A recent study by Elkatatny *et al.*¹³ observed CSF leakage in 6.6% in fascia lata graft.

People with CM-I are more likely to suffer from syringomyelia, which is one of the most common causes of neurological symptoms and impairments in these patients. One of the major aims of surgical therapy for individuals with CM-I is the enhancement or elimination of syringomyelia¹⁹. Syringomyelia enhancement or resolution was recorded in all of the published series (paediatric, adult, combined and total) for almost three-quarters of the patients (78%) and there was no significant difference in syringomyelia outcomes across any of the series subgroups²⁰. Our study showed a comparable result regarding reduction of size of syrinx.

Our study limitations were small sample of patients and short period of follow-up which may have a role in our findings.

CONCLUSION

CM-I decompression surgery with duraplasty by fascia lata graft has a better outcome and lower significant rate of CSF leakage and other

postoperative complications than engineered collagen graft (DuraGen).

Conflict of interest : none

REFERENCES

- Chiari, H. Uber Veränderungen des Kleinhirns infolge von Hydrocephalie des Grosshirns. *Deutsche medizinische Wochenschrift*. 1891; 17, 1172-5. (in German) <https://doi.org/10.1055/s-0029-1206803>
- Armonda, R.A., Citrin, C.M., Foley, K.T. and Ellenbogen, R.G. Quantitative Cine Mode Magnetic Resonance Imaging of Chiari I Malformations. *An Analysis of Cerebrospinal Fluid Dynamics. Neurosurgery*. 1994; 35, 214-24. <https://doi.org/10.1227/00006123-199408000-00006>
- Goel, A. and Desai, K. Surgery for Syringomyelia. An Analysis Based on 163 Surgical Cases. *Acta Neurochirurgica*. 2000; 142, 293-302.
- Stover, L.J., Bergan, U., Nilsen, G. and Sjaastad, O. Posterior Cranial Fossa Dimensions in the Chiari I Malformation. Relation to Pathogenesis and Clinical Presentation. *Neuroradiology*. 1993; 35, 113-8. <https://doi.org/10.1007/BF00593966>
- Almotairi FS, Tisell M. Cerebrospinal fluid disturbance in overweight women after occipitocervical decompression in Chiari malformation type I. *Acta Neurochir*. 2016;158(3):589-94.
- Hoffman H, Bunch KM, Paul T, Krishnamurthy S. Comparison of pericranial autograft and AlloDerm for duraplasty in patients with type I Chiari malformation: retrospective cohort analysis. *Operative Neurosurgery*. 2021 Dec;21(6):386-92.
- Elsaïd, A and El-Borady, M. Posterior Fossa Decompression with Duroplasty for Treatment of Chiari Type I Malformation: Surgical Technique, Clinical and Radiological Outcome. *Egyptian Journal of Neurosurgery*. 2015; 30, 285-90.
- Battal B, Kocaoglu M, Bulakbasi N, Husmen G, Tuba Sanal H, Tayfun C. Cerebrospinal fluid flow imaging by using phase-contrast MR technique. *Br J Radiol*. 2011; 84: 758-65.
- Prickett K & Wise S. Grafting materials in skull base reconstruction. In *Comprehensive Techniques in CSF Leak Repair and Skull Base Reconstruction*. Karger Publishers. 2013; 74:24-32.
- Oró JJ, Mueller DM. Posterior fossa decompression and reconstruction in adolescents and adults with the Chiari I malformation. *Neurol Res*. 2011; 33: 261-71.
- Klekamp, J. Surgical treatment of Chiari I malformation—analysis of intraoperative findings, complications, and outcome for 371 foramen magnum decompressions. *Neurosurgery*. 71(2), 365–80.
- Kamal, H.M. Posterior Fossa Decompression with Microscopic Fenestration of Foramen of Magendi and Duroplasty in Treatment of Adult Chiari Type I Malformation: Preliminary Results in 18 Consecutive Patients. *Egyptian Journal of Neurosurgery*. 2009; 24, 63-78.

13. Elkatatny AA, Aly MH. Chiari Malformation Type 1 in Adults Managed by Surgical Decompression: New Prospective. *Open Journal of Modern Neurosurgery*. 2020; 8;10(3):382-91.
14. Chotai S, Medhkour A. Surgical outcomes after posterior fossa decompression with and without duraplasty in Chiari malformation-I. *Clinical neurology and neurosurgery*. 2014;125:182-8.
15. Farber, H., McDowell, M. M., Alhourani, A., Agarwal, N. & Friedlander, R. M. Duraplasty type as a predictor of meningitis and shunting after Chiari I decompression. *World Neurosurg*. 118, e778–e783.
16. Vanaclocha, V. & Saiz-Sapena, N. Duraplasty with freeze-dried cadaveric dura versus occipital pericranium for Chiari type I malformation: Comparative study. *Acta Neurochir*. 1997; 139(2), 112–9. <https://doi.org/10.1007/bf02747190>.
17. Attenello FJ, McGirt MJ, Garcés-Ambrossi GL, Chaichana KL, Carson B, Jallo GI. Suboccipital decompression for Chiari I malformation: outcome comparison of duraplasty with expanded polytetrafluoroethylene dural substitute versus pericranial autograft. *Child's Nervous System*. 2009 Feb;25(2):183-90.
18. Yahanda AT, Adelson PD, Akbari SHA, et al. Dural augmentation approaches and complication rates after posterior fossa decompression for Chiari I malformation and syringomyelia: A Park-Reeves Syringomyelia Research Consortium study. *J. Neurosurg. Pediatr.* 2021; doi: 10.3171/2020.8.PEDS2087.
19. Haroun, R.I., Guarnieri, M., Meadow, J.J., Kraut, M. and Carson, B.S. Current Opinions for the Treatment of Syringomyelia and Chiari Malformations: Survey of the Pediatric Section of the American Association of Neurological Surgeons. *Pediatric Neurosurgery*. 2000; 33, 311-17. <https://doi.org/10.1159/000055977>
20. Zhang, Z.Q., Chen, Y.Q., Chen, Y.A., Wu, X., Wang, Y.B. and Li, X.G. () Chiari I Malformation Associated with Syringomyelia: A Retrospective Study of 316 Surgically Treated Patients. *Spinal Cord*. 2008; 46, 358-63. <https://doi.org/10.1038/sj.sc.3102141>