

Endoscopic Approach for Management of Colloid Cyst

Mahmoud Hamed Abdelaal ¹M.B.B.Ch ; Adel Ragab Almelesy ¹MD ; Alazzazi Rabei Alazzazi ¹MD .

*Corresponding Author:

Mahmoud Hamed Abdelaal
mahmoudhamed633@gmail.com

Received for publication August 07, 2022; Accepted November 22, 2022;
 Published online November 22, 2022.

doi: 10.21608/aimj.2022.154942.2072

Citation: Mahmoud H. Adel R. and Alazzazi R. . Endoscopic Approach for Management of Colloid Cyst. AIMJ. 2022; Vol.3- Issue11 : 210-219.

¹Neurosurgery Department, Faculty of Medicine, Al-Azhar University, Cairo , Egypt.

ABSTRACT

Background: Third ventricular colloid cysts are uncommon tumors that make up 15 to 20% of intraventricular tumors and 0.2 to 2% of intracranial tumors. Colloid cysts are benign tumors, but they may grow until they block the foramen of Monro, which might result in a fatal accident.

Aim of the work: To assess of the efficacy of endoscopic excision (total or subtotal) of the colloid cyst in relation to the size of cyst.

Patients and methods: The research was prospectively carried out at the neurosurgery department of Al-Azhar university hospitals, from January 2019 to December 2021. Included fifteen patients with colloid cyst and they were operated by endoscope for their mass and hydrocephalus.

Results: This study showed that male-to-female ratio was 1.5:1, and the median age was 32.87 years. Headache was the commonest presenting symptom affecting in 93.3% of patients. Most patients (93.3%) were hydrocephalic at time of presentation. The mean cyst diameter was 20.53 mm. The cyst was usually hyperdense in CT scans (60%), hyperintense in T1W MRI (60%) and with variable T2W appearance.

Conclusion: Colloid cysts are usually hyperdense in CT scans and hyperintense in T1 MRI. They may require surgical resection if larger than 1 cm in diameter or causing symptoms to avoid rapid neurological deterioration and unexpected death brought on by CSF flow occlusion. The size of the colloid cyst has no significant impact on of the efficacy of the endoscopic resection of the colloid cyst.

Keywords: Approach; Colloid cyst size; Endoscopic.

Disclosure: The author has no financial interest to declare in relation to the content of this article. The Article Processing Charge was paid for by the author.

Authorship: The author has a substantial contribution to the article.

Copyright The Author published by Al-Azhar University, Faculty of Medicine, Cairo, Egypt. Users have the right to read, download, copy, distribute, print, search, or link to the full texts of articles under the following conditions: Creative Commons Attribution-Share Alike 4.0 International Public License (CC BY-SA 4.0).

INTRODUCTION

More than half of individuals with third ventricle colloid cysts present with symptoms at the time of identification and eventually need neurosurgical treatment. Without regard to gender, they were often diagnosed between the second and fifth decades of life, and the median diameter of symptomatic tumors was around 12 mm.¹

Most of these individuals exhibit hydrocephalus symptoms, such as headache, vomiting, impaired vision, gait ataxia, and a deterioration in cognitive abilities. A tiny percentage of individuals with symptoms have acute obstructive hydrocephalus, which may develop into sudden death.²

In particular, for asymptomatic individuals with accidentally detected lesions who are frequently lost to follow-up, attempts to build evidence-based prognostic variables and surgical indications have been hampered due to poor knowledge of the natural history of colloid cysts. Patients with lesions smaller than 1 cm in size often get repeated imaging and observation, but those with bigger or symptomatic lesions have surgery.²

On a computed tomography (CT) scan, colloid cysts are often homogeneously hyperdense as compared to the brain. Tumors are frequently hyperintense on T1-

weighted sequences of magnetic resonance imaging (MRI) and hypointense on T2-weighted sequences.³

Recently, several researchers have come to the conclusion that the endoscopic method of removing colloid cysts is less intrusive than conventional microsurgical methods and may reduce morbidity and postoperative consequences, including decreased rates of infection, infarct, and seizure. Additionally, the rate of shunt reliance has fallen statistically significantly.⁴

The inability to conduct bimanual micro dissecting of the cyst wall from the important structures is one of the main criticisms of the typical single-burr hole endoscopic procedure. This method depends on cyst wall suction followed by coagulation of the leftover cyst wall remnants. The likelihood of a subsequent recurrence is increased by the existence of remaining cyst wall. While endoscopic studies have reported shorter hospital stays and lower complication rates, microsurgical series have traditionally shown greater rates of full resection.⁵

The aim of the work was to assessment of the efficacy of endoscopic excision of the colloid cyst in relation to the size of cyst.

PATIENTS AND METHODS

The research was prospectively carried out at the neurosurgery department of Al-Azhar university hospitals, from January 2019 to December 2021. included fifteen patients with colloid cyst and they were operated by endoscope for their mass and hydrocephalus.

Preoperatively, all patients were subjected to:

History taking: Personal history: Name, age, sex, profession, place of residence, marital status, any unusual habits of medical significance, and the patient's complaints in their own words. In addition to other complaints related to the patient's symptoms, the complaint presented was the one that caused the patient the greatest discomfort, present history: concentrating on examination of the patient's symptomatology, particularly its onset, progression, and persistence. The patient was asked about other neurological symptoms if not mentioned, including symptoms of increased ICP as headache, nausea, vomiting, and visual symptoms, e.g., blurring of vision, symptoms of cranial nerve affection, sensory or motor affection, gait and balance disturbance, sphincteric disturbance, seizures, attacks of loss of consciousness, and memory deficit, past history: including allergies, past radiation exposure, previous surgeries, drugs used, and any related medical conditions such diabetes and high blood pressure and family history: including history of diabetes, hypertension, tumors and similar conditions among family members, and positive consanguinity.

Clinical examination: General examination: complete general examination was applied for every case including the patient's skeletal and urogenital systems, length, weight, head, neck, chest, and belly, as well as their vital signs and neurological examination: A fully detailed and thorough neurological examination was performed for every case, including:

Conscious level assessment by GCS, general intellectual functions including orientation, general fund of knowledge, and global attention, memory and affect, cranial nerves with special attention to optic nerve by visual acuity, field of vision and fundus, motor system including state of muscles, tone, and motor power, reflexes, including superficial and deep reflexes, sphincters, sensory system including superficial, deep and cortical sensations and gait and coordination.

Investigations: standardized laboratory tests: including PT, PC, INR, serum sodium and potassium, CBC, blood sugar, hepatic and renal functions tests, and blood sugar. ECG was done for all patients more than 40 years of age and radiological investigations: all patients had preoperative plain and postcontrast CT scans as well as MRI with contrast of the brain. CT scans were used primarily to show the hydrocephalic changes, presence of calcified or hemorrhagic areas. MRI of the brain with contrast was done to show the exact site, size, and enhancement of the lesion to differentiate from other lesions of the third ventricle, and for planning of the management. MRI included

T1W, T2W, and T1W with contrast, and FLAIR sequences obtained in axial, coronal and sagittal planes. Typically, axial views are used to quantify cyst size.

Inclusion criteria: Patients with large colloid cysts of third ventricle (1 cm or more in diameter) or smaller symptomatic cysts, age range 12 – 65 years and patients fit for general anesthesia.

Exclusion criteria: Patients under the age of 12 and over the age of 65, those with small, asymptomatic third ventricle colloid cysts, those with radiologically solid colloid cysts, those with colloid cysts outside the third ventricle, those who refuse surgery or are medically unfit for surgery, and those with other third ventricle lesions.

Operative procedures: A right frontal linear or semilunar skin incision was made over Kocher's point, 3 cm lateral from midline, immediately anterior to the coronal suture, while the patient was under general anesthesia, reclined, and had his or her head raised 30 degrees. A 1.5-cm burr hole was done at Kocher's point and a cruciate dural incision was made. After bipolar cauterization of the cortical surface and vessels, the endoscope was introduced into the ventricular system.

The relationship between the anatomical landmarks and the colloid cyst was determined after comprehensive endoscopic evaluation of the anatomical structures and foramen of Monro landmarks. Bipolar coagulation of the cyst capsule and the choroid plexus above it was used as the first step in the resection of the cyst, which was then followed by the fenestration of the capsule.

Suction of the contents was tried after inserting a central venous cannula. After the cyst's entire contents were removed, bipolar shrinking of the cyst capsule's inner and outer surfaces enabled maximal resection.

The endoscope was withdrawn after making sure that there was no intraventricular bleeding. EVD was placed in 3 patients. Gel foam was used to plug the site of the corticectomy and to cover the burr hole, followed by galeal and skin closure

Postoperative management: Prior to being moved to the normal patients' ward, all patients had at least the first 24 hours of postoperative monitoring in an intensive care unit (ICU). All patients were treated during the postoperative hospital stay by prophylactic broad-spectrum antibiotics, anti-epileptics, and dehydrating measures, in addition to analgesics, antipyretics and antiemetic as needed. Routine postoperative laboratory investigations were done for all patients including CBC, liver and renal functions, and serum electrolytes.

A thorough and in-depth postoperative neurological clinical examination was performed on each patient.

The patients were monitored in the early postoperative period for manifestations of increased ICP, and for possible postoperative complications.

In patients with EVDs, the EVD was initially left open at 15 cm H₂O and monitored for amount and

color of fluid. Weaning of EVD was usually tried on the third day as long as the CSF was clear. The patient was carefully watched for symptoms of elevated ICP, such as headache, nausea, and vomiting, and the EVD was closed for 24 hours after that. Subsequently, a brain CT scan was done to make sure that the ventricles had not enlarged, and the EVD was then taken out. When there were signs of hydrocephalus, the patient was operated upon for V-P shunt insertion.

Postoperative radiology: All patients were subjected to control plain and postcontrast CT scans of the brain in the first 48 hours postoperatively to evaluate extent of tumor resection, size of ventricles, periventricular CSF permeation, and cortical effacement. Another brain CT scan was done 24 hours after closure of EVD before its removal, then another CT scan 1 – 2 days after removal of EVD. Serial CT scans of the brain were done during the postoperative hospital stay until the patient was discharged for exclusion of hydrocephalus. MRI of the brain with contrast was done 1 month after surgery to detect any cyst remnants.

Patient discharge and follow-ups: Patients were kept in the hospital until they were stable enough for discharge. Then, at intervals of one week, one month, three months, and six months, all patients were followed up in the outpatient clinic.

Outcome measures:

Patient's outcome was assessed according to:

Extent of tumor resection: evaluated by postoperative plain and postcontrast CT scans of the brain in the first 48 hours, and follow-up MRI done after 1 month. Resection is called “gross total resection” when there are no obvious remnants of colloid cyst visible on postoperative brain scans. If a portion of the cyst can still be seen on a postoperative brain scan, it is called a “subtotal resection.” And improvement of symptoms: including headache, nausea and vomiting, attacks of loss of consciousness, visual symptoms including blurring of vision, diminution of vision and diplopia, gait disturbance, urinary incontinence, memory deficit, motor deficit, dizziness, seizures, and DCL. The postoperative improvement of symptoms was assessed in the 6 months period of follow-up.

Postoperative complications: including persistent hydrocephalus requiring V-P shunting, intraventricular hemorrhage, intracerebral hematoma, subdural hematoma, subdural hygroma, arterial infarction, venous infarction, mutism, memory deficit, hemiparesis/hemiplegia, CSF leak, seizures, ventriculitis, meningitis, wound infection, and death.

RESULTS

Items		Study cases n= 15
Age (years)	Mean ± SD	32.87 ± 9.86
	Median (min-max)	31 (16-46)
Sex		
• Males		9 (60%)
• Females		6 (40%)

Quantitative data represented as (mean ± SD) or median (min-max), Categorical data represented as Number (%)

Table 1: Demographic data in the study cases

	Study cases n= 15	
	Frequency	Percent (%)
Headache	14	93.3
Blurring of vision	8	53.3
Diminution of vision	3	20
Diplopia	2	13.3
Vomiting	4	26.7
Gait disturbance	3	20
Attacks of Loss of consciousness	2	13.3
Seizures	2	13.3
Urinary incontinence	2	13.3
Dizziness	2	13.3
Memory deficit	1	6.7
DCL	1	6.7
Tremors	1	6.7

Categorical data expressed as Number (%)

Table 2: Analysis of the presenting symptoms in the study cases

	Study cases n= 15	
	Frequency	Percent (%)
Normal	3	20
Papilledema (bilateral)	12	80
decreased visual acuity	5	33.3
6 th nerve palsv	2	13.3
Gait disturbances	3	20
Kinetic tremors	1	6.7
Memory deficit	1	6.7
DCL	1	6.7

Categorical data expressed as Number (%)

Table 3: Analysis of the signs in the study cases

Items	Study cases n= 15
Preoperative hydrocephalus	
No	1 (6.7%)
Yes	14 (93.3%)
Preoperative V-P shunt	
No	15 (100%)
Yes	0 (0%)

Categorical data expressed as Number (%)

Table 4: Analysis of preoperative data in the study cases

Items	Study cases n= 15
Preoperative cyst CT density	
Hyperdense	9 (60%)
Hypodense	1 (6.7%)
Isodense	5 (33.3%)
Preoperative CT contrast enhancement	
No	15 (100%)
Yes	0 (0%)
Preoperative cyst T1W MRI signal	
Hyperintense	9 (60%)
Hypointense	1 (6.7%)
Isointense	5 (33.3%)
Preoperative cyst T2W MRI signal	
Hyperintense	8 (53.3%)
Hypointense	5 (33.3%)
Isointense	2 (13.3%)
Preoperative MRI contrast enhancement	
No enhancement	13 (86.7%)
Ring enhancement	2 (13.3%)

Categorical data expressed as Number (%)

Table 5: Analysis of preoperative radiological data in the study cases

Items	Study cases n= 15
Surgical procedure	
Endoscopic	15 (100%)
EVD insertion	
No	9 (60%)
Yes	6 (40%)
EVD duration (days)	Mean ± SD 7 ± 3.32
	Median (min-max) 7 (3-11)
ETV	
Not done	11 (73.3%)
Done	4 (26.7%)
Extent of tumor resection	
Subtotal	5 (33.3%)
Total	10 (66.7%)

Categorical data expressed as Number (%)

Table 6: Analysis of surgical data in the study cases

	Subtotal	resection (N=5)	Total resection (N=10)	Groups	Test	of significance
Cyst diameter (mm)		23.02 ± 7.4	19.2 ± 6.3		t= 0.969	p= 0.350

P: probability.

Quantitative data are expressed as mean ± SD (range)

T: Paired samples t-test

Table 7: Correlation between extent of resection and diameter of the cyst

Case 1

History: 28 years old male patient, complaining of dull-aching bifrontal headache for 2 months of gradual onset and progressive course. The patient also developed blurring of vision 1.5 month prior to admission of gradual onset and progressive course.

Examination: GCS 15 and Bilateral papilledema G3.

Imaging: CT showed hyperdense well-circumscribed circular mass in the third ventricle with no contrast enhancement, and hydrocephalus and MRI showed isointense circular third ventricular mass in T1W sequence, and hyperintense in T2W sequence, measuring 25 mm in diameter, with no contrast enhancement.

Management: Endoscopic approach, no EVD was inserted and ETV was done.

Postoperatively: All symptoms improved, no complications, follow-up CT and MRI showed GTR of the cyst and the patient was discharged 6 days after surgery with excellent outcome.

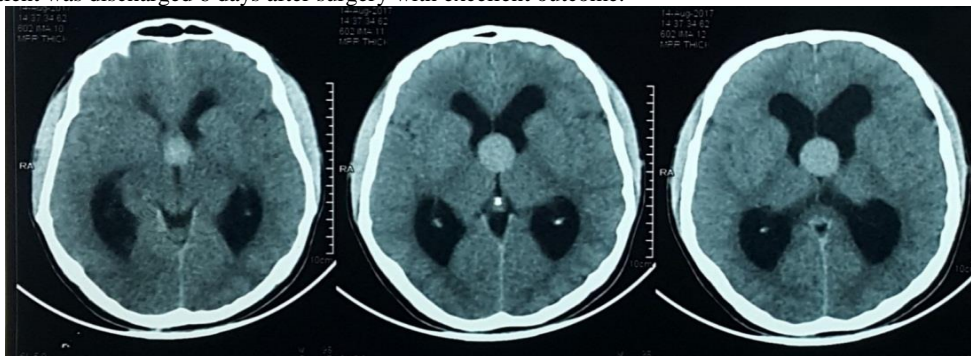

Fig. 1: Preoperative brain CT scan showing hyperdense colloid cyst in the third ventricle and hydrocephalus.

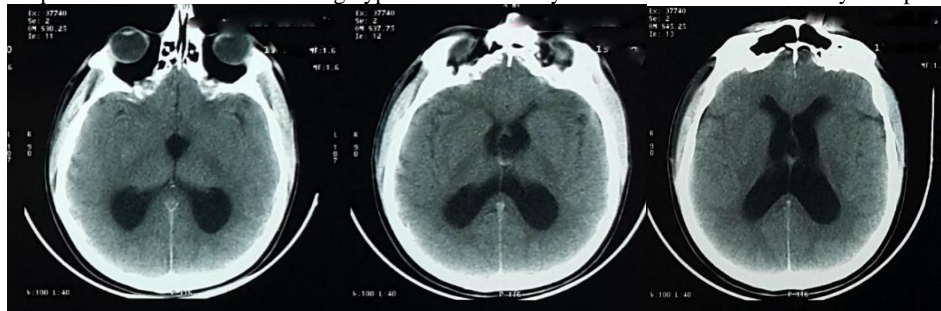


Fig. 2: Postoperative brain CT scan showing GTR of colloid cyst and normal-sized ventricles

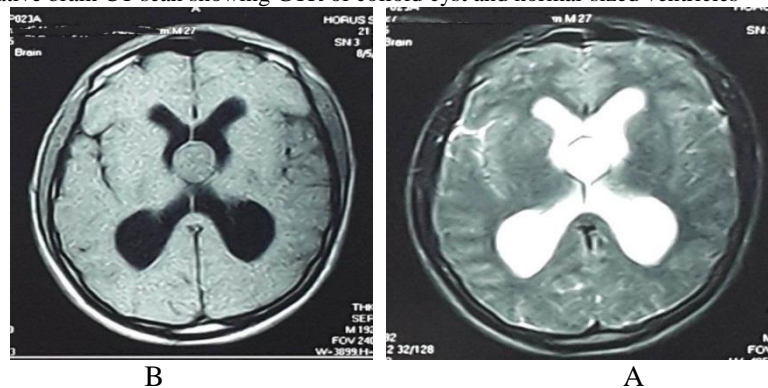


Fig. 3: Preoperative MRI of the brain showing isointense colloid cyst in the third ventricle in T1W sequence (A) and hyperintense in T2W sequence (B)

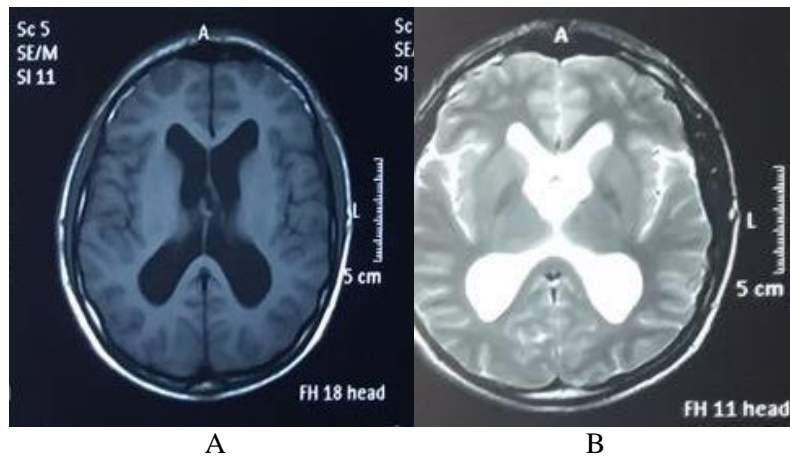


Fig. 4: Postoperative MRI of the brain done after 1 month of surgery showing GTR of the colloid cyst in axial T1W (A) and T2W (B) sequences

Case 2

History: 27 years old male patient, complaining of bifrontal headache for 3 months of acute onset and intermittent course, associated with nausea and vomiting. The patient also developed blurring and diminution of vision, more in the left eye, for 1.5 month of gradual onset and progressive course.

Examination: GCS 15, visual acuity in right eye 6/12, and in left eye 6/36 and bilateral papilledema G3.

Imaging: CT showed hyperdense round mass in the third ventricle with no contrast enhancement, and hydrocephalus and MRI showed isointense circular mass in the roof of the third ventricle in T1W sequence, and hypointense in T2W sequence, measuring about 11 mm in diameter, with no contrast enhancement.

Management: Endoscopic approach, EVD was inserted after cyst resection.

Postoperatively: All symptoms improved, no complications, follow-up CT and MRI showed small cyst remnants, EVD was removed 4 days postoperatively and the patient was discharged 12 days after surgery with good outcome.

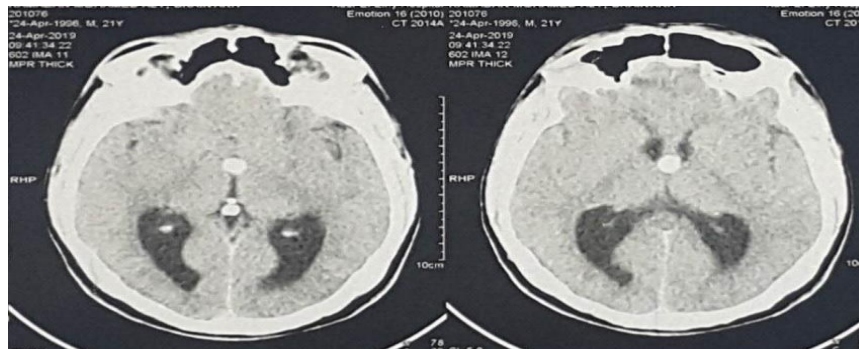


Fig. 5: Preoperative brain CT scan showing hyperdense third ventricular colloid cyst and hydrocephalus.

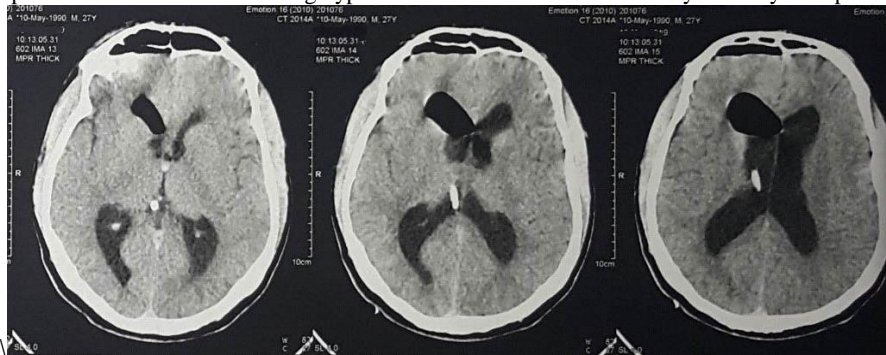


Fig. 6: Postoperative brain CT scan done 1 day after surgery showing small hyperdense colloid cyst remnant, pneumocephalus and EVD

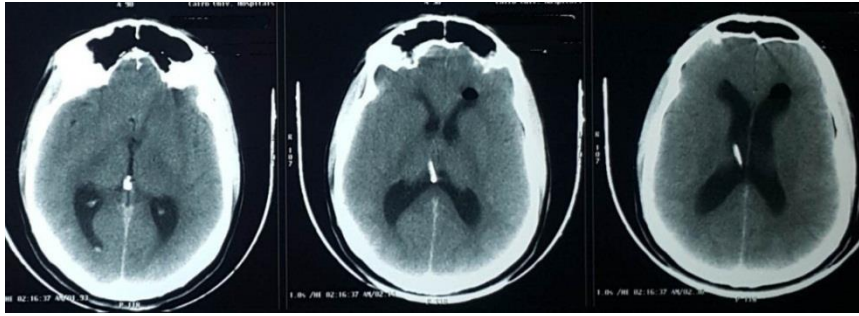


Fig 7: Brain CT scan done 24 hours after closure of EVD showing normal-sized ventricles

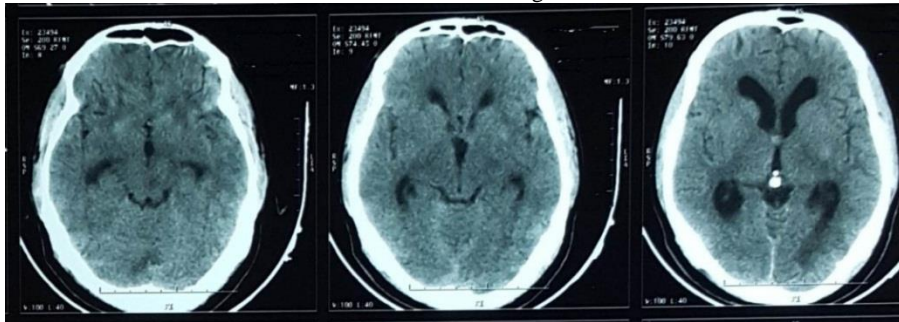


Fig. 8: Follow-up brain CT scan done after removal of EVD showing small cyst remnant, and normal-sized Ventricles

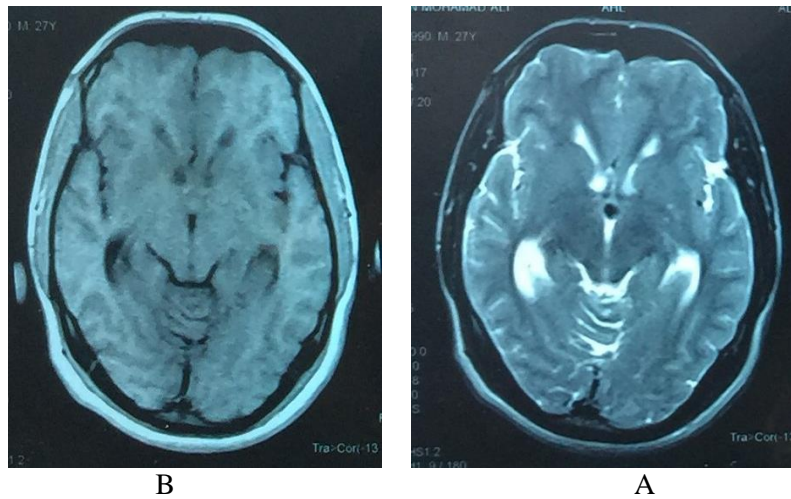


Fig. 9: Preoperative MRI of the brain showing colloid cyst of the third ventricle, isointense in axial T1W (A) and hypointense in T2W sequence (B)

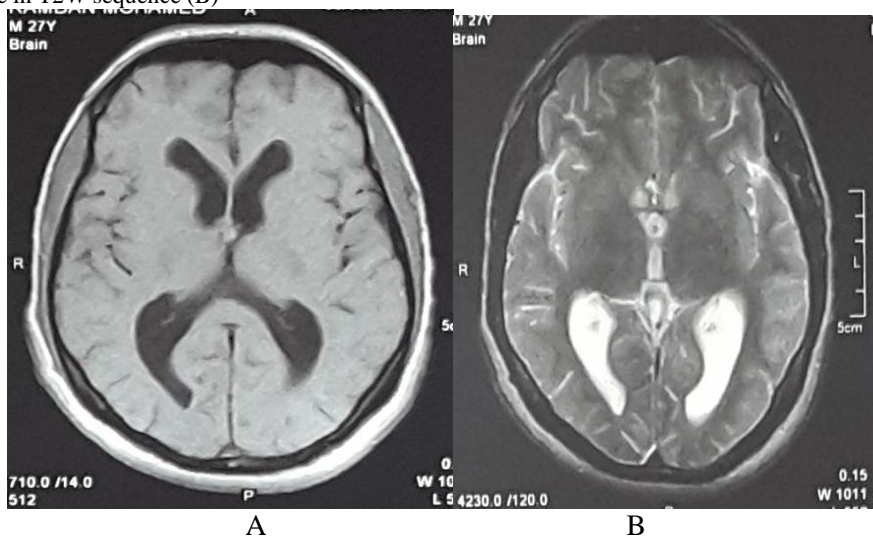


Fig. 10: Postoperative MRI of the brain done after 1 month of surgery showing small isointense cyst remnant in axial T1W sequence (A) hypointense cyst remnant in axial T2W sequence (B).

DISCUSSION

Colloid cysts are not genuine tumors but rather an uncommon developmental abnormality. Colloid cysts are made up of an inner epithelium of ciliated or mucin-producing cells and an outer fibrous layer.⁶

Due to the long-standing dominance of microsurgical techniques, the endoscopic approach in the treatment of intraventricular malignancies has only recently been generally relevant. At first, it was mostly used in conjunction with so-called aiding neuroendoscopy for tumor biopsy.⁷ Powell et al. were the first to document a successful endoscopic aspiration of a third ventricle colloid cyst in 1983.⁸

The best way to treat colloid cysts is still up for dispute, despite the fact that endoscopic colloid cyst removal has gained popularity over the last 20 years. Endoscopic cyst resection typically does not include a radical resection, despite the fact that it has a low complication rate and great short-term results.⁹ A greater risk of cyst recurrence must thus be anticipated.¹⁰

The current study was conducted at Al-Azhar University hospitals aiming to analyze the colloid cyst's size in relation to the effectiveness of endoscopic removal. A total of 15 patients were included, and their age ranged between 16 and 46 years (mean = 32.87 years).

A recent report stated that These tumors may develop at any age; however, they often show symptoms between the ages of three and six.¹¹ Vorbau et al. included a total of 20 cases whose age ranged between 14 and 61 years (mean = 39 years).¹²

In another study handling the same perspective, The incidental group's average age at surgery was 39.7 years (range: 12-69 years), whereas the symptomatic group's average age was 43.3 years (range: 11-81 years).¹³ The previous study reported an age range higher than ours.

In the current study, we included a total of 9 male patients (60%) along with 6 females (40%). In line with our findings, Yadav et al. reported the superiority of male gender in that pathology, as they constituted 66.67% of the included cases, in their study that included 24 patients.¹⁴ Mishra et al. also confirmed the previous findings.¹⁵

On the other hand, Margetis and his coworkers reported that In the incidental group, there were 10 men and 10 females (50%) whereas in the symptomatic group, there were 28 males (49.1%) and 29 females (50.9 percent).¹³ It is apparent that the previous study had a more or less similar prevalence of both genders in their included sample. Another recent study also confirmed the previous findings.¹²

In our study, all cases had a GCS of 15 apart from only one patient who had a GCS of 14. Mishra et al. reported that Four patients who were unconscious when they arrived at the emergency room needed an urgent external ventricular drain (6.78 percent).¹⁵

Regarding the presenting symptoms of the included cases, headache was the most prominent symptom, as it was reported by 14 patients (93.3%), followed by blurring of vision (8 patients – 53.3%) and other visual symptoms (7 patients – 46.7%). Other manifestations included nausea, vomiting, loss of consciousness, visual loss, gait disturbances,

diplopia, seizures, urinary incontinence, dizziness, memory deficit, DCL and tremors.

Colloid cysts may induce elevated intracranial pressure, headache, and papilledema even though they are usually asymptomatic.¹⁶ The headaches are often frontal, sporadic, intense, transient, and accompanied by nausea and vomiting. By laying down, the headache may be eased.¹⁷ Occasionally, hydrocephalus may cause irregularities in gait.¹¹

In a related study, the most common presenting symptoms were headache (70 percent), nausea, vomiting, and dizziness (30 percent), neuropsychological deficits (30 percent), paresthesia (25 percent), hemiparesis (10 percent), loss of consciousness (5 percent), impaired vision, fatigue, and seizure (10 percent), and tremor, gait disturbance, a twitching hand, and a shaking hand (5 percent).¹¹

Additionally, according to Mishra and his colleagues, the majority of their patients complained of non-localizing headaches (53; 89 percent). In addition, there were other signs such as vomiting (20; 34%), drop attacks (14; 24%), impaired vision (13; 22%), ataxia with incontinence (13; 22%), diplopia (3; 5%), altered sensorium (4; 6.8%), and seizure (4%). (1; 1.7 percent).¹⁵

When it comes to clinical signs detected in our patients, papilledema was detected in 12 patients (80%), decreased visual acuity (5 patients – 33.3%), gait disturbance (13.3%) and sixth nerve palsy (13.3%). Other findings included kinetic tremors, memory deficit and DCL.

Other authors agreed with our findings regarding papilledema, as it was the most prevalent sign in their study (23/24 cases – 95.83%).¹⁸

In the current study, preoperative hydrocephalus was present in the majority of patients included (14 patients – 93.3%). However, no cases had previous VP shunt surgery.

Likewise, in the recent study conducted by Vorbau and his associates, in all cases except one, the cysts in the anterior third ventricle partially blocked the foramina of Monro and led to obstructive hydrocephalus (5 percent).¹²

In our study, the cyst's average diameter was 20.53 mm, and its diameter varied from 7 to 31 mm.

In a similar study conducted in 2014, For the incidental group, the median maximum cyst diameter was 9.7 mm (range 3-31 mm), but for the symptomatic group, it was 12 mm (range 5-34 mm).¹³

Other authors reported that the cyst's size ranged from 14 to 24 mm (median, 20 mm).¹⁴

In the current study, CT evaluation revealed hyperdense lesions in 9 patients (60%), followed by isodense lesions (33.3%) and hypodense lesion (6.7%). No contrast enhancement was detected in all of these cases.

Mishra and his associates reported that in 44 (or 75% of patients), the tumor was hyperdense; in fifteen (15%), it was isodense; and in nine (10%), it was hypodense.¹⁵

In a similar study, Yadav et al. reported that in 22 cases, a CT scan revealed a non-enhancing hyperdense lesion (91.67 percent).¹⁴ Mathiesen et al.

proved that The viscosity of a colloid cyst is correlated with its density on a CT scan.¹⁹

In our study, MRI revealed ring enhancement in only two cases (13.3%). In T1 images, nine cases had a hyperintense lesion, while another five had isointense lesion. The remaining case had hypointense lesion. On T2 images, hyperintense, hypointense and isointense lesions were detected in 53.3%, 33.3% and 13.3% of patients respectively.

Pollock et al. revealed that the colloid cyst's elevated T2 signal most likely reflects continuous cyst growth, therefore these imaging properties might potentially be employed as surgical cues.²⁰

Previous studies reported that The presence of cholesterol esters is likely the cause of the hypointensity in T2-dependent MRI images, which might make aspiration problematic.²¹

In the current study, EVD was inserted in six patients only (40%). Other authors reported that In 20% of incidental and 51% of symptomatic instances, an EVD was required.¹³

Yadav and his associates reported that Four instances (16.67%) still had external ventricular drains in place due to mild bleeding.¹⁴ Others reported that In 14 patients with modest chronic oozing or hazy CSF owing to the dissipation of the colloid material in the case of big cysts, intraventricular drains were employed (23.73 percent).¹⁵

Our findings showed that 10 out of the included 15 cases had total resection (10 cases – 66.7%), while the remaining five cases had subtotal resection.

According to the research, around 65 percent of times entire or gross total excision of the colloid cyst is achievable. Boogaarts et al.,⁹ which confirms our findings. The use of 30-degree optics allows for a better understanding of the third ventricle's anatomy. Coagulation remodeling of the tumor's capsule is advised before its removal. This causes the capsule to contract and makes further manipulation easier. The use of flexible tools put into the endoscope's lateral channels is beneficial at this point in the surgery. This calls for some surgical procedure expertise.²²

In another study, Total resection was accomplished in 82.3 percent of symptomatic patients and 90 percent of incidental cases ($p = 0.49$). The remaining cases had subtotal resection.¹³ The previous authors reported higher total excision rates compared to ours. The results of the previous study showed that If surgery is being considered for an accidental colloid cyst, endoscopic resection should be the first course of action since it may be done safely.

Another study reported that in 16 instances, complete cyst excision was accomplished (84.2 percent). Due to significant adhesion to the tela choroidea at the third ventricle's roof, minor fragments of the cyst capsule had to be left behind in 3 patients.¹² Stachura and his associates reported that 47 individuals (81%) had a complete colloid cyst removal. The choroid plexus, venous system, and wall adherence of the tight capsule to the third ventricle's roof influenced the radicality of the surgery in 11 instances.⁷

Differences between different studies regarding success rates could be attributing to mass characteristics, size, site and surgical experience.

In the present investigation, there was no substantial variation between the subtotal and total groups regarding preoperative tumor size ($p = 0.350$), which

had mean values of 23.02 mm and 19.2 mm in the same groups respectively. This indicates that tumor size had no significant impact on the quality of endoscopic resection.

To the best of our knowledge, there is a paucity of studies evaluating the effect of cyst size on the quality of endoscopic resection, and this represents a strength point of our study.

We did not encounter any persistent post-operative morbidity or mortality in our study, and that was the state in the study conducted by Hoffman et al. who also denied the occurrence of mortality or permanent morbidity in their included 56 patients.¹⁰

Our study has some limitations; first of all, it is a single center trial that included a small sample size. Additionally, the long-term follow up is lacking. The previous drawbacks should be well handled in the upcoming studies.

CONCLUSION

Colloid cysts are rare benign intracranial lesions, commonly located in the anterior aspect of the roof of the third ventricle. Colloid cysts most frequently present in the middle age from the third to fifth decades, and affect men more than women. Colloid cysts are usually symptomatic, presenting with symptoms of hydrocephalus, most commonly with headache. Colloid cysts are usually hyperdense in CT scans and hyperintense in T1 MRI. Colloid cysts require surgical resection if larger than 1 cm in diameter or causing symptoms to avoid rapid neurological deterioration and sudden death due to obstruction of CSF flow. The size of the colloid cyst has no significant impact on of the efficacy of the endoscopic resection of the colloid cyst.

Conflict of interest : none

REFERENCES

1. Isaacs AM, Bezchlibnyk YB, Dronyk J, Urbaneja G, Yong H, Hamilton MG. Long-term outcomes of endoscopic third ventricle colloid cyst resection: case series with a proposed grading system. *Operative Neurosurgery*. 2020; 19(2):134-42.
2. Beaumont T, Limbrick D, Rich K. Natural history of colloid cysts of the third ventricle. *J Neurosurg*. 2016; 125; 1420-30.
3. Algin O, Ozmen E, Arslan H. Radiologic manifestations of colloid cysts: A pictorial essay. *Can Assoc Radiol J*. 2013; 64; 56-60.
4. Sethi A, Cavalcante D, Ormond DR. Endoscopic versus microscopic transcallosal excision of colloid cysts: a systematic review in the era of complete endoscopic excision. *World neurosurgery*. 2019; 132:e53-8.
5. Sheikh A, Mendelson Z, Liu J. Endoscopic versus microsurgical resection of colloid cysts: A systematic review and meta-analysis of 1,278 patients. *World Neurosurg*. 2014, 82; 1187-97.
6. Heller RS, Heilman CB. Colloid cysts: evolution of surgical approach preference and management of recurrent cysts. *Operative Neurosurgery*. 2020; 18(1), 19-25.

7. Stachura K, Grzywna E, Krzyżewski RM, Kwinta BM. Retrospective evaluation of endoscopic treatment in colloid cyst of the third ventricle. *Videosurgery and Other Miniinvasive Techniques*. 2021; 16(1): 115-25.
8. Powell MP, Torrens MJ, Thomson GJ, Horgan GJ. Isodense colloid cysts of the third ventricle: a diagnostic and therapeutic problem resolved by ventriculoscopy. *Neurosurgery*. 1983; 13(3), 234-7.
9. Boogaarts HD, Decq P, Grotenhuis JA, Le Guérinel C, Nseir R, Jarraya B, et al. "Long-term results of the neuroendoscopic management of colloid cysts of the third ventricle: a series of 90 cases." *Neurosurgery*. 2011; 68(1), 179-87.
10. Hoffman CE, Savage NJ, Souweidane MM. The significance of cyst remnants after endoscopic colloid cyst resection: a retrospective clinical case series. *Neurosurgery* . 2013; 73(2), 233-9.
11. Chheda MG, Wen PY. Uncommon brain tumors. In Loeffler J. S. and Eichler A. F. (Eds.), UpToDate 2021; Online: *Wolters Kluwer*.
12. Vorbau C, Baldauf J, Oertel J, Gaab MR, Schroeder HW. Long-term results after endoscopic resection of colloid cysts. *World neurosurgery*. 2019; 122, e176-e185.
13. Margetis K, Christos PJ, Souweidane M. Endoscopic resection of incidental colloid cysts. *Journal of neurosurgery*. 2014; 120(6), 1259-67.
14. Yadav YR, Parihar V, Pande S, Namdev H. Endoscopic management of colloid cysts. *Journal of Neurological Surgery Part A: Central European Neurosurgery*. 2014; 75(05), 376-80.
15. Mishra S, Chandra PS, Suri A, Rajender K, Sharma BS, Mahapatra A. Endoscopic management of third ventricular colloid cysts: eight years' institutional experience and description of a new technique. *Neurology India*. 2010; 58(3), 412.
16. Macdonald L, Humphreys RP, Rutka JT, Kestle JR. Colloid cysts in children. *Pediatric neurosurgery*. 1994; 20(3), 169-77.
17. Spears RC. Colloid cyst headache. *Current pain and headache reports*. 2004; 8(4), 297-300.
18. Yadav Y, Yadav N, Parihar V. Management of colloid cyst of third ventricle. *Turk Neurosurg*. 2015; 25; 362-71.
19. Mathiesen T, Grane P, Lindquist C, von Holst H. High recurrence rate following aspiration of colloid cysts in the third ventricle. *Journal of neurosurgery*. 1993; 78(5), 748-52.
20. Pollock BE, Schreiner SA, Huston III J. A theory on the natural history of colloid cysts of the third ventricle. *Neurosurgery*. 2000; 46(5), 1077-83.
21. El Khoury C, Brugières P, Decq P, Cosson-Stanescu R, Combes C, Ricolfi F, et al. "Colloid cysts of the third ventricle: are MR imaging patterns predictive of difficulty with percutaneous treatment?". *American journal of neuroradiology*. 2000; 21(3), 489-92.
22. Wilson DA, Fusco DJ, Wait SD, Nakaji P. Endoscopic resection of colloid cysts: use of a dual-instrument technique and an anterolateral approach. *World neurosurgery*. 2013; 80(5), 576-83.