

**Skull Penetrating Stone due to falling from height: A Case Report****Ahmad Mokhtar Abodahab\* and Ebtsam Ahmed Mohammed Abdelbary**

Department of Diagnostic Radiology, Faculty of Medicine , Sohag University, Sohag, Egypt

**Abstract:**

**Background:** Falling from height is a common condition that can occur in different age groups. Many types of injuries can occur due to it, such as skull fractures. Skull penetrating foreign bodies (other than fire arm injuries and explosives) are generally uncommon. Penetrating blunt objects is rare. CT is a useful modality in diagnosis of head trauma in general and in diagnosis of penetrating foreign bodies especially. Unlike magnetic resonance imaging which is useful in special cases of head trauma with a penetrating foreign body.

**Case Report:** We present a case in which a child presented at Sohag University hospital with falling from a height less than 2 meters causing penetration of the frontal bone of the skull by a stone on the land, which is a very rare presentation. The patient presented with scalp bleeding, post-concussion and disturbed conscious level. Vital signs were normal. A Computed Tomography scan (Multislice CT – 8 slices) of the skull was done with 3D reformatted images.

**Conclusion:** Head trauma from penetrating objects (other than knife stapes or fire arm injuries) is uncommon. Blunt object penetration is very uncommon. It can be serious or even fatal. CT is the best imaging modality for diagnosis of such lesions. Metallic artifacts can be a limitation of their role. Although the finding is almost diagnostic, still the history and clinical finding is the key for diagnosis as the shape and density of the stone in some sections could be similar to ivory osteoma.

**Keywords:** Computed Tomography; Picture Archiving & Communication System (PACS); Three Dimensional (3D).

**DOI:** 10.21608/svuijm.2022.167431.1430

**\*Correspondence:** [Dr.ahmadabodahab@gmail.com](mailto:Dr.ahmadabodahab@gmail.com)

**Received:** 6 October,2022.

**Revised:** 1 November,2022.

**Accepted:** 3 November,2022.

**Cite this article as:** Ahmad Mokhtar Abodahab and Ebtsam Ahmed Mohammed Abdelbary. (2023). Skull Penetrating Stone due to falling from height: A Case Report. *SVU-International Journal of Medical Sciences*. Vol.6, Issue 1, pp: 397- 405.

**Copyright:** © Abodahab & Abdelbary (2023) Immediate open access to its content on the principle that making research freely available to the public supports a greater global exchange of knowledge. Users have the right to Read, download, copy, distribute, print or share link to the full texts under a [Creative Commons BY-NC-SA 4.0 International License](https://creativecommons.org/licenses/by-nc-sa/4.0/)

## Introduction

Falling from height is a common condition that can occur in different age groups. Many types of injuries can occur due to it, such as skull fractures. Early consequences such as contusion, hemorrhage, vascular injuries could be lethal while late consequences may also occur such as seizures and infections. Skull penetrating foreign bodies (other than fire arm injuries and explosives) are generally uncommon. Penetrating cerebral blunt injuries caused by objects of non-missile nature like stones are rare. (Concetta et al., 2010).

Intracerebral stones, not cause artifacts and may simulate bone on a CT scan, unlike the metallic objects which can cause artifacts on CT scan, it is difficult to differentiate between stone particles and bone particles in a depressed fracture (Naci et al., 2009). Pediatric traumatic brain injury may occur as a result of different mechanisms. Non-missile injuries such as stone injuries are caused by objects traveling at a slow speed. They represent a small percentage of overall head injury. Children are at a higher risk for penetrating injuries, because of their softer skulls. The most common presentation is the orbito-cranial presentation, the entrance site is the roof of the orbit due to its thin wall, and it usually involves the upper eyelid and its entrance to the cranium is through the orbital roof into the frontal lobe (Evangelos et al., 2018).

## Presentation of the case report

**Clinical history:** A 5-year-old male is presented to the emergency department of Sohag University hospital with a

head injury due to falling from a height. His father said that the boy fell from a height of less than 2 meters (Balcony of the first floor).

**Physical examination:** The child was presented with a stone that is penetrating the front of the skull above the left orbit. The patient presented with scalp bleeding, post-concussion and disturbed conscious level. Vital signs were normal. No other organs were traumatized.

**Imaging findings:** Routine radiological investigations for trauma such as abdominal ultrasound were free from any finding related to trauma. A CT scan (Multislice CT – 8 slices) of the skull was done. The scan of DICOM type is sent from a working CT workstation to a CD as the PACS at the time of the scan wasn't working. CT tomogram shows a well-defined rectangular shaped radiopaque lesion measuring 27 X 41 mm penetrating the frontal bone directly above the orbit (Fig. 1 & 2).

All dimensions of it were estimated in different directions (Fig. 3 & 4).

Only small foci of contusion are related to it on different cut sections of soft tissue window (Fig. 5) with minimal mass effect on ipsilateral ventricle and midline (Fig. 6).

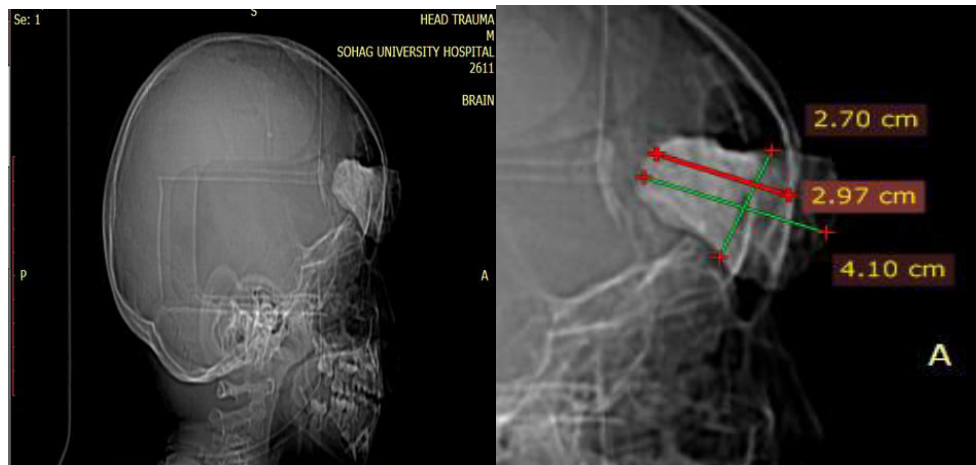
This foreign body object caused fracture of the left orbit upper wall with fracture and depression of its medial aspect and bowing of its lateral part (green stick like fracture) (Fig. 7 & 8) while other bones of the skull were intact (Fig. 9).

The object density measures more than 2000 Hu, denoting its rocky nature

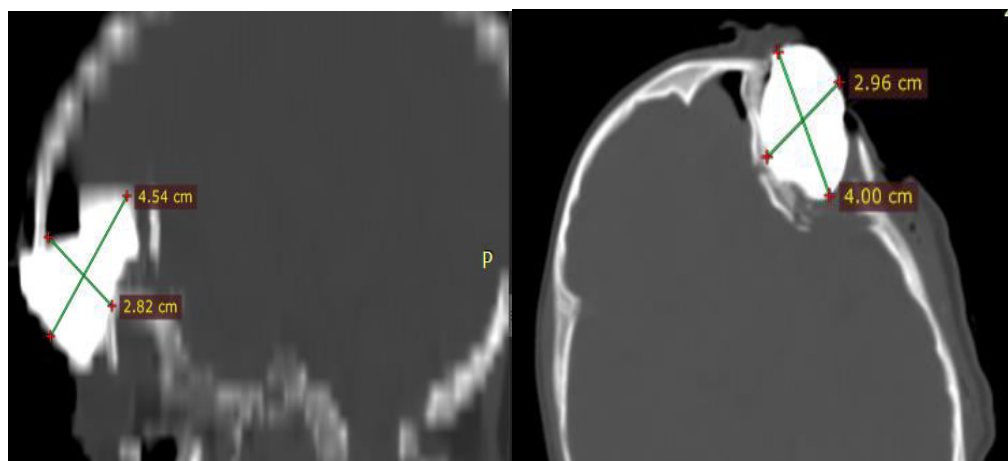
(Fig.10). 3D reformate images were done (Fig.11). The left eye globe was intact and was not affected by the trauma (Fig. 12& 13).

**Operative interference and surgical findings:** After a CT scan, the patient

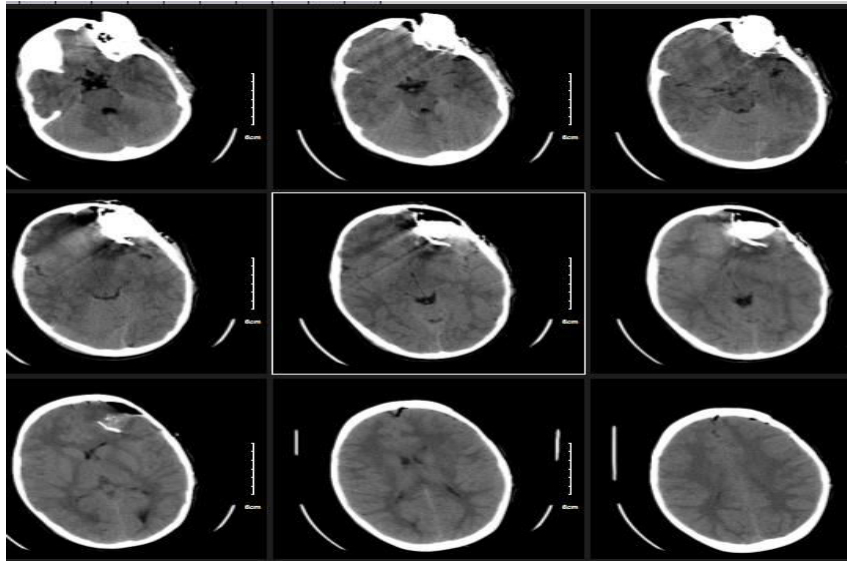
is referred directly to the neurosurgery department and surgery was done for extraction of the stone and treating a related fracture.



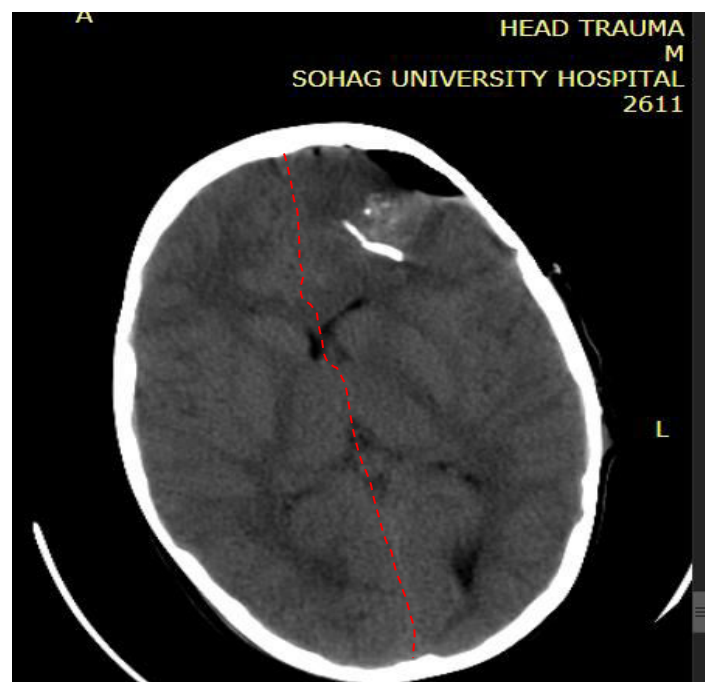
**Figure(1&2):** A 5-year-old male patient; CT showing a radio-opaque rectangular shaped foreign body penetrating the frontal part of the skull. It measures 27 X 41 mm (*Green Lines*) and penetrating depth of 29 mm from inner table of frontal bone (*Red Line*).



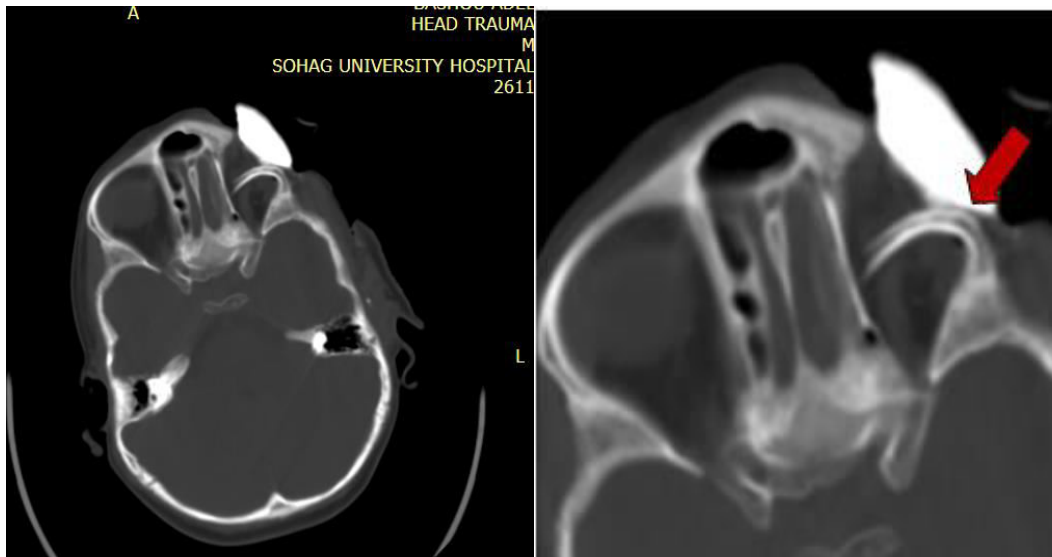
**Figure(3&4):** A 5-year-old male patient, Sagittal reformate & Axial CT scan of the brain, bone window, cut sections at the level of maximal dimensions of the penetrating stone, which measures ( 45 X 28 X 29 mm) .



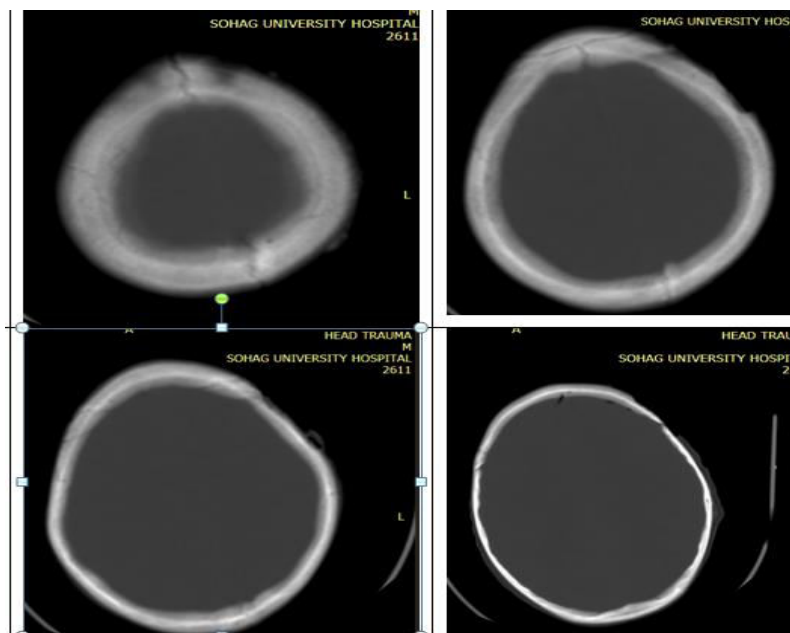
**Figure(5):** A 5-year-old male patient; Axial non enhancing CT scan of the head, brain window, different cut sections at and above the level of the penetrating stone. that causing minimal related artifact less than caused by a metallic object of the same size.



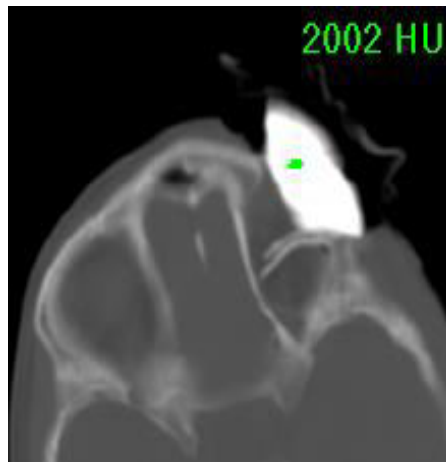
**Figure(6):** A 5-year-old male patient; Axial CT scan of the head, brain window, cut section above the level of the penetrating stone, showing related cerebral contusion and pneumocephally. The foreign body causing minimal mass effect on the anterior horns of lateral ventricles with med line shift.



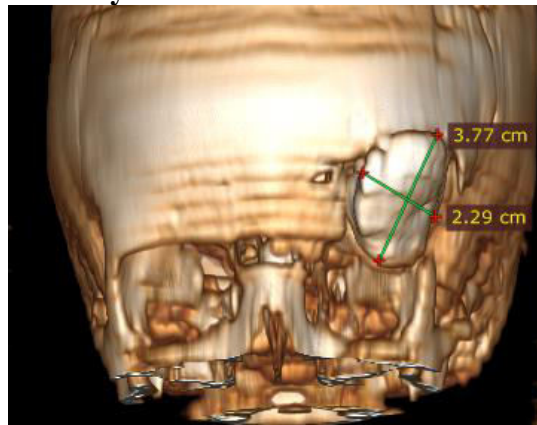
**Figure(7&8):** A 5-year-old male patient; Axial non enhancing CT scan of the head, bone window showing radio dense foreign body penetrating the left frontal bone just above the Lt orbit causing depressed bone fracture medially and bowing of the bone laterally (*Red Arrow*) due to young age nature of bone.



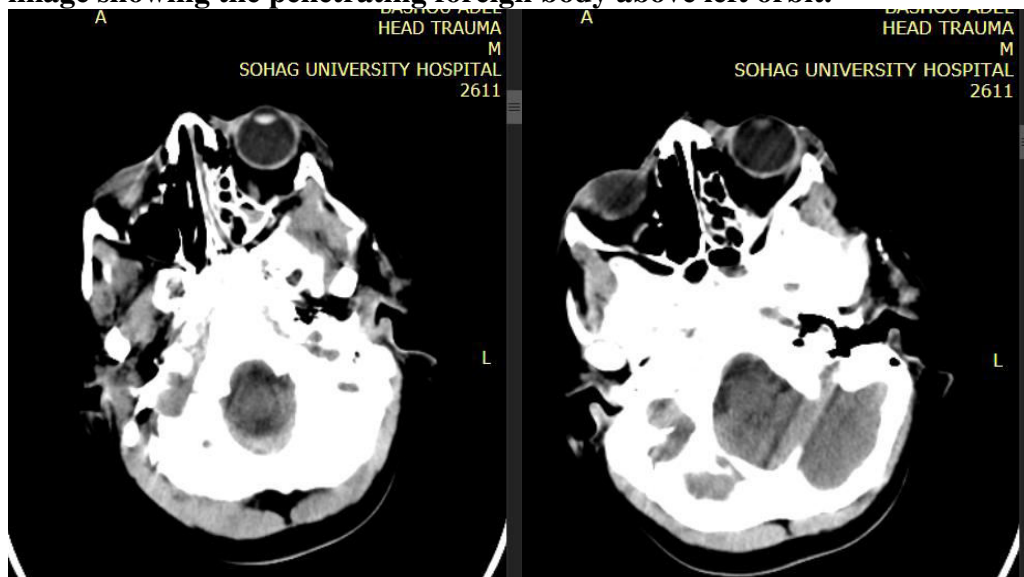
**Figure(9):** A 5-year-old male patient; Axial CT scan of the brain, bone window, cut sections above the level of the penetrating stone, confirming that the bones proximal are intact with no detectable fractures or any other abnormalities.



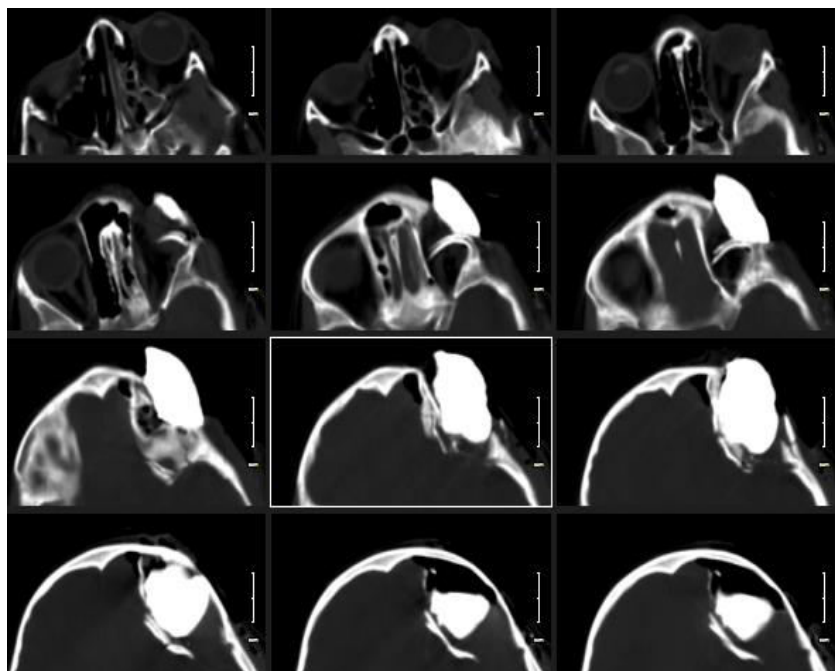
**Figure(10):** A 5-year-old male patient; Axial non enhancing CT scan of the brain, (bone window) showing radio dense foreign body density is more than 2000 HU, which is the density of metallic like structures.



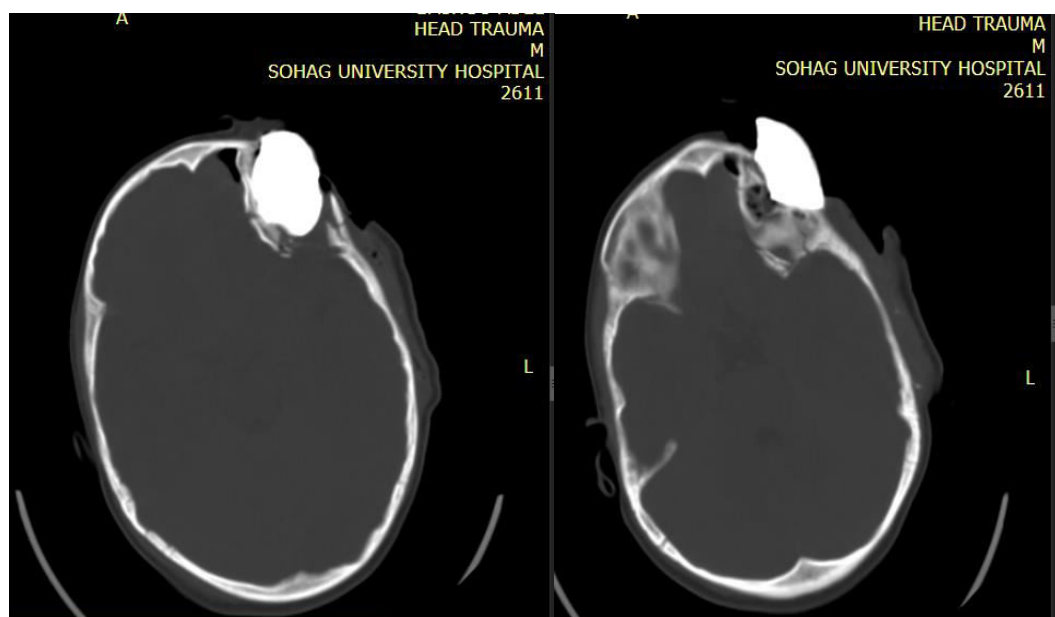
**Figure(11):** 5-year-old male patient; Axial CT scan of the brain, 3D reformate image showing the penetrating foreign body above left orbit.



**Figure(12&13):** A 5-year-old male patient; Axial CT scan of the brain, brain window, cut section below the level of the penetrating stone, confirming that eye globe is intact with eye lens seen in position. Notice that the patient is not well



**Figure(14): A 5-year-old male patient; Axial non enhancing CT scan of the head, bone window, different cut sections of the penetrating stone.**



**Figure(15&16): A 5-year-old male patient; Axial non enhancing CT scan of the brain, (bone window) showing that the radio dense foreign body in the cut sections not including other finding of trauma may be misdiagnosed as a an ivory osteoma.**

### Discussion

Penetrating orbito-cranial injury caused by a foreign body is uncommon and often causes serious damage. The clinical cause of penetrating injuries may be accompanied by

various pathologic conditions such as bone fractures, vascular lesions, or neurologic deficits. However, there can be doubt that penetrating wounds of the head and neck are potentially

more lethal than those affecting other parts of the body (Sang-Soak et al., 2009; Khadija et al., 2021).

Each imaging modality has strengths and limitations; CT is a useful modality in diagnosis of head trauma in general and in diagnosis of penetrating foreign bodies especially. Complications of penetrating an object may be infection, abscess formation, foreign body granuloma, neurovascular injury or object migration. The complications also may be related to the nature of the foreign body and possibility of contamination (Rond et al., 1992).

Foreign objects can penetrate the skin, the eye globe or enter the head and neck through the mouth, nose and external auditory meatus. It may reach into the orbits, paranasal sinuses or the deep spaces of the head and neck. A wide variety of incidents involving foreign bodies have been reported in the literature (Jan et al., 2021; Roodrajeetsing et al., 2016).

Traumatic cranio facial foreign bodies represent a rare entity threatening the ocular, cerebral and vasculo-nervous structures. The majority of these lesions seem to be caused by metallic objects such as needles, keys and hooks, or other sharp objects as pencils (Khadija et al., 2021).

**Differential Diagnosis:** Ivory osteoma is similar to the shape and density of the stone in some sections (Fig. 15&16).

**Abbreviations:**

**CT** Computed Tomography

**MRI** Magnetic Resonance Imaging

**PACS** Picture Archiving & Communication System

Here we presented a case in which a child presented at Sohag University hospital with falling from a height less than 2 meters causing penetration of the frontal bone of the skull by a stone on the land. The patient presented with scalp bleeding, post-concussion and disturbed conscious level. Vital signs were normal. CT scan (Multislice CT – 8 slices) of the skull was done with 3D reformatted images which showed a well-defined rectangular shaped radiopaque stone penetrating the frontal bone directly above the orbit causing fracture of the left orbit upper wall with fracture and depression of its medial aspect and bowing of its lateral part, other bones of the skull were intact. Only small foci of contusion were related to it on different cut sections of soft tissue window with minimal mass effect on ipsilateral ventricle and midline.

**Conclusion**

Head trauma from penetrating objects (other than knife stapes or fire arm injuries) is uncommon. Blunt object penetration is very uncommon. It can be serious or even fatal. CT is the best imaging modality for diagnosis of such lesions. Metallic artifacts can be a limitation of their role. Although the finding is almost diagnostic, still the history and clinical finding is the key for diagnosis as the shape and density of the stone in some sections could be similar to ivory osteoma.

**3D** Three Dimensional

**CD** Compact disc

**DICOM** Digital Imaging and Communications in Medicine



## References

- **Concetta A, Gerardo C, Mariella C, Alessandro AA, Daniele C, Francesco MS, and Francesco T (2010).** "Penetrating head injury by a stone: case report and review of the literature" *Clinical Neurology and Neurosurgery*; 112(9):813-6.
- **Evangelos D, Dimitrios G, Alexandros B, Andreas M, Georgios S, Marios T (2018).** "Pediatric Nonmissile Penetrating Head Injury: Case Series and Literature Review" *World Neurosurgery* 110: 193-205.
- **Jan OV, Christoph M, Jonas W, Benedicta BB, Tobias E, Jana V, Stefen D, Jan DR, Georg B and Nadine Th(2021).** "Imaging foreign bodies in head and neck trauma: a pictorial review " *Insights Imaging* 12:20.
- **Khadija S, Karim C, Hicham N, Youssef O, RedaArabi A, Mohamed M (2021).** "A rare case of a penetrating cranio-facial foreign body stuck in the skull base" *International Journal of Surgery Case Reports*. doi.org/10.1016/j.ijscr.2021.105721
- **Naci B, Belma A, Alpay S, and Ilhan E (2009).** "Intracranial Retained Stone After Depressed Skull Fracture. Problems in the Initial Diagnosis " *The American journal of forensic medicine and pathology*; 30: 198 –200.
- **Rond G, Lawrence MAL, and Charlesp K (1992).** "Foreignbodyofthe skullbase due to transorbital penetrating trauma " *Otolaryngology-Head and NeckSurgery* Volume 107 Number 6 Part 1.
- **Roodrajeetsing G, Wen SX, Jun Yand Dang ZW (2016).** "Intracranial foreign body through the sagittal sinus: case report and review of literature" *Chinese Neurosurgical Journal* 2:16.
- **Sang-Soak A, Young-Jin S, and Ki-Uk K (2009).** "Penetrating Orbitocranial Metallic Foreign Body Injury - A CaseReport" *Journal of Korean Neurotraumatology Society*;5:103-105.