

Comparative Study between Mohler (Modified Millard) and Fisher Techniques in Unilateral Cleft Lip Repair

Alaa M.A. Gaber^{a*}, Samia M.A. Said^b, Mohamed Yousef A. ^c, Ahmed A.A. Ali^a
^aPlastic Surgery Department, Faculty of Medicine, South Valley University, Qena, Egypt.

^bPlastic Surgery Department, Faculty of Medicine, Sohag University, Sohag, Egypt.

^cGeneral Surgery Department (Gastrointestinal Tract Surgery Branch), Faculty of Medicine, South Valley University, Qena, Egypt.

Abstract

Background: Cleft lip & palate are among most common congenital craniofacial malformations, with global incidence of 1/1000 live births. Goal of surgical repair is to enhance function & aesthetic presence of lip while providing appropriate anatomical reconstruction. Over time, numerous methods for cleft lip repair have been characterized. Ideal lip repair has symmetrical nasolabial folds & alae of nose on sides, natural-looking philtrum & Cupid's bow in both static & dynamic states, & hidden scar.

Objectives: The purpose of this study is to compare esthetic results between Mohler & Fisher technique in unilateral cleft lip healing.

Patients and methods: Prospective, randomized controlled research of 30 studied cases with unilateral cleft lip & palate was performed; divided into two groups (Mohler and Fisher groups), admitted to Plastic Surgery Department; Qena University Hospital from May 2021 to April 2022 (one year duration). Studied cases with microform cleft lip, syndromic cases, & non-compliant studied cases for photography and follow up were excluded. Anthropometric measurements were taken manually and valuation of quality of cleft lip repair was performed based on Steffensen's grading criteria.

Results: Anthropometric measurements were taken postoperatively from patients photos and compared with the preoperative measurements taken manually and these measurements were compared between the two groups. Lip height and vermilion height were higher in Fisher group likened to Mohler group; however, there is no significant lip width and alar base length. Outcomes between the two groups were compared according to Steffensen's criteria, it showed that good outcomes were more frequent in Fisher group compared to Mohler group but without statistically significant difference. Assessment of patient satisfaction was compared between the two groups; it was more excellent score in Fisher's group than in Mohler's group.

Conclusion: Fisher technique was more favorable than Mohler technique. This was revealed from our results according to Steffensen's grading criteria. Also, patient satisfaction from esthetic outcomes was more desirable in Fisher than Mohler repair for a long time follow up.

Keywords: Mohler; Fisher, Unilateral; Cleft lip.

DOI: 10.21608/svuijm.2022.157510.1387

***Correspondence:** am9841004@gmail.com.

Received: 23 August, 2022.

Revised: 8 September, 2022.

Accepted: 11 September, 2022.

Cite this article as: Alaa M.A. Gaber, Samia M.A. Said, Mohamed Yousef A. , Ahmed A.A. Ali. (2023). Comparative Study between Mohler (Modified Millard) and Fisher Techniques in Unilateral Cleft Lip Repair. *SVU-International Journal of Medical Sciences*. Vol.6, Issue 1, pp: 435- 449 .

Introduction

Cleft lip & palate are among most common congenital craniofacial malformations, with global incidence of 1/1000 live births (Roberts et al., 2020).

Goal of surgical repair is to enhance function & aesthetic presence of lip while providing appropriate anatomical reconstruction. Over time, numerous methods for cleft lip repair were characterized (Marcus et al., 2017).

Ideal lip repair has symmetrical nasolabial folds & alae of nose on both sides, natural-looking philtrum & Cupid's bow in both static & dynamic states, & hidden scar (Adetayo et al., 2019).

Millard developed rotational advancement method in 1964, which involves inserting lateral flap into upper part of lip & rotating medial part downward. Benefits of this method include reconstructing philtrum & Cupid's bow, transferring wound tension beneath base of ala, reducing nasal flare, & directing normal alveolar procedure progress (Millard 1986).

Mohler modified rotation advancement repair markings to produce scar that is more symmetric with non-cleft-side philtral column. Modification was accomplished by straightening rotation incision's curve & expands incision into columella (Mohler 1987).

Fisher launched anatomical subunit approximation method in 2005, which is derived from previously identified methods & adheres to concept of lip anatomical subunits, (Fisher 2005).

Fisher's method borrowed idea of using sloped incisions to lengthen lip from Rose-Thompson method, which permitted him to construct smaller triangular flap above cutaneous roll, since explained by Noordhoff, with incisions respecting lip's anatomical subunits (Noordhoff 1997).

The purpose of this study is to compare esthetic results between Mohler & Fisher technique in unilateral cleft lip repair

Patients and methods

Study design: Prospective , Randomized Controlled research was showed for studied cases presented with unilateral cleft lip with & without cleft palate (UCL/P) that admitted to Plastic Surgery Department; Qena University Hospital from May 2021 to April 2022 (one year duration).

Approval and consent: The research was approved by the Ethics Committee of faculty of medicine , SVU, Qena , Egypt for study in human researches , with **Ethical Approval Code : SVU-MED-PIS013-1-21-4-189**. Informed consent & written releases from parents for their children photos were signed.

Study Population (Eligibility criteria): *Inclusion criteria:* Unilateral cleft lip with & without cleft palate, non-syndromic cases, & studied cases with compliance for photography and follow up. *Exclusion criteria:* Microform cleft lip, syndromic cases, and non-compliant patients for photography & follow up.

Research group: total number of thirty studied cases was separated into 2 categories: group (A): fifteen studied cases with (UCL/P) that repaired with Mohler technique and group (B): 15 patients with (UCL/P) that repaired with Fisher technique.

Data Collection: Data collected in a clinical sheet for every patient that included the demographic and clinical data; **table (1)** .

Table 1. Demographic & clinical data of population research

Total number of patients	No. of Patients	Percentage
	30	100%
sex		
Men	(19)	63.3percent
women	nineteen	
	(11)	36.7percent
	elevan	
Age, months	3-7 months	
Mean (± SD)	16.57 (± 8.87)	
Median	5	
Cleft type		
Incomplete	18	60%
Complete	12	40%
Cleft side		
Right sided	17	56.7%
Left sided	13	43.3%
Associated cleft palate	14	47%
Associated cardiac anomalies	8	26.7%
Repair technique		
Fisher	15	50%
Mohler	15	50%

Methods of evaluation: Pre- & post-operative anthropometric measurements for both non-cleft & cleft sides included vertical lip height, horizontal lip width, vermillion height, & alar base length. Results of these measurements were compared among two categories. Steffensen's grading criteria were used to compare quality of cleft lip repair among two categories.

Time of operation :-For operative time , It took time about (60 -120) minutes, mean about 90 minutes for both techniques .It depends on severity of the cleft , pre- operative anthropometric measurements and markings.

Surgical technique:

Anesthesia: General anesthesia is used for all patients in supine position. Surgeon tapes straight, cuffed endotracheal tube to chin to prevent distortion of lower lip & modification of landmarks. Occlusive patches are applied to eyes, & throat pack is inserted.

Measurements and Marking: Anthropometric measurements were taken by graduated ruler or caliper preoperatively then landmarks are made with either gentian violet or a marking pen. Then, 1:200,000 epinephrine is injected in planned dissection planes of lip to maximize hemostasis and facilitate dissection.

For group (A): Mohler technique Fig. (1):

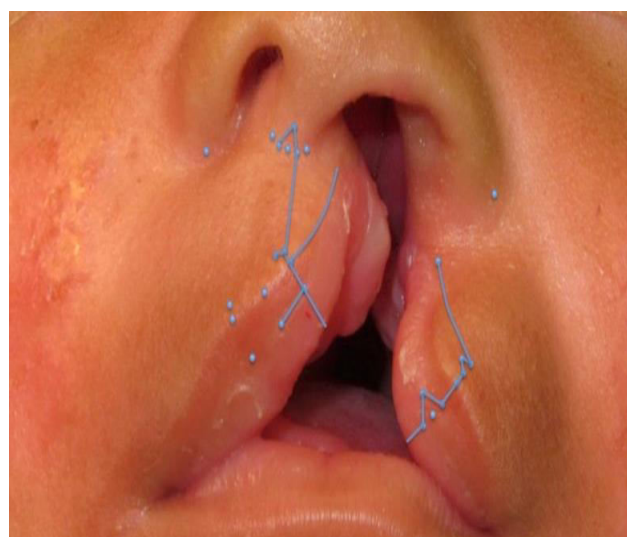


Fig.1. Markings of Mohler technique (Mohler, 2020).

Surgical markings for Mohler repair initially follow Millard's description of traditional white roll markings. Height & depth of Cupid's bow are characterized on unaffected side of medial lip element. These 2 points indicate height of Cupid's bow on cleft side, at which white roll usually disappears. Height of cutaneous upper lip on non-cleft side determines white roll mark in lateral lip element. Sign on white roll is determined by measuring distance from medial aspect of alar base on lateral lip. In contrast to

classic *Millard*, back-cut apex is characterized on columella two mm superior to base of columella above upper lip & 4/7th across columella toward non-cleft side. C-flap & M-flap have usual markings. Receiving incision for Noordhoff triangular vermilion flap is attracted like diagonal line on dry lip one mm inferior to white roll, toward red line, in vermilion of medial lip component. L- flap's is then delineated by making incision one mm inferior to white roll mark on lateral lip component. All incisions are created through skin & mucosa to full thickness.

For group (B): Fisher technique Fig. (2):

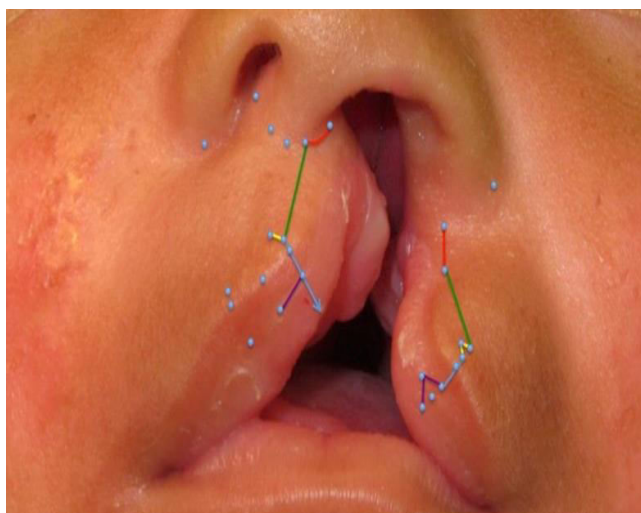


Fig.2. Markings of Fisher technique (Fisher, 2020).

Incisions are created perpendicular to white roll on peak of Cupid's bow at cleft side & base of philtral column at lateral lip. Incision is then enlarged superolaterally along labio-columellar crease to final closure point in nostril sill, which is symmetrical to non-cleft side philtral column.

Small triangle is located above level of white roll, to lengthen medial lip as described by *Rose-Thompson*. Noordhoff described triangular vermilion flap from lateral lip element to compensate for central vermilion deficiency. Nasal defects were repaired in both organizations by centralizing columellar base & septum,

releasing attachments of lower lateral cartilage from lateral piriform rim, repositioning symmetrical alar base at same level, & equalizing nostril circumference.

Postoperative care and follow-up:

Sutures were removed after 7 days, and all patients were followed up for period from six to twelve months (average = nine months).

Post - operative complications:

Post - operative complications are very common in cleft lip repair. In our study the complications observed post- operative were infection , poor healing ,verimilion notching ,hypertrophic scar and residual irregularities .

Complications , especially post- operative hypertrophic scars, veimillion notching and residual irrigeularities were more observed with modified Millard technique than Fisher approach

Table 2. Complications in our study

Complications	Cases	Percentage %
1-Infection	1 case	3 %
2- Vermillion notching	2 cases	6%
3 -Poor Healing	2 cases	6%
4-Hypertrophic scar	1 case	3%
5-Residual Irregularities	1 cases	3%

Statistical Analysis

Statistical Package for Social Sciences version twenty five was used to analyses data. Frequencies & relative percentages were used to represent qualitative data. To determine variation among qualitative variables, Chi square test & Fisher exact were used, as noted. For parametric data, quantitative information was

presented as mean ± SD & for non-parametric data as median & range. For parametric & non-parametric variables, independent Student-t test & Mann Whitney test were used to determine variation among quantitative variables in 2 categories. P-value of ≤ 0.05 shows that outcome is important.

Results

The research contained thirty studied cases with unilateral cleft lip with & without cleft palate. Fifteen studied cases underwent repair with *Mohler* (modified *Millard*) technique, group (A), and the other fifteen underwent repair with *Fisher* (anatomical subunit approximation) technique, group (B). Associated cleft palate were reported in 14 patients. Associated cardiac anomalies were present in 8 patients, **table (1)**.

There were 19 males (10 repaired by *Mohler* 'technique and 9 repaired by *Fisher* 'technique) and 11 females (5 repaired by *Mohler* 'technique and 6 repaired by *Fisher* 'technique). Age at time of cleft repair ranged from three-seven months with average 5 months, it presented that two categories were similar in years old and gender without important difference, **table (3)**.

Side of cleft was right sided in 17 patients (9 repaired by *Mohler* 'technique and 8 repaired by *Fisher* 'technique). Left sided cleft presented in 13 patients (6 repaired by *Mohler* 'technique and 7 repaired by *Fisher* 'technique).

Degree of cleft was complete in 12 studied cases (7 repaired by *Mohler* 'technique and 5 repaired by *Fisher* 'technique) and incomplete in eighteen studied cases (eight fixed by *Mohler* 'method and ten repaired by *Fisher* 'technique), it showed that the two groups were comparable in the side and extent of cleft without statistically significant difference, **table (3)**.

Table 3. Comparing between demographic & clinical characteristics of the two studied groups.

Variables		<i>Fisher</i> (n=15)	<i>Mohler</i> (n=15)	<i>t</i> / χ^2	<i>p</i>
<i>Age (months)</i> <i>Mean ± SD</i>		17.5 ± 9.42	15.64 ± 8.33	0.578	0.513
Sex	Male	9 (60%)	10 (66.7%)	0.144	0.705
	Female	6 (40%)	5 (33.3%)		
Side	Right	8 (53.3%)	9 (60%)	0.136	0.713
	Left	7 (46.7%)	6 (40%)		
Extent	Comple te	5 (33.3%)	7 (46.7%)	0.556	0.456
	Incompl ete	10 (66.7%)	8 (53.3%)		

It showed that 2 categories were similar in years old, gender, side, and extent of cleft without statistically significant difference.

Anthropometric measurements were taken postoperatively from patients' photos and compared with the preoperative measurements then comparison between the two groups were made, it showed that lip height and vermilion height were higher in *Fisher* category associated to *Mohler* category, though, there is no important variation in lip width and alar base length, **table (4)**.

Table 4. Comparing among the 2 studied categories according to anthropometric measurement

Variables	<i>Fisher</i> (n=15)	<i>Mohler</i> (n=15)	<i>Student-t test</i>	<i>P-value</i>
Lip height Mean ± SD	1.07 ± 0.127	0.974 ± 0.098	2.32	0.028
Lip width Mean ± SD	1.01 ± 0.085	1.05 ± 0.136	0.966	0.342
Vermilion height Mean ± SD	1.24 ± 0.135	1.07 ± 0.143	3.35	0.002
Alar base length Mean ± SD	1.04 ± 0.069	0.982 ± 0.118	1.64	0.112

It shows that lip height and vermilion height were higher in *Fisher* category compared to *Mohler* group, however, there is no significance in lip width and alar base length.

Outcomes between the two groups were compared according to *Steffensen's* criteria, It showed that good outcomes were more frequent in *Fisher* group compared to *Mohler* group but without statistically significant difference, **table (5)** and poor outcomes were less frequent in *Fisher* group compared *Mohler* group but without statistically significant difference, **table (6)**.

Table 5. Good outcomes according to *Steffensen's* grading criteria between the two groups.

Criteria	<i>Fisher</i> (n=15)		<i>Mohler</i> (n=15)		<i>Chi square</i> (χ^2)	<i>P-value</i>
	<i>N</i>	<i>%</i>	<i>N</i>	<i>%</i>		
Cutaneous roll symmetry	14	93.3	12	80	1.15	0.284
Vermilion symmetry	11	73.3	7	46.7	2.22	0.136
Scar appearance	14	93.3	10	66.7	3.3	0.068
Cupid's bow	12	80	8	53.3	2.4	0.121
Lip length	10	66.7	7	46.7	1.22	0.271
Nostril symmetry	9	60	7	46.7	.536	0.464
Alar dome	9	60	6	40	1.2	0.275
Alar base	8	53.3	5	33.3	1.22	0.271

It shows that good outcome more frequent in *Fisher* group compared to *Mohler* group but without statistically significant difference.

Table 6. Poor outcomes according to Steffensen's grading criteria between the two groups.

Criteria	Fisher (n=15)		Mohler (n=15)		Chi square (χ^2)	P-value
	N	%	N	%		
	Cutaneous roll symmetry	0	--	1		
Vermilion symmetry	1	6.7	3	20	1.15	0.284
Scar appearance	0	--	1	6.7	1.03	0.311
Cupid's bow	0	--	1	6.7	1.03	0.311
Lip length	1	6.7	3	20	1.15	0.284
Nostril symmetry	2	13.3	3	20	0.240	0.624
Alar dome	2	13.3	2	13.3	--	1
Alar base	3	20	4	26.7	0.186	0.666

It shows that poor outcome less frequent in *Fisher* group compared *Mohler* group but without statistically significant difference.

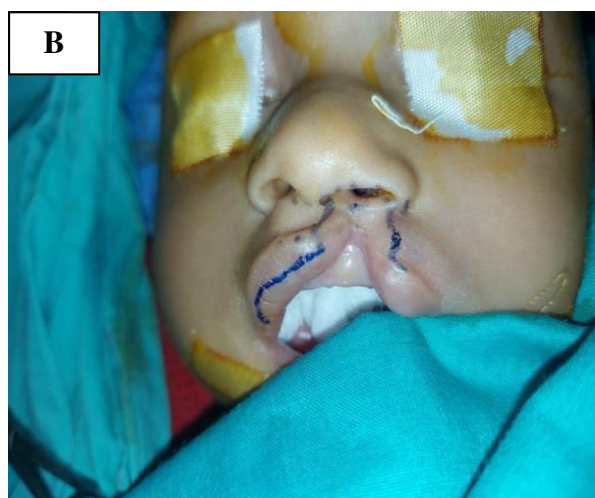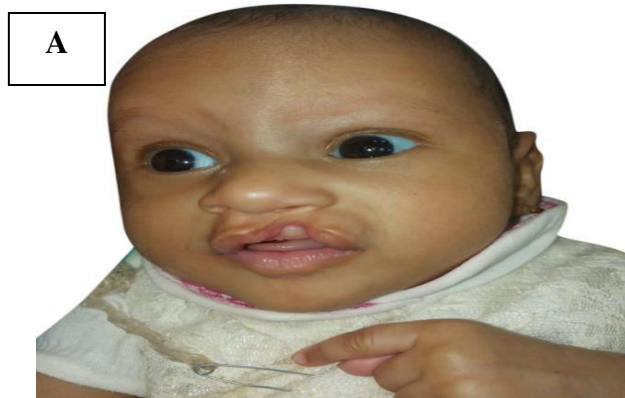Patient satisfaction (from their parents) was assessed and compared between the two groups, it was excellent in 13 patients in *Fisher's* category & 11 patients in *Mohler's* category, **table (7)**.

Table (7): Patient satisfaction between the two groups.

Grade	Fisher (n=15)		Mohler (n=15)		Chi square (χ^2)	P-value
	N	%	N	%		
Excellent	13	86.7%	11	73.3%	1.5	0.682
Good	1	6.7%	1	6.7%		
Fair	1	6.7%	2	13.3%		
Poor	0	--	1	6.7%		

It shows that excellent outcome is more frequent in *Fisher* group compared *Mohler* group but without statistically significant difference.

Clinical Cases



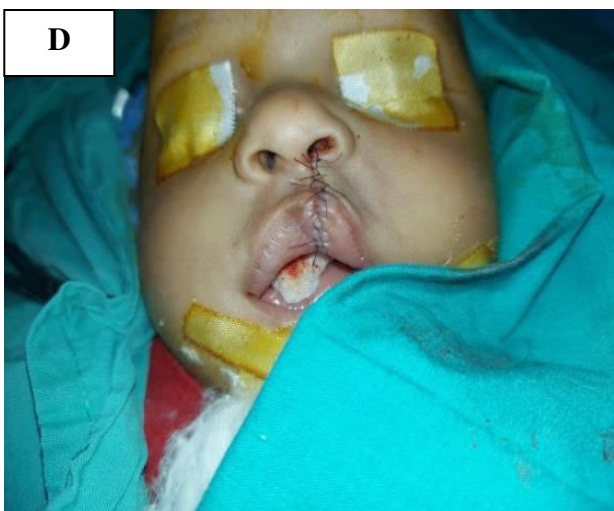
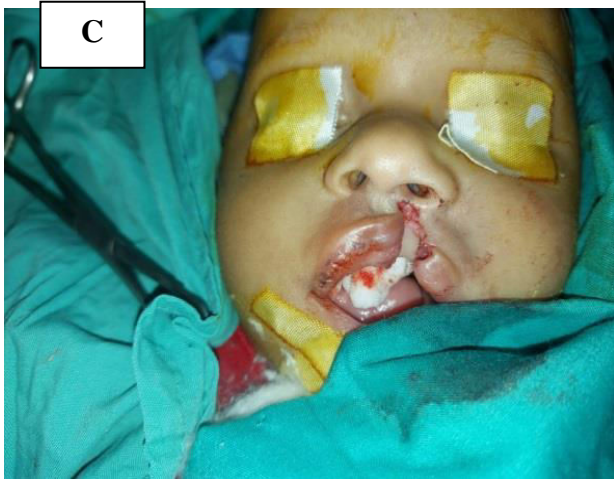
Fig.3
(A): Female , 4 months , presented with Lt incomplete cleft lip, repaired with Fisher technique.
(B): Markings of Fisher approach.
(C): Intraoperative dissection.
(D): Immediate post- operative repair.
(E):1 month post –operative follow up.
(F): Late post- operative follow up.

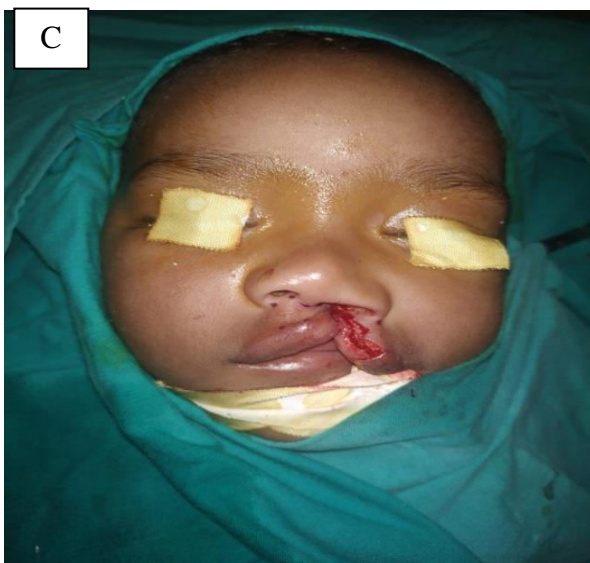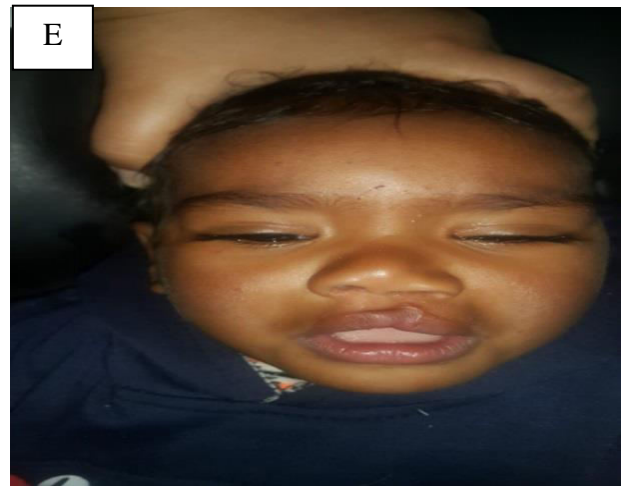

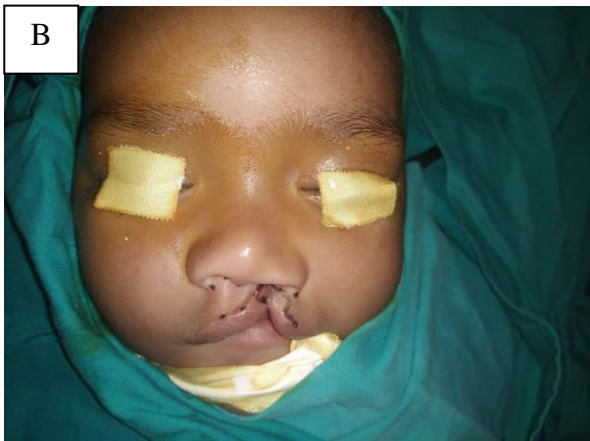
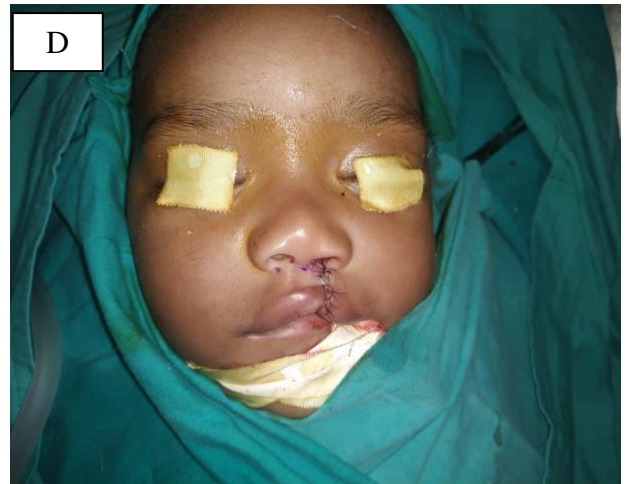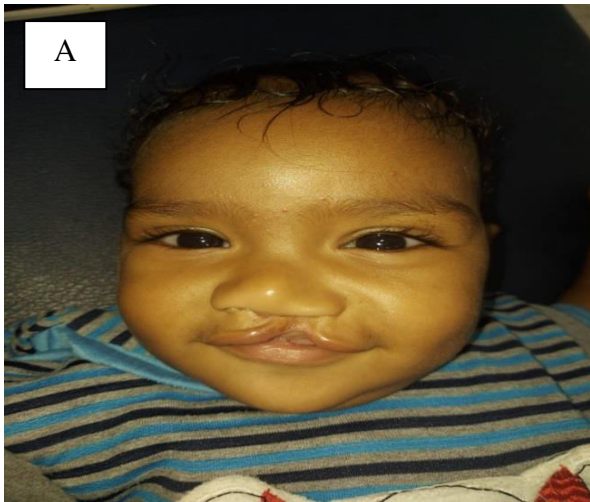Fig.4
(A): Male , 5 months , Left incomplete cleft lip, repaired with Fisher technique .
(B): Markings of Fisher technique.
(C): intraoperative dissection.
(D): Immediate post- operative repair.
(E): Late post- operative follow up.

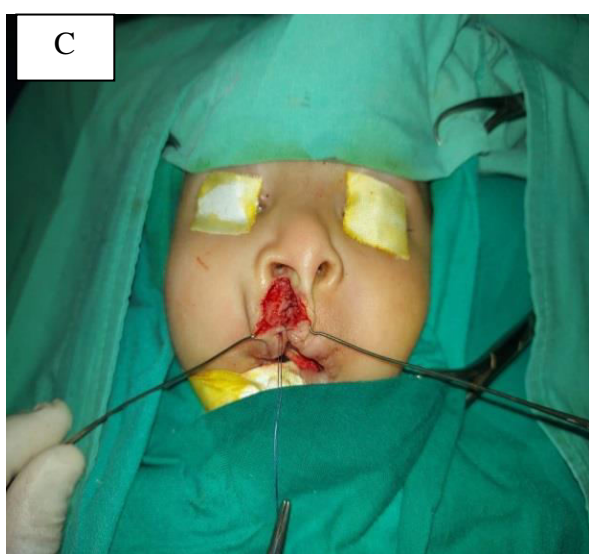
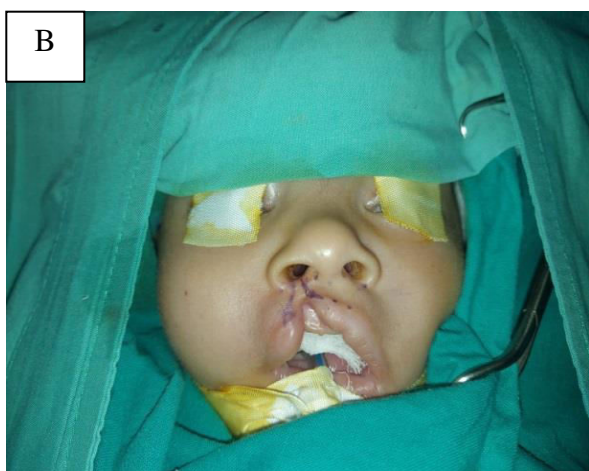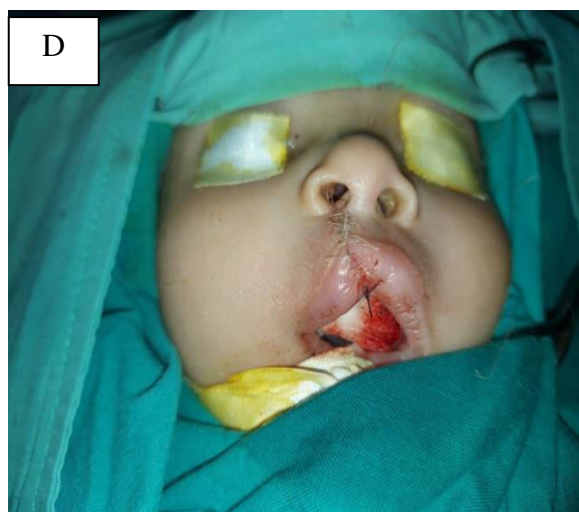

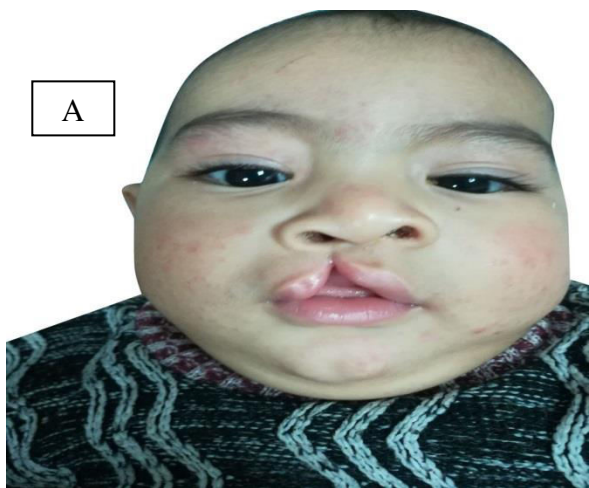
Fig.5

(A): Male , 6 months , with Right incomplete cleft lip , repaired by Mohler technique.

(B) Markings of Mohler technique.

(c): Intraoperative dissection showing orbicularis oris muscle.

(D): Immediate post- operative repair.

(E): Late post- operative follow up.

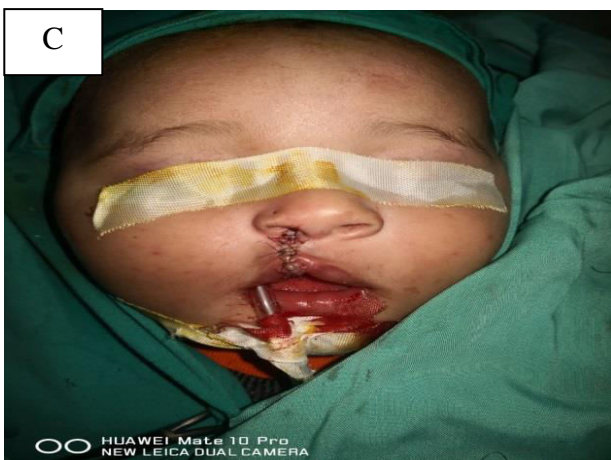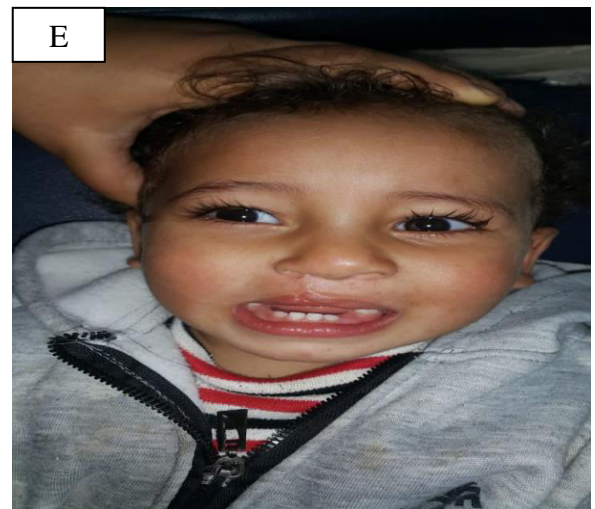

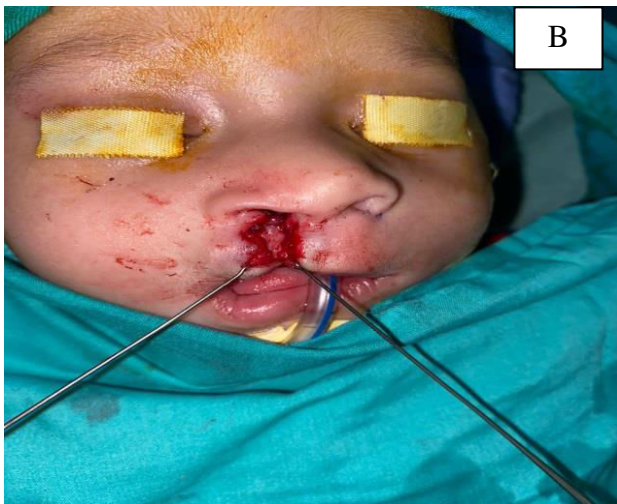
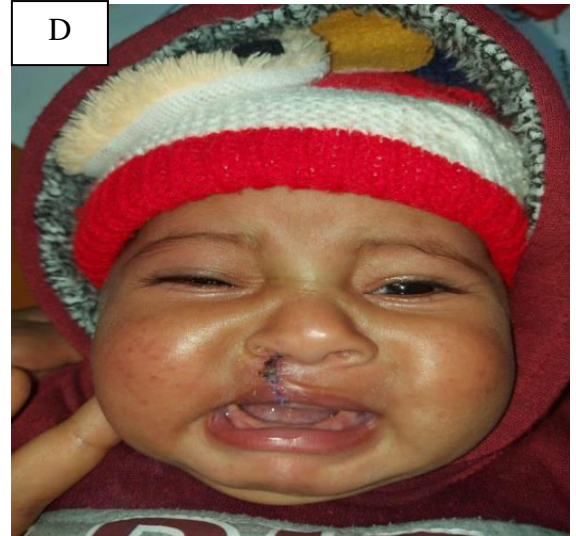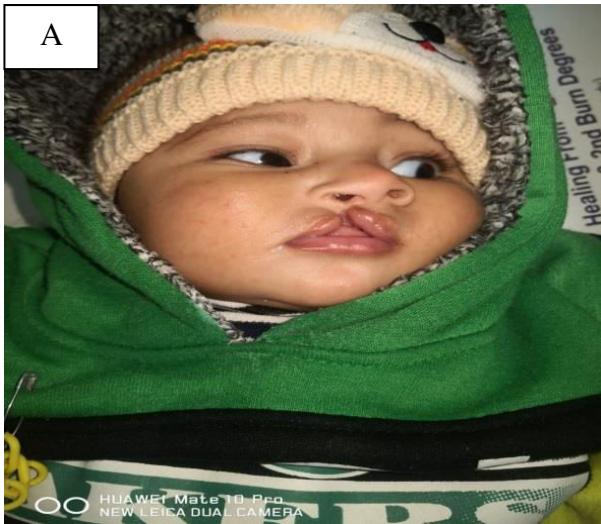Fig.6
(A):Male, 4 months , Right incomplete cleft lip, repaired with Mohler approach.
(B): Intraoperative dissection.
(C): Immediate post- operative repair.
(D):1 week post- operative follow up .
(E): Late post- operative follow up.

Discussion

Many methods were defined for repair of unilateral cleft lip. goal of repair is to restore functionally and esthetically normal lip with hidden scars and without distortion of anatomical landmarks. The evolution of techniques started from straight line repair then rotation advancement repair and lastly anatomical subunit approximation repair, (Vyas et al., 2014).

Regarding the demographic and clinical characteristics of 2 studied categories, our research presented that these groups were comparable in age, sex, side of the cleft, and extent of the cleft, without statistically significant difference. The anthropometric measurements between the two studied groups, showed that lip height and vermilion height were higher in Fisher category associated to Mohler category, but, there is no important variation in lip width and alar base length.

Comparing among 2 categories according to Steffensen's grading criteria presented that good outcomes were more frequent in Fisher group compared to Mohler group without statistically significant difference. While poor outcomes were less frequent in Fisher group compared to Mohler group without statistically significant difference. Assessment of patient satisfaction between the two groups, reported that excellent esthetic outcomes were more frequent in Fisher group compared to Mohler group but without statistically significant difference.

Similar results were obtained from a study by Mittermiller et al., The study enrolled 68 patients unilateral cleft lip repair. Thirty-three studied cases had modified rotation- advancement repair & thirty five had anatomic subunit repair. The study reported that there were no important variations among Fisher repair and Mohler

technique groups as regard age, sex, side, and extent of the cleft (Mittermiller et al., 2020).

Furthermore, Mittermiller et al., reported that 13 Lip revision was performed in twelve studied cases with rotation-advancement technique & 1 studied case with anatomical subunit repair . This distinction was statically important ($P < 0.001$), .

Mittermiller et al., researchers concluded that switching from rotation-advancement repair to anatomic subunit repair enhanced lip aesthetics while decreasing occurrence of scar contracture, hypertrophy, & widening, as illustrated by reduction in revision rate for these suboptimal scars. Even so, rate of red vermilion debulking processes increases early in adoption of anatomic subunit repair, necessitating minor changes in method, (Mittermiller et al., 2020).

Also, the study was supported by Patel et al. It included 22 cases, where 11 studied cases had modified rotation-advancement repair & 11 had anatomic subunit maintained. There were no important variations among both categories as regard years old, sex, and extent of the cleft. But the majority of the rotation-advancement group were left sided with significant difference between studied groups (Patel et al. ,2019).

According to Steffensen's grading criteria, Patel et al., reported that good outcomes were more frequent in Fisher group compared Mohler group but without statistically significant difference. While poor outcomes were less frequent in Fisher group compared Mohler group but without statistically significant difference. Based on quantitative outcomes, he noted that Fisher anatomical subunit method may produce more reliable results regardless of severity of cleft (Patel et al., 2019).

Moreover, study by Deshmukh et al that enrolled 50 studied cases with unilateral cleft lip with/without cleft palate. All studied cases were

then randomly assigned to one of two lip repair methods. Research found no important variations in years old, gender, side, & extent of cleft among Fisher approach & Mohler technique categories. Comparison of immediate postoperative aesthetic results revealed that Fisher repair improved postoperative aesthetic results (**Deshmukh et al., 2019**).

Kwong et al. in 2019 used eye-tracking technology to compare Fisher, Mohler, & Millard methods of unilateral cleft lip repair surgery & deduced that Fisher repair were best aesthetically, followed by Mohler technique, & finally Millard one. This finding supports our previous findings that Fisher method for cleft lip repair can produce superior aesthetic results (**Kwong et al., 2019**).

Suchyta et al., researchers compared postoperative results of Fisher, Millard, & Mohler cleft lip repair methods using online crowdsourcing platform Mechanical Turk. Research included 8 photographs of children who did not have unilateral cleft lips & 21 children who had Fisher, Millard, & Mohler repairs. Respondents were asked if they had scar, if they were personally comfortable with surgical outcome, & how they rated overall look, scar severity, & nasal symmetry on Likert scale of one to five (**Suchyta et al., 2020**).

Suchyta et al. reported that more patients in Fisher group were satisfied in comparison to both Mohler and Millard techniques. Average ratings of nose symmetry, general appearance, & satisfaction with surgical outcome did not differ statistically significantly among repair organizations. Outcomes show that Fisher repair produced most favorable aesthetic results when compared to Millard & Mohler methods, especially in terms of scar severity (**Suchyta et al., 2020**).

Furthermore, El-Maghraby et al., in unilateral cleft lip repair, Fisher anatomical subunit approximation method & Millard rotational advancement method were compared. Research included twenty studied cases who were repaired using each method. Both groups were comparable in terms of gender & years old. Lip height, vermilion height, & alar base length were significantly higher in Fisher category compared to Millard category, but there was no big variation in lip width (**ElMaghraby et a., 2021**).

Scar presence was good in ninety percent of cases in Fisher's group & sixty five percent in Millard's group, as per Steffensen's grading criteria in their research, while poor outcomes were less frequent in Fisher group compared Millard group. They concluded that Fisher's method exceeded Millard's method (**ElMaghraby et al., 2021**).

Conclusion

Fisher anatomical subunit method for unilateral cleft lip repair was more favorable and applicable than Mohler modified rotation advancement technique. This was revealed from our results according to Steffensen's grading criteria. Also, patient satisfaction from esthetic outcomes were more desirable in Fisher than Mohler repair for a long time follow up.

Recommendations

We suggest using Fisher anatomical subunit approximation method in unilateral cleft lip repair because it produces better scar outcomes than Mohler rotational progression method. However both methods demonstrated clinically acceptable post-operative aesthetics, Fisher's technique performed better overall than Mohler's repair.

Conflict of interest: None declared.

Source of funding: None.

References

- **Adetayo AM, Adetayo MO, Adeyemo WL, James OO, Adeyemi MO (2019).** Unilateral cleft lip: evaluation and comparison of treatment outcome with two surgical techniques based on qualitative (subject/guardian and professional) assessment. *J Korean Associated Oral Maxillofacial Surg*, 45(3):141-151,.
- **Deshmukh M, Vaidya S, Deshpande G, Galinde J, Natarajan S. (2019).** Comparative Evaluation of Esthetic Outcomes in Unilateral Cleft Lip Repair Between the Mohler and Fisher Repair Techniques: A Prospective, Randomized, Observer-Blind Study. *J Oral Maxillofacial Surg*, 77(1):182.e1-182.e8,.
- **ElMaghraby, M. F., Ghozlan, N. A., Ashry, M. H (2021).** Comparative study between Fisher anatomical subunit approximation technique and Millard rotation-advancement technique in unilateral cleft lip repair. *Alexandria Journal of Medicine*,57(1), 92-102,.
- **Fisher (2020).** Unilateral Cleft Lip Repair: Surgical Tutorial for Professionals , Children’s Hospital of Philadelphia.” : 8–10.
- **Fisher DM (2005).** Unilateral cleft lip repair: an anatomical subunit approximation technique. *Plastic Reconstructive Surgery*,116(1):61-71,.
- **Kwong JW, Cai LZ, Azad AD, Lorenz HP, Khosla RK, Lee GK, et al., (2019).** Assessing the Fisher, Mohler, and Millard Techniques of Cleft Lip Repair Surgery With Eye-Tracking Technology. *Ann Plastic Surg*, 82(5S Suppl. 4):S313-S319,.
- **Marcus JR, Allori AC, Santiago PE (2017).** Principles of Cleft Lip Repair: Conventions, Commonalities, and Controversies. *Plastic Reconstructive Surgery*,139(3):764e-780e,.
- **Millard DR Jr. Cleft Craft (1986)** .the evolution of its surgery. I. the unilateral deformity. Vol. 105. Boston: Little, Brown; p. 3,.
- **Mittermiller PA, Martin S, Johns DN, Perrault D, Jablonka EM, Khosla RK (2020).** Improvements in Cleft Lip Aesthetics with the Fisher Repair Compared to the Mohler Repair. *Plastic Reconstructive Surgery Glob Open*. Jun 23;8(6):e2919,.
- **Mohler (2020).** Unilateral Cleft Lip Repair: Surgical Tutorial for Professionals.:6–10.
- **Mohler LR (1987).** Unilateral cleft lip repair. *Plastic Reconstructive Surg*, 80(4):511-7,.
- **Noordhoff MS (1997).**The surgical technique for the unilateral cleft lip-nasal deformity: Noordhoff Craniofacial Foundation.
- **Patel TA and Patel KG, (2019).** Comparison of the Fisher Anatomical Subunit and Modified Millard Rotation-Advancement Cleft Lip Repairs. *Plastic Reconstructive Surgery*, 144(2):238e-245e,.
- **Roberts JM, Jacobs A, Morrow B, Hauck R, Samson TD (2020).** Current

Trends in Unilateral Cleft Lip Care: A 10-Year Update on Practice Patterns. *Ann Plastic Surgery*, 84(5):595-601,.

- **Suchyta M, Azad A, Patel AA, Khosla RK, Lorenz HP, Nazerali RS (2020).** Applied Online Crowdsourcing in Plastic and Reconstructive Surgery: A Comparison of Aesthetic Outcomes in Unilateral Cleft Lip Repair Techniques. *Ann Plastic Surgery*,84(5S Suppl. 4):S307-S310,.
- **Vyas RM and Warren SM (2014).** Unilateral cleft lip repair. *Clinical Plastic Surg*,41(2):165-77,.