

Diagnostic Performance of an Abbreviated Screening Protocol for Osteomyelitis and Soft Tissue Infection of the Foot: A Cross Sectional Analytic Study

MENNATALLAH ELSAYED (ME), M.D.*; NEVEIN E.M. EL-LEITHY (NE), M.D.*;
AHMED M. MUSTAFA BALBOULA (AB), M.D.**;
MOSTAFA M. IBRAHIM ABDEL-HAMID (MM), M.Sc.* and SALLY Y. SHOKRALLA (SS), M.D.*

The Departments of Diagnostic & Interventional Radiology and General Surgery**, Faculty of Medicine, Kasr Al-Ainy, Cairo University*

Abstract

Background: Treatment of a foot infection can vary significantly depending on the presence of osteomyelitis or an abscess. Rapid and efficient evaluation of patients with diabetic foot ulcer is of great importance. While MRI is known to be the imaging modality of choice in these cases, it is also known to be a costly and lengthy exam.

Aim of Study: The aim of our study is to compare the diagnostic performance of a rapid protocol to a full protocol in the evaluation of presence osteomyelitis and abscesses of the foot and to detect patients that profit on performing a standard protocol.

Patients and Methods: This cross sectional analytic study involved 41 patients with diabetic foot ulcer (29 male, 12 female with age range from 41 to 77 years with mean \pm SD = 57.29 \pm 10.7). Clinical reports of the full protocol were used as gold standard, combined with clinical data. Information regarding the utilization of intravenous contrast, the existence of osteomyelitis, reactive osteitis, and abscesses of soft tissues were extracted from clinical reports. By the utilization of one T1 non fat-saturated and one STIR sequences, two radiologists with experience evaluated all patients for the existence of osteomyelitis, reactive osteitis, or a soft tissue abscess. Inter-rater agreement was calculated, also sensitivity, specificity and accuracy of both radiologists were tested.

Results: There was an almost perfect inter-observer agreement for diagnosis of osteomyelitis with a kappa value of 0.951. A moderate inter-rater agreement was noted for the presence of soft tissue abscesses. Both observers showed a high sensitivity for the diagnosis of osteomyelitis (100% and 95.2% for observer 1 and 2 respectively). They both were less sensitive for diagnosing soft tissue infection (sensitivity of 80% for both observers).

Conclusions: This rapid two sequenced protocol has a high reliability and significant diagnostic performance in

Correspondence to: Dr. Mennatallah Elsayed (ME),
[E-Mail: Mennaelsayed22@yahoo.com](mailto:Mennaelsayed22@yahoo.com)

detection of osteomyelitis, and its high sensitivity, specificity and accuracy make it beneficial in screening for cases that can profit after a full standard protocol.

Key Words: Osteomyelitis – Abscess – Foot – Evaluation.

Introduction

DIABETIC foot ulcer is amid the most common complications in uncontrolled diabetic patients. It is also a common cause for foot osteomyelitis and lower limb amputation [1,2]. There is a high pooled prevalence of diabetic foot ulceration in the whole world in general and in Africa specifically [3,4]. Recent data suggest that there is an increase in lifetime risk of foot ulcers in diabetic patients [5].

A rapid identification of foot ulcers, soft tissue infection, and osteomyelitis and a precise evaluation of the extent of this infectious process is of great importance for proper management of the patients and for choosing the most appropriate therapy [6,7].

Osteomyelitis is one of the most grave complications of diabetes, being associated with sustained antibiotic therapy, long term hospitalization, as well as being associated with higher rates of re-infection and amputations compared with patients with soft tissue infection [8]. Even though bone biopsy is the gold standard for a definite diagnosis of osteomyelitis, it has a major drawback being an invasive procedure, and not always practical [9].

List of Abbreviations:

MRI : Magnetic resonance imaging.
K : Kappa.
CI : Confidence interval.
OM : Osteomyelitis.

Radiology offers the opportunity to diagnose diabetic foot infection by using a less invasive procedure that when combined with physical, laboratory, and microbiological examinations. Radiography is the first line imaging modality in evaluating a diabetic foot, with MRI being the following step and modality of choice in the diagnostic process of osteomyelitis and associated soft-tissue complications with a high sensitivity and specificity in diagnosing osteomyelitis [10,11].

MRI represents a diagnostic procedure with limited access and high cost, especially when needed in the emergency cases [12]. Moreover, MRI studies in the setting of a diabetic foot require immediate and fast interpretation by radiologists. These limitations may be reduced for patients with suspected foot osteomyelitis if an abbreviated rapid imaging protocol decreased the exam duration while preserving a diagnostic performance [13].

Recent studies have evaluated the diagnostic performance of a two sequence protocol, with different planes of imaging, compared with a flexible full protocol in evaluation of patients with diabetic foot ulcers and demonstrated a high diagnostic accuracy [13,14].

Aim of Study:

The aim of our study is to assess if an abbreviated protocol consisting of two sequences only with no contrast enhancement, can be used as a screening tool for osteomyelitis and soft tissue abscesses in diabetic foot ulcer patients, and to make a comparison between this rapid protocol's performance and a variable full protocol irrespective of the use of contrast intravenously.

Patients and Methods

Ethics committee approval was obtained for this cross sectional analytic study. Informed consent was also obtained from all patients.

We evaluated 41 feet of 41 patients (29 male, 12 female with age range from 41 to 77 years with mean \pm SD = 57.29 \pm 10.7). The demographic data of the patients, namely the age and sex in the study population were shown in Table (1). The mean duration of diabetes in our patients was 9.8 \pm 7.2 years. The mean duration of foot ulcers was 3.2 \pm 1.6 weeks. Diabetic neuropathy was recorded in 94% of our patients, diabetic nephropathy and retinopathy were recorded in 27% and 16.2% of our patients respectively. Amongst our patients, 72% were hypertensive and 13.1% had a previous cardiovascular insult. The patients were referred from Vascular Surgery Department of Kasr Al-Ainy

Hospital, Cairo University between September 2021 to February 2022. All patients were subjected to history taking, clinical provisional examination and MRI examination of the affected foot.

Table (1): Demographic characteristics among the study population.

	Study population (n = 41)	
Sex:		
- Male:		
n (%):	29	71%
- Female		
n (%)	12	29%
Age (years):		
Mean \pm SD.	57.29 \pm 10.7	
Median (IQR)	57 (52-61)	
Range (Min-Max)	36 (41-77)	

N : Number.

IQR: Interquartile range.

Inclusion criteria:

All the involved patients had diabetic foot ulcer with a clinical suspicion of osteomyelitis based on one or more of these criteria: Positive probe-to-bone test, high inflammatory biomarkers, a persistent non-healing ulcer, drained synovial fluid and the location of the ulcer over a bony prominence.

Exclusion criteria:

The following exclusion criteria were applied: Patients in whom MRI is contraindicated like pacemakers and implants, patients with claustrophobia to MRI, patients with orthopnea who can't tolerate supine position in MRI.

MR image protocol:

MR examinations were performed for all patients using closed field 1.5 tesla MRI machine "ACHIEVA" equipment (from PHILIPS Medical Systems, Best, the Netherlands) using a phased array extremity coil to evaluate for a diagnosis of osteomyelitis. The patients were examined in a supine position with the feet located at the side of the magnet in the foot coil with the foot being flexed. The acquired imaging parameters were summarized in Table (2). Preliminary scout localizers in axial, coronal and sagittal planes were done. The coverage included all the examined foot from medial to lateral and from anterior to posterior. Care was taken to confirm a homogeneous STIR images fat suppression evaluated in these examinations.

Table (2): Full standard MRI protocol parameters.

	TR	TE	FOV	Matrix
<i>Standard:</i>				
Coronal T1 non FS	516	9	180-200	320X320
Coronal T2	3928	83	180-200	320X320
Coronal STIR	5377	50	180-200	320X320
Sagittal T2	4087	116	180-200	320X320
Axial T1 FS without Contrast	420	10	120-140	256X256
Axial T1 FS with Contrast	420	10	120-140	256X256

MR image analysis:

The following items were evaluated by a radiologist in the clinical reports by the use of a full magnetic resonance imaging protocol: The usage of intravenous contrast, the presence of osteomyelitis and/or reactive osteitis and the presence of abscess of soft tissues. The radiologist who verified the full protocol clinical report was a certified musculoskeletal radiologist with experience of more than 20 years. Clinical reports were used as a gold standard for diagnosis combined with all available clinical data [15]. Two musculoskeletal radiologists (of more than 10 years of experience) blinded to each other results, blinded to radiographs and previous imaging were requested to individually evaluate every case and interpret the T1 non-fat saturated sequence and the STIR sequence, regardless of the plane acquired with a preference to coronal sequences. Both radiologists were requested to assess for the diagnosis of osteomyelitis (osseous focal reduced T1 signal and equivalent fluid signal on STIR WIS with adjacent edema of soft tissue), reactive osteitis (normal osseous T1 signal and osseous high focal STIR signal with adjacent edema of soft tissue), or soft tissue abscess. Though it was not the primary goal of this study, the two radiologists were also requested to describe other alternate diagnoses (pathology not representing an infection) which may produce signs similar to that of infection or make the diagnosis more confusing. Those confusing diagnoses described in the clinical full report were additionally dictated. Statistical analysis of these findings was done.

Statistical analysis:

All data were collected, tabulated and statistically analyzed using SPSS 26.0 for windows (SPSS Inc., Chicago, IL, USA). Qualitative data were described using number and percent. Quantitative data were described using range (minimum and maximum), mean, standard deviation and median. The used test was Cohen's kappa coefficient (κ): is a statistic that is used to measure inter-rater

reliability between the two observers and the clinical report. Agreement was classified as: None (0-0.20), minimal (0.21-0.39), weak (0.40-0.59), moderate (0.60-0.79), strong (0.80-0.90) and almost perfect (above 0.90). The used diagnostic test parameters were: Sensitivity (True Positive Rate), Specificity (True Negative Rate), Positive predictive value (PPV), Negative predictive value (NPV) and accuracy.

Reference standard for diagnosis:

The presence of osteomyelitis was established using all available clinical information including the full protocol clinical reports.

Results

Generalized results by the full protocol:

Osteomyelitis was detected in 21 cases of the examined 41 foot exams. Amongst the 21 exams diagnosed with osteomyelitis, 35 bones were affected. Sixteen of the bones affected with infection existed in toes, 14 were noted in metatarsal bones, 2 existed in the mid-foot, and 3 existed in the hind-foot.

Osteomyelitis results:

The agreement among both observers on the presence of osteomyelitis was almost perfect (Table 3), with a Kappa value of 0.951 (95% CI of 0.857-1.0). The two observers revealed high accuracy (100% and 97.6% for observer 1 and 2 respectively) in diagnosing osteomyelitis (Table 4). Osteomyelitis was correctly identified by observer 1 using the screening protocol in all 41 cases (Fig. 1). On the other hand, observer 2 identified 39 cases with osteomyelitis and disagreed with the full standard protocol and clinical report in 2 cases, calling them reactive osteitis (Fig. 2).

Table (3): Inter-observer agreement for diagnosis of osteomyelitis and abscess formation.

	Kappa	95% CI	Degree of agreement between the 2 observers
Osteomyelitis	0.951	0.857-1.0	Almost Perfect
Abscess	0.773	0.475-1.0	Moderate

CI: Confidence interval.

Table (4): Sensitivity, Specificity, Positive, Negative Predictive Values and accuracy of both observers for diagnosing osteomyelitis.

	Sensitivity	Specificity	PPV	NPV	Accuracy
Observer 1	100.0%	100.0%	100.0%	100.0%	100.0%
Observer 2	95.2%	100.0%	100.0%	95.2%	97.6%

PPV: Positive predictive value.

NPV: Negative predictive value.

Abscess results:

Agreement between both observers on the presence of an abscess was moderate (Table 3), with a Kappa value of 0.773 (95% CI of 0.457-1.0). Observer 1 and 2 had a reduced sensitivity for soft tissue abscess identification being 80% for both observers (Table 5).

Other alternate diagnoses:

Amongst the 41 cases, 4 cases had an established diagnosis of inflammatory arthritis on the full protocol clinical report. 1/4 cases had an established diagnosis of inflammatory arthritis with the rapid protocol by both observers. Seventeen out of forty one cases had an established diagnosis with of a charcotjoint. Amongst those 17, the

screening protocol diagnosed a charcotjoint in 15/17 for both observers. There were 2 cases of fractures not related to infection mentioned in the clinical report of the standard full protocol, both cases were also diagnosed on the screening protocol also by both observers.

Table (5): Sensitivity, Specificity, Positive, Negative Predictive Values and accuracy of both observers for diagnosing an abscess.

	Sensi- tivity	Speci- ficity	PPV	NPV	Accuracy
Observer 1	80.0%	94.4%	66.7%	97.1%	92.7%
Observer 2	80.0%	100.0%	100.0%	97.3%	97.6%

PPV: Positive predictive value.
NPV: Negative predictive value.

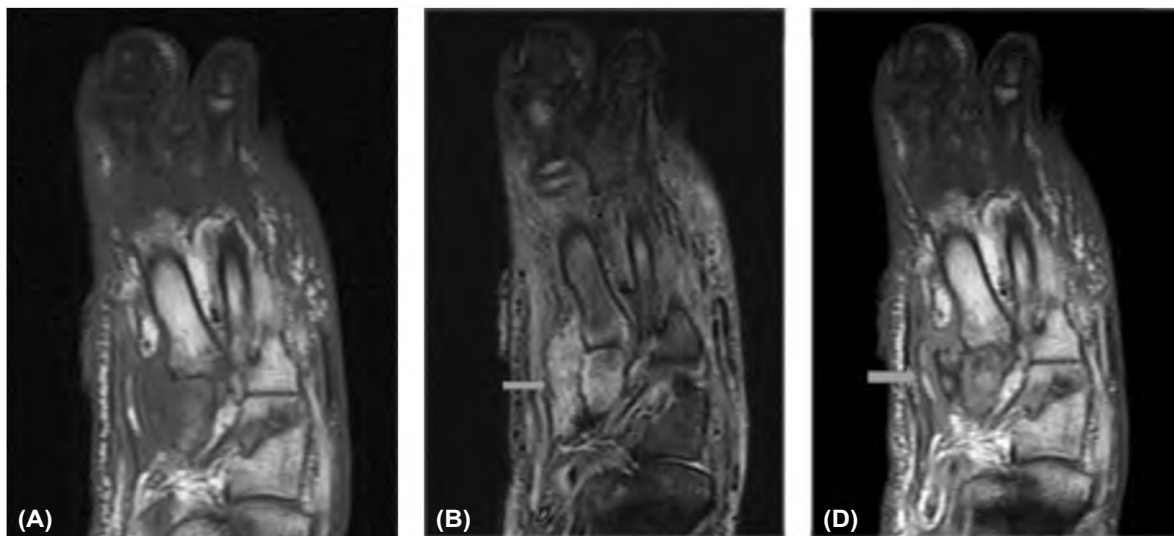


Fig. (1): A 53-year-old female with diabetes and a non healing draining foot ulcer. The medial aspect of the mid-foot was swollen. There was agreement considering the presence of osteomyelitis and a soft tissue abscess between observers 1 and 2 using the rapid protocol and the clinical report for a full, contrast-enhanced protocol. (A) Coronal T1 pre-contrast non-fat saturated image shows confluent low T1 signal through the medial cuneiform and base of first metatarsal bone. (B) Coronal STIR shows high signal through the medial cuneiform with adjacent soft tissue collection. These findings meet classical MRI criteria for osteomyelitis and soft tissue abscess and the diagnosis could be reached using these two pulse sequences alone. Abscess presence was confirmed at surgery. (C) Coronal contrast-enhanced T1 non fat-saturated image shows the rim-enhancing fluid collection as seen on b (thick arrows).

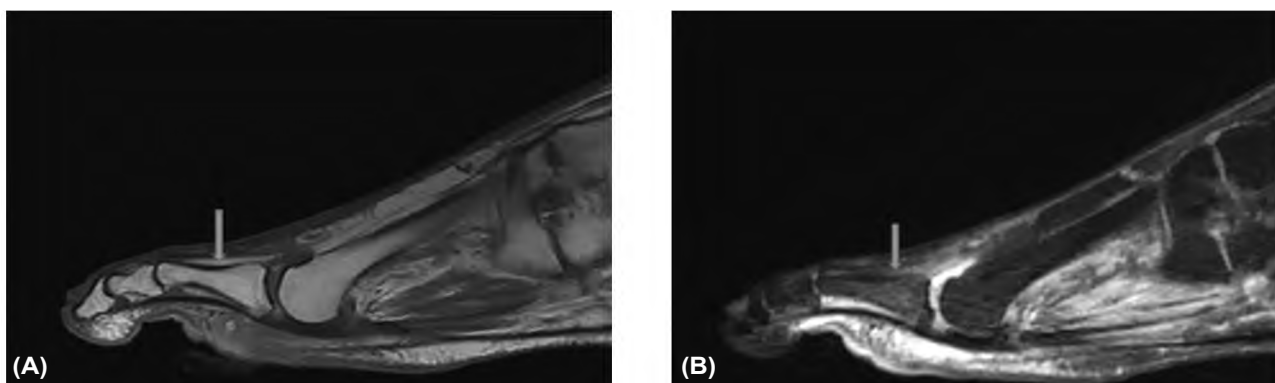


Fig. (2): A 60-year-old male presenting with a non healing diabetic forefoot ulcer. In this case, using the rapid screen, the observers felt this signifies reactive osteitis while the clinical report described it as an osteomyelitis. (A) Sagittal T1 pre-contrast non-fat saturated image shows a cutaneous ulcer underneath the proximal phalanx of 2nd toe, with lacking of extensive focal low T1 signal (thick arrow). (B) Sagittal STIR shows a cutaneous ulcer beneath the proximal phalanx of same 2nd toe with soft tissue edema extending to bone and focal, faint bone marrow edema-like signal in the subjacent proximal phalanx (thick arrow).

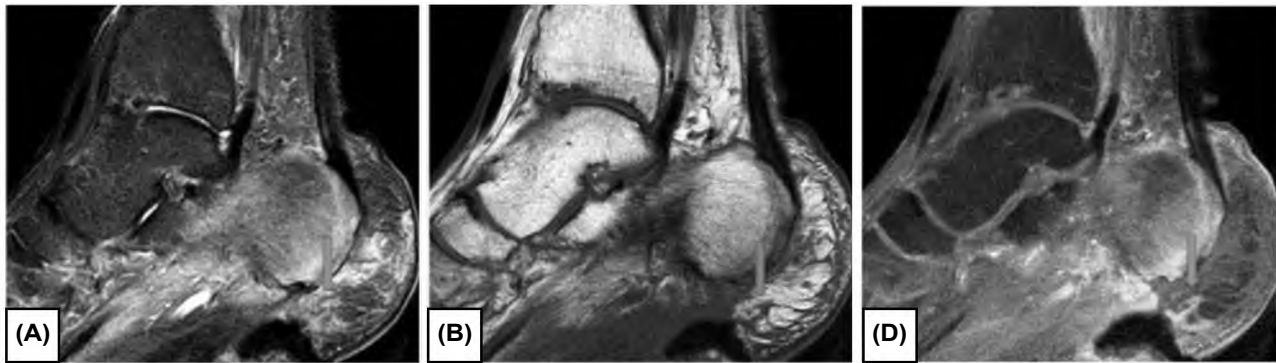


Fig. (3): A 50-year-old male presenting with a non-healing diabetic heel ulcer. In this case, using the rapid screen, both observers did not recognize an abscess. However, with the use of post-contrast imaging, the clinical report made the diagnosis of an abscess. The patient was treated with intravenous antibiotics. Twelve months later, the latest clinical report indicated that this abnormality has resolved without the need for surgical intervention. (A) and (B) Sagittal STIR and T1 non fat saturated WIs demonstrate non-confluent soft tissue edema and no definite fluid collection (thick arrows). (C) Sagittal T1 weighted post-contrast fat saturated image shows a patchy area of central non enhancement in the soft tissues underlying the deep heel ulcer (thick arrow).

Discussion

In cases where osteomyelitis is clinically suggested, fast and precise diagnosis is mandatory to avoid chronic infection and complications caused by destruction or necrosis of bones. The gold reference for diagnosis is bony biopsy with histopathology, culture and sensitivity, which may not be achievable or possible in all patients. In clinical routine, the diagnosis is classically based on both clinical and imaging data [6]. Magnetic resonance imaging is the imaging modality of choice in the diagnosis of osteomyelitis with a high sensitivity and specificity [15,16]. While magnetic resonance imaging is commonly used in the evaluation of diabetic foot ulcers, there is no agreement on what represents an ideal protocol. Magnetic resonance imaging efficacy is of high value, as it is an expensive and lengthy exam. Previous studies have shown a high diagnostic performance for abbreviated rapid MRI protocols to monitor for various diseases [17]. Recent studies have tested the accuracy of a protocol using only two sequences in different planes in comparison to a full length protocols and showed a proper diagnostic presentation [13,14].

Our study suggests that if osteomyelitis is not suspected after evaluation of the non fat saturated T1 and fluid-sensitive fat-saturated (STIR) weighted images, an additional full protocol involving other different sequences is unlikely to diagnose osteomyelitis. According to our study, this rapid protocol has high accuracy in ruling out osteomyelitis amongst cases not following its standard MRI criteria (100% and 97.6%) when in comparison to a full protocol. This rapid protocol is also highly reliable and reproducible for the diagnosis of

osteomyelitis with an almost perfect inter-rater agreement. We believe that no previous studies have recorded the inter-observer reliability of this abbreviated protocol in screening for osteomyelitis in patients with diabetic foot ulcers.

Regarding soft tissue abscesses, the protocol showed a moderate sensitivity in ruling out abscesses (80% for both observers). Both observers showed a high specificity in ruling out osteomyelitis and abscess (94.4% to 100%) when using the standard MR criteria for their diagnosis. These findings suggest that the rapid protocol may be of value in identifying patients who do not need a full protocol.

While the American college of radiology recommends the use of intravenous contrast in case of performance of MRI for the assessment of osteomyelitis of the foot, its importance in the diagnostic performance is not well established. Previous studies revealed that intravenous contrast is of use in the detection of complications of soft tissue infection including tissue necrosis, abscess formation, and sinus tracts [5,18]. In our study, the use of intravenous contrast was not of statistically significant value in diagnosing osteomyelitis. However, we suggest that lack of use of IV contrast reduced the sensitivity of the rapid protocol in diagnosing soft tissue abscesses. These results agree with previous literature reporting improved portrayal of soft tissue infection with the use of intravenous contrast [13,14]. MR image appearance of an abscess shows a uniform to mildly irregular high-signal intensity focal lesion on fluid-sensitive sequences, with corresponding intermediate to low signal intensity on T1-weighted imaging and with marginal enhancement on post-contrast images

with a reported sensitivity and specificity to be 89% and 80% respectively [18]. Definitely, large abscesses are easily and confidently diagnosed compared to small ones. Thus, small abscesses pose a diagnostic dilemma. Abscesses can be obscured on MRI examinations in diabetic patients, in whom there is a diffuse signal intensity increase in subcutaneous and muscle tissue due to edema [19]. However, treatment for abscesses depends on their size and location [20], which includes percutaneous drainage, surgical debridement, and intravenous and oral antibiotics, consequently small abscesses may not need surgical intervention. Fig. (3) illustrates a case of a false negative result using the rapid protocol. The clinical report following the full standard protocol was established upon the presence of a rim enhancing region with central non enhancement. On the other hand, STIR sequence showed only soft tissue edema corresponding the area of non enhancement with no definite fluid collection. However, regardless of this MRI appearance of a marginally enhancing abscess, the last clinical report revealed resolution of this appearance in this area after the patient was managed with intravenous antibiotics with no surgical interference.

Considering the previously described findings and according to the study done by Singer et al. [14], we suggest that the ultimate usefulness of the rapid protocol can be reached when the interpreting radiologist can evaluate the two sequences in real time, it can help classification of patients into one of three categories to help determine who may benefit from a full imaging protocol: Definite osteomyelitis, definitely no osteomyelitis, and indeterminate cases. Subcategorization into "indeterminate" cases is of high diagnostic value, as according to recent studies [21], a high false positivity noted with the conventional T1 and T2 weighted sequences may lead to a non essential treatment with antibiotics. The false positive cases may be due to dependence of MRI sequences on bone marrow signal changes, which are non specific to bony infection, as they may be due to marrow reactive edema, charcotarthropathy or stress fractures. Some "indeterminate" cases may benefit from additional imaging.

Among our 41 cases, the rate of bone and joint pathologies depending on previously mentioned marrow signal changes simulating osteomyelitis was moderate. In cases of inflammatory joint or charcotarthropathy, an accurate diagnosis of osteomyelitis can pose a challenge, even with the use of a full standard protocol. Nevertheless, we would stress that the aim of this study is to classify

cases into one of three categories: Definitely osteomyelitis, definite no Osteomyelitis, and indeterminate. If these alternate diagnoses was suspected and osteomyelitis was not obviously identified, the case shall be recognized as an indeterminate case that requires a full standard protocol with contrast. Consequently, this rapid protocol would be efficient even when considering such confusing factors.

Our study has multiple limitations: First of all, the patients MRI examinations were interpreted by radiologists with no available previous imaging studies. In daily practice, musculoskeletal magnetic resonance imaging exams are evaluated in combination with available plain radiography, the lack of which may have affected the study diagnostic performance. Second, the gold reference for the diagnosing acute osteomyelitis is histopathology and tissue culture which were not available in our study. We depended on documents provided by clinicians to provide the diagnosis. There are inevitable hazard of inaccuracy in this method, however, we followed published guidelines regarding this issue [6], in which biopsy is not always indicated in the management of a suspected case of pedal osteomyelitis. Third, in our study, we did not perform a sub-classification to assess the diagnostic capability of magnetic resonance imaging when patients remained considered suggestive with either findings of reactive osteitis or osteomyelitis (normal osseous T1 signal and osseous high focal STIR signal). Recent studies reported that more than half of patients with a diabetic foot ulcer and MRI signs positive for reactive osteitis, but not presenting with classical imaging findings of osteomyelitis, will in the end be diagnosed with osteomyelitis [17]. Lastly, our study did not test the diagnostic performance of limited protocol, compared to full protocol in the description of extent of infection for preoperative preparations.

Conclusions:

In conclusion, this rapid, abbreviated, no-contrast, protocol consisting of two sequences was both efficient and reliable in ruling out osteomyelitis with the use of the standard MRI osteomyelitis signs. While less reliable with less accuracy for the diagnosis of soft tissue abscesses, it showed a proper sensitivity. In addition, real-time evaluation of sequences using this rapid protocol can help recognition of cases that would profit from further investigation and administration of contrast. This may reduce imaging time and decrease undesirable intravenous contrast administration, especially in diabetic patients who are known to have affected renal functions.

Future studies advised for further investigation include involving implementing this rapid protocol in daily clinical practice, with real-time radiologist observing each examination to determine which patients will benefit from a full protocol to diagnose acute osteomyelitis.

References

- 1- BEKELE F., CHELKEBA L., FEKADU G. and BEKELE K.: Risk factors and outcomes of diabetic foot ulcer among diabetes mellitus patients admitted to Nekemte referral hospital, western Ethiopia: Prospective observational study. *Ann. Med. Surg. (Lond)*, Jan. 18; 51: 17-23, 2020.
- 2- SINGER A.J., TASSIOPOULOS A. and KIRSNER R.S.: Evaluation and management of lower-extremity ulcers. *New England Journal of Medicine*, 377 (16): 1559-1567, 2017.
- 3- GERAGHTY TAND and LAPORTA G.: Current health and economic burden of chronic diabetic osteomyelitis, *Expert Review of Pharmacoeconomics & Outcomes Research*, 19 (3): 279-286, 2019.
- 4- ZHANG X., SUN D. and JIANG G.C.: Comparative efficacy of nine different dressings in healing diabetic foot ulcer: A Bayesian network analysis. *Journal of diabetes*, 11 (6): 418-426, 2019.
- 5- BOULTON A., ARMSTRONG D.G., HARDMAN M.J., MALONE M., EMBIL J.M., ATTINGER C.E., LIPSKY B.A., ARAGÓN-SÁNCHEZ J., LI H.K., SCHULTZ G. and KIRSNER R.S.: Diagnosis and Management of Diabetic Foot Infections. American Diabetes Association, 2020.
- 6- LIPSKY B.A., BERENDT A.R., CORNIA P.B., PILE J.C., PETERS E.J., ARMSTRONG D.G., DEERY H.G., EMBIL J.M., JOSEPH W. S., KARCHMER A.W., PINZUR M.S., SENNEVILLE E. and Infectious Diseases Society of America: 2012 Infectious Diseases Society of America clinical practice guideline for the diagnosis and treatment of diabetic foot infections. *Clinical infectious diseases: An official publication of the Infectious Diseases Society of America*, 54 (12): e132-e173, 2012.
- 7- LIPSKY B.A., ARAGÓN-SÁNCHEZ J., DIGGLE M., EMBIL J., KONO S., LAVERY L., SENNEVILLE É., URBANCIC-ROVAN V., VAN ASTEN S., International Working Group on the Diabetic Foot & Peters E.J.: IWGDF guidance on the diagnosis and management of foot infections in persons with diabetes. *Diabetes / metabolism research and reviews*, 32 (Suppl 1): 45-74, 2016.
- 8- LAVERY L.A., RYAN E.C., AHN J., CRISOLOGO P.A., OZ O.K., LA FONTAINE J. and WUKICH D.K.: The Infected Diabetic Foot: Re-evaluating the Infectious Diseases Society of America Diabetic Foot Infection Classification. *Clinical infectious diseases: An official publication of the Infectious Diseases Society of America*, 70 (8): 1573-1579, 2020.
- 9- MALONE M., BOWLING F.L., GANNASS A., JUDE E.B. and BOULTON A.J.: Deep wound cultures correlate well with bone biopsy culture in diabetic foot osteomyelitis. *Diabetes/metabolism research and reviews*, 29 (7): 546-550, 2013.
- 10- Expert Panel on Musculoskeletal Imaging, WALKER E.A., BEAMAN F.D., WESSELL D.E., CASSIDY R.C., CZUCZMAN G.J., DEMERTZIS J.L., LENCHIK L., MOTAMEDI K., PIERCE J.L., SHARMA A., YING-KOU YUNG E. and KRANSDORF M.J.: ACR Appropriateness Criteria Suspected Osteomyelitis of the Foot in Patients With Diabetes Mellitus. *Journal of the American College of Radiology: JACR*, 16 (11S): S440-S450, 2019.
- 11- DONOVAN A. and SCHWEITZER M.E.: Use of MR imaging in diagnosing diabetes-related pedal osteomyelitis. *Radiographics: A review publication of the Radiological Society of North America, Inc.*, 30 (3): 723-736, 2010.
- 12- RANKEY D., LEACH J.L. and LEACH S.D.: Emergency MRI utilization trends at a tertiary care academic medical center: Baseline data. *Acad. Radiol.*, 15 (4): 438-443, 2008.
- 13- KOTECHA H.M., LO H.S., VEDANTHAM S., SHIN H. and CERNIGLIA C.A.: Abbreviated MRI of the foot in patients with suspected osteomyelitis. *Emergency Radiology*, 27 (1): 9-16, 2020.
- 14- SINGER A.D., UMPIERREZ M., KAKARALA A., SCHECHTER M.C., MACEROLI M., SHARMA G.B. and RAJANI R.R.: Performance of a rapid two-sequence screening protocol for osteomyelitis of the foot. *Skeletal Radiology*, 49 (6): 977-984, 2020.
- 15- DINH M.T., ABAD C.L. and SAFDAR N.: Diagnostic accuracy of the physical examination and imaging tests for osteomyelitis underlying diabetic foot ulcers: Meta-analysis. *Clinical Infectious Diseases*, Aug. 15; 47 (4): 519-27, 2008.
- 16- KAPOOR A., PAGE S., LAVALLEY M., GALE D.R. and FELSON D.T.: Magnetic resonance imaging for diagnosing foot osteomyelitis: A meta-analysis. *Archives of Internal Medicine*, Jan. 22; 167 (2): 125-32, 2007.
- 17- ROSS A.B., CHAN B.Y., YI P.H., REPPLINGER M.D., VANNESS D.J. and LEE K.S.: Diagnostic accuracy of an abbreviated MRI protocol for detecting radiographically occult hip and pelvis fractures in the elderly. *Skeletal Radiol.*, 48 (1): 103-8, 2019.
- 18- TURECKI M.B., TALJANOVIC M.S., STUBBS A.Y., GRAHAM A.R., HOLDEN D.A., HUNTER T.B. and ROGERS L.F.: Imaging of musculoskeletal soft tissue infections. *Skeletal Radiology*, 39 (10): 957-971, 2010.
- 19- LEDERMANN H.P., MORRISON W.B. and SCHWEITZER M.E.: Pedal abscesses in patients suspected of having pedal osteomyelitis: Analysis with MR imaging. *Radiology*, Sep. 224 (3): 649-655, 2002.
- 20- WEAVER J.S., OMAR I.M., MAR W.A., KLAUSER A.S., WINEGAR B.A., MLADY G.W., MCCURDY W.E. and TALJANOVIC M.S.: Magnetic resonance imaging of musculoskeletal infections. *Polish Journal of Radiology*, 87: e141-e162, 2022.
- 21- RAJ S., PRAKASH M., RASTOGI A., SINHA A. and SANDHU M.S.: The role of diffusion-weighted imaging and dynamic contrast-enhanced magnetic resonance imaging for the diagnosis of diabetic foot osteomyelitis: A preliminary report. *Polish Journal of Radiology*, 87: e274-e280, 2022.

مقارنة بروتوكول فحص سريع ثنائى التسلسل بالبروتوكول لقياسى فى الرنين المغناطيسى لتشخيص التهاب عظام القدم فى مرضى القدم السكرى

يشير داء السكرى إلى مجموعة من الأمراض التى تؤثر على كيفية استخدام الجسم لسكر الدم (الجلوكوز).

تتطور مضاعفات مرض السكرى على المدى الطويل تدريجياً. كلما طالت فترة الإصابة بمرض السكرى مع عدم المحافظة على انتظام معدل الجلوكوز كلما زاد خطر حدوث مضاعفات.

يزيد تلف الأعصاب فى القدمين أو ضعف تدفق الدم إلى القدمين من خطر المضاعفات المختلفة المتعلقة بالقدم. إذا تركت الجروح والبثور دون علاج، فقد تتسبب فى إصابات خطيرة، وغالباً ما تشفى بشكل بطئ. وقد يصل الالتهاب إلى عظام القدم. وقد تتطلب هذه الالتهابات بتر الإصبع أو القدم أو الساقفى النهاية.

تشخيص التهاب العظام فى هذه الحالة ليس سهل يبدأ بأخذ السيرة المرضية والفحص السريرى وبعض الاختبارات. وقد يحتاج إلى عدة فحوصات أخرى تتضمن: الفحوصات المخبرية للدم، الزراعة الميكروبية، أشعة سينية أو صورة رنين مغناطيسى.

قد تبدو الأشعة السينية للقدم طبيعية فى المراحل المبكرة من الحالة.

وهنا يأتى دور التصوير بالرنين المغناطيسى الذى يلتقط صوراً تفصيلية بشكل استثنائى للعظام والأنسجة الرخوة التى تحيط بها والذى بدوره يساهم بشكل كبير فى التشخيص.

حيث أن التصوير الرنين المغناطيسى (بروتوكول الفحص الكامل) يستلزم بعض الوقت، اتجهت بعض الدراسات لتقييم دور بروتوكول سريع ثنائى التسلسل فى تشخيص التهاب عظام القدم فى مرضى القدم السكرى.

فى دراستنا أظهرت النتائج أن (البروتوكول السريع ثنائى التسلسل) فعلاً فى استبعاد التهاب العظام والنقى. علاوة على ذلك، كان البروتوكول دقيقاً ومحددأ فى الحكم على التهاب العظام والنقى عند استخدام معايير التهاب العظام والنقى التقليدية بالرنين المغناطيسى. على الرغم من أن التشخيص كان أقل دقة فى تشخيص الخراجات، إلا أنه كان هناك حساسية معتدلة.

قد يؤدي ذلك إلى توفير وقت التصوير وتحسين الإنتاجية وتقليل التعرض غير الضرورى للصبغة الوريدية المستخدمة فى بروتوكول الفحص الكامل. هناك حاجة إلى مزيد من الدراسات مع حجم عينة أكبر لتأكيد نتائجنا.