

TREATMENT OF PEDIATRIC MANDIBULAR FRACTURES USING CUSTOMIZED COMPUTER ASSISTED PEEK PLATES

Nourhan M. Abdelmoneim^{1*} MSc, Ahmed S. El-mahalawy² PhD, Mahitab M. Soliman³ PhD, Marwa G. Noureldin⁴ PhD, and Omneya A. Gamaleldin⁵ PhD

ABSTRACT

INTRODUCTION: Pediatric mandibular fracture is particularly challenging and its management is still controversial. The disadvantages of conventional metal plates such as stress shielding, restricting bone growth, particularly in children, palpability, thermal sensitivity, and interference with diagnostic imaging, elicited the search for better options for fracture fixation. Therefore, polyether ether ketone (PEEK) has emerged as a promising alternative in the development of new osteosynthesis plates.

OBJECTIVES: To evaluate the efficacy of customized computer assisted PEEK plates in the fixation of pediatric mandibular fractures in terms of clinical and radiographic assessment parameters.

MATERIALS AND METHODS: The present study was conducted on seven children with recent displaced mandibular fractures indicated for open reduction and internal fixation (ORIF). All children were treated using customized computer assisted PEEK plates. Patients were then followed up for three months. Each patient was assessed clinically in terms of the operative time and postoperative complications. Radiographic assessment was done with the aid of an immediately postoperative orthopantomogram and computed tomography (CT) after three months to assess the bone healing and evaluate the mean bone density along the fracture site.

RESULTS: The overall postoperative complications were 14.3%. The mean operative time was (0:56 ±00:07). The mean bone density at the third month revealed a statistically significant ($p < 0.001$) increase when compared to the preoperative mean bone density results.

CONCLUSION: Customized computer assisted PEEK plates may be a better option for treating pediatric mandibular fractures as it offers reasonable operative time, precise reduction, less postoperative complications, and proper bone healing.

KEYWORDS: PEEK, Customized plates, Computer assisted plates, Pediatric mandibular fractures.

RUNNING TITLE: Customized PEEK Plates in Pediatric Mandibular Fractures.

1 Assistant lecturer of Oral and Maxillofacial Surgery, Oral and Maxillofacial Surgery Department, Faculty of Dentistry, Fayoum University, Fayoum, Egypt

2 Professor of Oral and Maxillofacial Surgery, Oral and Maxillofacial Surgery Department, Faculty of Dentistry, Alexandria University, Alexandria, Egypt

3 Professor of Oral and Maxillofacial Surgery, Oral and Maxillofacial Surgery Department, Faculty of Dentistry, Alexandria University, Alexandria, Egypt

4 Assistant professor of Oral and Maxillofacial Surgery, Oral and Maxillofacial Surgery Department, Faculty of Dentistry, Alexandria University, Alexandria, Egypt

5 Assistant professor of Diagnostic and Interventional Radiology, Diagnostic and Interventional Radiology Department, Faculty of Medicine, Alexandria University, Alexandria, Egypt

***Corresponding author:**

E-mail: nourhanabdelmoneim@gmail.com

INTRODUCTION

Mandibular fractures among the pediatric population are particularly challenging and are considered one of the most common and complicated types of traumatic injuries to the maxillofacial region in children, accounting for 45% to 95% of all facial skeleton bone injuries (1).

The treatment of mandibular fractures in growing children during the deciduous and mixed dentition stages has remained a subject of controversy, where the key concerns are mandibular dentition development and skeletal growth (2).

Open reduction and internal fixation (ORIF) has become the gold standard technique to treat displaced and unstable fractures of the pediatric mandible that can't be reduced or stabilized using closed methods (3, 4). Over the last forty years, fractures indicated for ORIF in pediatric population were treated with metal plates and screws, which are the most commonly used osteosynthesis plates (3, 5).

Although metal plates provide proper fixation, support to the fracture site, and bone healing, their shortcomings, such as stress shielding

of the underlying bone and restricting bone growth, particularly in children, palpability, thermal sensitivity, sepsis, and interference with diagnostic imaging, along with material advancements, have motivated researchers to search for better alternative materials for the fixation of pediatric mandibular fractures (6,7).

In recent years, a high-performance thermoplastic polymer, PEEK, has emerged as an attractive option for the fabrication of new osteosynthesis plates and a promising future alternative to metals like titanium, due to its superior mechanical, physical, and biocompatibility characteristics (8,9).

Polyether ether ketone has a modulus of elasticity that is close to that of human bone, so it has less stress shielding effect than metals. In addition, it avoids unwanted metallic ion interactions, is compatible with computed tomography (CT), and magnetic resonance imaging procedures, and sustains most sterilization techniques (10). It also has exceptional characteristics of strength, high stiffness, durability, biocompatibility, and biological stability, as well as fracture and degrading resistance, which allow it to be milled into accurate designs without the risk of implant fracture or failure (11).

The fabrication of customized computer assisted osteosynthesis plates prior to surgery has been made easier thanks to modern technological advances in virtual planning, computer-aided design/computer-aided manufacturing (CAD/CAM), and rapid prototyping technology through the construction of unique three-dimensional(3D) frameworks that can eliminate the requirement for intraoperative modification and adaptation, resulting in a shorter operation time and fewer complications (12,13).

Only a few records exist in the current literature that show the outcomes of mandibular fracture treatment with custom-made PEEK osteosynthesis plates in maxillofacial trauma in adults (14,15). Furthermore, the unique properties of pediatric mandibular fractures have led us to question the efficacy of a new customized computer assisted PEEK plates based on 3D models generated from CT scans of pediatric patients. Therefore, the aim of the study was to evaluate the efficacy of customized computer assisted PEEK plates in the fixation of pediatric mandibular fractures in terms of clinical and radiographic assessment parameters.

MATERIALS AND METHODS

This study was a prospective clinical and radiographic study. The Research Ethics Committee at the Faculty of Dentistry, Alexandria University approved the present study in September 2020 and informed written consent was obtained from all patient's guardians prior to the study.

Patients

Based on sample size calculation, seven children with mandibular fractures indicated for ORIF were recruited from the Emergency Department of Alexandria University Teaching Hospital according to the following criteria:

Inclusion criteria were, children suffering from recent non-comminuted displaced mandibular fractures, age range of 6-13 years with no gender predilection, and systemically free. Exclusion criteria were children with systemic disorders that impair bone repair, the age above 13 years, having condylar fractures, infection or pre-existing mandibular pathology at the fracture site, and patients who are unable to tolerate follow-up intervals.

Materials

Polyether ether ketone disc (breCAM.Bio-HPP® PEEK milling disc Manufactured by Bredent GmbH & Co.KG, Senden, Germany, www.bredent.com), titanium monocortical screws with a 2.0 mm head diameter, and an 8 ml length were used to secure the customized plates. (Manufactured by JEIL Medical Corporation Company: Seoul, Korea. www.jeilmed.co.kr.)

Methods

Pre-surgical phase

Preoperative assessment

For each stabilized patient, preoperative assessment were carried out through an accurately detailed history taking, comprehensive extra-oral and intra-oral clinical examination. In addition to careful radiographic examinations of the preoperative CT scan of the facial bones for all children.

B.Preoperative Virtual Planning, Surgical Simulation and Fabrication of customized computer assisted PEEK plates (17-21)

Based on preoperative CT data of the study participants, processing of the DICOM (Digital Imaging and Communications in Medicine) files was performed using the specialized DICOM image processing Mimics Innovation Suite 21 software (Materialise, Leuven, Belgium) and 3D models of the fractured mandibular segments were reconstructed. Fractured segments of the mandible were virtually reduced and repositioned to their anatomic configuration using the repositioning option in the simulation module in the designing software (3-Matic software) (Materialise NV, Leuven, Belgium). These virtually reduced 3D models were used to design the virtual customized PEEK plates in the optimal position with intimately adapted fitting surfaces. The required shape, size, and the distances between screw holes in customized plates were changed for each patient, according to the relationship with the permanent tooth buds (if present) using 3-Matic software (Materialise NV, Leuven, Belgium). (Figure 1-3). Finally, the plate design was exported in stereolithography (STL) format and the CAM plate model was constructed using specially designed software (inLAB CAM SW 16) (Dentsply Sirona

Susquehanna Commerce. W. Philadelphia Street, USA) which is directly linked to the 5-axis milling machine (inLAB MC X5) (Dentsply Sirona Susquehanna Commerce. W. Philadelphia Street, USA) to be the basis for the milling of the customized plates from PEEK discs. (breCAM.BioHPP® PEEK milling disc. Bredent GmbH & Co.KG, Senden, Germany). Then Sterilization of the customized computer assisted peek plates was carried out by autoclaving at 134⁰ C (17-21).

Surgical phase

Prior to the surgery, prophylactic antibiotic therapy in the form of intravenous Cefotaxime 50mg/kg/day/12hr. (Cefotax 1 gm, E.I.P.I.C.O., Egypt) was given to all the children to avoid postoperative infection. The doses were calculated and provided based on each patient's body weight. All children's surgical operations were performed under general anaesthesia utilizing nasotracheal intubation. After induction of anaesthesia, surgical site disinfection using povidone-iodine surgical scrub (Betadine: Povidone-iodine, 7.5% Purdue Products L.P.) had been done, followed by draping with sterile towels exposing only the surgical region. Risdon or arch bar with Ivy loop wiring were applied to the teeth in each case based on the stage of dentition. Local anesthetic solution with vasoconstrictor (ArtPharmadent 4%: articaine Hcl 4% with epinephrine 1/100000, Art pharma, Egypt) was applied along the fracture location to allow for hemostasis. The fractures were approached via an intraoral vestibular incision. Assessment of the operating time was started from the beginning of the incision by using a stop watch. Complete elevation of the mucoperiosteal flap and subperiosteal dissection were performed to allow proper exposure of the fracture line. According to the fracture location, if indicated, careful dissection of the mental nerve was done for adequate retraction and exposure followed by disimpaction of the fracture segments, removal of any granulation tissues if found, or any soft tissue entrapped within the fracture line. Teeth in the fracture line were managed either by extraction or preservation, as indicated in each case. Manual reduction of the fracture was performed by proper repositioning of the fractured segments into the original position that was guided by the proper fitting of the customized PEEK plates to the surface topography of the mandible in its tailored position to confirm proper reduction of the fractured segments and restore of the pre-morbid occlusion. With temporary intermaxillary fixation (IMF), the occlusion was checked and placed into centric occlusion to serve as a guide for fracture reduction. Drilling was performed through the holes of the plates under copious saline irrigation. The plates were fixed using monocortical titanium 2.0 screws (Figure 4). The closing wires of the IMF were

released immediately after fixation to test the stability of the osteosynthesis clinically by bi-manual palpation across the fracture site and to verify that the occlusion was stable and reproducible. After irrigation with saline, closure of the surgical wound was done. The operating time ended with the placement of the last suture. A compression bandage around the chin and the mandible was applied extra-orally to minimize edema and facilitate the healing.

Postoperative phase

Early postoperative care included instructions to apply an ice pack extra-orally starting immediately postoperatively and continuing for twenty-four hours. All children were given postoperative medications. The doses were calculated and divided based on each patient's body weight. The antibiotic schedule was continued post-operatively using intravenous cefotaxime (Cefotax 1 gm, E.I.P.I.C.O., Egypt) with an average dose of 50 mg/kg/day to be divided into two equal doses every 12 hours for the first day, followed by oral Amoxicillin trihydrate + Potassium clavulanate (Augmentin 457, GlaxoSmithKline, UK) with an average dose of 45mg /kg/day to be divided into equal doses twice daily for the next five days. In addition, Ibuprofen 20 mg/kg/day (Brufen 400, Abbott) to be divided every eight hours for three days as analgesic anti-inflammatory drug, Metronidazole 7.5 mg/kg (Flagyl 125 mg, GlaxoSmithKline, UK) every eight hours for five days. α -Chemo-trypsin 5 mg ampoules (α -chemo-trypsin, Leurquin, France, packed by Amoun pharmaceutical company, Egypt) as anti-oedematous once daily for two days. All children were instructed to maintain good oral hygiene and to rinse their mouth using 0.12% Chlorhexidine (Hexitol 125mg/100ml, concentration 0.125%: Arabic drug company, ADCO, Egypt) antiseptic mouthwash starting the day after surgery three times daily for ten days. The children were instructed to follow a soft, fully liquid, high protein, high-calorie diet for a period of up to four weeks postoperatively.

Follow-up phase

The protocol of the follow up consists of clinical and radiographic assessment up to three months postoperatively.

Clinical assessment parameters

Duration of operation: the operative time was assessed via clinical assessment using a stop watch, from incision until the placement of the last suture, measuring unit (hours).

Postoperative complications in terms of wound dehiscence, infection, occlusal discrepancies, segmental mobility, neurosensory disturbances, plate failure (including plate loosening, plate breakage, and screw loosening), mal-union, and non-union. At the following intervals: 24 hours postoperatively, every week for one month, two and three months postoperatively.

Radiographic assessment

Radiographic assessment was evaluated immediately postoperative with the aid of an Orthopantomogram (OPG) to evaluate the accuracy of reduction and alignment of the fractured segments.

In the third postoperative month, CT scans were performed to assess the bone healing and to evaluate the mean bone density at the site of fracture in Hounsfield unit (HU). Radiodensitometric measurement to evaluate the mean bone density at the site of fracture were calculated preoperatively and at the third month postoperatively using RadiAnt DICOM Viewer (64-bit) software, the mean bone density at the fracture site was calculated from the cross-sectional cut through (measurements and tool option) within the software by selecting a 0.025cm^2 ellipse placed every time at the site of the fracture line at six different locations close to the fracture line, The averages of them were then calculated to determine the preoperative, and 3 months' postoperative mean bone density.

A secondary operation for the removal of the plates was carried out after radiographically confirmed healing of the fractured bones.

Statistical analysis

Quantitative data was explored for normality using Shapiro-Wilk tests. The mean, standard deviation, range (minimum and maximum), and median were used to summarize quantitative data. For normally distributed quantitative data, a Paired t-test was used to compare between two periods. Numbers (n.) and percentages (%) were used to represent qualitative data. The significance level was set at $p \leq 0.05$ for all tests. The IBM SPSS Statistics Version 20.0 for Windows (Armonk, NY: IBM Corp, USA) was used to conduct the statistical analysis.

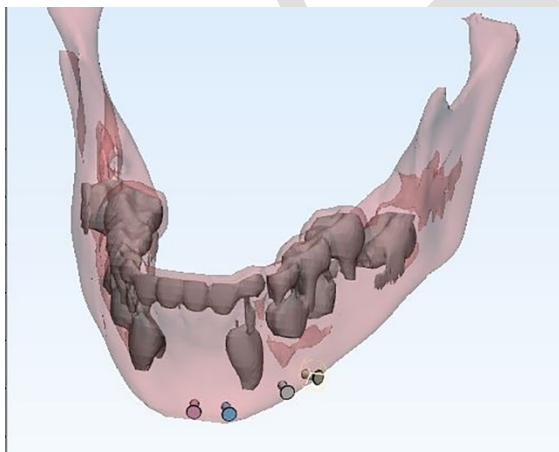


Figure (1): Virtual planning of the optimal position and distances between screw holes in the virtual customized PEEK plate according to the tooth buds position.

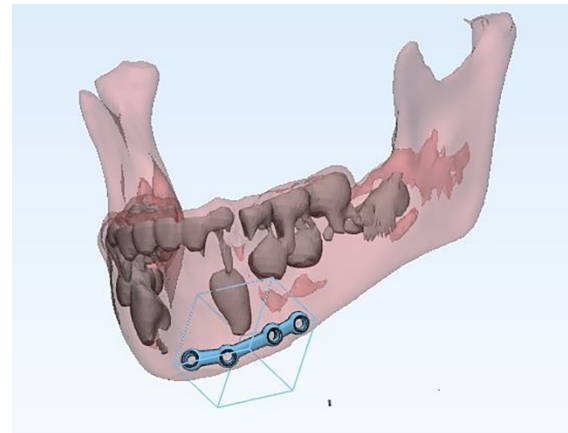


Figure (2): Virtually reduced 3D models used to design the virtual customized PEEK plate.

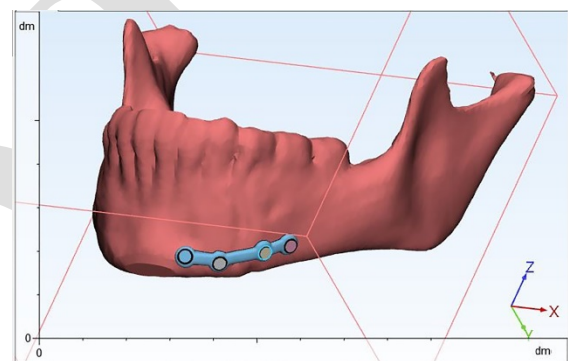


Figure (3): Intimate adaption of the final virtual customized PEEK plate on mandibular surface topography.

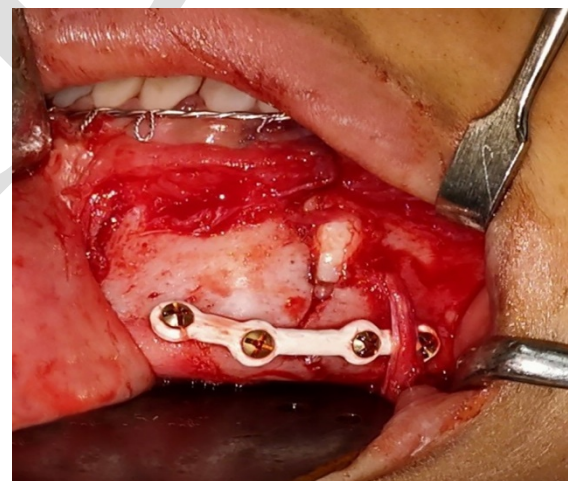


Figure (4): Fixation of customized peek plate into its accurate position.

RESULTS

The enrolled children in the present study underwent ORIF of mandibular fractures using customized computer assisted PEEK plates (n=7). The demographic data of the study participants in terms of age, gender, fracture location, fracture etiology were presented in (Table 1).

Clinical assessment parameters (Table 2).

Duration of operation

The mean operative time was reasonable (0:56 ± 00:07) (Table 2).

Postoperative Complications

During the follow-up period, all children in the study healed uneventfully, the overall postoperative complications rate was 14.3%. There were no cases of wound dehiscence, infections, occlusal discrepancies, segmental mobility, or neurosensory disturbances among the study participants, except one case (14.3%) where minor occlusal discrepancy was noted in the second week postoperatively. IMF using guiding elastics for 1 week was used to adjust the occlusion. Adequate occlusion was achieved after one week. There were no clinical signs of plate failure, mal-union, or nonunion throughout the follow-up period (Table 2).

Radiographic assessment results

The immediate post-operative OPG showed proper reduction and accurate vertical alignment of the fracture segments and the inferior border of the mandible in all children. After three months, CTs of the cases showed proper bony union in all directions, with anatomic vertical and horizontal alignment of the mandibular bone. Bone healing was achieved and the fracture line couldn't be detected in all the cases. In any case, there was no radiographic evidence of the presence of plate failure, malunion, or nonunion. The CT scans revealed that the customized peek plates caused no injury to any permanent tooth buds in all the cases. The mean preoperative bone density was 338.8 ± 52.07 HU. While the mean bone density after three months was 644.5 ± 50.93. They showed a 93.96 ± 32.71% increase from the preoperative values, which was a statistically significant increase in the bone density after three months (p<0.001) (Table 3).

A second surgery for plate removal was performed after radiologically confirmed healing of the fractured bones.

Table (1): Descriptive summery of the study participant's demographic data (n=7).

Demographic Data Variables		
Age: Mean (SD)		7.7±2.5
Median (Min. – Max.)		7.0 (6-13)
Gender: n (%)	Males	5 (71.4%)
	Females	2 (28.6%)
Fracture location : n (%)	Left Para-symphyseal	3(42.9%)
	Right Para-symphyseal	3(42.9%)
	Right body	1 (14.2%)
Fracture etiology: n (%)	Fall from height	3(42.9%)
	RTA	2 (28.7%)
	Animal kick	1 (14.2%)
	Fall during playing	1 (14.2%)

SD: Standard deviation

Table (2): Descriptive analysis of the clinical assessment parameters among the study participants (n=7).

Clinical assessment parameters	
Duration of operation (hours)	
Mean ± SD.	0:56 ±00:07
Postoperative complications	n (%)
Infection	0 (0.0%)
Dehiscence	0 (0.0%)
Occlusal discrepancies	1 (14.3%)
Segmental mobility	0 (0.0%)
Malunion	0 (0.0%)
Nonunion	0 (0.0%)
Neurosensory disturbances	0 (0.0%)
Plate Failure	0 (0.0%)
Overall postoperative complications	1 (14.3%)

SD: Standard deviation

Table (3): Descriptive analysis of the mean bone density values in Hounsfield Unit (HU) throughout the follow up period (n= 7).

Follow up period	Bone density (HU)
Preoperative	
Min. – Max.	258.1 – 407.8
Mean ± SD.	338.8 ±52.07
Median	325.8
3 month postoperative	
Min. – Max.	582.2 – 730.7
Mean ± SD.	644.5 ±50.93
Median	645.7
Percent of Increase	
Mean ± SD.	93.96 ±32.71
t (p)	12.370* (<0.001*)

SD: Standard deviation t: Paired t-test

p: p value for comparing between Preoperative and 3 month postoperative

*: Statistically significant at p ≤ 0.05

DISCUSSION

As a result of the negative consequences of metal plates for pediatric fracture treatment and the promising advantages of PEEK biomaterial, as well as the great advances in CAD/CAM technology in the maxillofacial surgery field. The present study was aimed to evaluate the efficacy of customized computer assisted PEEK plates in the fixation of pediatric mandibular fractures in terms of clinical and radiographic assessment parameters.

All of the customized PEEK plates fabricated in the present study showed an adequate fit to the bone surface, offered excellent reduction and guided alignment of the fractured segments, which was the key to successful reduction and

optimum functional results post-operatively. This is in accordance with the findings of Voss et al., in 2016 (18) and Abaas et al., in 2021 (15).

The fractured segments were exposed utilizing a standardized intraoral surgical approach via vestibular incision, which might decrease the amount of periosteum disruption, resulting in enhanced vascularity to the surgical site, which improves healing and reduces the risk of post-operative complications, in coincidence to the findings of Sheta et al., in 2015 (21).

The mean operative time was (0:56 ± 00:07) which is considered a reasonable time. The customized design, which required no intra-operative time for plate adjustment, may be attributed to the reduction in operative time in the customized computer assisted PEEK plates. This is consistent with the findings of Amundson et al., in 2020 (22) and Abaas et al., in 2021 (15).

The wound healing results of the present study showed that all children healed uneventfully without wound dehiscence, infection, or neurosensory disturbances. These results may be attributed to excellent PEEK biocompatibility because of its bio-inert and hydrophobic characteristics. In agreement with the results reported by Lv et al., in 2022 (23) who demonstrated no obvious complications occurred in 12 patients who underwent reconstruction of defects in the orbital-maxillary-zygomatic (OMZ) complex using patient-specific PEEK implants and concluded that patient-specific PEEK implantation can successfully reconstruct the complicated 3D structure of the OMZ complex and demonstrates excellent biocompatibility and clinical outcomes.

This is inconsistent with the results of Jonkergouw et al., in 2016 (24) who reported the results of patient-specific cranial PEEK implants in 40 individuals that showed a 28 % total complication rate. Infection (13%), post-operative hematoma (10%), and wound-related difficulties (2.5%) were among the complications, however the researchers determined that the outcomes were good despite the high complication rate.

All of the participants in the study had satisfactory postoperative occlusion at the end of the follow-up phase. Only one case (14.3%) had minor occlusal discrepancy in the second week postoperatively. IMF using guiding elastics for 1 week was used to adjust the occlusion. Adequate occlusion was achieved after one week. In accordance to Bansal et al., in 2021 (25), who explained that because mixed dentition is continually changing, mild occlusion derangement is not an issue in pediatric patients. The teeth will eventually erupt into appropriate occlusion and minor occlusal discrepancies are compensated for by mandibular development and teeth eruption.

Bony union was assessed clinically and radiographically till the end of the third month. All

of the cases in our study achieved initial fracture segment stability intra-operatively and over a variety of follow-up periods, without any evidence of plate failure or segmental mobility, which could lead to non-union or malunion, on the contrary, radiographic evidence of bony union was present in all cases by the end of follow-up. And this was confirmed by the statistically significant increase in the bone density when comparing the preoperative and the third month values. This finding demonstrated that the mechanical properties of customized peek plates were sufficient to produce stability in pediatric mandibular fractures. This could be due to the fact that peek have sufficient strength and stiffness to preserve functional stability during the healing process. This finding is consistent with Dessoky et al., in 2020 (14) that found a statistically significant increase in the mean bone density when using custom made peek plates for treatment of mandibular fracture in adults.

The limitations of the present study are the high cost of the peek material, plate manufacturing, and lack of price stability. In regards to the limited follow-up period in the present study, long-term follow-up of more cases is needed to accurately assess potential effects on postoperative mandibular growth.

CONCLUSION

Within the limits of this study, the overall conclusion that can be drawn from this study is that, with the aid of virtual surgical planning and CAD/CAM technology, customized PEEK plates can successfully treat pediatric mandibular fractures. Customized computer assisted PEEK plates may be a better option for treating pediatric mandibular fractures as it offers reasonable operative time, precise reduction, less postoperative complications, and proper bone healing. Increased plate cost, preoperative virtual surgical planning, and plate production time in the trauma environment are barriers that can hinder installation of the customized plates for all pediatric patients, so it should be reserved for some special cases in the mixed dentition stage according to the position of the developing tooth buds.

Conflict of interest

The authors declare that they have no conflict of interest.

Funding statement

The author, as a staff member of Fayoum University, received a financial support to purchase the supplies for this study from Fayoum University. The authors declare that this support neither affected the results nor the independence of the author to publish the results or own the data.

REFERENCES

1. Rostyslav Y, Yakovenko L, Irina P. Fractures of the lower jaw in children (causes, types, diagnosis

- and treatment). Retrospective 5 year analysis. *J Oral Biol Craniofac Res.* 2020;10:1-5.
2. Sharma A, Patidar DC, Gandhi G, Soodan KS, Patidar D. Mandibular Fracture in Children: A New Approach for Management and Review of Literature. *Int J Clin Pediatr Dent.* 2019;12:356-9.
 3. Kushner GM. Pediatric Mandible Fractures. In: *Pediatric Maxillofacial Trauma.* Cham: Springer; 2021. pp. 97-114.
 4. Allred LJ, Crantford JC, Reynolds MF, David LR. Analysis of Pediatric Maxillofacial Fractures Requiring Operative Treatment: Characteristics, Management, and Outcomes. *J Craniofac Surg.* 2015;26:2368-74.
 5. Andrew TW, Morbia R, Lorenz HP. Pediatric Facial Trauma. *Clin Plast Surg.* 2019;46:239-47.
 6. Riviş M, Roi C, Roi A, Nica D, Văleanu A, Rusu LC. The implications of titanium alloys applied in maxillofacial osteosynthesis. *Appl Sci.* 2020;10:3203.
 7. Kanno T, Sukegawa S, Furuki Y, Nariai Y, Sekine J. Overview of innovative advances in bioresorbable plate systems for oral and maxillofacial surgery. *Jpn Dent Sci Rev.* 2018;54:127-38.
 8. Mounir M, Atef M, Abou-Elfetouh A, Hakam MM. Titanium and polyether ether ketone (PEEK) patient-specific sub-periosteal implants: two novel approaches for rehabilitation of the severely atrophic anterior maxillary ridge. *Int J Oral Maxillofac Surg.* 2018;47:658-64.
 9. Godbole SD, Chandak AV, Balwani TR. Poly Ether Ether Ketone (PEEK) Applications in Prosthodontics--A Review" Peek into PEEK at Peak". *J Evol Med Dent Sci.* 2020;9:3242-7.
 10. Mbogori M, Vaish A, Vaishya R, Haleem A, Javaid M. Poly-Ether-Ether-Ketone (PEEK) in Orthopaedic practice-A Current Concept Review. *J Orthop Case Rep.* 2022;1:3-7.
 11. Bathala L, Majeti V, Rachuri N, Singh N, Gedela S. The Role of Polyether Ether Ketone (Peek) in Dentistry - A Review. *J Med Life.* 2019;12:5-9.
 12. Li K, Li J, Du W, Xu C, Ye B, Luo E. Computer-Aided Design and Manufacturing Cutting and Drilling Guides with Prebent Titanium Plates Improve Surgical Accuracy of Skeletal Class III Malocclusion. *Plast Reconstr Surg.* 2020;145:963e-74.
 13. Herford AS, Miller M, Lauritano F, Cervino G, Signorino F, Maiorana C. The use of virtual surgical planning and navigation in the treatment of orbital trauma. *Chin J Traumatol.* 2017;20:9-13.
 14. Dessoky NY, El-Mahallawy AS, Fahmy MH, Khalil MM. Use of custom made peek plates for treatment of mandibular fracture. *Alex Dent J.* 2020;45:125-8.
 15. Abaas RA, Salah KA, Mounir R. Clinical assessment of Open Reduction Internal Fixation (ORIF) of Mandibular Body Fractures Using Computer-Assisted Polyetherether Ketone (PEEK) Custom Made Plates Versus Conventional Titanium Plates: A Randomized Clinical Trial. *Indian J Public Health Res Dev.* 2021;12:322-6.
 16. Li P, Tang W, Liao C, Tan P, Zhang J, Tian W. Clinical evaluation of computer - assisted surgical technique in the treatment of comminuted mandibular fractures. *J Oral Maxillofac Surg Med Pathol.* 2015;27:332-6.
 17. Zeng W, Lian X, Chen G, Ju R, Tian W, Tang W. Digital diagnosis and treatment program for maxillofacial fractures: A retrospective analysis of 626 cases. *J Oral Maxil Surg.* 2018;76:1470-8.
 18. Voss JO, Varjas V, Raguse JD, Thieme N, Richards RG, Kamer L. Computed tomography-based virtual fracture reduction techniques in bimaxillary fractures. *J Cranio Maxill Surg.* 2016;44:177-85.
 19. Vajgel A, Camargo IB, Willmersdorf RB, De Melo TM, Filho JRL, Vasconcellos RJ. Comparative finite element analysis of the biomechanical stability of 2.0 fixation plates in atrophic mandibular fractures. *J Oral Maxillofac Surg.* 2013;71:335-42.
 20. Li P, Long J, Tang W, Li J, Liang R, Tian DW. Stress distribution on the mandibular condyle and the distraction area in distraction osteogenesis by finite element analysis. *J Craniofac Surg.* 2013;24:1031-7.
 21. Sheta MS, Shoushan MM, Hussein MM, Abd Elaal SE. Evaluation of using microplates osteosynthesis for pediatric mandibular fractures. *Tanta Dent J.* 2015;12:149-55.
 22. Amundson M, Newman M, Cheng A, Khatib B, Cuddy K, Patel A. Three-Dimensional Computer-Assisted Surgical Planning, Manufacturing, Intraoperative Navigation, and Computed Tomography in Maxillofacial Trauma. *Atlas Oral Maxillofac Surg Clin North Am.* 2020;28:119-27.
 23. Lv M, Yang X, Gvetadze SR, Gupta A, Li J, Sun J. Accurate reconstruction of bone defects in orbital-maxillary-zygomatic (OMZ) complex with polyetheretherketone (PEEK). *J Plast Reconstr Aesthet Surg.* 2022;75:1750-7.
 24. Jonkergouw J, van de Vijfeijken SE, Nout E, Theys T, Van de Castelee E, Folkersma H, et al. Outcome in patient-specific PEEK cranioplasty: A two-center cohort study of 40 implants. *J Craniomaxillofac Surg.* 2016;44:1266-72.
 25. Bansal A, Yadav P, Bhutia O, Roychoudhury A, Bhalla AS. Comparison of outcome of open reduction and internal fixation versus closed treatment in pediatric mandible fractures-a

retrospective study. J Craniomaxillofac Surg.
2021;49:196-205.

ADJ