

The Complication Rate of Mini Open Transforaminal Lumbar Interbody Fusion: Single Institution Experience; A Retrospective Case Study

HAITHAM M.A. EL-MORSY, M.D.; MOHAMED M. MOHI ELDIN, M.D. and EHAB M. EISSA, M.D.

The Department of Neurosurgery, Faculty of Medicine, Cairo University

Abstract

Background: The mini-open TLIF and other minimally invasive approaches introduced for treating lumbar degenerative disk disease and instability achieving high success rate and safety as the conventional approaches, with less soft tissue damage, minimal blood loss and less hospital stay.

Aim of Study: The aim of this study is to demonstrate the complication rate and surgical technique of the mini-open transforaminal approach for lumbar interbody fusion (TLIF) combine with transpedicular screw fixation.

Patients and Methods: A retrospective study was conducted on 28 patients underwent Mini-open TLIF combined with trans-pedicular screw fixation for grade one or grade two spondylolisthesis and degenerative disk disease from 2012 to 2014. Two paramedian approaches 4cm for each were done for insertion of the pedicular screws with unilateral TLIF cage insertion with autologous bone graft. Decompression was done either unilateral or bilateral according to the patient side of radiculopathy. Sixteen patients (57.2%) were degenerative spondylolisthesis, 7 patients (25%) were diagnosed as isthmic type spondylolisthesis and 5 patients (17.8%) was diagnosed as degenerative disk disease, two of them (7.1%) had previous operation at the same level. Twenty patients (71.4%) were operated at the L4/5 level and eight patients (28.6%) at the L5/S1 level.

Results: All patients were able to ambulate next day of surgery. We had one case with transient weakness, 2 cases of screw malposition without clinical manifestations, and one case of infection. The mean estimated blood loss was 251.79cc. The average hospital stay was 4.14 days. The average follow-up was 9 months.

Conclusions: The mini-open TLIF approach is an efficient and safe approach for treating instability and degenerative diseases of the lumbar spine. The outcome was encouraging and it may be an operation of choice for lumbar spinal fusion in selected patients with a good safety profile.

Key Words: *Spondylolisthesis – TLIF – Screw – Fusion – Complication.*

Correspondence to: Dr. Haitham M.A. El-Morsy,
[E-Mail: haithammorsy79@gmail.com](mailto:haithammorsy79@gmail.com).

Introduction

MINI-TRANSFORAMINAL lumbar interbody fusion (Mini-TLIF) is a minimally invasive surgical (MIS) procedure aiming at achieving a lot of goals as pedicle screw instrumentation, decompression, posterolateral fusion, interbody fusion, and low grade spondylolisthesis reduction. It has small incision length and limited muscle denervation [1].

The Mini-TLIF procedure is done using microscopic visualization and special retractors. This provides a good exposure such as conventional TLIF. Two paramedian incisions can be used to decompress the nerve roots. Transpedicular screws fixation and interbody fusion can then be done [2].

The Mini-TLIF procedure is associated with decreased muscle trauma, less blood loss and shorter hospital stay [3].

Patients and Methods

Study design:

A prospective cross sectional study was performed.

Study population:

A prospective cross sectional study was performed throughout the period from March 2012 to December 2014, on 28 patients who were subjected to one level Mini-TLIF with transpedicular screw fixation, and unilateral or bilateral decompression. The candidates were refractory patients (failure of conservative treatment for 3 months), radicular pain associated with spondylolisthesis, mechanical low back, recurrent disc herniation, and degenerative disc disease. Full history taking and complete neurological examination were done before the

operation. Plain erect radiographs (static, dynamic, and oblique views) and magnetic resonance imaging (MRI) of the lumbosacral spine were performed.

Routine preoperative laboratory investigations were performed for general anesthesia.

Technique of Mini-TLIF:

Under general anesthesia, the operation is done on a radiolucent table in prone position.

The entry points of the pedicles were marked on both sides aided by the use of fluoroscopy in the anterior-posterior and lateral views. The skin incision is leveled according to these entry points. The skin incision is about two finger breadth off the midline and about four cm in length.

The index finger is used for blunt dissection of the paraspinal muscles. Then, we try to feel the facet of interest and the one above. We use special retractors or regular Williams retractor for the procedure. After placing the retractor, the C arm was used for confirmation of the correct level and the facet of interest.

Inserting the screws before preparing the disc space helps in opening the disc space by applying distraction on the contralateral screws, especially when the disc space is narrow. Facetectomy is then done by high speed drill or by using a mallet and osteotome. Scalpel is used to open the disc space and the contents were evacuated with pituitary rongeurs. Special instrumentation was used for removal of the cartilaginous end plates. Bone is packed in the floor of the disc space before insertion of the TLIF cage which is also filled with bone to promote fusion. The proper placement of interbody cage is checked by fluoroscopy.

We place the rods and we then tighten the screws in compression to prevent cage migration and to restore the normal lordosis. The wound is closed in layers after irrigation with antibiotic solution. Subfascial drain is rarely used and is removed after 24 hours.

Follow-up questionnaires were then administered postoperatively.

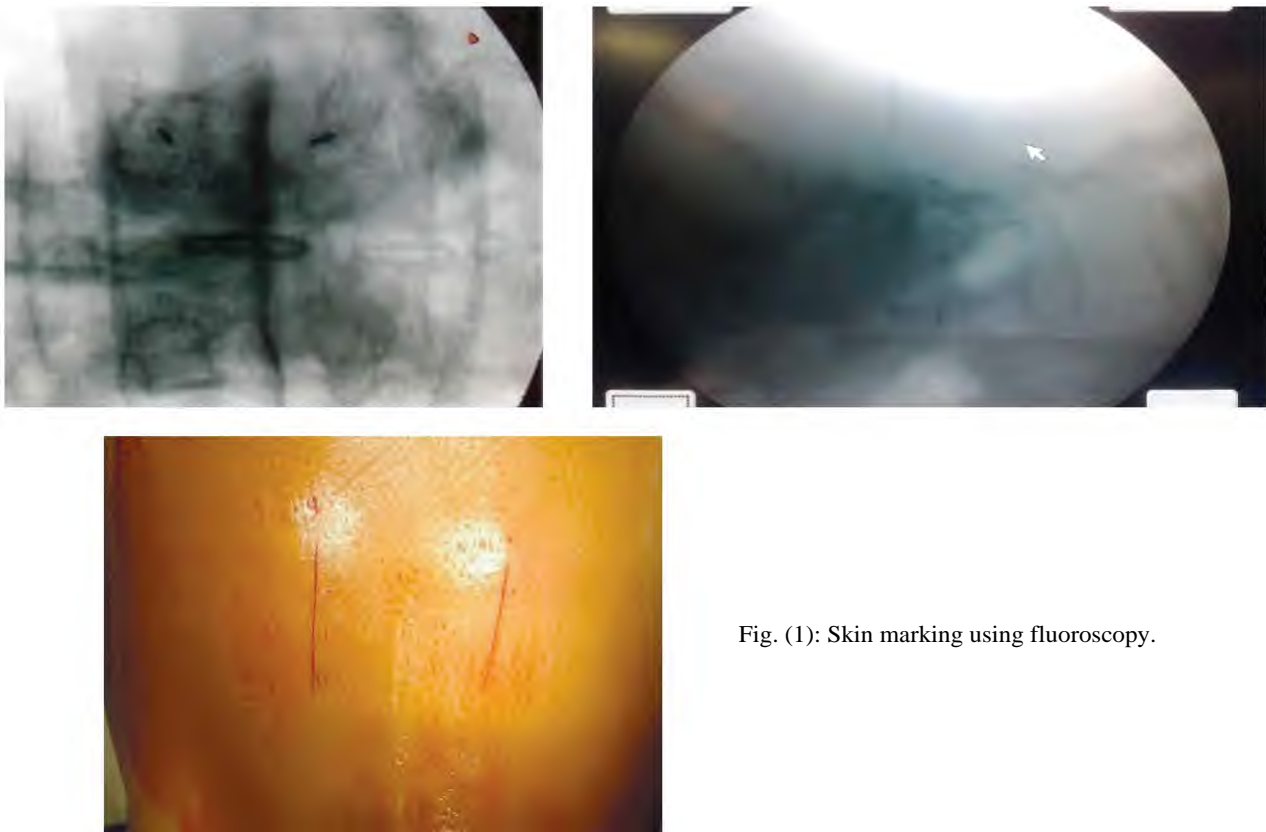


Fig. (1): Skin marking using fluoroscopy.

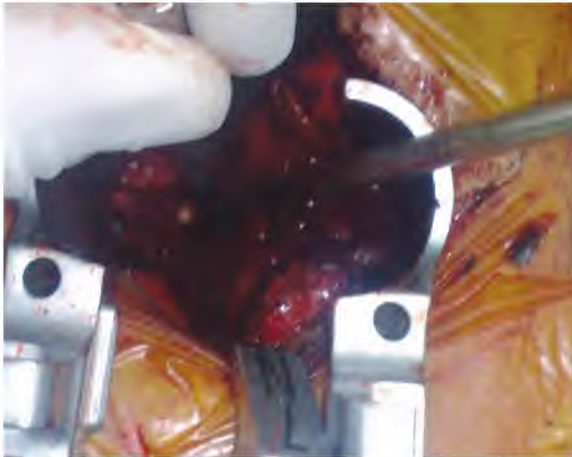

Fig. (2): Intraoperative photo for retractor used in Mini Open technique.



Fig. (3): Intraoperative images for cage insertion. Left: TLIF cage. Middle: Size trial. Right: After insertion of the cage.

Results

28 patients were operated with the youngest was 30 years and the oldest was 71 years old and mean age of 48.29 years. They were 12 male patients (42.9%) and 16 female (57.1%), 16 out of the 28 patients (57.2%) had degenerative spondylolisthesis, 5 patients (17.8%) were diagnosed with degenerative disc disease; 2 of them (7.1%) had

previous operation at the same level and 7 patients (25%) were diagnosed with isthmic type spondylolisthesis.

Eight patients (28.6%) at L5/S1 level and twenty patients (71.4%) were operated at the L4/5 level. The minimum estimated blood loss intraoperative was 150mL and the maximum amount was 300mL, with mean blood loss 251.79mL.

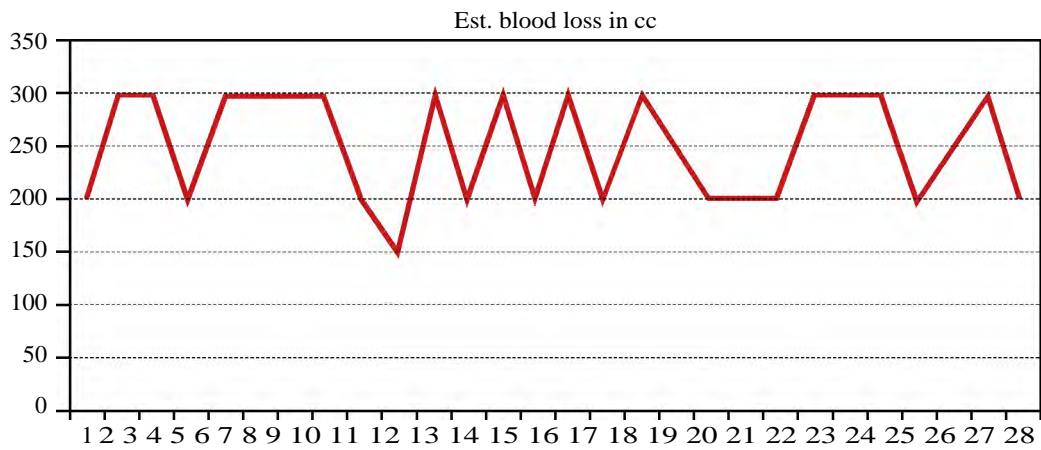


Chart: Intraoperative estimated blood loss.

The minimum hospital stay was 3 days and the maximum was 6 days; with an average hospital stay 4.14 days. The complications were as follows; 1 case of infection (3.6%) after 1 month of good improvement after surgery as symptoms recurred with elevated erythrocyte sedimentation rate and CRP levels. After two months of parenteral antibiotics treatment, symptoms improved and laboratory investigations became normal. One case of adjacent segment disease (3.6%) presented with back pain 18 months after the operation, it was diagnosed by MRI that showed disc degeneration at the level above the fused segment. The patient improved very well with medical treatment and physiotherapy without surgery. We had two cases (7.1%) diagnosed with pedicular screws malposition which were diagnosed with regular postoperative computed tomography. The malposition was not associated with any clinical manifestation and the treatment was conservative.

There was one case of immediate weakness postoperative (grade 3 weakness ankle dorsiflexion) that improved with steroids and regained the full motor power after three months.

Table: Reported complications.

Complications	Frequency	Percent
Adjacent segment failure	1	3.6
Infection	1	3.6
Malposition of screw	2	7.1
Weakness less than 3 months	1	3.6
No	23	82.1
Total	28	100.0

Discussion

The surgical treatment aim in the lumbar spine surgery is to decompress the neural tissue and to stabilize the unstable segments if indicated. This is done with elimination of motion through the facet joint and the intervertebral disc with fusion [4,5]. All fusion techniques are augmented with instrumentation (posterior pedicle screws, anterior plates and cages for interbody fusion) [6]. Posterolateral fusion is done with conventional midline posterior approach with decortication of facets, transverse process and pars to enhance fusion using allo or autograft bone, and then augmented with transpedicular screws [6]. However, persistence of discogenic pain was reported and explained by the micromotion present in the involved disc. Because of this reason in addition to the fact that lumbar vertebral body account for most of surface area and support load to the spine, interbody fusion is

preferred to be done for better correction and maintenance of sagittal and coronal plane [7].

This technique has minimal blood loss intraoperative, shorter surgery time and shorter hospital stay and is accompanied with early ambulation. The minimum intraoperative blood loss was 150mL and the maximum was 300mL, with mean blood loss 251.79mL. Wang et al. [8] reported that the average intraoperative blood loss was 264±89mL and Tangviriyapaiboon [2] reported 398.3mL. Our results were slightly more than Oh et al. [9] who reported 163mL, [10] 194mL and 150mL. [11].

The complications in our study were: (1 infection that responds well to antibiotic, 1 case with adjacent segment disease, 2 cases with screw malposition, and 1 case with temporary weakness). After reviewing other authors' results, the overall complications of this procedure were acceptable that means that the mini-open TLIF operation is safe to treat degenerative lumbar spine diseases in selected cases [2,8,10].

Conclusion:

Our study showed that the Mini-TLIF approach is an efficient and safe approach for treating instability and degenerative diseases of the lumbar spine. It has very good safety profile with acceptable complication rate.

References

- 1- KIM K.T., LEE S.H., SUK K.S. and BAE S.C.: The quantitative analysis of tissue injury markers after mini-open lumbar fusion. *Spine*, Mar. 15; 31 (6): 712-6, 2006.
- 2- TANGVIRIYAPAIBOON T.: Mini-open transforaminal lumbar interbody fusion. *J. Med. Assoc. Thai.*, Sep 1; 91 (9): 1368-76, 2008.
- 3- HOLLY L.T., SCHWENDER J.D., ROUBEN D.P. and FOLEY K.T.: Minimally invasive transforaminal lumbar interbody fusion: Indications, technique, and complications. *Neurosurgical focus*, Mar. 1; 20 (3): 1-5, 2006.
- 4- WEINSTEIN J.N., LURIE J.D., TOSTESON T.D., HANSCOM B., TOSTESON A.N., BLOOD E.A., BIRKMEYER N.J., HILIBRAND A.S., HERKOWITZ H., CAMMISA F.P. and ALBERT T.J.: Surgical versus nonsurgical treatment for lumbar degenerative spondylolisthesis. *New England Journal of Medicine*, May 31; 356 (22): 2257-70, 2007.
- 5- YAN D.L., PEI F.X., LI J. and SOO C.L.: Comparative study of PILF and TLIF treatment in adult degenerative spondylolisthesis. *European Spine Journal*, Oct. 1; 17 (10): 1311, 2008.
- 6- BONO C.M. and LEE C.K.: Critical analysis of trends in fusion for degenerative disc disease over the past 20 years: Influence of technique on fusion rate and clinical outcome. *Spine*, Feb. 15; 29 (4): 455-63, 2004.

- 7- BARRICK W.T., SCHOFFERMAN J.A., REYNOLDS J.B., GOLDTHWAITE N.D., MCKEEHEN M., KEANEY D. and WHITE A.H.: Anterior lumbar fusion improves discogenic pain at levels of prior posterolateral fusion. Spine, Apr. 1; 25 (7): 853-7, 2000.
- 8- WANG J., ZHOU Y., ZHANG Z.F., LI C.Q., ZHENG W.J. and LIU J.: Comparison of one-level minimally invasive and open transforaminal lumbar interbody fusion in degenerative and isthmic spondylolisthesis grades 1 and 2. European Spine Journal, Oct. 1; 19 (10): 1780-4, 2010.
- 9- OH C.H., HYUN D., YOON S.H. and PARK H.: Mini-open and conventional-open transforaminal lumbar interbody fusion augmented by pedicle screw fixation: Comparative result of clinical, perioperative parametric, functional and radiological assessments. J. Spine, 2 (136): 2, 2013.
- 10- PENG C.W., YUE W.M., POH S.Y., YEO W. and TAN S.B.: Clinical and radiological outcomes of minimally invasive versus open transforaminal lumbar interbody fusion. Spine, Jun. 1; 34 (13): 1385-9, 2009.
- 11- SALEHI S.A., TAWK R., GANJU A., LAMARCA F., LIU J.C. and ONDRA S.L.: Transforaminal lumbar interbody fusion: Surgical technique and results in 24 patients. Neurosurgery, Feb. 1; 54 (2): 368-74, 2004.

دراسة مرجعية لمعدل المضاعفات المصاحبة للتدخل المحدود للإلتحام بين أجسام الفقرات القطنية ؛ خبرة مؤسسة واحدة

هناك العديد من الأمراض التي قد تصيب المنطقة القطنية بالعمود الفقري ومنها حالات الانزلاق الغضروفي، ضيق القناة العصبية وقنوات مخارج الأعصاب، وأيضاً حالات تزلج الفقرات القطنية بأسبابها المختلفة. هذه الأمراض قد تسبب العديد من الأعراض لدى المرضى ومنها الام مزمنة بأسفل الظهر والام بالساقين. وقد استعدت هذه الأمراض لظهور وتطور العديد من الطرق التي استهدفت توسيع القناة العصبية وتخفيف الضغط حول جذور الأعصاب وأيضاً التحام الفقرات القطنية في حالات عدم استقرار العمود الفقري نتيجة بعض الأمراض التي تصيب المنطقة. القطنية أو المتوقعة من بعض التدخلات الجراحية للمنطقة القطنية.

وقد قدم هذا البحث دراسة لأحدى الطرق الحديثة المستخدمة لالتحام الفقرات القطنية وذلك من خلال فتح جراحي محدود على جانبي منتصف المنطقة القطنية باستخدام أقفاس توضع ما بين أجسام الفقرات للمساعدة على الالتحام فيما بينها والتي يتم وضعها من خلال قنوات مخارج الأعصاب مع تثبيت للحركة بين الفقرات باستخدام مسامير عنق الفقرات.

وقد بينت هذه الدراسة من خلال النتائج التي تحققت وتفنيد المشا كل المصاحبة لهذا التدخل. فاعليته في تحقيق نسب جيدة في معدلات التحسن لدى المرضى.

وقد تميز هذا النوع من التدخل الجراحي عن غيره في أنه لا يحتاج في معظم الحالات لنقل الدم للمرضى أثناء الجراحة، الحركة المبكرة للمرضى من الفراش بعد الجراحة ونسب عالية من الرضى لدى المرضى عن معدلات الألم المحتملة بعد الجراحة وأيضاً عن الفتح الجراحي الصغير الناتج عن هذا النوع من التدخل.