**Original Paper**

The potential ameliorative mechanisms of spirulina platensis or grape seed proanthocyanidin extract against thyroid disruptors and epigenetic micro- RNA derangements in L-thyroxine -induced hyperthyroidism in rats

Samy A. Hussein¹, Samir A. Abdel- Aal², Mohammed A. Marzouk¹, Marwa Darweish³, Asmaa H. A. Hussain¹

¹ Department of Biochemistry, Faculty of Veterinary Medicine, Benha University, Egypt.

² Department of Animal, poultry and environmental hygiene, Faculty of Veterinary Medicine, Benha University, Egypt.

³ Department of Pathology, Faculty of Veterinary Medicine, Benha University, Egypt.

ARTICLE INFO**Keywords**

Hyperthyroidism
GSPE
Spirulina
Thyroid hormones
Micro-RNA

Received 15/07/2022

Accepted 06/09/2022

Available On-Line
01/10/2022

ABSTRACT

An excessive amount of thyroid hormone is produced by an overactive thyroid gland, which keeps the body active. This study was carried out to investigate how hyperthyroidism-prompted liver damage and apoptosis could be alleviated with spirulina platensis and grape seed proanthocyanidin extract in rats. Forty-eight male rats were divided into six groups. Group 1: received no drug. Group2 (hyperthyroidism): Rats received L-Thyroxine at dose of (50, 100, 200 ug/kg b.wt) orally for first three weeks of study, respectively. Group3 (GSPE Protected): Rats received GSPE (150/kg b. wt/day) for the first 3 weeks, then continued administered with L-Thyroxine for other 3 weeks. Group 4 (GSPE treated): Rats administered a daily dose of L-Thyroxinen for 3 weeks, followed by GPSE (150/kg b. wt/day) for another 3 weeks. Group 5 (Spirulina Protected); Rats received Spirulina and L-Thyroxine as in group III. Group 6 (Spirulina treated): Rats received Spirulina and L-Thyroxine similar to group IV. The data obtained demonstrated a substantial rise in serum T3 and T4 with marked decrease in TSH concentrations in hyperthyroid rats. A significant upregulation in miRNA 224 and downregulation in liver Protein kinase C alpha and miRNA 382 were observed in hyperthyroid rats. However, a significant decrease in T3, T4 and miRNA 224 with significant upregulation of miRNA 382 and PKC α and TSH level were observed after Spirulina and GSPE treatment and protection. In conclusion, GSPE and Spirulina platensis had a potential therapeutic and protective effect in Hyperthyroidism, through direct inactivation of T4 to T3 and mitigate micro-RNA and PKC α that essential for thyroid hormone homeostasis and thyroid functions.

1. INTRODUCTION

Hyperthyroidism induces a hyper-metabolic state characterized by decrease cholesterol levels, increase lipolysis, and enhanced gluconeogenesis while hypothyroidism is characterized by increased cholesterol levels, decreased lipolysis, and decreased gluconeogenesis (Cicatiello et al., 2018). According to (Işman et al., 2003), hyperthyroidism is a hypermetabolism caused by elevated free T4 and/or free T3 serum levels. This hypermetabolic oxidative stress is brought on by a rise in the prooxidant to antioxidant ratio in a condition (Hashem, 2016). People who have hyperthyroidism may develop widespread health issues like cardiovascular illnesses (heart failure and increased risk of heart attack), diabetes mellitus, oxidative damage to the liver and osteoporosis.

Spirulina (SP) is regarded as a top-notch dietary supplement with numerous health advantages. There are plenty of proteins, carotenoid (β -Carotene), polyunsaturated fatty acids, glycolipids, polysaccharides, vitamins A, E, and B, as well as iodine, calcium, magnesium, manganese, potassium, zinc, and iron (Hoseini et al., 2013). Spirulina contains phycocyanin, a strong antioxidant that gives spirulina its rich

green hue. (Lissi et al., 2000). Spirulina is well documented for its clinical importance in diabetes, hypertension, and cancer (Palaniswamy and Veluchamy, 2018), besides its antioxidant, immune-modulating, anti-microbial (Finamore et al., 2017), and radio-protective properties Ibrahim (2014). Many woody plants, including grape seeds and white pine, contain pro-anthocyanidins (PAs), oligomers and polymers of monomeric flavonoids. In comparison to vitamins C, E, and -Carotene, grape seed pro-anthocyanidins extract (GSPE) PAs exhibited much better protection against oxygen free radicals and have a wide range of biological, pharmacological, and chemo-protective activities. (Bagchi et al., 2002). GSE has a major role in free radicals' resistance that led to oxidative stress (Vayuphar and Laksanalamai, 2012), as well as protecting cells from the Effects of toxic substances (Sharma, 2004). Several studies have been shown that through scavenging superoxide and hydroxyl radicals, PAs exhibit strong antioxidant and anticancer activity, as well as the ability to avoid liver and kidney damage brought on by drugs (Engelbrecht et al., 2007). Therefore, the aim of this study is to assess the potential

* Corresponding author: elasal_81@yahoo.com

protective mechanisms of grape seed pro-anthocyanidin extract and *Spirulina platensis* against thyroxine-induced hyperthyroidism in rat model.

2. MATERIAL AND METHODS

2.1 experimental Animals

In this investigation, 48 male rats weighing 140–160 g and aged 8–12 weeks were used. The animals were obtained from laboratory Animals Research Centre, Faculty of Veterinary Medicine, Benha University and kept in separate metal cages under constant environmental and dietary circumstances. Rats were given a consistent ration of food, and unlimited access to fresh, clean drinking water was provided. Prior to the start of the trial, all rats underwent an acclimatisation phase lasting a minimum of 15 days. Experiment was conducted according to the guide for care of laboratory animals approved by the ethical animal committee of Benha university (Approval no. BUFVTM 02-8-21).

2.2 Chemical and Antioxidant agents

2.2.1. Chemicals

L-Thyroxine (Eltroxin)[®]: Thyroxine (Eltroxin)[®] 50 ug tablets, was obtained from GlaxoSmithKline GmbH, Germany. Rat model of the hyperthyroid received L-Thyroxine (Eltroxin)[®] at dose of (50, 100, 200ug/kg b.wt) orally for one, two and the three weeks of study, respectively (Guerrero et al., 1999).

2.2.2. Antioxidant compounds

2.2.2.1 spirulina platensis:

Pure *Spirulina platensis* powder was kindly obtained from (National Research Centre, Dokki, Egypt). Rats received 1.0 mL of a distilled water suspension containing 300 mg/kg body weight of spray-dried spirulina platensis powder. (Simsek et al., 2009).

2.2.2.2 Grape Seed Proanthocyanidin Extract:

Grape Seed Pro-anthocyanidin (GSPE) was purchased from Al Debeiky Pharma Company for Pharmaceutical industries, Al Obour, Cairo, Egypt. Yamakoshi et al. (2002) gave the GSPE orally at a dose of 150 mg/kg b.wt (Yousef et al., 2009). GSPE was dissolved in DMSO 7 percent and diluted to the appropriate concentration with sterile saline solution to create the GSPE solution. (Mona A. El-Gawish et al., 2006).

2.4 Experiment Design

After 2 weeks of acclimatization, the rats were randomly divided into 6 equal groups (n = 8 rats per group) as following:

Group 1 (Normal control): received no drug.

Group 2 (hyperthyroidism): Rats received L-Thyroxine (Eltroxin)[®] at dose of (50, 100, 200ug/kg b.wt) orally for one, two and the three weeks of study, respectively..

Group 3 (GSPE + hyperthyroid Protected): Rats received GSPE (150/kg b. wt/day) for the first 3 weeks, then continued administered with Eltroxin for other 3 weeks.

Group 4 (GSPE+ hyperthyroid treated): Rats administered a daily dose of L-Thyroxine (Eltroxin)[®] at dose of

(50, 100, 200ug/kg b.wt) orally for one, two and the three weeks of study, respectively, followed by GPSE (150/kg b. wt/day) for other 3 weeks.

Group 5 (Spirulina + hyperthyroid Protected): Rats received Spirulina (300mg/kg b.wt /day) for the first 3 weeks, then continued with administered with Eltroxin for other 3 weeks.

Group 6 (Spirulina+ hyperthyroid treated): Rats administered a daily dose of L-Thyroxine (Eltroxin)[®] at dose of (50, 100, 200ug/kg b.wt) orally for one, two and the three weeks of study, respectively, followed by Spirulina (300/kg b. wt/day) for other 3 weeks.

2.5 Sampling

2.5.1 Blood samples

Blood samples for serum separation were collected by ocular vein puncture at the end of the experimental period and after overnight fasting in dry, clean, and screw capped tubes and serum was separated by centrifugation at 2500 r.p.m for 15 minutes. The clean, clear serum was separated by Automatic pipette and received in dry sterile samples tube, then kept in a deep freeze at -20 ° C until used for subsequent biochemical analysis. All sera were analysed for the following parameters: Triiodothyronine (T3), Thyroxin (T4) and Thyroid stimulating hormone (TSH).

2.5.2 Tissue specimens

At the end of experiment (6 weeks), Rats were sacrificed by decapitation after blood was obtained, and their abdomens were subsequently opened so that liver could be collected.

A- For molecular analysis

All animal species' liver tissues were taken, placed in Eppendorf tubes, and immediately frozen in liquid nitrogen before being held at -80°C for RNA extraction of PKC α , Micro- 224 and MicroRNA 382 gene expression and DNA damage by comet assay. DNA damage analysis through single cell electrophoresis (comet assay).

B-For Histopathological examination (thyroid and liver)

Histopathological analysis of thyroid and livers' tissue specimens treated in neutral buffered formalin solution at 10% according to (Bancroft and Gamble, 2008). After proper fixation, the samples were dehydrated in ascending grades of ethyl alcohol, then cleared in xylol, embedded in paraffin and finely blocking occurred. These samples were sectioned at 5 μ m in thickness and stained with hematoxylin and eosin (H and E) for microscopical examination.

2.6 Analysis

2.6.1 Biochemical analysis

Using an ELISA kit, a solid phase enzyme immunoassay was used to quantitatively measure the levels of serum TSH and T4 (XEMA. Co) with a catalog No.: K2011 and K212I, respectively. However, serum T3 was done by an Electrochemiluminescence (ECLIA) immunoassay and carried out using (Cobase 801 immunoassay analyzer) with code number: 10032.

2.5.2 Molecular analysis (Liver)

Real-time qPCR analysis was used to assess the PKC α mRNA expression in rat liver. The load was managed with β -actin. According to the manufacturer's recommendations, total RNA was extracted from the liver using the High Kit for extraction of pure RNA (Thermo Scientific, Fermentas,

#K0731) RNA Extraction kit. RevertAid™ First Strand CDNA synthesis kit (#EP0451, Thermo Scientific, Fermentas, USA) was used to reverse transcribe each cDNA sample. Then, using the Faststart Universal SYBR Green

Master, real-time quantitative PCR amplification was carried out (Roche, GER). Using the 2-Ct technique, the target gene was normalised with β-actin (Livak and Schmittgen, 2001) (Table, A).

Table A Forward and reverse primers sequence used in qPCR.

Gene	Forward primer (5'→3')	Reverse primer (5'→3')
PKCα	TTTGTACTTCTCTTGTCGGGT	ACATTCATGTCGCAGGTGTCGA
B-actin	AAGTCCCTCACCTCCAAAAG	AAGCAATGCTGCACCTTCCC

miR-224 and miRNA382 were determined using Real-time PCR with SYBR Green was used to measure expression of miRNAs in the liver, with U6 as an internal reference. The isolated cDNA was amplified using 2X Maxima SYBR

Green/ROX qPCR Master Mix following the manufacturer protocol (Thermo scientific, USA, # K0221) and miRNA specific forward primer (Table, B) and a universal reverse primer included with the purchase Quanti-Mir RT kit.

Table B: Forward and reverse primers sequence used in qPCR.

Gene	Primer sequence (5'-----/3')
miRNA224	CAAGTCACTAGTGGTTCGGTT
miRNA382	GAAGTTGTTCTCGTGGTGGATTCC
U6	TGACACGCAAATTCGTGAAGCGTTC
Universal reverse primer	CCAGTCTCAGGGTCCGAGGTATTCC

2.5.3 DNA fragmentation analysis (Comet assay)

Following various treatments, the comet assay was used to check for potential DNA damage. The movement of DNA from immobilized nuclear DNA is measured in order to identify DNA strand breaks and alkali labile spots. The comet assay was carried out in the current investigation in accordance with the instructions provided by Singh et al. (1988).

2.5.4 Statistical analysis

The data were all given as Mean ± S.E Comparisons between the groups were performed by using one-way analysis of variance (ANOVA), and Duncan's multiple range test was used to compare the means. SPSS, version 18.0 software was

used. When the value of p was ≤ 0.05, the differences were considered statistically significant.

3. RESULTS

A significant decrease in serum TSH with increase T3 and T4 concentrations were observed in L-Thyroxine (Eltroxin)^R induced hyperthyroidism when compared with normal control group. Treatment and protection with GSPE (G4), spirulina (G6) to L-Thyroxine induced hyperthyroidism in rats exhibited a significant increase in TSH with decrease T3 and T4 as compared with L-Thyroxine induced hyperthyroidism group Table (1) and Figures (1,2,3).

Table 1 Effect of protection and treatment with Spirulina or GSPE on serum TSH, T3 and T4 concentrations of Eltroxin-induced hyperthyroidism in rats

Animal groups	TSH (nU/ml)	T3 (pg/ml)	T4 (pg/ml)
Control non treated(G1)	4.34 ^a ±0.14	4.42 ^e ±0.10	6.34 ^e ±0.17
Hypothyroidism(G2)	2.33 ^e ±0.08	8.65 ^a ±0.26	9.77 ^a ±0.22
Hypothyroidism+ GSPE protection(G3)	3.27 ^e ±0.10	5.14 ^e ±0.18	7.84 ^e ±0.14
Hypothyroidism + GSPE treatment(G4)	2.90 ^d ±0.09	6.58 ^b ±0.19	8.83 ^b ±0.20
Hypothyroid+ spirulina protection(G5)	3.80 ^d ±0.10	4.80 ^d ±0.11	6.92 ^d ±0.11
Hypothyroidism+ spirulina treatment(G6)	2.78 ^d ±0.09	5.39 ^d ±0.17	8.02 ^e ±0.19

Data are presented as (Mean ± S.E). S.E = Standard error. Mean values with different superscript letters in the same column are significantly different at (P≤ 0.05)

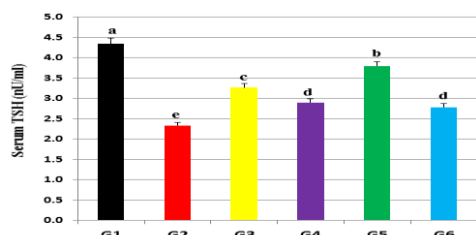


Fig (1) Effect of Spirulina or GSPE treatment on serum TSH concentration in experimental model of hyperthyroidism in rats.

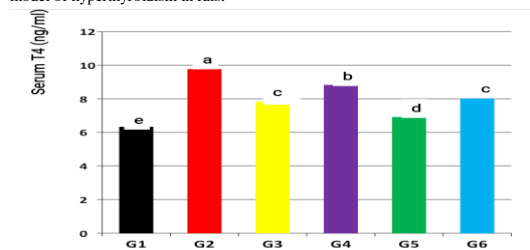


Fig (2) Effect of Spirulina or GSPE treatment on serum T4 concentration in experimental model of hyperthyroidism in rats.

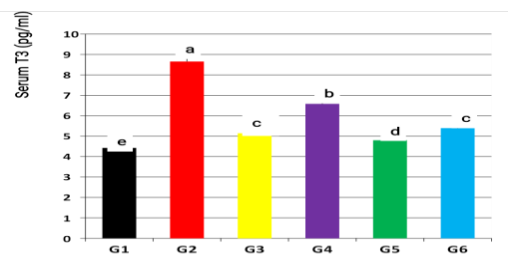


Fig (3) Effect of Spirulina or GSPE treatment on serum T3 concentration in experimental model of hyperthyroidism in rats.

3.4 Molecular Parameters

A significant downregulation in miRNA 382 and PKCα gene expression, and upregulation in miRNA 224 were observed in thyroxine-induced hyperthyroidism when compared with normal control group. Treatment and protection with GSPE(G4), spirulina (G6) and protection with GSPE(G3), spirulina (G5) to Thyroxine-induced hyperthyroidism in rats exhibited a significant down regulation in miRNA 224 with a significant upregulation in miRNA 382 and PKCα gene

expression as compared to the Thyroxine-induced hyperthyroidism group Table (2) and Figures (4,5,6).

Table 2 Effect of protection and treatment with Spirulina or GSPE on liver tissue miRNA 224, miRNA 383 and PKCa gene expressions of Eltroxin-induced hyperthyroidism in rats

Animal Groups	MirRNA 224	MirRNA 382	PKCα
Control non treated (G1)	1.00± 0.08	1.00±0.05	1.00±0.06
Hypothyroidism (G2)	10.78 ^a ±0.52	0.08 ^e ±0.01	0.30 ^d ±0.02
Hypothyroidism+ GSPE protection (G3)	4.66 ^a ± 0.16	0.50 ^e ±0.03	0.73 ^b ±0.04
Hypothyroidism + GSPE treatment (G4)	8.06 ^b ± 0.34	0.18 ^d ±0.01	0.52 ^c ±0.03
Hypothyroid+ spirulina protection (G5)	3.63 ^e ±0.15	0.74 ^b ±0.04	0.99 ^a ±0.06
Hypothyroidism+ spirulina treatment (G6)	6.63 ^c ±0.23	0.42 ^c ±0.02	0.56 ^c ± 0.03

Mean values with different superscript letters in the same column are significantly different at (P<0.05).

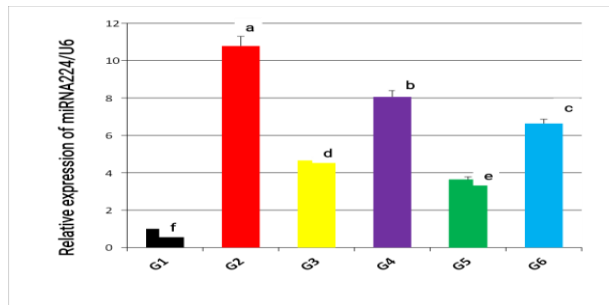


Fig (4) Effect of Spirulina or GSPE treatment on miRNA 224 gene expression in experimental model of hyperthyroidism in rats.

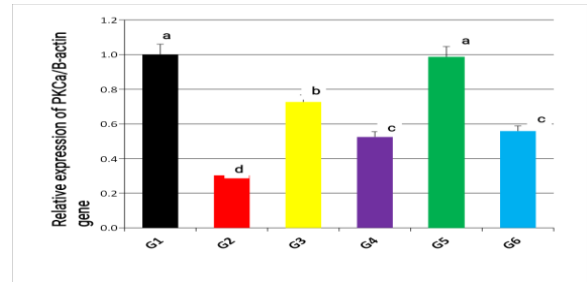


Fig (6) Effect of Spirulina or GSPE treatment on PKCa gene expression in experimental model of hyperthyroidism in rats

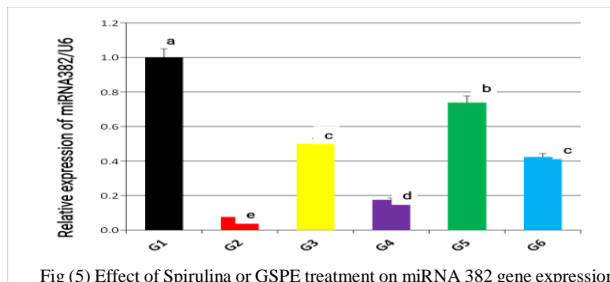


Fig (5) Effect of Spirulina or GSPE treatment on miRNA 382 gene expression in experimental model of hyperthyroidism in rats

Comet assay (DNA damage in liver tissue)

DNA damage in the rat liver following administration of Eltroxin and the treatment and protective effect of Spirulina or GSPE administrations was evaluated by comet assay. The comet assay results, which are shown in Table (3) and Figure (7), revealed that Eltroxin treatment significantly increased DNA damage, as evidenced by an increase in tail length and tail DNA percentage in the liver tissue of hyperthyroid rats compared to the normal control group. Spirulina or GSPE treatment and protection significantly reduced DNA damage compared to the hyperthyroidism control group. Furthermore, a significant decrease in DNA damage was noticed in G4 and the highest decrease in G5.

Table 3 Comet assay parameters obtained by image analysis in rat liver following treatment

Animal Groups	Tailed (%)	Untailed (%)	Tails length (μm)	Tail DNA (%)	Tail moment
Control non treated (G1)	1.5	98.5	1.01 ^f ±0.09	1.28	1.29
Hypothyroidism (G2)	29	71	9.13 ^a ±0.40	7.87	71.62
Hypothyroidism+ GSPE protection (G3)	12	88	4.19 ^d ±0.13	4.13	17.30
Hypothyroidism + GSPE treatment (G4)	22	78	7.00 ^b ±0.42	6.25	43.25
Hypothyroid+ spirulina protection (G5)	8	92	2.72 ^e ±0.12	3.06	8.32
Hypothyroidism+ spirulina treatment(G6)	16	84	5.82 ^c ±0.21	4.69	27.30

Means ± S.E within the same column of tail length carrying different superscript letters are significantly different (P< 0.05) at each time point.

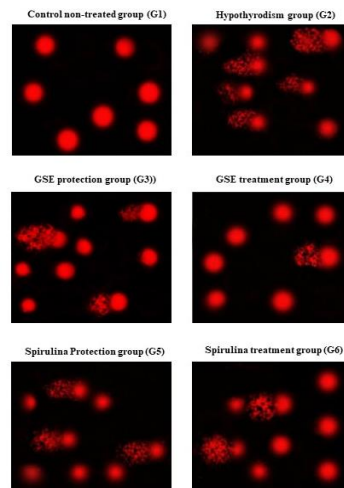


Fig (7) Photomicrographs representation of liver DNA damage, using comet assay, in Eltroxin administered rats following treatment with Spirulina or GSPE

Histopathological Findings

The microscopic examination of thyroid gland in control group showed normal architecture of gland with low cuboidal epithelium and eosinophilic colloid (Fig.8a). Hyperthyroidism group showed excessive secretion of some follicles with flattened epithelium while some showed deep eosinophilic secretion (Fig.8b). In Spirulina protected group, the thyroid follicles were lined with cuboidal epithelium with eosinophilic secretion in some follicles with other showed detached follicular epithelium in the colloid while some showed hyperplastic epithelium (Fig.8c). The examined thyroid of rats in Spirulina treated group showed mostly normal follicles while some are empty from colloid (Fig.8d). In grape seed protected group the examined thyroid follicles showed papillary projection with excessive secretion (Fig. 8e). Grape seed treated group showed empty follicles with hyperplasia of most follicular epithelium with absence of colloid (Fig. 8f).

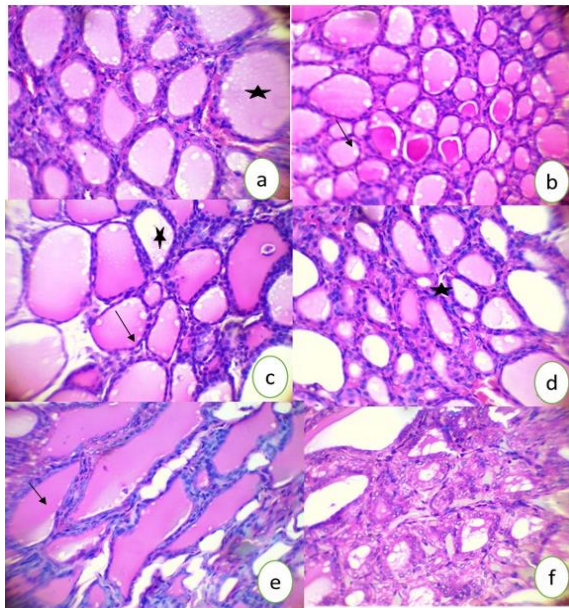


Fig (8) Histopathological finding of thyroid gland in control group a: showed normal architecture of thyroid follicles lined with low cuboidal epithelium and eosinophilic colloid. Hyperthyroidism group b: showed excessive secretion of some follicles with flattened epithelium (star) while some showed deep eosinophilic secretion (arrow). Spirulina protected group c: showed cuboidal epithelium with eosinophilic secretion in some follicles with other showed detached follicular epithelium in the colloid (star) while some showed hyperplastic epithelium (arrow). Spirulina treated group d: showed mostly normal follicles while some are empty from colloid (star). grape seed protected e: showed papillary projection with excessive secretion. Grape seed treated group showed empty follicles with hyperplasia of most follicular epithelium that free from colloid H&E 400 x.

Moreover, Histopathological finding of liver in control group showed normal architecture of hepatic tissue (fig. 9a). Hyperthyroidism group showed congestion of portal blood vessels with mild leucocytic cellular infiltration around bile duct with newly formed bile ductules while hepatocytes showed severe hydropic degeneration with micro-vesicular steatosis (Fig. 9b). Spirulina protected group showed hydropic degeneration with pyknotic nuclei (fig. 9c). Spirulina treated group congested blood vessels with presence of fat vacuoles inside hepatocytes (fig. 9d). In grape seed protected group, the examined liver showed congestion of portal blood vessel with vascular degeneration of hepatocytes (Fig. 9e). While the liver in grapeseed treated showed normal hepatic cords with some pyknotic nucleus (Fig. 9f).

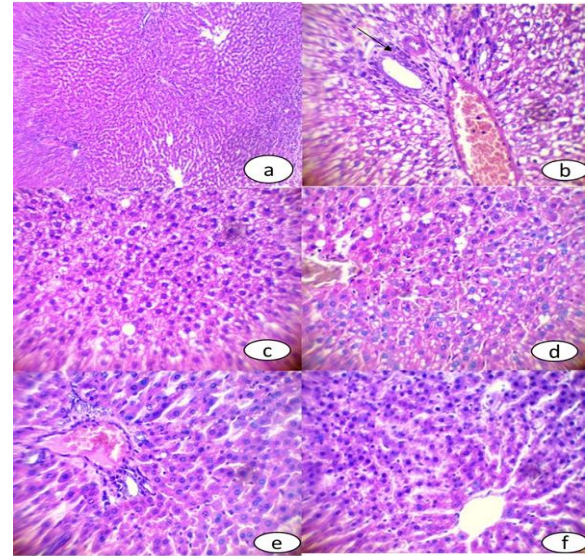


Fig (9) Histopathological finding of liver in control group a: showed normal architecture of hepatic tissue H&E 100. Hyperthyroidism group b: showed congestion of portal blood vessels with mild leucocytic cellular infiltration around bile duct with newly formed bile ductules (arrow) while hepatocytes showed sever hydropic degeneration with minute fatty changes. Spirulina protected group c: showed hydropic degeneration with pyknotic nuclei. Spirulina treated group d: congested blood vessels with presence of fat vacuoles inside hepatocytes. Grape seed protected group e: congestion of portal blood vessel with vascular degeneration of hepatocytes. Grape seed treated f: normal hepatic cords with many pyknotic nucleus. H&E 400.

4- DISCUSSION

Thyroid hormones (THs), T4 and T3, are released by the thyroid gland and act at the cellular level. Seleno-protein iodothyronine deiodinases (DIO) are crucial for THE intracellular action because they locally convert T4 into T3, rT3 (reverse triiodothyronine), or T3 in T2 (Bianco et al., 2006). Finally, T3-modulated transcription factors called thyroid hormone nuclear receptors (TRs) can bind DNA regions known as thyroid hormone Responsive Elements (TREs) to control the transcription of target genes (Brent et al., 2012). The obtained results showed that TXN-induced hyperthyroidism in rats was associated with a considerable rise in serum T3, and T4 with marked decrease in TSH concentrations. Like this, Kim et al. (2019) reported that TXN injection caused a notable rise in the blood T3, and T4 levels and decrease in TSH level in hyperthyroidism throughout the first two weeks of postnatal life of cerebellar development. Also, Hammad et al. (2021) exhibited significant increase of the thyroid hormones in rats given thyroxine at a dose of 25µg/day. Likewise, Ramadan et al. (2021) mentioned that animal injected with L-thyroxine at different doses (0.2; 1; 5; or 10 mg/kg b.wt) for 21 days showed a marked increase in serum T4, T3 and levels in hyperthyroidism group, while TSH level was decreased obviously. Furthermore, Sergalieva et al., (2022) reported that, an increase of T4 and T3 with decrease in TSH, concentration was observed after TXN administration. The current study showed that treatment and protection with GSPE or spirulina to hyperthyroid rats exhibited a marked decrease in T3 and T4 and increase in TSH concentration as compared with hyperthyroid non-treated group. This result came in accordance with Albrahim et al. (2020) who reported that GSE treatment to Eltroxin-induced hyperthyroid mice significantly normalize elevated T3 and T4 levels as well as normalizing the lower TSH level (Belcaro et al., 2022). The presence of phenolic compounds, particularly pro-anthocyanidins, which have a higher antioxidant capacity than vitamin C or E, contributes to its

ability to scavenge oxidants and free radicals (Romanelli et al., 2021). Also, Al-Naely et al. (2018) reported that grape seed extract (GSE) interferes with drug showed improved performance in thyroid hormone levels and normalized TSH in the experimental groups.

Treatment and protection with Spirulina and GSPE significantly decreased serum TSH concentration in hyperthyroid rats. So, confirming the anti-hyperthyroidism activity of GSPE extract and Spirulina. Similarly, Ebrahim et al. (2020) and Martins et al. (2021) showed that rats with hyperthyroidism had considerably decreased serum levels of T3, T4, and TSH when spirulina was given to them orally. Additionally, Atiglan et al. (2022). T3 and T4 levels in rats with TXN-induced hyperthyroidism were shown to be lower following treatment with spirulina and GSE. Furthermore, according to Mandel and Cooper (2001), the synthesis of the thyroid hormones T3 and T4 is prevented by MMI because it inhibits the incorporation of iodine into thyroglobulin (TG) tyrosyl residues and the coupling of iodotyrosyl residues to produce iodothyronine. Grape seed has the potential resistance against the negative role of TXN Inhibiting the factors that produce T4 and T3 Hasona et al. (2018) showed that the harmful effects of oxidative stress were greatly reduced by the administration of GSE. The containing of the flavonoids may explain the reasons after the elevation of T4 over T3 in liver, is the potential of inhibiting the and deiodinase D1 enzyme that enhances the conversion of T4 to T3 in liver of rats treated with GSPE after L-Thyroxine-induced hyperthyroidism.

A significant upregulation in liver miRNA 224 and downregulation in miRNA 382 were observed in TXN-induced hyperthyroidism group. Similarly, Peixoto et al. (2021) found that miRNA 224 action showed the long-term effects of early nicotine exposure (6 mg/Kg b.wt), which acts as Thyroid hormones elevator like L-Thyroxine. In the liver, nicotine offspring showed lower Higher miR-224 expression and type 1 deiodinase (DIO1) mRNA expression are involved. Treatment and protection of hyperthyroid rats with GSPE and spirulina resulted in a considerable downregulation of miRNA 224 expression and an overexpression of miRNA 382. The amount of miR-382-5p was discovered to be elevated in HCC tissues, as demonstrated by Nie et al. (2021). Protein Kinase C alpha (PKC α) showed a significant downregulation in hyperthyroid rats. Similarly, Tian et al. (2022) confirmed that 2, 2'-dipyridyl disulphide administration lowered thyroid hormone levels, has significantly increased the gene expression of PKC, here as the hormones increase, the level of PKC α expression is decrease. However; Costilla et al. (2019) indicated the impact of Contrary to our predictions, the increased expression of isoenzymes of PKC α , β and γ . revealed the ROS effect on PKCs during hyperthyroidism. Hyperthyroidism on the regulation of the cellular antioxidant system and showed the increased ROS found in hyperthyroidism induces antioxidant enzyme transcription through the activation of the Nrf-2 factor in lymphoid tissues. When compared to hyperthyroid animals, the GSE plus spirulina treatment significantly increased the expression of PKC. Similar to this, Lei et al. (2022) discovered that spirulina therapy led to PKC upregulation. The hepatic DNA damage and apoptosis evaluate the potential efficacies of L-Thyroxine and/or GSE or Spirulina in ameliorating the hyperthyroidism induced hepatic DNA fragmentation. Comparing hyperthyroid rats to control rats, there was a clear increase in DNA tail percentage and tail moment. The DNA tail percentage and tail moment decreased as a result of the protection with GSPE and spirulina, in contrast. Likewise, Alnahdi et al. (2018)

showed an elevated in the hepatic apoptosis enzyme, caspase 3 in the liver of hyperthyroid rats, suggesting that apoptosis may be linked to hyperthyroid DNA fragmentation. Hyperthyroidism can cause apoptosis by increasing the production of many death receptors and their ligands, including TNF- α and FasL, resulting in the activation of caspases, which play a major role in apoptotic cell death. Administration of GSE and/or Spirulina to hyperthyroidism rats, effectively decreased caspase-3 (Alnahdi et al., 2018). So, the amelioration of apoptosis was more pronounced in hepatic of hyperthyroidism rats supplemented with Spirulina simultaneously with GSE. Spirulina and/or GSE administration to hyperthyroid rats clearly reduced hepatic caspase-3 activity compared to untreated rats. This finding could point to the anti-apoptosis properties of the agents used. Previous research in rat models, Homayoun et al. (2020) demonstrated that both Spirulina and GSE have anti-apoptotic properties. Moreover, Al-Bishri et al. (2017) found that the increased DNA tail percentage and tail moment indicate that hyperthyroidism significantly induced DNA damage in rats' liver.

5. CONCLUSION

GSPE and Spirulina platensis has therapeutic properties against hyperthyroidism-induced liver damage, these natural antioxidant agents can be able to modulate the elevation of THs, via direct inactivation of miRNA 224, enhance miRNA 382 and PKC α a signal transduction molecule that functions for thyroid regulators influencing TH production as well as thyroid cell functions.

6. REFERENCES

1. Al-Bishri, W.M., 2017. Hepato therapeutic efficacy of native curcumin and nano-curcumin: a novel therapy against hyperthyroidism induced liver oxidative and inflammatory damage in rats. *Int J Adv Res*, 4(12), 86-97.
2. Albrahim, T. and Robert, A., 2020. Renal protective effects of grape seed extract treatment against Eltroxin-induced hyperthyroidism, kidney damage, and oxidative stress in male mice. *Environmental Science and Pollution Research*, 27(15), 17963-17971.
3. AL-Naely, A.J., Wali, J.K., Shattnan, D.T. 2018. Grape seed extract role against carbimazole action on thyroid gland and lipid profile in male rats. *Al-Qadisiyah Journal of Pure Science*, 23(2), 9-16.
4. Alnahdi, H.S., 2018. The Possible Ameliorative Mechanisms of Curcumin and/or Coenzyme Q10 Against Hyperthyroidism Induced Liver Damage in Rats. *Entomology and Applied Science Letters*, 5(1), 7-16.
5. Bagchi, D., Bagchi, M., Stohs, S.J., Ray, S.D., Sen, C.K., Preuss, H.G., 2002. Cellular protection with proanthocyanidins derived from grape seeds. *Ann N Y Acad Sci.*, 957, 260-70.
6. Bancroft, J.D. and Gamble, M., 2008: *Theory and Practice of Histological Techniques*. 6th Edition, *Churchill Livingstone*, Elsevier, China.
7. Bianco, A.C. and Kim, B.W. 2006: Deiodinases: Implications of the local control of thyroid hormone action. *J. Clin. Invest.* 116, 2571-2579.
8. Brent, G.A., 2012. Mechanisms of thyroid hormone action find the latest version: Science in medicine Mechanisms of thyroid hormone action. *J. Clin. Invest.* 2012, 122, 3035-3043.
9. Cicatiello, A.G., Di Girolamo, D., Dentice, M., 2018: Metabolic effects of the intracellular regulation of thyroid hormone: Old Players, new concepts. *Front. Endocrinol. (Lausanne)* 11, 9, 474.
10. Costilla, M., Macri Delbono R., Klecha A., Cremaschi G.A., Barreiro Arcos M.L., 2019. Oxidative stress produced by hyperthyroidism status induces the antioxidant enzyme transcription through the activation of the Nrf-2 factor in lymphoid tissues of Balb/c mice. *Oxidative medicine and cellular longevity* 2019, 7471890.

11. Ebrahim, R.M., 2020. Prophylactic effect of *Spirulina platensis* on radiation-induced thyroid disorders and alteration of reproductive hormones in female albino rats. *International Journal of Radiation Research*, 18(1), 83-90.
12. Engelbrecht, A.M., Mattheyse, M., Ellis, B., Loos, B., Thomas, M., Smith, R., Peters, S., Smith, C., Myburgh, K., 2007. Proanthocyanidin from grape seeds inactivates the PI3-kinase/PKB pathway and induces apoptosis in a colon cancer cell line. *Cancer Lett.* 258(1), 144-153.
13. Finamore, A., Palmery, M., Bensehaila, S., Peluso, I., 2017. Antioxidant, immunomodulating, and microbial-modulating activities of the sustainable and ecofriendly spirulina. *Oxid. Med. Cell Longev.* 2017: 3247528
14. Hashem, H.A., El-Metwaly, H., Mobarak, Y.M., 2016. Impact of Induce Thyroxine and Carbimazole Vacillation on Liver of Female Rats. *Egypt. Acad. J. Biolog. Sci.* 8(2), 15-29.
15. Hasona, N. and Hussien, T., 2017. Biochemical, histopathological and histochemical effects of *Vitis vinifera* L extract on acetic acid-induced colitis. *J Complement Med Res* 6(4), 351-356.
16. Hasona, NA, 2018. Grape seed extract attenuates dexamethasone-induced testicular and thyroid dysfunction in male albino rats. *Andrologia* 50, e13002.
17. Homayoun, M., Targhi, R. G., Soleimani, M., 2020. Anti-proliferative and anti-apoptotic effects of grape seed extract on chemo-resistant OVCAR-3 ovarian cancer cells. *Research in Pharmaceutical Sciences*, 15(4), 390.
18. Hoseini, S.M., Khosravi-Darani, K., Mozafari, M.R., 2013. Nutritional and medical applications of spirulina microalgae. *Mini Rev Med Chem.*, 13(8), 1231-1237.
19. Ibrahim, R.M., Anees, L.M., Kamal El-Dein, E.M., 2014. Effect of *Spirulina platensis* on oxidative stress induced by gamma radiation and H - pylori infected rats. *Int. J. Res. Stud. Sci. Eng. Technol.* 1(7), 28-37.
20. İşman, C.A., Yeğen, B.C., Alican, I., 2003. Methimazole-induced hypothyroidism in rats ameliorates oxidative injury in experimental colitis. *Journal of Endocrinology* 177 (3), 471-476.
21. Kim, M. and Lee, B.C., 2019. Therapeutic effect of *Scutellaria baicalensis* on L-thyroxine-induced hyperthyroidism rats. *Evidence-Based Complementary and Alternative Medicine*. 2019, 3239649.
22. Kim, S.M., Kim, S.C., Chung, I.K., Cheon, W.H., Ku, S.K., 2012. Antioxidant and protective effects of *Bupleurum falcatum* on the L-thyroxine-induced hyperthyroidism in rats. *Evid Based Complement Alternat Med.* 2012:578497.
23. Li, A., Wu, N., Sun, J., 2022. E2F1-induced microRNA-224-5p expression is associated with hepatocellular carcinoma cell migration, invasion and epithelial-mesenchymal transition via MREG. *Oncology Letters*, 23(3), 1-14.
24. Lissi, E.A., Pizarro, M., Aspee, A., Romay, C., 2000. Kinetics of phycocyanine bilin groups destruction by peroxy radicals. *Free Radic. Biol. Med.* 28(7), 1051-1055.
25. Mandel, S.J. and Cooper, D.S., 2001. The use of antithyroid drugs in pregnancy and lactation. *The Journal of Clinical Endocrinology & Metabolism*, 86(6), 2354-2359.
26. Nie, X., Liu, H., Wei, X., Li, L., Lan, L., Fan, L., Chen, W.D., 2021. miRNA-382-5p Suppresses the Expression of Farnesoid X Receptor to Promote Progression of Liver Cancer. *Cancer Management and Research*, 13, 8025-8035.
27. Palaniswamy, R. and Veluchamy, C., 2018. Therapeutic uses of spirulina: are view. *Int. J. Curr. Innov. Res.* 4(1), 975-979.
28. Peixoto, T.C., de Moura, E.G., Quitete, F.T., Simino, L.A., Torsoni, A.S., Torsoni, M.A., Lisboa, P.C., 2021: Early life nicotine exposure alters mRNA and microRNA expressions related to thyroid function and lipid metabolism in liver and BAT of adult wistar rats. *Molecular and Cellular Endocrinology*, 523, 111141.
29. Ramadan, H.M., Taha, N.A., Ahmed, H.H., 2021: Melatonin enhances antioxidant defenses but could not ameliorate the reproductive disorders in induced hyperthyroidism model in male rats. *Environmental Science and Pollution Research*, 28(4), 4790-4804.
30. Romanelli Vicente Bertolo, M., da Conceicao Amaro Martins, V., de GuzziPlepis, A.M., Bogusz Junior, S., 2021. Rheological study of the incorporation of grape seed extract in chitosan and gelatin coatings. *Journal of Applied Polymer Science*, 138(12), 50052.
31. Sergaliev, M.U., Tsybizova, A.A., Andreeva, L.A., Myasoedov, N.F., Bashkina, O.A., Samotrueva, M.A., 2022. Effect of glyprolins on white blood cell parameters and phagocytic activity of neutrophils in conditions of experimental hyperthyroidism. *Bulletin of the Russian Military Medical Academy*, 24(1), 55-60.
32. Sharma, G., Tyagi, A.K., Singh, R.P., Chan, D.C., Agarwal, R., 2004. Synergistic anti-cancer effects of grape seed extract and conventional cytotoxic agent doxorubicin against human breast carcinoma cells. *Breast cancer research and treatment*. 85(1), 1-12
33. Sharma, R., Bharti, S., Kumar Hari, K.V.S., 2014. Diet and thyroid - myths and facts. *J. Med. Nutr. Nutraceut.* 3(2), 60-65.
34. Singh, N.P., McCoy, M.T., Tice, R.R., and Schneider, E.L., 1988. A simple technique for quantitation of low levels of DNA damage in individual cells. *Experimental cell research*, 175(1), 184-191
35. Tian, H., Ba, W., Zhang, X., Wang, X., Dong, Y., Li, X., Ru, S., 2022. mRNA-miRNA sequencing reveals mechanisms of 2, 2'-dipyridyl disulfide-induced thyroid disruption in Japanese flounder (*Paralichthys olivaceus*). *Aquatic Toxicology* 248, 106191.
36. Vayuphar, B. and Laksanalamai, V., 2012. Recovery of Antioxidants from Grape Seeds and its Application in Fried Food. *J Food Process Technol* 3 (4):152
37. Yousef, M.I., Saad, A.A., El-Shennawy, L.K., 2009, Protective effect of grape seed proanthocyanidin extract against oxidative stress induced by cisplatin in rats. *Food Chem Toxicol.*, 47(6), 1176-1183.