



Official Journal Issued by
Faculty of
Veterinary Medicine

Benha Veterinary Medical Journal

Journal homepage: <https://bvmj.journals.ekb.eg/>



Since 1990

Original Paper

Wounds healing activities of topical chitosan/ Zinc oxide nanocomposite membrane and local insulin injection in diabetic rats through activation of growth factors and suppression of matrix metalloproteinase expressions

Samy A. Hussein¹, Omayma A. R. AboZaid¹, Aziza Amin², Gamal Abdelaziz³, Sameh A. Hassan¹

¹Department of Biochemistry, Faculty of Veterinary Medicine, Benha University, Egypt.

²Department of Pathology, Faculty of Veterinary Medicine, Benha University, Egypt.

³Labeled Compounds Department, Hot Labs Center, Egyptian Atomic Energy Authority, Cairo, Egypt.

ARTICLE INFO

Keywords

Diabetic wound

chitosan/ZnO

nanoparticles

Growth factors

MMP 9

Received 10/07/2022

Accepted 23/08/2022

Available On-Line

01/10/2022

ABSTRACT

Diabetes mellitus causes impaired wound healing. In this study, the potential wound healing activities of topical chitosan/ Zinc oxide nanocomposite membrane and local insulin injection in diabetic rats were evaluated. Diabetes was induced by a single IP injection of Streptozotocin (STZ) at a dose of 50mg/kg b.wt. Forty-eight male rats were divided into Six groups. Group I: control wounded, non-treated, non-diabetic rats, Group II: wounded diabetic non-treated, Group III: Normal wounded rats treated with chitosan/ Zinc oxide nanocomposite membrane, Group IV: Diabetic wounded treated with chitosan/ Zinc oxide nanocomposite membrane rats, Group V: wounded diabetic rats treated with local insulin injection, Group VI: Wounded diabetic rats treated with chitosan/ Zinc oxide nanocomposite membrane and local insulin injection. After 14 days of wound treatment, rats were euthanized and the skin tissue was collected for (EGF), (PDGF), (MMP9) and miRNA 21 gene expression analysis. A significant down-regulation of EGF, PDGF and miRNA 21 with up-regulation in MMP 9 were observed in diabetic non treated wounds as compared with control wounded. Meanwhile, a significant increase of EGF, PDGF and miRNA 21 with decrease in MMP 9 gene expression was observed in insulin, Chitosan/ZnO membrane treatment alone or in combination in wounded diabetic rats. Conversely, MMP9 was significantly down regulated after different treatments. The finding indicated that topical Chitosan/ZnO nanocomposite membrane and insulin injection exhibited a great effect on the acceleration of diabetic wound healing via increasing pro-angiogenic effect, re-epithelialization, and remodeling of ECM .

1. INTRODUCTION

Diabetic wounds (DWs) are extra complex and continual, that have a considerable long-status effect at the morbidity, mortality, and satisfactory of patient's lives (Sanapalli et al., 2021). However, the risk to do managed experimentation on the nature and remedy of DWs is limited. In addition, there may be a colossal inconstancy in the well-known of care among organizations and clinicians, making it frequently hard to look at treatments or effects (Eming et al., 2014).

In diabetic wounds, fibrin cuffs encircle tiny blood vessels, which prevents the granulation of new blood vessels, and tissue. In general, inflammatory infiltrates should disappear after removing dead tissue and microorganisms, whereas it persists chronically in diabetes wounds with a distinct neutrophil phenotypic profile. (Martin and Nunan, 2015).

In both humans and animals, wound healing is a crucial yet challenging process, containing a complicated process run under the control of overlapping but sequential phases, such as phases of hemostasis/inflammation, proliferation, and remodeling (Lindley et al., 2016).

Chitosan is an entirely natural polysaccharide, nontoxic, and possesses the necessary compatibility with human tissues and blood. Since chitosan possesses unique biological

activity that encourages human cell proliferation and tissue regeneration in addition to having potent antibacterial, hemostatic, and analgesic properties, it is suitable as a material for bandages and can hasten the healing of wounds. Studies on chitosan wound dressings have been conducted and are still ongoing today. (Wang et al., 2020).

In an animal model, zinc oxide nanoparticles have the ability to cure a variety of wound types. Much research has been done to support its epithelialization-stimulating effect on damaged skin. (Khorasani et al., 2019).

The impact of insulin on increasing the rate of wound healing has been found in different animal models, and in different wound types, such as diabetic and non-diabetic, burn wounds, excision wounds, fractures, and cutaneous ulcerations (Liu et al., 2004; Zhang et al., 2007). Moreover, insulin quickens wound recovery by regulating multiple cellular functions in multiple aspects of the healing process (Dhall et al., 2015).

The present study aims to estimate the potential wound healing effect of chitosan/ZnO membrane and insulin injection on growth factors such as EGF and PDGF in addition to MMP 9 and miRNA 21 gene expression in an experimental model of the diabetic wound in rats and histopathological evaluation.

* Corresponding author: sameh.abdelhady4483@gmail.com

2. MATERIAL AND METHODS

2.1. Experimental Animals:

Forty-eight male Wister albino rats of two months weight between 180-200g. Rats were housed in separated metal cages and kept at constant environmental and nutritional conditions throughout the period of experiment. The rats were fed on constant ration and fresh, clean drinking water was supplied ad-libitum. All rats were acclimatized for minimum period of 15 days prior to the beginning of study. Experiment was conducted according to the guide for care of laboratory animals approved by the ethical animal committee of Benha university (Approval no. BUFVTM 02-8-21).

2.2. Chemicals and antioxidant agents:

Streptozotocin:

Streptozotocin (STZ) was bought from (Sigma Chemical Co. U.S.A.) and used to induce hyperglycemia by single intraperitoneal (i.p) injection at a dose of 50 mg /kg body wt. (Ramanathan *et al.*, 1999).

Insulin:

Long performing insulin was bought from (Lantus Solostar, Sanofi-Aventis, Germany). It is subcutaneously injected at a dose of (2 U/rat per day) (Michael *et al.*, 2012).

Chitosan (CS): was obtained from (Sigma-Aldrich, Chemical Company).

Zinc oxide nanoparticles (nZnO): were acquired from (Sigma-Aldrich).

Polyvinyl alcohol (PVA): was purchased from (Loba, chemie).

2.3. Membrane Preparation:

Preparation of PVA/CS and PVA/CS/ZnO composite membranes:

2% of the chitosan solution was prepared by dissolving 1g of chitosan solution in 1% acetic acid (v/v). PVA solution became organized by dissolving 5 gm of PVA powder in 100 cc of distilled water. 20 ml mixture solution of polymer changed into combined to put together the ratio of 1:3 and 1:4 of PVA:CS mixture homogenous polymer solution. Under stirring, 100 mg of ZnO nano-powder was dispersed in blend solution. The aggregate changed into sonicated for 30 min after magnetic stirring and the resulting solution was cast onto glass plates and the obvious membranes were received after solvent evaporating slowly in air at room temperature. and coded in accordance to composition as the subsequent PVA/CS, PVA/CS/ZnO 1:3:1 and PVA/CS/ZnO 1:4:1 (Omer *et al.*, 2021).

2.4. Induction of diabetes:

Experimental diabetes in male rats was induced by a single intraperitoneal (i.p.) injection of the STZ at a dose of 50 mg /kg body wt. STZ was dissolved in a buffer of citrate, pH 4.5. After STZ injection the glucose solution (5%) w/v was provided to the animals in single day to keep away from hypoglycemia which is probably induced by means of STZ. Hyperglycemia turned into confirmed 48 h after STZ injection by monitoring the blood glucose using ACCU-CHEK sensor glucometer. Diabetic rats were diagnosed with glucose levels higher than 250 mg/dL (Ramanathan *et al.*, 1999).

2.5. Experimental design:

The rats were randomly divided into six groups of eight rats each, kept in separated cages for every group, and categorized as following:

Group I (Normal wound): wounded, non-treated, non-diabetic rats.

Group II (Diabetic wound non treated): wounded, non-treated, diabetic rats.

Group III (Normal wound treated with chitosan/ ZnO nanocomposite membrane): wounded, non-diabetic rats treated with the topical application of chitosan/ ZnO nanocomposite membrane, the wounded area was covered with membrane and membrane was replaced with fresh one at 3,5, 7, 10,12 and 14 days.

Group IV (Diabetic wound treated with chitosan/ ZnO nanocomposite membrane): wounded, diabetic rats with topical application of chitosan/ ZnO nanocomposite membrane.

Group V (Diabetic wound treated with local insulin): wounded, diabetic rats treated with local insulin injected subcutaneously (2U/rat per day) for 14 days.

Group VI (Diabetic wound treated with local insulin and chitosan/ ZnO nanocomposite membrane): wounded, diabetic rats treated with topical application of chitosan/ ZnO nanocomposite membrane and local insulin injection.

2.6. Excisional skin wound Induction:

Following a week of initiating diabetes, every rats back had full-thickness excisional skin wound. Thiopental sodium (40 mg/kg/rat) (Gopal *et al.*, 2014) was used to make the rats unconscious and Hair on the back was removed. A typical wound with a diameter of 6 mm for each rat, was created using a surgical marker pen. Next, using a sharp scalpel blade to reach the muscle layer, full-thickness incisions were created. (João DeMasi *et al.*,2016). After the surgery, each rat was housed individually. Rats were observed twice daily to ensure that all the membranes were on the wounds (Colobatiu *et al.*, 2019).

2.7. Sampling:

Skin Tissue samples: Pentobarbital overdose injections intraperitoneally were used to put the animals to sleep after 14 days of wound treatment (Zhou *et al.*, 2017). Skin specimens were obtained from the widest area of the wound tissue with the surrounding normal skin margin. Skin tissues were kept in liquid nitrogen and stored at -80°C till RNA extraction for determination of the following gene expression: (EGF), (PDGF), (MMP9) and (miRNA 21).

2.8. Histopathological examination:

The skin tissue specimens were removed and fixed in 10% formalin solution after proper fixation, 5 µm tissue paraffin sections were routinely prepared and stained with hematoxylin and eosin (H&E) according to Bancroft and Layton (2019).

2.9. Analysis:

Molecular analysis:

Quantitative RT-PCR used for determination of EGF, PDGF, MMP9, and miRNA 21. in Skin tissue according to the method described by Thermo Scientific, Fermentas, # K0731. β-actin was used as load control. RNA Extraction kit according to manufacturer's instructions. With each cDNA, sample was reverse transcribed using RevertAid TM First Strand CDNA synthesis kit (#EP0451, Thermo Scientific, Fermentas, USA). Then, real-time quantitative PCR amplification was performed on Faststart Universal SYBR Green Master (Roche, GER). The target gene was normalized with β-actin by the 2^{-ΔΔCt} method (Livak and Schmittgen, 2001).

2.10. Statistical analysis:

Comparisons between the groups were performed by one-way analysis of variance (ANOVA), using SPSS Version 20. The data are presented as the means ± SE. At p ≤ 0.05, the differences were considered significant.

Table 1 Forward and reverse primers sequence for primers in qPCR.

Gene	Forward primer (5' ----- 3')	Reverse primer (5' ----- 3')
EGF	CGATGTCAGCACCGAGACTT	CGTTGCTGCTTGACTCTTCG
PDGF	CCAACCTGAACCCAGACCAT	AGGAGAACAAGACCCGACG
MMP9	TCGAAGCGACCTCAAGTG	TTCGGTGTAGCTTTGGATCCA
B-actin	AAGTCCTCACCTCCAAAAG	AAGCAATGCTGCACCTTCCC
miRNA 21	TAGCTTATCAGACTGATGTTGA	GAGCAGGCTGGAGAA
U6	TGACACGCAAATTCGTGAAGCGTTC	CCAGTCTCAGGTCCGAGGTATTC

3. RESULTS

Molecular analysis:

Effect of treatment with insulin and chitosan/ZnO nanocomposite membrane on EGF, PDGF, MMP 9 and miRNA 21 gene expression in diabetic wound rats are presented in table (2) and figures (1,2,3, and 4).

A significant decrease of EGF and PDGF gene expression were observed in skin tissue of diabetic wounds compared with normal wound. However, treatment with insulin (group V) and CS/ZnO membrane with insulin injection (group VI) to diabetic wound in rats exhibited a significant increase in EGF and PDGF gene expressions as compared with diabetic wound non-treated group (group II) With highest decrease in (group VI) followed by (group V) and finally (group IV). Also, marked increases in EGF and PDGF gene expressions were observed in CS/ZnO membrane treated normal wound rats (group III) comparing with normal non treated group (group I).

Markedly increase of MMP 9 and decrease in miRNA 21 gene expression were observed in skin tissue of diabetic wounds compared with normal wound. However, treatment with insulin (group V) and CS/ZnO membrane with insulin injection (group VI) of wounded diabetic rats showed a significant decrease in MMP 9 with highest decrease in (group VI) followed by (group V) and finally (group IV). Additionally, treatment with insulin (group V) and CS/ZnO membrane with insulin injection (group VI) to diabetic wound in rats exhibited a significant increase in miRNA 21 gene expressions compared with diabetic wound non-treated group (group II) with highest increase in (group VI) followed by (group V) and finally (group IV). Also, a significant decrease in MMP 9 and increase in miRNA 21 gene expressions were observed in CS/ZnO membrane treated normal wound rats (group III) comparing with normal non treated group (group I).

Table 2 EGF, PDGF, MMP 9 and miRNA 21 gene expressions in control and different experimental groups

Parameters	EGF Fold change ± SE	PDGF Fold change ± SE	MMP9 Fold change ± SE	miRNA 21 Fold change ± SE
Animal Groups				
Control wounded, non-treated, non-diabetic rats (GI)	1.00 ± 0.08 ^e	1.00 ± 0.07 ^e	1.00 ± 0.05 ^b	1.00 ± 0.07 ^d
Diabetic wounded, non-treated rats (GII)	0.60 ± 0.04 ^f	0.34 ± 0.03 ^f	1.43 ± 0.09 ^a	0.40 ± 0.03 ^e
Control wounded, non-diabetic rats treated with membrane (GIII)	6.36 ± 0.34 ^a	9.58 ± 0.42 ^a	0.21 ± 0.02 ^d	7.36 ± 0.36 ^a
Wounded, diabetic rats with topical application of membrane (GIV)	1.67 ± 0.08 ^d	2.64 ± 0.2 ^d	0.64 ± 0.03 ^c	1.11 ± 0.08 ^d
Wounded, diabetic rats treated with local insulin injected (GV)	2.55 ± 0.14 ^c	3.61 ± 0.23 ^c	0.35 ± 0.02 ^d	2.69 ± 0.13 ^c
Wounded, diabetic rats treated membrane and local insulin injection (GVI)	4.23 ± 0.27 ^b	5.74 ± 0.3 ^b	0.26 ± 0.02 ^e	5.66 ± 0.28 ^b

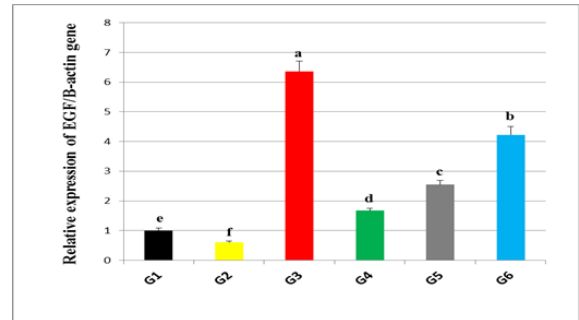


Figure 1 Effect of insulin injection and CS/ZnO nanocomposite membrane on EGF gene expression in experimental model of diabetic wound in rats.

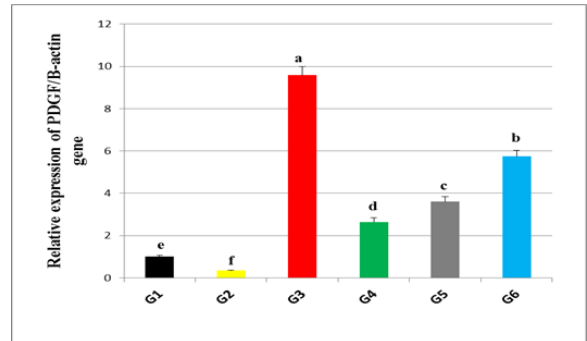


Figure 2 Effect of insulin injection and CS/ZnO nanocomposite membrane on PDGF gene expression in experimental model of diabetic wound in rats.

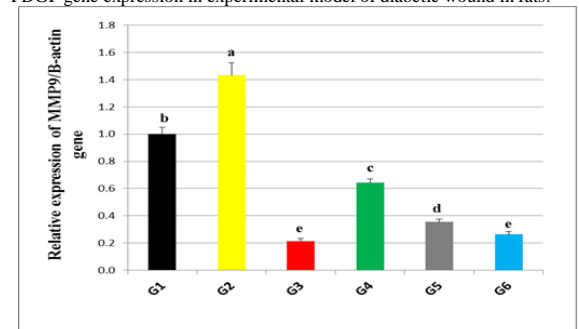


Figure 3 Effect of insulin injection and CS/ZnO nanocomposite membrane on MMP 9 gene expression in experimental model of diabetic wound in rats.

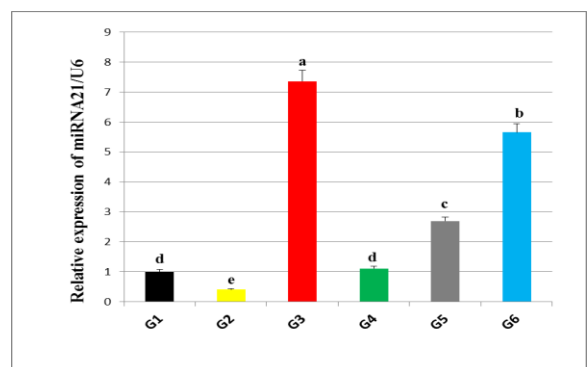


Fig. (4): Effect of insulin injection and CS/ZnO nanocomposite membrane on miRNA 21 gene expression in experimental model of diabetic wound in rats.

Histopathological Findings:

On skin tissue of wound sample during day 14 wound healing was assessed, samples taken from both non-diabetic and diabetic as well as treated rats. After 14 days of the beginning of treatment, the results of the microscopic examination of treatment indicated its positive effect on the process of wound healing with variable degrees.

Interestingly, no leukocytic cellular infiltrations were detected in the healing of wounds in non-diabetic rats as well as non-vascular granulation tissue that composed mainly from fibroblasts was noticed in some examined cases with complete re-epithelization was also observed among this group (figure 5a-c). Additionally, comparing with other groups the cell density was higher throughout the epidermal layer. Meanwhile, these wound healing process of diabetic rats showed mild leukocytic cellular infiltrations as well as complete re-epithelization (figure 5d-e). Moreover, the cell density was less throughout the epidermal layer compared with the normal wound. However, the healing of non-diabetic wounds treated with membrane exhibit an intact epidermal layer that covers typical non-vascular granulation tissue in all investigated cases with the absence of inflammatory cellular infiltration (figure 5f-h). In the meantime, in diabetic wounds treated with membrane, an intact epidermal layer with less cell density in comparison to the non-diabetic wound was seen.

Additionally, mild vascular granulation tissue with leukocytic cellular infiltrations was also observed among this group (figure 6a-c). The histopathological evaluation of diabetic wounds treated with local insulin revealed increased granulation tissue deposition containing greater numbers of larger vessels as the number and luminal size of the blood vessels was greater than in the other investigated groups. Furthermore, the epidermal layer of skin obtained from the diabetic rats-treated with local insulin was thicker and had a greater basal cell density (figure 6e-f), consequently, in this group, the wound healing maturation process was more apparent in comparison to the other treated groups. In the meantime, in the experimental group, diabetic wound treated with both membrane and local insulin, its microscopical findings revealed a thin layer of epithelium covered a thin layer of mildly vascular granulation tissue (figure 6g-i).

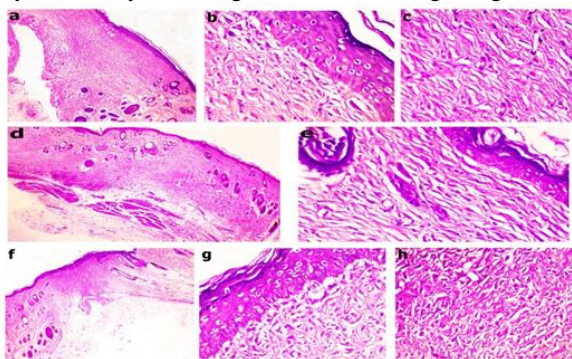


Figure 5 H&E-stained histological sections of a wound at 14 days from non-diabetic rats (a-c), diabetic rats (d-e), Normal rats treated with a membrane (f-h), showing (a, d, f) granulation tissue (x100), (b, e, g) an intact epidermal cell layer covering the granulation tissue (x400), (c, h) maturation of granulation tissue layer (x400).

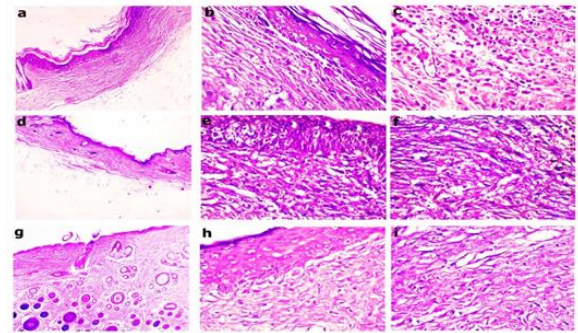


Figure 6 H&E-stained histological sections of a wound at 14 days from diabetic wounds treated with CS/ZnO membrane (a-c), diabetic rats treated with local insulin (d-f), diabetic rats treated with CS/ZnO membrane and local insulin (g-i), showing (a, d, g) granulation tissue (x100), (b, e, h) epidermal cell layer that is still intact covering the granulation tissue (x400), (c, f, i) maturation of granulation tissue layer (x400).

4. DISCUSSION

Hemostasis, inflammation, multiplication, and remodeling are the four steps of the wound healing process that help to restore the integrity of the skin. (Reinke and Sorg 2012).

The results of the present work showed in table (1) and figure (1,2) revealed that, notably increase in wound tissue EGF and PDGF activities in CS/ZnO membrane treated group compared to the normal group, and markedly, down-regulation in non-treated diabetic rats compared to the normal group. In line with our finding, Ueno *et al.*, 2001 proven that chitosan has demonstrated cell proliferative properties that are essential for effective healing in addition to its antibacterial and antifungal properties. It is known to stimulate macrophages and polymorphonuclear leucocytes for phagocytosis and the generation of IL-1, TGF-, and PDGF. Activation of fibroblasts is strongly associated with the degree of de-acetylation, and chitosan also promotes fibroblast proliferation (Minagawa *et al.*, 2007).

Parallel to Feng *et al.* (2021) who declared that, through the stimulation of inflammatory cell development represented by macrophages, fibroblasts and capillaries, chitosan can speed up the healing of skin wounds, Chitosan can encourage the release of cytokines such transforming growth factor-b. (TGF-b), PDGF, and IL-1. TGF-b causes macrophages to flock to injure sites, encouraging fibroblast growth and increasing collagen production. Additionally, Li *et al.*, (2008) implied that, in diabetic wounds, PDGF and its receptors express less, indicating a function in the healing process.

Moreover, EGF accelerates wound epithelialization and lessens scarring by limiting excessive wound contraction (Svensjo *et al.*, 2002).

Similar reports by Okabe *et al.*, (2013) detected that, growth factor (EGF) increased cell proliferation and differentiation and growth by binding to (EGFR). initially discovered in nerve growth factors taken from mouse submandibular gland.

EGFR signaling improved the rat of wound epithelialization and triggers keratinocyte migration to the wound (Pienimaki *et al.*, 2001).

Sommeling *et al.* (2013). confirmed that, at a wound site, EGF can promote the growth of granulation tissue and enhance the quality of wound recovery.

Our results suggest that, a treatment with CS/ZnO membrane and insulin injection to diabetic wound in rats show a noticeable increase in EGF and PDGF activities compared with rats treated with CS/ZnO membrane and rats treated with insulin injection only.

The obtained outcomes shown in table (1) and figure (3,4) revealed that, a markedly up-regulation in wound tissue MMP 9 activities in diabetic non-treated rats compared with the normal control group. Supporting our findings Gooyit *et al.* (2014) reported that, an increase of active MMP-9 was recorded in diabetic mice with delayed wound closure, which can be harmful to the restoration process.

Treatment with chitosan/ZnO membrane to diabetic wounds showed a noticeable improvement in tissue MMP 9 activities compared with diabetic rats treated with insulin injection only and rats treated with CS/ZnO membrane with insulin injection. Similar to Moura *et al.*, (2022) who detected enhanced re-epithelialization and collagen synthesis occurred concurrently with enhanced MMP-9 activity in wounds treated with Ag-ZnO/AgO NPs. the inhibition of this enzyme in mice, helped to highlight the significance of MMP-9, this caused uneven ECM remodeling, reduced collagen synthesis and postponed re-epithelialization (Kyriakides *et al.*, 2009).

In line with our finding, Long *et al.*, (2018) demonstrated that, following skin damage, it was discovered that keratinocytes MiR-21 levels had increased, which occurred at the same time as TGF- β 1, a crucial wound-healing facilitator. Furthermore, another player in the regulation of the inflammatory and proliferative stages of wound healing is MiR-21.

Moreover, Yang *et al.* (2011) revealed that TGF- β 1 upregulated miR-21, which became, subsequently necessary for TGF-driven keratinocyte migration. In connection with this, miR-21 has been linked to characteristics of wound healing such as migration of cells, angiogenesis, and re-epithelialization. In light of this, overexpression of miR-21 in a rat model of wound healing considerably increases the rate of healing because, targeting the tumor suppressor phosphatase and tensin homolog (PTEN) activates the AKT/PI3K signaling pathway (Xiong *et al.*, 2013).

In line with our finding, Baghaie *et al.*, (2017) observed that, the epidermis was totally welded in the tissue sections with the PVA/St/Cs/nZnO hydrogel membranes, and necrosis, granulation, and edoema were not seen. appendices of the dermal, including hair follicles, were identified were growing on both sides of the incision, and fat hypoderm was developing. Low in quantity and of the lymphocyte type were the remaining inflammatory cells. blood vessel density dropped in comparison to the control sample, suggesting the start of the regeneration phase.

Similar reports by Ribeiro *et al.*, (2020) detected that chitosan stimulates the proliferation of fibroblasts, blood vessels, and collagen deposition in the wound site, which is characterized by the formation of granulomatous tissue. After 14 days of treatment with insulin-chitosan nanoparticles, a decrease in the intensity of fibroplasia was detected while an increase in the presence of fibrosis was observed for these groups.

5. CONCLUSION

The topical chitosan/Zno nanocomposite membrane and local insulin injection are effective in treatment of diabetic

wounds via inhibition of MMP-9 and stimulation of PDGF and EGF that improve the healing process.

6. REFERENCES

1. Baghaie, S.; Khorasani, M. T.; Zarrabi, A. and Moshtaghian, J. 2017 . Wound healing properties of PVA/starch/chitosan hydrogel membranes with nano Zinc oxide as antibacterial wound dressing material. *Journal of Biomaterials Science, Polymer Edition*, 28), 18: 2220 –2241.
2. Bancroft, J.D. and Layton, C. 2019 . The hematoxylin and eosin. In: *Bancroft's Theory and Practice of Histological Techniques*. Elsevier, pp. 126–138.
3. Colobatiu, L.; Gavan, A.; Potarniche, A.V.; Rus, V.; Diaconeasa, Z.; Mocan, A.; Tomuta, I.; Mirel, S. and Mihaiu, M. 2019 . Evaluation of bioactive compounds-loaded chitosan films as a novel and potential diabetic wound dressing material. *Reactive and Functional Polymers* 145 - 104369.
4. Danaei, G.; Finucane, M.M.; Lu, Y.; Singh, G.M.; Cowan, M.J. and Paciorek, C.J. 2011 . National, regional, and global trends in fasting plasma glucose and diabetes prevalence since 1980: systematic analysis of health examination surveys and epidemiological studies with 370 country-years and 2.7 million participants, *Lancet* 37: 31–40.
5. Dhall, S.; Silva, J. P.; Liu, Y.; Hrynyk, M.; Garcia, M.; Chan, A.; Lyubovitsky, J.; Neufeld, R. J. and Martins-Green, M. 2015 .Release of insulin from PLGAalginate dressing stimulates regenerative healing of burn wounds in rats. *Clin. Sci. Lond.*) 129, 1115–1129.
6. Eming, S.A.; Martin, P. and Tomic-Canic, M. 2014 . Wound repair and regeneration: mechanisms, signaling, and translation, *Sci. Transl. Med.* 6 (265) : 265sr6.
7. Feng, P.; Luo, Y.; Ke, C.; Qiu, H.; Wang, W.; Zhu, Y.; Hou, R.; Xu, L. and Wu, S. 2021 . Chitosan-Based Functional Materials for Skin Wound Repair: Mechanisms and Applications. *Bioeng. Biotechnol.* 9: 10.3389-650598.
8. Gooyit, M.; Peng, Z.; Wolter, W.R., Pi, H.; Ding, D. and Heseck D, 2014 . A chemical biological strategy to facilitate diabetic wound healing. *ACS Chem Biol.*; 9 1 .105–110.
9. Gopal, A.; Kant, V.; Gopalakrishnan, A.; Tandan, S. K. and Kumar, D. 2014 . Chitosan-based copper nanocomposite accelerates healing in excision wound model in rats. *European Journal of Pharmacology* 731 : 8–19.
10. João De Masi, E.C.; Campos, A.C.; João De Masi, F.D.; Ratti, M.A.; Ike I.S. and João De Masi, R.D. 2016 . The influence of growth factors On skin wound healing in rats. *Braz. J. Otorhinolaryngol.* 82, 512–521.
11. Khan, A.R.;Huang, K.; Jinzhong, Z.; Zhu, T.; Morsi, Y.; Aldalbahi, A.; El- Newehy, M.; Yan, X. and Mo, X. 2021 . Exploration of the antibacterial and wound healing potential of a PLGA/silk fibroin based electrospun membrane loaded with zinc oxide nanoparticles, *J. Mater. Chem. B.* 9:1452–1465.
12. Khorasani, M.T.; Joorabloo, A.; Adeli, H.; Mansoori-Moghaddam, Z. and Moghaddam, A. 2019 . Design and optimization of process parameters of poly(vinyl alcohol)/chitosan/ nano zinc oxide hydrogels as wound healing materials, *Carbohydr. Polym.* 207: 542–554.
13. Kyriakides, T.R.; Wulsin, D.; Skokos, E.A.; Fleckman, P.; Pirrone, A.; Shipley, J.M.; Senior, R.M. and

- Bornstein, P. 2009 . Mice that lack matrix metalloproteinase-9 display delayed wound healing associated with delayed reepithelization and disordered collagen fibrillogenesis. *Matrix Biol.* 28 (2), 65–73.
14. Li, H.; Fu, X.; Zhang, L.; Huang, Q.; Wu, Z. and Sun, T. 2008 . Research of PDGF-BB gel on the wound healing of diabetic rats and its pharmacodynamics, *J. Surg. Res.* 145: 41–48.
 15. Lindley, L.E; Stojadinovic, O.; Pastar, I. and Tomic-Canic, M. 2016 . Biology and biomarkers for wound healing. *Plast Reconstr Surg*; 138 3 Suppl .18S-28S.
 16. Liu, Y.; Zhang, X.; Zhang, Z.; Fang, P. Y. and Xu, W. S. 2004 . Effects of topical application of insulin on the wound healing in scalded rats. *Zhonghua Shao Shang Za Zhi.* 20, 98-101.
 17. Livak, K.J. and Schmittgen, T.D. 2001 . Analysis of relative gene expression data using real-time quantitative PCR and the 2- $\Delta\Delta$ CT Method. *Methods*; 25 4 .402-408.
 18. Martin, P. and Nunan, R. 2015 . Cellular and molecular mechanisms of repair in acute and chronic wound healing, *Br. J. Dermatol.* 173 2 . 370–378.
 19. Michaela, S.T.; Ganeshb, R.N. and Viswanathan, P. 2012 . Effect of long acting insulin supplementation on diabetic nephropathy in Wistar rats. *Indian Journal of Experimental Biology* Vol.50, December 2012 pp. 867-874.
 20. Minagawa, T.; Okamura, Y.; Shigemasa, Y.; Minami, S. and Okamoto, Y. 2007 . Effects of molecular weight and deacetylation degree of chitin/chitosan on wound healing. *Carbohydr Polym* 67:640–644.
 21. Moura, F. B. R.; Ferreira, B.A.; Muniz, E.H.; Justino, A. B.; Silva, A.G.; Ribeiro, R. I. M.; Dantas, N.O.;Ribeiro, D. L.; Araújo, F. A.; Espindola, F.S.; Almeida Silva, A.C. and Tomiosso, T.C. 2022 .Antioxidant, anti-inflammatory, and wound healing effects of topical silver-doped zinc oxide and silver oxide nanocomposites. *International Journal of Pharmaceutics* 617:121620. <https://doi.org/10.1016/j.ijpharm.2022.121620>.
 22. Okabe, K.; Hayashi, R.; Hattori, N. A.; Sakamoto, Y. and Kishi, K. 2013 . Wound treatment using growth factors. *Modern Plastic Surgery.*; 3: 108-112.
 23. Pienimaki, J.P.; Rilla, K. and Fulop, C. 2001 . Epidermal growth factor activates hyaluronan synthase 2 in epidermal keratinocytes and increases pericellular and intracellular hyaluronan, *J. Biol. Chem.* 276 : 20428–20435.
 24. Ramanathan, M.; Jaiswal, A.K. and Bhattacharya, S.K. 1999 .Superoxide dismutase, catalase and glutathione peroxidase activities in the brain of streptozotocin-induced diabetic rats. *Indian. J.Exp.Biol.*; 37: 182-183.
 25. Reinke, J.M. and Sorg, H. 2012 . Wound repair and regeneration, *Eur. Surg. Res.* 49 35–43.
 26. Ribeiro, M. C.; Correa, V. L. R.; Silva, F. K.L.; Casas, A. A.; Chagas, A. L.; Oliveira, L.P.; Miguel, M. P.; Diniz, D. G.A.; Amaral, A.C. and Menezes, L. B. 2020 .Wound healing treatment using insulin within polymeric nanoparticles in the diabetes animal model. *European Journal of Pharmaceutical Sciences* 150: 105330.
 27. Sanapalli, B. K. R.; Yele, V.; Singh, M. K.; Krishnamurthy, P. T. and Karri, V. V. S.R. 2021 . Preclinical models of diabetic wound healing: A critical review *Biomedicine & Pharmacotherapy* 142 -111946.
 28. Svensjo, T.; Yao, F.; Pomahac, B.; Winkler, T. and Eriksson, E. 2002 . Cultured autologous fibroblasts augment epidermal repair. *Transplantation*, 73: 1033-41.
 29. Ueno, H.; Mori, T. and Fujinaga, T. 2001 . Topical formulations and wound healing applications of chitosan. *Adv Drug Deliv Rev* 52:105–115.
 30. Wang, W.; Xue, C. and Mao, X. 2020 . Chitosan: Structural modification, biological activity and application.I. *J. of Biological Macromolecules* 164: 4532–4546.
 31. Xiong, B.; Cheng, Y.; Ma, L. and Zhang, C. 2013 . MiR-21 regulates biological behavior through the PTEN/PI-3 K/Akt signaling pathway in human colorectal cancer cells. *Int. J. Oncol.* 42: 219-228.
 32. Zhang, X.J.; Wu, X.; Wolf, S. E.; Hawkins, H. K.; Chinkes, D. L. and Wolfe, R. 2007 . Local insulin-zinc injection accelerates skin donor site wound healing. *J. Surg. Res.* 142, 90-96.
 33. Zhou, J.; Ni, M.; Liu, X.; Ren, Z. and Zheng, Z., 2017 . Curcumin promotes vascular endothelial growth factor (VEGF)-mediated diabetic wound healing in streptozotocin-induced hyperglycemic rats. *Med. Sci. Monit.* 23, 555–562.