




Official Journal Issued by
Faculty of
Veterinary Medicine

Benha Veterinary Medical Journal

Journal homepage: <https://bvmj.journals.ekb.eg/>



Since 1990

Original Paper

Biochemical, histological and immunohistochemical studies on the efficacy of garlic oil against thioacetamide- induced hepatotoxicity in rats.

Faten. I. ELSayed¹, Fatma A. Gad², Reda. I. El Kammar³, Osama Ahmed⁴

¹Departments of Pharmacology, Faculty of Veterinary Medicine, Benha University

²Departments of Clinical Pathology, Faculty of Veterinary Medicine, Benha University

³Departments of Histology, Faculty of Veterinary Medicine, Benha University

⁴Departments of Anatomy and Embryology, Faculty of Veterinary Medicine, Benha University

ARTICLE INFO

Keywords

Garlic oil
Thioacetamide
Serum biochemical
analysis
Histopathology
Immunohistochemistry

Received 27/06/2022

Accepted 17/07/2022

Available On-Line

01/10/2022

ABSTRACT

The main aim of this study is to evaluate the protective effect of garlic oil against thioacetamide- induced hepatotoxicity in albino rats. Thirty rats divided into 5 groups **1:** control group received 1 ml of isotonic saline orally once daily; **2:** garlic oil group rats were received orally 200 mg/ kg body weight of garlic oil once daily; **3:** Thioacetamide (TAA) group was intoxicated with TAA at a dose of 100 mg/kg body weight twice weekly by intraperitoneal injection; **4:** Garlic oil+ TAA group received garlic oil followed by TAA; **5:** Silymarin+TAA group rats were received Silymarin at a dose of 50 mg/kg body weight orally followed by TAA. All treatments have been continued for 30 days. TAA-treated rats revealed dramatic increases in ALT, AST, ALP, TC and TG with a significant decline in TP, Alb, and HDL when compared to the control group. The TAA+garlic and TAA+Silymarin groups, on the other hand, showed an improvement in the previous parameters. Oxidative stress parameters demonstrated a significant reduction in the elevated level of MDA in garlic group than TAA-treated rats, along with increased SOD, GSH and CAT. Histopathological and immunohistochemical results showed that TAA -treated rats revealed evidence of severe damage to the hepatic parenchyma with higher number of Bax immunopositive cells and down regulation of Bcl2 expression in cytoplasm of affected hepatocytes. However, garlic treated group restored the toxic effect on liver. In conclusion, garlic oil has a potent protective effect against TAA- induced hepatotoxicity due to its powerful antioxidant activity.

1. INTRODUCTION

Liver is considered the largest gland in the body, it represented nearly 2-3% of adults body weight (Carton et al., 2008). Liver has multiple of vital functions including Synthesis, metabolism and detoxification of different metabolites. Using a lot of drugs increase risk of liver injury. Drug induced hepatotoxicity is a major cause of liver diseases, the United States acute liver study group states that drug induced liver injury is the cause for more than half of acute liver failure (Holt and Ju, 2006). It was reported that thioacetamide (TAA) is a potent hepatotoxin which is usually used to induce cirrhosis and hepatocellular carcinoma subsequently in experimental animal models. (Helmy et al., 2018).

The use of natural products as liver remedies has been known for long decades. Last century has seen a big development in the application of usage of natural product. One of these products is garlic (*Allium sativum*) garlic oil in particular as it is rich in a bio-active organosulfur compound as allicin, diallyle Sulfide and S-allyl cystein (Shalaby and Hammada, 2015). Because of its biological properties, garlic's significance has been largely increased based on its organosulfers contents that give it its distinct flavor and

contribute to its beneficial health effects (Mumtaze et al., 2020). Nowadays many garlic preparations are being used in the medical field as fresh garlic extract, aged garlic extract and finally garlic oil. The aim of the current study was to evaluate the hepatoprotective impact of garlic oil on TAA-induced hepatotoxicity.

2. MATERIAL AND METHODS

2.1. Chemicals:

Thioacetamide: it was obtained from Lobachemi PVT Mumbai India. The recommended dose for hepatotoxicity is 100 mg/kg intraperitoneally twice a week for 30 days (Gheith and El-mahmoudy, 2019).

Garlic oil: It was purchased from El Captin Company. Cairo, Egypt. It was administered orally for 30 days at a dose of 200 mg/kg body weight (Ncir et al 2020).

Silymarin: Silymarin was used as the patent preparation Hepaticum® (Medical union pharmaceuticals) Abu sultan, Ismalia Egypt. It was given at a dose of 50 mg/kg body weight by gastric tube (Yan-Yu et al 2006).

* Corresponding author: Fatenibrahim73@yahoo.com

2.2. Animals:

Thirty male Wister albino rats weighing between 225±25 grams were used in the current study. They were obtained from the Benha University Faculty of Veterinary Medicine's Animal House. Before starting the experiment, rats were maintained for one week before starting the experiment for acclimatization. The experimental design, procedure and animal handling were authorized by the Animal Ethical Committee of Cares and Use in Benha University's Faculty of Veterinary Medicine in Egypt. (Ethical approval number BUFVTM 01-05-22).

2.3. Study design:

The acclimatized 30 rats were randomly categorized into five groups (N= 6 per group) and received the following treatment for 30 days.

First Group: rats were given orally one mL of isotonic saline used as control group.

Second Group: rats were given orally garlic oil once daily at a dose of 200 mg/ kg body weight used as garlic group

Third Group: rats were injected intraperitoneally with TAA, twice weekly, at a dose of 100 mg/kg body weight. used as TAA-intoxicated group

Fourth Group: rats were given orally garlic oil once daily at a dose of 200 mg/ kg body weight followed by intraperitoneal injection 100 mg/kg body weight of TAA twice weekly kept as TAA+garlic group.

Fifth Group: rats were given orally Silymarin at a dose of 50 mg/kg body weight, then TAA at a dose of 100 mg/kg body weight ip twice weekly kept as Silymarin +TAA group.

2.4. Blood sample collection:

After the end of experiment, six rats of each group were retro-orbitally punctured to obtain blood samples for biochemical analysis. Each blood sample was collected in a sampling tube without anticoagulant allowed to clot, then centrifugated and the serum was collected in Eppendorf tube using automatic pipette.

2.5. Tissue samples:

All rats were sacrificed after blood sampling; the livers were quickly collected and cleaned with physiological saline. Firstly, the whole organ was examined for macroscopic alterations. Half of specimens were stored at -70 °C for further examination of oxidation biomarkers and the other half was fixed in 10% formalin for histopathological and immunohistochemical examinations.

2.6. Biochemical Assessment:

All biochemical assessments for liver biomarkers were conducted spectrophotometrically. Measurement of the enzymatic activities of AST/ALT and ALP in serum was carried out according to the principle described by Retiman and Frankel (1957) and Belfield and Goldberg (1971), respectively. total protein and albumin were measured according to Doumas et al. (1971). While triglycerides (TG), total cholesterol (TC) and HDL was determined on the bases of Fassati and Prencipe, (1982), Richmond, (1973) and Lopes virella et al., (1977), respectively.

2.7. Lipid peroxidation and antioxidant activity:

Half of each rat liver was minced, homogenized and centrifuged and the supernatant was collected for estimation of MDA, CAT, SOD and GSH according to Ohkawa et al, (1979), Aebi, (1984), Nishikma et al (1972) and Buetler et al (1963) respectively.

2.8. Histopathology examination:

One cm³ liver specimens was collected from rats in all groups and used in the light microscope study. The specimens were washed in distilled water for removal of

blood clots and other debris, fixed for 48-72 hours in ten percent of formalin, then immersed in ascending grades of ethyle alcohol for dehydration followed by cleared in xylene and embedded in paraffin wax. Sections 4-5µm thick were cut, placed onto glass slides and stained with Harris's hematoxylin and eosin stain for general histological examination Bancroft and Gamble (2002).

2.9. Immunohistochemical examination:

On positive charged microscope slides, 5 µm of Paraffin sections of liver were collected. Xylene was used for deparaffinized of sections, then rehydrated in descending grades of ethanol, followed by rinsing in phosphate-buffered saline.

The antigen was extracted by heating tissue sections in a 10 mM citrate buffer with a pH of 6.0 for 40 minutes, followed by 20 minutes of cooling at room temperature. Sections were treated for 15 minutes with 3 % hydrogen peroxide in methanol to reduce the peroxidase activity. For preventing non-specific stains, the sections were incubated for 30 min with 10% normal goat serum at room temperature.

Sections were then incubated for 30 minutes at room temperature with 1:200 dilution mouse anti-human Bax polyclonal antibodies. The sections were then treated for 30 minutes at room temperature with goat anti-mouse secondary antibody. DAB stain was used to stain the slides.

At room temperature for 30 minutes, sections were incubated with mouse polyclonal Bcl2 antibodies at a dilution of 1:600. The sections were then exposed for 30 minutes at room temperature to human anti-mouse secondary antibody. DAB stain was used to stain the slides. Visualization was carried out according to Kumar and Rudbeck, (2009).

2.10. Statistical analysis:

All data are displayed as mean ± SE. Graph Pad Prism V.6 software was used to conduct a one-way analysis of variance (ANOVA) and a turkey's post hoc test to identify significant differences between groups. values were considered significant at a P value equal to or less than 0.05.

3. RESULTS

3.1. Serum biochemical measurements

TAA- intoxication induced a significant increase in activities of enzymatic liver biomarkers (AST, ALT, ALP) when compared to control group. Concurrent administration of garlic oil with TAA restored the effects of TAA and almost returned them nearly similar to the Silymarin-treated group as standard hepato -protective agent (Table 1).

Our results revealed a dramatic decrease in level of total protein, Albumin in TAA-intoxicated group in comparison to control group; meanwhile dramatic increase in total protein and albumin levels were observed in the group co - treated with garlic oil and TAA from one hand and TAA and Silymarin group from the other hand, Furthermore, significant reductions in TP and Alb levels were observed in the TAA+ Silymarin group when compared to the TAA +garlic group. (Table 1).

TAA-induced liver intoxication resulted in a significant increase in TC and TG levels, as well as a significant decrease in HDL. Administration of garlic at dose of 200 mg/ kg body weight for one month remarkably prevented TAA -induced hepatic damage and lead to comparatively significant decrease in TC and TG levels as nearly to control and Silymarin treated groups along with significant increase in HDL level. Additionally, there was significant decreases

in TG and TC with significant elevation in HDL in TAA+Silymarin group comparing with TAA+garlic group (Table 2)

Table 1 Effect of oral administration of garlic oil at 200 mg /kg body weight for successive 30 days on liver biomarker (AST, ALT, ALP), total protein and albumin on TAA (100 mg/kg b.wt.) - Intoxicated rats. (n=6).

Parameters	Control	Garlic	TAA	TAA+ Garlic	TAA+ Silymarin
ALT (U/L)	48.02 ± 1.73 ^a	49.82 ± 1.77 ^a	133.91 ± 12.01 ^d	117.35 ± 1.53 ^c	99.05 ± 1.22 ^b
AST (U/L)	56.56 ± 1.39 ^a	58.43 ± 1.37 ^a	118.02 ± 2.57 ^d	99.93 ± 1.47 ^c	75.21 ± 1.63 ^b
ALP (U/L)	94.53 ± 1.32 ^a	96.22 ± 2.73 ^a	183.59 ± 1.73 ^c	129.46 ± 1.62 ^b	98.93 ± 1.13 ^a
TP (g/dl)	8.95 ± 0.92 ^d	8.82 ± 0.73 ^d	4.54 ± 0.67 ^a	5.71 ± 0.81 ^b	6.56 ± 0.58 ^c
Alb (g/dl)	6.25 ± 1.09 ^d	6.02 ± 1.03 ^d	2.99 ± 0.91 ^a	4.12 ± 0.88 ^b	5.27 ± 1.01 ^c

Different superscript letters showed significant difference (P≤0.05) within the same rows

Table 2 Effect of oral administration of garlic oil at 5 mg /kg body weight for successive 30 days on Lipid profile (Cholesterol, Triglyceride, HDL) levels on TAA (100 mg/kg b.wt.) intoxicated rats. (n=6).

Parameters	Control	Garlic	TAA	TAA+ Garlic	TAA+ Silymarin
TC (mg/dl)	105.7 ± 1.22 ^a	103.12 ± 1.37 ^a	168.5 ± 1.41 ^d	129.9 ± 1.35 ^c	112.3 ± 1.44 ^b
TG (mg/dl)	114.6 ± 1.99 ^a	113.54 ± 1.43 ^a	198.07 ± 1.67 ^d	149.39 ± 1.63 ^c	129.9 ± 1.35 ^b
HDL (mg/dl)	34.09 ± 0.54 ^d	35.03 ± 0.53 ^d	18.39 ± 0.44 ^a	22.94 ± 0.49 ^b	27.9 ± 0.39 ^c

Different superscript letters showed significant difference (P≤0.05) within the same rows

3.2. Effect on oxidative stress biomarkers

Regarding oxidative stress and antioxidant parameters, a marked increase in MDA level with a dramatic drop in SOD, GSH and CAT activities were noticed in the TAA group when compared with the control group. While garlic-treated rats showed non-significant difference in the previous variables comparing with control group. Meanwhile, the TAA + Garlic and TAA + Silymarin groups showed a dramatic drop in MDA level as well as an increase in SOD, GSH, and CAT compared to the TAA-treated group. In comparison to the TAA+Garlic group, the TAA+Silymarin group showed a marked drop in MDA and an increase in SOD, CAT, and GSH activities (Table 3).

Table 3 Effect of oral administration of garlic oil at 5 mg /kg body weight for successive 30 days on oxidative stress biomarker (CAT, SOD, GSH and MDA) on TAA (100 mg/kg b.wt.) intoxicated rats. (n=6).

Parameters	Control	Garlic	TAA	TAA + Garlic	TAA + Silymarin
MDA (nmol/g)	55.45 ± 1.11 ^a	53.34 ± 1.13 ^a	139.21 ± 1.43 ^d	117.72 ± 1.23 ^c	102.9 ± 1.03 ^b
GSH (U/gm)	15.33 ± 0.39 ^d	15.02 ± 0.37 ^d	3.92 ± 0.43 ^a	9.99 ± 0.33 ^b	12.99 ± 0.35 ^c
SOD (U/gm)	66.82 ± 0.43 ^b	67.01 ± 0.48 ^d	38.62 ± 0.49 ^a	47.11 ± 0.51 ^b	58.8 ± 0.50 ^c
CAT (U/gm)	25.57 ± 0.22 ^d	26.02 ± 0.17 ^d	4.20 ± 0.19 ^a	15.14 ± 0.21 ^b	21.23 ± 0.15 ^c

Different superscript letters showed significant difference (P≤0.05) within the same rows

3.3. Pathological findings

3.3.1. Macroscopic examination

As shown in figure 1(A, B) gross examination of liver of control group and garlic oil treated group revealed normal deep red coloration, shining, smooth texture without any abnormalities. Liver of TAA- intoxicated rats shown grey-red coloration, rough surface, slight swelling (Figure 1 C). In contrast liver of rats concurrently treated with Silymarin and TAA for 30 days were comparatively healthier with bright smooth surface (Figure 1D). Interestingly, liver of rats concurrently treated with garlic oil and TAA for 30 days showed significant recovery as red colure and nearly similar to Silymarin treated group (Figure 1 E).

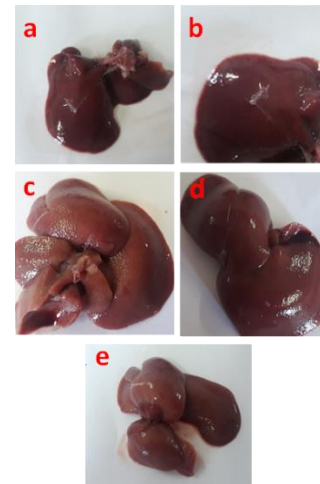


Figure 1 Macroscopic picture of liver obtained from control (a), garlic oil (b), TAA (c), TAA+silymarin (d), TAA+ garlic oil (e) treated rats showing (a),(b) normal deep red shiny smooth liver tissue ,(c) grey red rough surface (d) Comparative healthier smooth surface liver,(e) red colored liver nearly similar to silymarine treated group .

3.3.2. Microscopic examination

In the control group, the histological examination of liver tissue revealed normal structure of the liver parenchyma, displaying radiating cords of hepatocytes from central veins with blood sinusoids between the cords in the control group (Figure 2a). There were no alterations in garlic treated group compared to normal as it also exhibited normal hepatic architecture (Figure 2b). On other hand liver of TAA- treated rats showed evidence of obvious hepatic damage, which is demonstrated by vacuolation, infiltrating with mononuclear lymphocytic inflammatory cells and congestion and edema of central vein (Figures 2c, 2d). Garlic co-treatment attenuated the hepatic damage and showed significant protection of the hepatic cells (Figure 2e). Silymarin treatment rats restored the liver architecture to normal with minimal damage represented in some degenerative vacuolar changes of pericentral area (Figure 2f).

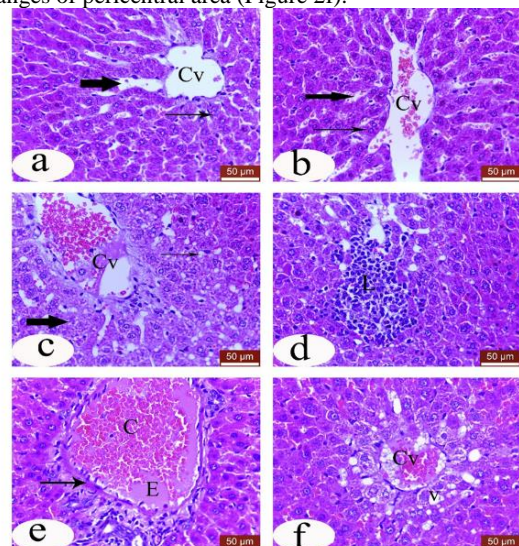


Figure 2 Micrographs of hepatic tissue, (a) Livers of control rats; (b) treated rats with garlic, a and b showed normal hepatic architecture; (Cv) central vein, (thick arrow) blood sinusoid and (thin arrow) radiating cord of hepatocytes. Thioacetamide-intoxicated rats (c, d) which showed congested; vacuolation and lymphocytic cellular infiltration (L). Thioacetamide-injected rats treated with garlic (d) showed edema (E x400), congestion (C) of portal vessels (arrow). Thioacetamide-injected rats treated with silymarin (e) showing congestion of central vein (Cv) and hydropic degeneration and vacuolation of hepatocyte (V). H&E, stain

3.4. Immunohistochemical study

Immunopositive cells were more numerous and displayed a more pronounced immunostaining reaction in the TAA intoxicated liver (Figure. 3c) than those in the control (Figure 3a) and garlic treated rats (Figure 3b) which showed mild staining reaction and the other treated groups, TAA combined with garlic (Figure 3d) which demonstrated moderate staining reaction and combined TAA with Silymarin (Figure 3e) which showed slightly mild immunostaining reaction. On the other hand, Bcl2 immunostaining reaction in liver tissue showed reversed results than were showed in Bax expression. The TAA intoxicated rats showed down regulation of Bcl2 expression in cytoplasm of the affected hepatocytes (Figure 4c) in comparison with control rats (Figure 4a) and garlic treated rats (Figure 4b) which showed mild expression and other treated groups, combined TAA with garlic (Figure 4d) which showed moderate expression and combined TAA with Silymarin (Figure 4e) that manifested by high Bcl2 expression.

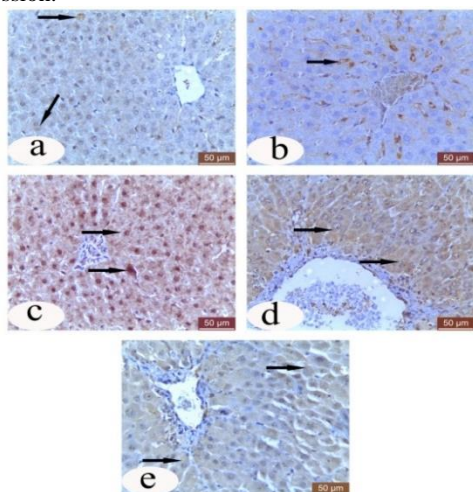


Figure 3 Micrographs of hepatic tissue, (a) Livers of control rats; (b) treated rats with garlic, a and b mild immunostaining reaction to Bax. TAA intoxicated rats (c) which showing marked up regulation of Bax. TAA injected rats treated with garlic (d) showed moderate expression. Combined treatment of TAA with silymarin (e) showing slightly mild immunostaining reaction. Bax immunostaining expression.

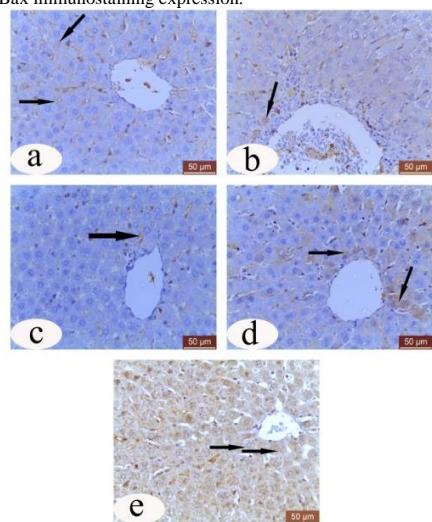


Figure 4 Micrographs of hepatic tissue, (a) Livers of control rats; (b) treated rats with garlic, a and b showed mild immunostaining reaction to Bcl2. Thioacetamide intoxicated rats (c) which showed marked down regulation of Bcl2. TAA injected rats treated with garlic (d) showed moderate expression. Combined treatment of TAA with silymarin (e) showed high immunostaining reaction. Bcl2 immunostaining expression.

4. DISCUSSION

Hepatotoxicity is one of the most common organ injuries. As the digested materials are absorbed and directly transported to the liver to be metabolized and eliminated Oehme, 2008. Drugs pass to liver for metabolism, during which considerable number of drugs produced free radicals, including reactive nitrogen species (RNS) and reactive oxygen species (ROS) which induce liver injury be there oxiditave potentials (Videla, 2009). One of these most toxic drugs for the liver causes hepatic damage, and its toxic metabolite is regarded to impair with the movement of RNA from the nucleus to the cytoplasm, potentially injuring membranes (Isabel, 2009).

Garlic oil is one of natural medicinal products. Its pharmacological effect is attributed to presence of active constituent as sulfur and phenolic compounds which has antioxidant activity.

The purpose of the current study was to investigate any potential protective effects of garlic oil against TAA-induced hepatotoxicity.

AST, ALT, ALP are the most sensitive biomarker indicate hepatic structural damage. Administration of TAA induced a marked increase in ALT, ALP and AST activities. This elevation is due to systemic damage of hepatic cell. In agree with our result Krishna Mohan (2018), Seema et al. (2017) who reported elevation of liver enzymes after TAA intoxication. Also, the increased level of ALP is a reliable marker for biliary flow alteration (Sehrawat et al., 2006) as ALP mainly arises from sinusoidal surface of the hepatocyte and the microvilli of the bile canaliculi and ducts. Restoration of liver enzymes to values nearly to those of control or Silymarin treated groups along with with garlic oil is evidence for the effect of garlic on prohibition of leakage of intracellular enzymes, this finding was in agree with that revealed by Padalko et al. (2012), Sharma et al. (2010) and Alkreathy et al. (2010) who observed that taking of aged garlic extract caused reduction of elevated level of ALT, AST and ALP in rats treated with Cadmium, Lead and Doxorubicin.

TAA also significantly decreased Albumin and total protein that may attributed to hepatocyte damage that resulted in reduction in the capacity of cells to synthesize proteins, while concurrent treatment with garlic oil restored their levels nearly to control and Silymarin -treated groups, similar result was recorded by Nasr, (2014) and Abbas et al. (2013) based on their antioxidant properties.

TAA - intoxication induced significant increase in TC and TG levels while the concentration of HDL was significantly decrease in serum compared to control group. This may be attributed to its bioactivation in the liver to reactive metabolites, causing the production of ROS responsible for oxidative stress which impair metabolic function of liver (Tanbek et al 2017)

Interestingly, garlic oil treatment induced significant reduction in serum level of TG and TC. This may be attributed to its compounds as S-allyl- cysteine which caused reduction of cholesterol. This result and those of Chowdhury et al. (2008) were in the same line and they said that the garlic caused drop in TC is due to decreased hepatic activity of lipogenic enzymes. Drop in TG level may be attributed to that garlic caused decrease of fatty acid synthesis (Elmahdi et al., 2008). On the opposite side, garlic administration led to increase in HDL level and that agreed with Zahid et al. (2005) who mentioned that garlic decreased serum increased

HDL- through inhibiting the activity of hydroxyl-3-methylglutaril- CoA reductase "HMG-CoA.

Excessive reactive species either Oxygen or Nitrogen led to oxidative damage to tissues and organs when they exceed the ability of antioxidant system to eliminate them. In the present investigation, TAA administration caused oxidative stress in hepatic tissue as evidenced by significantly lower levels of CAT, SOD, and GSH as well as significantly higher levels of MDA. Our data was in the same line to that reported by Bashandy et al. (2018). Interestingly, in the present work that administration of garlic oil with TAA protected liver tissues from TAA-induced oxidative stress by enhancing antioxidant status. This restoration is nearly similar to that observed in Silymarin -treated group. The ability of garlic to eliminate hydroxyl and peroxyl radicals is believed to be the reason for the marked decrease in lipid peroxide level in the garlic-treated group Yamasaki et al (1997), Also restoration of lipid peroxidation in group treated with Silymarin is attributed to its ability to scavenge ROS Ramakishan et al. (2006). These results were consistent with those of Mudathir et al. (2008) and Hassan et al. (2009), who stated that garlic polyphenols are an important class of bioactive phytochemicals in garlic that act as antioxidants.

Our study provides evidence of obvious damage to the hepatic parenchyma was observed in TAA treated group. Interestingly liver of rats concurrently treated with garlic oil and TAA showed significant recovery .This result is in agreement with that reported by Krishna et al. (2018) who found that the portal tract liver of group treated with *Allium sativum* ethanolic extract 200 and 400 mg/kg, showed dose-dependent alterations such as a small aggregate of chronic inflammatory cells and moderate portal inflammation, which confirms protective effect of the ethanolic extract against severe hepatic damage induced by TAA. Also, our findings are consistent with those of study reported by Neir et al (2020) who observed that garlic oil pretreatment before deltamethrin reserved the structure of liver tissue.

Both Bax and Bcl-2 are visceral proteins, Bcl-2 promotes cell survival and Bax induces cell death (Youle and Strasser 2008). In apoptosis, Bax stimulates the release of cytochrome C from mitochondria that aids in the cascading activation of caspases ending with cell death while Bcl-2 inhibits Bax from the release of cytochrome C, thus restricting activation of the apoptotic machinery (Janumyan et al. 2008). Also, DNA fragmentation activates Bax and inhibits Bcl-2 up to p53 (Mohamed et al. 2011).

In the present work, Bax and Bcl-2 protein immunohistochemistry revealed that, due to ROS production, which increases apoptosis, Bax protein expression in the liver of TAA-treated rats was significant increased, whereas Bcl-2 protein expression in this group was significantly reduced. Gad et al. (2013) observed that TAA has induced apoptosis and increased caspase 3 expression in liver tissue. these results confirmed the apoptotic effect produced by TAA in our study. On the other hand, based on our results, it was induced that garlic oil and Silymarin CO- co-treatment decreased the Bax expression along with increased Bcl-2 expression which may be owed to their antioxidant properties that reduced apoptosis of hepatocytes (Wang et al., 2018).

5. CONCLUSION

From the current study, it can be concluded that garlic oil is beneficial in improving biochemistry, oxidative/antioxidant stress, histological and immunohistochemical changes

caused by TAA toxicity in the liver. It could be recommended as adjunct therapy in hepatic affections.

6. REFERENCES

1. Aebi, H. 1984. Catalase in vitro. In: Methods in enzymology: Elsevier. p 121-126.
2. Alkreathy, H.; Zoheir, A.D.; Nessar, A.; Mark, S., Soad; S.A., Osman, A.M. 2010. Aged garlic extract protects against doxorubicin-induced cardiotoxicity in rats. Food Chem Toxicol 48, 951–956
3. Bancroft, J. D; Gamble, M. 2002. Theory and practice of Histological Techniques. 5th Ed., Churchill Livingstone, Medical Division of Pearson Professional Ltd.
4. Bashandy, S.A.; Ebaid, H.; Moussa, S.A.A.; Alhazza, I.M.; Hassan, I.; Alaamer, A.; Al Tamimi, J. 2018. Potential effects of the combination of nicotinamide, vitamin B2 and vitamin C on oxidative-mediated hepatotoxicity induced by thioacetamide. Lipids in Health and Disease 17- 29.
5. Beutler, E. 1963. Improved method for the determination of blood glutathione. J. lab. clin. Med. 61, 882-888.
6. Chowdhury, M.M.R.; Manuddin, S.M.; Islam, M.K. 2008. Effects of turmeric and garlic on blood cholesterol level in guinea pig. Banglades J Pharamacol 3, 17-20.
7. Carton, R.S.; Kumer, V.; Fausto, N.; Nelso, F. 2005. Robbins and Cotran pathogenic basis of diseases (7th ed). St. Louis, Mo. Elsevier Saunder (P1110). ISBN0-7216-0187-1.
8. Dumas, B.T; Watson, W.A.; Biggs, H.G. 1971. Albumin standards and the measurement of serum albumin with bromocresol green. Chimica Acta 31, 87-96.
9. El-Mahdi, B.; Khalil, M.M.; Abulgasim, A.I. 2008. The effect of fresh crushed garlic bulbs (*Allium sativum*) on plasma lipids in hypercholesterolemic rats. Res J Anim Vet Sci 3, 15-19.
10. Fassati, P.; Prencipe, L. 1982. Serum triglycerides determined colorimetrically with an enzyme that produces hydrogen peroxide. Clin Chem 28, 2077-2080.
11. Gad, F.A.; Abd Alla, O.A; Farid, A.S.; Fararh, K.M. 2013. Biochemical, Histopathological and Immunohistochemical changes in paracetamol, fish oil and thioacetamide treated rats. Benha Veterinary Medical Journal 25(1), 18-28.
12. Gheith, I.; Elmahmoudy, M.A 2019. Hepcidin-orchestrated Hemogram and Iron Homeostatic Patterns in Two Models of Subchronic Hepatic injury. Biomedical and Environmental Sciences 32, 153-161.
13. Hassan, H.A; El-Agmy, S.M.; Gaur, R.L; Femando, A.; Raj, M.H.G.; Outhit, A. 2009. *In vivo* evidence of hepato- and reno-protective effect of garlic oil against sodium nitrite-induced oxidative stress. Int J Boil Sci 5(3), 249-255
14. Helmy, S.A.; El-Mesery, M.; El-Karef, A.; Eissa, L.A.; El Gayar, A.M. 2018. Chloroquine upregulates TRAIL/TRAILR2 expression and potentiates doxorubicin anti-tumor activity acetamide-induced hepatocellular carcinoma. model. Chem Biol Interact 279, 84-94.
15. Holt, M. P and JU, C. 2006. Mechanism of drug-induced liver injury. The AAPS journal 8(1)E48-E54

16. Isabel, F. 2009. Dysregulation of apoptosis in hepatocellular carcinoma cells. *World J Gastroenterol* 15,513-20
17. Janumyan, Y.; Cui, Q.; Yan, L.; Sansam, C.G.; Valentin, M.; Yang, E. 2008. G0 function of BCL2 and BCL-xL requires BAX, BAK, and p27 phosphorylation by Mirk, revealing a novel role of BAX and BAK in quiescence regulation. *J Biol Chem* 283, 34108–34120.
18. Krishna, M.; Madhan, M. 2018. Evaluation of hepatoprotective activity of *Allium sativum* ethanolic extract in thioacetamide induced hepatotoxicity in albino Wistar rats. *American Journal of Research in Medical Sciences*, 3(2), 48–53
19. Kumar, G.L.; Rudbeck, L. 2009. *Education Guide: Immunohistochemical Staining Methods*. 5th Edition. Dako North America, Carpinteria, California, USA.
20. Lopes-Virella; M.F.; Stone, P.; Ellis, S.; Colwell, J.A. 1977. Cholesterol determination in high-density lipoproteins separated by three different methods. *Clinical chemistry* 23, 882-884.
21. Mohamed, S.O.; Nawaz, M.; Ahsan, H. 2011. Role of Bcl-2 family proteins and caspases in the regulation of apoptosis. *Mol Cell Biochem* 351, 41–58.
22. Mudathir, K.F.; Suru, S.M.; Fafunso, M.A.; Obioha, U.E.; Faremi, T.Y. 2008. Protective roles of onion and garlic extracts on cadmium-induced changes in sperm characteristics and testicular oxidative damage in rats. *Food and Chem Toxicol* 46, 3604-3611.
23. Mumtaz, S.; Ali, S.; Khan, R.; Shakir, H.A.; Tahir, H.M.; Mumtaz, S.; Andleeb S. 2020. Therapeutic role of garlic and vitamins C and E against toxicity induced by lead on various organs. *Environ. Sci. Pollut. Res.*;27(9):8953-8964.
24. Nasr, A. Y. 2014. Protective effect of aged garlic extracts against the oxidative stress induced by cisplatin on blood cells parameters and hepatic antioxidant enzymes in rats. *Toxicol Rep* 16(1), 682-691.
25. Ncir, M.; Ali, B.M.; Hanen, S.; Mohamed, S.A.; Amina, L.; Fatma, M.A.; Tahia, B., Noureddine, A.; Abdelfattah, E.F; Mongi, S. 2020. Protective effects of *Allium sativum* essential oil rich in disulfides against deltamethrin induced oxidative stress and hepatotoxicity in rats. *Journal of Food Measurement and Characterization* 14, pages 2667–2675.
26. Nishikimi, M; Rao, N.A.; Yagi, K. 1972. The occurrence of superoxide anion in the reaction of reduced phenazine methosulfate and molecular oxygen. *Biochemical and biophysical research communications* 46, 849-854.
27. Oehma, W. 2008. *Comparative toxicology laboratories*, Kanas state university, Manhattan, KS66506-5606, USA, the basic science of poison ,7th ed ,MC –Graw Hill, New York, P557-567.
28. Ohkawa, H.; Ohishi, N.; Yagi, K. 1979. Assay for lipid peroxides in animal tissues by thiobarbituric acid reaction. *Analytical biochemistry* 95, 351-358.
29. Padalko, V; Kozlova, E.; Leonova, I. 2012. Protective efficacy of garlic on cadmium induced oxidative stress in young and adult rats. *Oxid. Antioxid. Med. Sci.* 1(2),101–109
30. Ramakrishnan, G.; Raghavendran, H.R.; Vinodhkumar, R. 2006. Suppression of N-nitrosodiethylamine induced hepatocarcinogenesis by Silymarin in rats. *Chem Biol Interact* 161, 104-14
31. Reitman, S.; Frankel, S. 1957. A colorimetric method for the determination of serum glutamic oxalacetic and glutamic pyruvic transaminases. *American Journal of Clinical Pathology* 28, 56-63.
32. Richmond, W. 1973. Preparation and properties of a cholesterol oxidase from *Nocardia* sp. and its application to the enzymatic assay of total cholesterol in serum. *Clinical chemistry* 19, 1350-1356.
33. Seema, Z.; Tanveer, A.W; Abir, A.A.; Majid, A.G. 2017. Amelioration of thioacetamide-induced liver toxicity in Wistar rats by rutin. *International Journal of Immunopathology and Pharmacology* 30 (3), 207-214
34. Sehrawat, A.; Khan, T.H.; Prasad, L.; Sultana, S. 2006. *Butea monosperma* and chemomodulation: protective role against thioacetamide-mediated hepatic alterations in Wistar rats. *Phytomedicine* 13, 157–63.
35. Shalaby, M.A.; Hammada, A.A. 2015. Protective effect of *Allium Sativum* juice and oil with vitamin E against testicular toxicity in rats. *World Journal of Pharmacy and Pharmaceutical sciences* 4(1), 155-170
36. Sharma, A.; Sharma, V.; Kansal, L. 2010. Amelioration of lead-induced hepatotoxicity by *Allium sativum* extracts in Swiss albino mice. *Libyan J. Med* 5(1):4621. doi: 10.3402/ljm. v5i0.4621.
37. Tanbek, K; Ozerol, E; Bilgic, S; Iraz, M; Sahin, N, Colak, C. 2017. protective effect of *Nigella sativa* oil against thioacetamide-induced liver injury in rats. *Medicine Science* 6(1):96-103
38. Videla, L.A. 2009. Oxidative stress signaling underlying liver diseases and hepatoprotective mechanism. *World Journal of Hepatology* 1 (1), 72-78.
39. Wang, L; Huang, Q; Li, YX; Huang, Y.F; Xie, J.H; Xu, L.Q; Dou, Y.X; Su, Z; Zeng, H, Fand Chen, J.N. 2018. Protective effect of silymarine on triptolide –induced acute hepatotoxicity in rats
40. Yamasaki, T; Lau, B.H. 1997. Garlic compounds protect vascular endothelial cells from oxidant injury. *Nippon Yakurigaku Zasshi.* 110(1),138-141
41. Yan-YU, Yun, M; S.; Zhi-P, C; Qi-neng, P. 2006. Preparation of Silymarin proliposome: a new way to increase oral bioavailability of Silymarin in beagle dogs. *International journal of pharmaceuticals* 319, 162-168.
42. Youle, R.J.; Strasser, A. 2008. The BCL-2 protein family: opposing activities that mediate cell death. *Nat Rev Mol Cell Biol* 9, 47–59.
43. Zahid AM, Hussain ME, Fahim M. 2005. Antiatherosclerotic effects of dietary supplementations of garlic and turmeric: restoration of endothelial function in rats. *Life Sci.*, 77(8): 837-857.