

Mandibular Ridge Augmentation Using Customized Titanium Mesh

Muhammad A Nawwar^{1*}, Eldibany R², Lydia N Melek³

1. Oral and Maxillofacial Surgery Department, Faculty of Dentistry, Alexandria University
2. Professor of Oral and Maxillofacial Surgery, Faculty of Dentistry, Alexandria University
3. Assistant professor of Oral and Maxillofacial Surgery, Faculty of Dentistry, Alexandria University

Introduction

Titanium Mesh (TiMe)is widely used in ridge augmentation. Computer guided surgery now plays an important role to improve the techniques and results in ridge augmentation procedures.

Objectives

Are to evaluate the use of mandibular three-dimensional (3D) printed model for prebending and customization of TiMe to be used in mandibular ridge augmentation compared to the conventional technique

Material and methods

This study included 14 patients divided equally into a study and control groups. Control Group treated by conventional method. In the study group, a 3D virtually created model (Fig.1) was used to contour the titanium mesh according to the needed amount of augmentation which helps in contouring the graft material (Fig.2).

Cone beam computed tomography (CBCT) was performed immediately postoperatively and six months later to evaluate the outcome of the procedure.

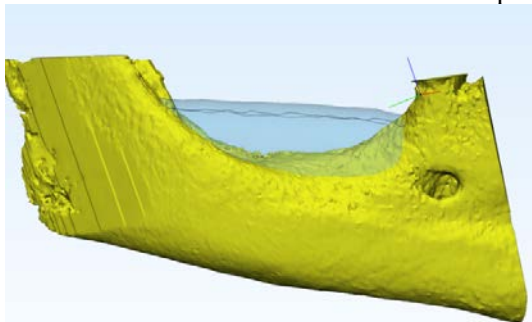


Figure (1): Virtual augmentation

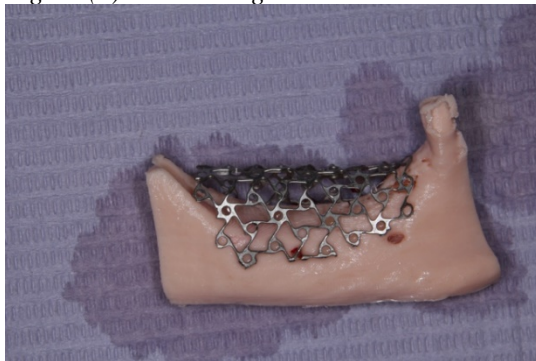


Figure (2): TiMe pre-adaptation using 3D model

Results

The mean of the operation time in study group was 66.43 ± 14.35 minutes opposite to control group in which the mean of the operation time was 122.9 ± 9.94 minutes. Immediately after the surgery, the mean of gained vertical dimension in the study group was 6.14 ± 0.48 mm and in control Group was 4.81 ± 0.73 mm while Six-months radiographic follow-up the mean of the gained vertical dimension in the study group was 5.36 ± 0.51 mm and in control group was 1.64 ± 1.25 mm (Fig. 3).

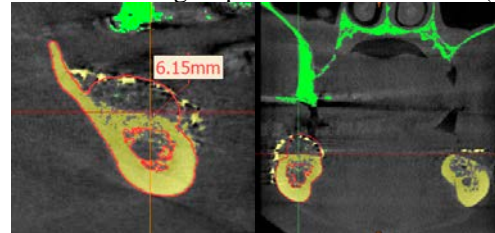


Figure (3): Follow up CBCT for augmented ridge

Conclusion

This study revealed the efficiency of the pre-customized titanium mesh in increasing the vertical bone height and decreasing the operation time.

References

- Hansson S, Halldin A. Alveolar ridge resorption after tooth extraction : A consequence of a fundamental principle of bone physiology. J Dent Biomech. 2012;3.
- dal Polo MR, Poli P, Rancitelli D, Beretta M, Maiorana C. Alveolar ridge reconstruction with titanium meshes : A systematic review of the literature. Med Oral Patol Oral Cir Bucal. 2014;19(6):639–46.
- Jacek B, Maciej P, Tomasz P, Agata B, Wies K. 3D printed models in mandibular reconstruction with bony free fl aps. J Mater Sci Mater Med. 2018;29(2):23.
- Hartmann A, Seiler M. Minimizing risk of customized titanium mesh exposures – a retrospective analysis. BMC Oral Health. 2020;20(1):36.