

ACCURACY OF CONE BEAM COMPUTED TOMOGRAPHY AND DIGITAL RADIOGRAPHY VERSUS CLEARING TECHNIQUE IN DETECTION OF CONFLUENT CANALS IN MANDIBULAR MOLARS (IN VITRO STUDY)

Faten M. Farid^{1*} BDS, Salma MH. Genena³ PhD, Sybel M. Moussa³ PhD,

1. Conservative, Faculty of Dentistry, Alexandria University, Egypt.

2. Lecturer of Endodontic, Conservative, Dentistry Department, Faculty of Dentistry, Alexandria University, Egypt.

3. Professor of Endodontic, Conservative, Dentistry Department, Faculty of Dentistry, Alexandria University, Egypt.

*Corresponding author: Name: Faten Mohamed Farid, E-Mail: Fatenmohamedfarid@gmail.com, Phone: 01028033850

INTRODUCTION

One of the most important and challenging issues in root canal treatment is canal morphology. Canal confluence is one of those challenging anatomic findings, often result in abrupt curvatures that could overstress instruments and cause their intracanal breakage, so the recognition of a confluence is a key factor in performing appropriate root canal treatment (1).

METHODOLOGY

This study was conducted on thirty-three extracted humans first and second mandibular molars (for periodontal reasons). All samples were inserted into a human cadaver's mandible, the teeth were mounted in the prepared alveolar sockets in the molar region to simulate a natural alignment and were fixed in the socket by wax. The teeth were scanned by CBCT and DPR from 0° and 20° mesial- and distal-tube shifts, then cleared and examined by stereomicroscope. All interpreted Data from CBCT and DPR were statistically compared with clearing technique by using Receiver operating curve analysis test (MedCalc Software Ltd. Version 20.115) and the statistical significance was set at ($p < 0.05$).




Figure (1): Mandibular specimen (a) embedded in its putty template (b) The angle between the X-ray beam and the tooth being imaged is measured by a mathematical protractor (c) The phosphor plate (d) is set in position by a standard posterior intra-oral film holder (e)

RESULTS

The statistical analysis showed that there was no significant difference between CBCT and the clearing technique ($p = 0.12$). However, a significant difference was found between the DPR and the clearing technique ($p < 0.001$). Sensitivity, specificity, Youden index, and AUC values were higher for CBCT than DPR. Sensitivity was 0.95 for CBCT compared to only 0.63 in case of DPR, and specificity was 0.98 and 0.87, for CBCT and DPR, respectively. DPR was able to correctly distinguish confluent canals in 63.2% of those identified by clearing method, compared to 94.7% correctly distinguished by CBCT.

DISCUSSION

To the best of our knowledge, various studies were conducted to study the canal morphology and proper anatomy. (2,3). However, the current study concerns about comparing CBCT with digital periapical radiography in the

detection of confluent canals. Our results were in agreement with Kongkiatkool, P et al. who compared CBCT to periapical radiography in evaluating the root canal configuration of mandibular first premolars by using a clearing technique (4). Within limitations of the current study, the null hypothesis was partially rejected.

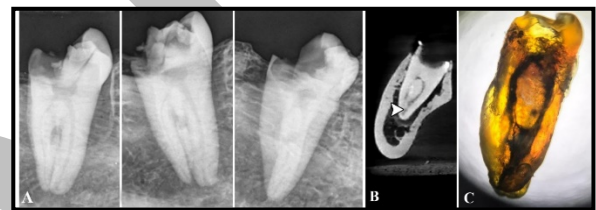


Figure (1): images (B) and (C) show matching between CBCT and clearing technique in detection of confluent canals while image (A) taken from different angulations shows that Digital periapical radiograph can't detect the presence of confluent canals.

Table (1): Diagnostic accuracy of digital PA and CBCT for detection

Canal	Radiographic modality	Sensitivity	Specificity	Youden index	AUC	95% CI	SE	P value of AUC
All canals	Digital PA	0.63	0.87	0.50	0.752	0.67, 0.82	0.02	<0.001*
	CBCT	0.95	0.98	0.96	0.96	0.92, 0.99	0.04	<0.001*
	P value of comparison	Difference between areas= 0.21 95% CI= 0.12, 0.30 P value= <0.001*						

CI: Confidence Interval, SE: Standard Error, AUC: Area under curve

*Statistically significant at p value < 0.05

CONCLUSION

Within the limitation of this study it was concluded that, CBCT has a greater accuracy in detection of confluent canals than digital periapical radiography in mandibular molar teeth. Limitations of digital periapical radiography must be recognized for reliable canal anatomy assessment in confluent canals.

REFERENCES

- Gambarini G, Ropini P, Piasecki L, Costantini R, Carneiro E, Testarelli L, et al. A preliminary assessment of a new dedicated endodontic software for use with CBCT images to evaluate the canal complexity of mandibular molars. *Int Endod J*. 2018;51:259-268.
- Vertucci FJ. Root canal morphology and its relationship to endodontic procedures. *Endod Topics* 2005;10:3-29.
- Furri M. Differences in the confluence of mesial canals in mandibular molar teeth with three or four root canals. *Int Endod J* 2008;41:777-80.
- Kongkiatkool P, Puapichartdumrong P, Tantanapornkul W, Piyapattamin T, Wisithphrom K. Accuracy of digital periapical radiography and cone beam computed tomography for evaluation of root canal configuration in human mandibular first premolars. *J Int Dent Medical Res* 2020;13:80-85.