

INCIDENCE OF CAROTID STENOSIS WITH MULTIPLE CORONARY ARTERY DISEASE IN ISCHEMIC STROKE PATIENTS AMONG EGYPTIAN POPULATION

By

Wael Khalefa Gad Ahmed², Sayed Ahmed fathy El-Zayat¹, Ahmed Abd El-Kader Nemr², Khaled Mohamed Sobh¹, Khaled Mohamed Yahia El-Nady³ and Ahmed Mohamed Abd El-Gafar Zidan⁴

¹Department of Neurology, Faculty of medicine, Al-Azhar University

²Department of Neurology, Al-Maadi Military Hospital

³Department of Cardiology, Al-Maadi Military Hospital

⁴Department of Diagnostic Radiology, Faculty of Medicine, Al-Azhar University

E-mail: wael.khalefa5@gmail.com

ABSTRACT

Background: An association between carotid atherosclerosis and coronary artery disease (CAD) has been well established as atherosclerosis is considered to be a generalized disease. Furthermore, many imaging modalities are used to assess cerebral vascular abnormalities.

Objective: To assess carotid and coronary stenosis association, along with imaging modalities to diagnose carotid stenosis.

Patients and Methods: A prospective cohort study was conducted between November 2019 to February 2021 in Al-Hussein University Hospital, Al-Maadi Military Hospital and Misr El-Qadema Mabara Hospital with 120 patients divided in two equal groups; the first group was patients who have cerebrovascular stroke, and the second group was patients who have multiple coronary artery diseases. Carotid and coronary stenosis were assessed in each group. All patients had been investigated with CT angiography and carotid duplex.

Results: The prevalence of coronary artery diseases among patients with carotid stenosis was 26.6% with 16 patients from 60 patients. On the other hand, the prevalence of carotid artery stenosis among patients with coronary artery diseases was 31.6% with 19 patients from 60 patients. Subsequently, There is a significant positive correlation between coronary and carotid stenosis with ($r= 0.886$; CI 95% = 0.813-0.932; $P < 0.001$). CT angiography was more sensitive than carotid duplex but, on the other hand, carotid duplex was more specific in detecting carotid stenosis.

Conclusion: There was a significant association between coronary artery stenosis and carotid vascular abnormalities. Additionally, digital subtraction angiography remains the gold standard imaging modality in detecting carotid stenosis.

Keywords: Coronary artery disease, CT angiography, Digital subtraction angiography, Carotid stenosis, Coronary stenosis.

INTRODUCTION

The cerebral circulation maintains sufficient cerebral blood flow under various hemodynamic conditions via regional vasoconstriction and vasodilation. Vasodilator capacity can be characterized by cerebrovascular reactivity (CVR) which can be assessed by the breath holding index (BHI) measuring the degree of vaso-relaxation in response to an increased carbon dioxide level during breath hold. Impaired CVR has been suggested as a risk factor for future stroke, white matter hyperdensities, subcortical infarctions, dementia and Parkinson's disease (*Rucka et al., 2015*).

An association between carotid atherosclerosis and coronary artery disease (CAD) has been well established because atherosclerosis is considered to be a generalized disease. It is estimated that these two conditions could be coexist ranging between 2-22% with the average of 8 %. These two conditions can be viewed as same disease process but different organs manifestation (*Wu et al., 2017*).

It was found that the patients who underwent coronary artery bypass graft (CABG) prior to carotid endarterectomy (CEA) have 3% risk of stroke, and the patient who underwent CEA prior to CABG also have 3% risk of myocardial infarction. The mechanism of stroke during CABG most frequently due to manipulation of "diseased" aortic arch during the surgery with a very small portion truly due to hemodynamics failure (*Naylor et al., 2014*).

Therefore, the subset of patient who has both carotid stenosis and CAD requiring CABG represent "vasculopathy"

or significant burden of atherosclerotic disease. This group of patient also have higher incidence of left main and a poorer left ventricular ejection fraction than that isolated CAD (*Halliday and Bax, 2018*).

The diagnosis of intracranial stenosis has improved with the advent and availability of non-invasive vascular imaging tests. Conventional catheter-based angiography remains the gold standard but has potentially serious risks and limited availability. Hence, magnetic resonance angiography (MRA), computerized multislices tomographic angiography (CTA), and transcranial Doppler (TCD) are the most commonly employed non-invasive modalities in the diagnostic evaluation of intracranial stenosis. Each has its own attributes and limitations. Besides, their utility in the anatomic diagnosis of intracranial stenosis, non-invasive imaging can also provide critical physiologic information (such as blood flow characteristics) which can assist in prognostication and recurrent stroke risk stratification (*Duffis et al., 2013*).

The present work aimed to assess the coincidence between multiple coronary artery diseases with carotid (extra and intra cranial part) artery stenosis, and evaluate the role of CT angiography and color Duplex versus digital subtraction angiography in evaluation of carotid stenosis.

PATIENTS AND METHODS

This study was conducted on 120 patients diagnosed as ischemic stroke with carotid artery stenosis and/or who have significant multiple coronary artery disease the patients were divided into two

equal groups: The first group has cerebrovascular stroke, and the second group has multiple coronary artery disease. The work was conducted at Al-Hussein University Hospital, Al-Maadi Military Hospital and Misr El-Qadema Mabara Hospital from November 2019 to February 2021. Study approval was given by the Research Ethics Committee of Al-Azhar Faculty of Medicine, Cairo, Egypt.

Inclusion criteria:

- Both sexes.
- Patients diagnosed as ischemic stroke.
- Patients diagnosed with multiple coronary artery disease and subjected for more than one coronary stent or CABG.

Exclusion criteria:

- History of autoimmune disease.
- History of rheumatic heart disease.
- Diagnosis of hemorrhagic stroke.
- Drug abuse.
- Radiation exposure.
- Patients diagnosed as Moya Moya Disease.

All patients were subjected to a full history for vascular risk factors. Data for the conventional vascular risk factors were collected from the medical history and laboratory tests. Hypertension was defined as a systolic blood pressure > 140 mm Hg and a diastolic blood pressure > 90 mm Hg. Diabetes mellitus was diagnosed based on the recommended

criteria of the American Diabetes Association, i.e. (1) symptoms of diabetes and a plasma glucose level > 200 mg/dl; (2) a fasting plasma glucose level 126 mg/dl, and (3) a history of diabetes or medication for glycemic control. Hyperlipidemia was defined as follows: previously diagnosed and treated hyperlipidemia or fasting total cholesterol > 240 mg/dl or LDL cholesterol > 160 mg/dl. The smoking status was classified as smokers or nonsmokers. Furthermore, all patients were subjected to carotid CT angiography and carotid ultrasound. Only few patients with higher suspicion were subjected to digital subtraction angiography. Regarding coronary stenosis, all patients were subjected to CT coronary angiography.

Statistical Analysis:

The collected data were organized, tabulated, and statistically analyzed using SPSS software statistical computer package (IBM Corp., Armonk, NY, USA). Categorical variables were expressed as number and frequencies. It was compared using Chi Square test or Fisher exact test when the expected value was less than 5. Correlations between outcome variables were performed using Spearman correlation coefficient. Receiver operating characteristic (ROC) curve and area under curve (AUC) were performed to assess the diagnostic ability of imaging in carotid stenosis. Consequently, sensitivity and specificity were further done. A two-sided p-value of <0.05 was considered statistically significant.

RESULTS

In the present work, 60 patients with cerebrovascular stroke and carotid stenosis were included in the first group and 60 other patients with multiple vessels coronary artery disease in the other group. Range of age was 21-72 years. Forty-two patients were males and 18 patients were females in the carotid group, while coronary group had 36 males and 24 females. Supported by clinical and investigations, the prevalence of coronary

artery disease among patients with carotid stenosis was 26.6% with 16 patients from 60 patients. On the other hand, the prevalence of carotid artery stenosis among patients with coronary artery disease was 31.6% with 19 patients from 60 patients. There was a significant positive correlation between coronary and carotid stenosis with ($r= 0.886$; CI 95% = 0.813-0.932; $P < 0.001$) (Figure 1 and Table 1).

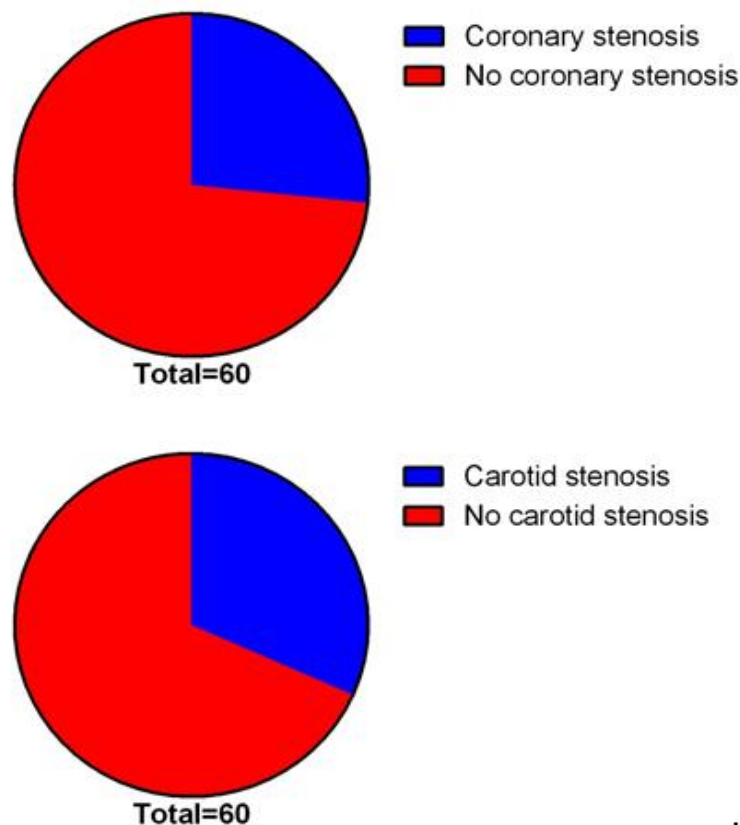


Figure (1): Pie chart of carotid and coronary stenosis in each group

Table (1): Relationship between carotid and coronary stenosis

	R	95% CI	P value
Coronary-Carotid stenosis association	0.89	0.81-0.93	< 0.001

Regarding risk factors of vascular stenosis among carotid group, there was significant difference comparing coronary stenosis finding in this group. There were 11 patients with hypertension, and 10 diabetic patients in patients with coronary stenosis, while there were 16 hypertensive patients and 19 diabetic patients in coronary group. This indicates hypertension as effective risk factors for

coronary stenosis in patients with carotid artery disease (**Table 2**).

Regarding coronary group, there was non-significant difference comparing carotid stenosis finding in this group. There were 13 patients with hypertension, and 11 diabetic patients in patients with carotid stenosis, while there were 17 hypertensive patients and 15 diabetic patients in the coronary group.

Table (2): Vascular risk factor among study groups

Parameters \ Groups	Carotid group					Coronary group				
	Coronary stenosis N=16		No coronary stenosis N=44		P	Carotid stenosis N=19		No carotid stenosis N=41		P
	N	%	N	%		N	%	N	%	
Hypertension	11	68.7	16	36.3	0.026	13	68.4	17	41.4	0.052
Diabetes mellitus	10	62.5	19	43.1	0.19	11	58	15	36.5	0.121
Hyperlipidemia	2	12.5	5	11.3	0.903	5	26	7	17	0.405
Smoking	8	50	11	25	0.066	10	52.6	14	34	0.174

The patients included in the study were subjected to both CT angiography compared with carotid duplex. Furthermore, patients with intracranial suspicious were subjected to digital subtraction. Among all 120 patients we found that CT angiography have an upper hand over carotid duplex. Moreover,

digital subtraction was more sensitive than other two modalities as it was the gold standard one. Imaging modalities were different in detecting carotid stenosis, as CTA was more sensitive than carotid duplex but, on the other hand, carotid duplex was more specific (**Table 3 and Figure 2**).

Table (3): Sensitivity and specificity of methods for carotid stenosis evaluation

Parameters \ Methods	Sensitivity	95% CI	Specificity	95% CI
CTA	86.73	78.4 - 92.7	72.73%	49.8 - 89.3
Carotid Duplex	80.61%	71.4 - 87.9	95.45%	77.2 - 99.9

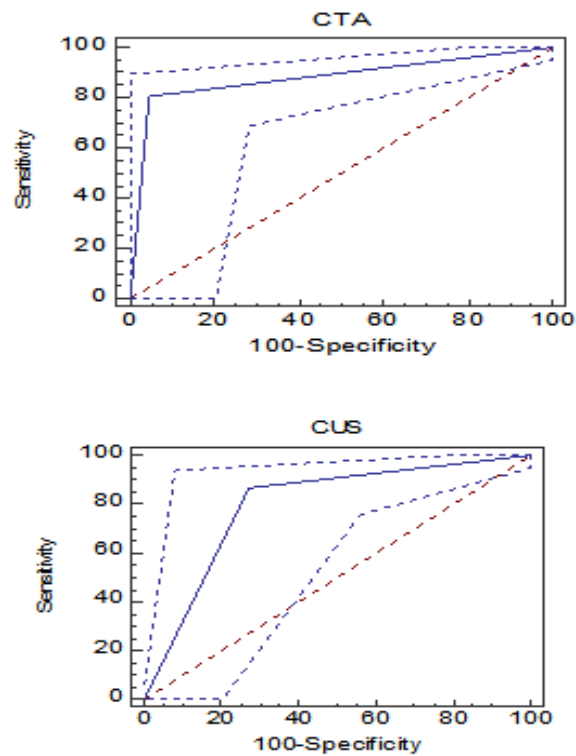


Figure (2): Sensitivity and specificity for carotid ultrasound and CTA in detecting carotid stenosis

DISCUSSION

This study revealed that the CAS was strongly associated with CAD. The prevalence of CAS in patients with CAD was 31.6%. The difference was statistically significant. Supportingly, a cross-sectional study was conducted by *Seo et al.* (2019) to evaluate the prevalence and clinical outcomes of asymptomatic carotid artery stenosis, and found that the prevalence of CAS in patients with CAD was 25.5%, but the result was not statistically significant. In addition, *Iwasaki et al.* (2011) assessed the prevalence of CAS in patients with CAD in Japanese population detected by carotid ultrasound. The prevalence was 19.6%, lower than that reported by *Iwasaki et al.* (2011) and *Seo et al.* (2019). This discrepancy may be

attributable to the different assessment tool and the different population characteristics.

Regarding risk factors of carotid stenosis among the coronary diseased group, there was a statistically significant difference comparing carotid stenosis finding in this group. This study indicated that hypertension was significant risk factors for carotid stenosis in patients with coronary artery disease. Supportingly, a cross-sectional study was conducted by *Mancheva et al.* (2020), and found that diabetes and smoking are independently related to increase CIMT. Measuring CIMT can detect early arterial wall changes. In addition, another cross-sectional study was conducted by *Gong et al.* (2020) who revealed that age, sex, medical history of hypertension, coronary

heart disease, and diabetes were risk factors for carotid atheromatous plaque formation.

This study highlighted that the sensitivity and specificity of CTA were 86.73% and 72.73% respectively, and of CDU was 80.61% and 95.45%, respectively. Imaging modalities were different in detecting carotid stenosis as CTA was more sensitive than carotid duplex but, on the other hand, carotid duplex was more specific. Similar to our results, a systematic review revealed that the sensitivity and specificity of CTA were 81.7% and 85.6%, respectively and CDU was 85.1% and 86.4%, respectively. Both imaging modalities detected a degree of stenosis greater than 50%. Unlikely, the sensitivity and specificity of both imaging modalities increased when the degree of stenosis was greater than 70%. The results were 90.6% and 93%, for CTA respectively, and 92.3% and 89%, for CDU respectively. According to the results of the systematic review, CDU sensitivity and specificity improved to 98.7% and 94.1%, respectively, where peak systolic velocity (PSV) and end diastolic velocity (EDV) were assessed (*Forjoe and Asad Rahi; 2019*). Consequently, these data suggested that a combination of the PSV and EDV consensus criteria should be used for CDU assessment of stenosis to sufficiently provide diagnostic confidence (*Franco-Gutiérrez et al., 2019*).

This study demonstrated the distribution pattern of atherosclerotic stenosis and severity of extracranial, intracranial and coronary arteries. Regarding intracranial stenosis, mild grades of stenosis <50% were noticed in

PCA and BA, whilst severe stenosis $\geq 50\%$ was higher in ACA. In addition, extracranial stenosis, of any grade, was more prevalent in ICA than CCA. In a Chinese multicenter study, *Hua et al; (2019)* stated that the proportion of patients with intracranial artery stenosis was higher than those with extracranial artery stenosis, and the proportion of anterior circulation artery stenosis was higher than that in the posterior circulation. In addition, another study, conducted by *Shrivastava et al., (2016)* evaluated the segmental distribution of intracranial and extracranial stenosis. They found that the most commonly involved intracranial stenosis segment was MCA, and the most commonly involved extracranial stenosis segment was ICA.

Multiple limitations were present in our study. First, the imaging modalities in the present study were used to identify stenosis greater than 50%, which was associated with less sensitivity and specificity than identification of stenosis greater than 70%. Second, the presence of concurrent CAD was the major risk factor for the occurrence of peri-CAS cerebral ischemic lesions in our study, but its underlying mechanism was not well evaluated. Third, the correlation between carotid plaque composition features and risks for peri-CAS cerebral ischemic lesions were not evaluated.

CONCLUSION

Both symptomatic and asymptomatic CAD can be commonly found in patients with CAS, and patients with CAD may carry a higher risk for the occurrence of peri-CAS cerebral lesions than patients without CAD. Additionally, digital subtraction angiography remained the

gold standard imaging modality in detecting carotid stenosis.

REFERENCES

- Duffis EJ, Jethwa P, Gupta G, Bonello K, Gandhi CD and Prestigiacomo CJ. (2013):** Accuracy of computed tomographic angiography compared to digital subtraction angiography in the diagnosis of intracranial stenosis and its impact on clinical decision-making. *Journal of Stroke and Cerebrovascular Diseases*, 22(7):1013-7.
- Forjoe T and Asad Rahi M. (2019):** Systematic review of preoperative carotid duplex ultrasound compared with computed tomography carotid angiography for carotid endarterectomy. *The Annals of The Royal College of Surgeons of England*, 101(3):141-9.
- Franco-Gutiérrez, R., Pérez-Pérez, A. J., Franco-Gutiérrez, V., Testa-Fernández, A. M., López-López, A., Pérez-Fernández, R., López-Reboiro, M. L., Regueiro-Abel, M., Crespo-Leiro, M. G. and González-Juanatey, C. (2019):** Usefulness of carotid ultrasonography in the assessment of coronary artery disease extension in patients undergoing exercise echocardiography. *Echocardiography*, 36(2): 336–344.
- Gong, H. Y., Shi, X. K., Zhu, H. Q., Chen, X. Z., Zhu, J., & Zhao, B. W. (2020):** Evaluation of carotid atherosclerosis and related risk factors using ultrasonic B-Flow technology in elderly patients. *Journal of International Medical Research*, 48(10): 0300060520961224.
- Halliday A and Bax JJ. (2018):** The 2017 ESC guidelines on the diagnosis and treatment of peripheral arterial diseases, in collaboration with the European Society for Vascular Surgery (ESVS). *European Journal of Vascular and Endovascular Surgery*, 55(3):301-2.
- Hua Y, Jia L, Xing Y, Hui P, Meng X, Yu D, Pan X, Fang Y, Song B, Wu C and Zhang C. (2019):** Distribution pattern of atherosclerotic stenosis in Chinese patients with stroke: a multicenter registry study. *Aging and disease*, 10(1):62.
- Iwasaki, M., Kuroda, S., Nakayama, N., Hokari, M., Yasuda, H., Saito, H., and Iwasaki, Y. (2011):** Clinical characteristics and outcomes in carotid endarterectomy for internal carotid artery stenosis in a Japanese population: 10-year microsurgical experience. *Journal of Stroke and Cerebrovascular Diseases*, 20(1): 55-61.
- Mancheva M, Paljoskovska-Jordanova S and Bosevski M. (2020):** Carotid intima media thickness is in a relation to risk factors for coronary artery disease. *Arterial Hypertension*, 183(27):8-14.
- Naylor AR, Schroeder TV and Sillesen H. (2014):** Clinical and imaging features associated with an increased risk of late stroke in patients with asymptomatic carotid disease. *Eur J Vasc*; 48:633-640.
- Rucka D, Marek J, Rucklova Z, Lubanda JC, Havranek S, Skvaril J, Varejka P, Chochola M, Karetova D, Korinek J and Linhart A. (2015):** Arterial stiffening contributes to impairment of cerebrovascular reactivity in patients with coronary artery disease without carotid stenosis. *Physiological Research*, 64(3):335-342.
- Seo J, Kim GS, Lee HY, Byun YS, Jung IH, Rhee KJ and Kim BO. (2019):** Prevalence and clinical outcomes of asymptomatic carotid artery stenosis in patients undergoing concurrent coronary and carotid angiography. *Yonsei Medical Journal*, 60(6):542-548.
- Shrivastava A, Srivastava T and Saxena R. (2016):** CT angiographic evaluation of pattern and distribution of stenosis and its association with risk factors among Indian ischemic stroke patients. *Polish Journal of Radiology*, 81:357-364.
- Wu Y, He J, Sun X, Zhao YM, Lou HY, Ji XL, Pang XH, Shan LZ, Kang YX, Xu J and Zhang SZ. (2017):** Carotid atherosclerosis and its relationship to coronary heart disease and stroke risk in patients with type 2 diabetes mellitus. *Medicine*, 96(39):33-41.

معدل الإصابة بضيق الشرايين السباتية لدى مرضى الشرايين التاجية المتعددة في مجموعة من المرضى المصريين المصابين بالسكتة الدماغية الاقفارية

وائل خليفة جاد أحمد²، سيد احمد فتحي الزيات¹، أحمد عبدالقادر نمر²، خالد محمد

صبح¹، خالد محمود يحيى النادي³، أحمد محمد عبدالغفار زيدان⁴

¹قسم أمراض المخ و الأعصاب، كلية الطب، جامعة الأزهر

²قسم طب المخ و الأعصاب، مستشفى المعادي للقوات المسلحة

³قسم أمراض القلب و الأوعية الدموية، مستشفى المعادي للقوات المسلحة

⁴قسم الأشعة التشخيصية، كلية الطب، جامعة الأزهر

E-mail: wael.khalefa5@gmail.com

خلفية البحث: الدورة الدموية المخية تحافظ على تدفق الدم الكافي للمخ تحت ظروف مختلفة من ديناميكية الدم عن طريق الانقباض والانبساط للأوعية المخية. ويوجد ارتباط بين ضيق الشرايين السباتية والشرايين التاجية نشأت جيداً حيث أن تصلب الشريين مرض عام.

الهدف من البحث: معرفه نسبه المصادفه بين أمراض الشرايين التاجية المتعددة وبين أمراض الشرايين السباتية (الجزء داخل وخارج المخ) و تقييم دور الأشعة بشكل عام و خصوصاً الأشعة المقطعية على الشريين مع الدوبلكس الملون فى تقييم ضيق الشرايين السباتية.

المرضى و طرق البحث: تم عمل البحث في مستشفى الحسين الجامعي و مستشفى المعادي العسكري , مستشفى مبرة مصر القديمة في الفترة بين نوفمبر 2019 و فبراير 2021. تضمنت الدراسة 120 مريض مقسمين الى مجموعتين متساويتين حيث المجموعة الأولى تشمل المرضى الذين تم تشخيصهم بسكتة دماغية اقفاريه غير نازفه و المجموعة الثانية تشمل المرضى الذين لديهم ضيق متعدد بالشرايين التاجية. كل المرضى قد خضعوا للأشعة المقطعية على الشرايين مع الدوبلكس الملون.

نتائج البحث: بعد الفحص الاكلينيكي و الاشعة و التحاليل تبين وجود عدد 16 مريض في مجموعة الشرايين المخية يعانون من قصور في الشرايين التاجية بنسبة 26.6% و على الجهة الاخرى وجد أنه يوجد 19 مريض من مجموعة الشرايين التاجية يعانون من قصور في الشرايين المخية بنسبة 31.6%. و هذا يثبت وجود صلة وثيقة جدا بين القصور في الشرايين التاجية و القصور في الشرايين التاجية و هذا التحليل له أهمية احصائية معتبرة

و بالنسبة للاشعة التي تقوم بتشخيص قصور و ضيق الشرايين المخية تبين القسطرة التشخيصية هي أفضل تقنيات الاشعة في هذا التشخيص و يليه الأشعة المقطعية بالصبغة و يليه الموجات الصوتية على الشرايين السباتية مع وجود حساسية للاشعة المقطعية بالصبغة برقم 86.7% بالمقارنة ب 80.6% في الموجات الصوتية على الشرايين السباتية. أما بالنسبة للخصوصية فقد وجد أنه أعلى في الموجات الصوتية على الشرايين السباتية برقم 95.4% مقارنة برقم 72.7% في الاشعة المقطعية بالصبغة.

الاستنتاج: هناك صلة وثيقة بين القصور في الشرايين المخية و القصور في الشرايين التاجية. و (القسطرة التشخيصية) هي أفضل تقنيات الاشعة في هذا تشخيص القصور في الشرايين المخية.

الكلمات الدالة: القصور في الشرايين التاجية، القصور في الشرايين المخية، الأشعة المقطعية على الشرايين مع الدوبلكس الملون، الموجات الصوتية على الشرايين السباتية.