

# Double Silicone Intubation for Management of Recurrent Acquired Nasolacrimal Duct Obstruction

Mahmoud Abd El-Halim Soliman Rabea, Mohamed Al Taher Abd El Wahab,  
Ehab El Sayed Abd El Salam\*

Department of Ophthalmology, Faculty of Medicine, Al-Azhar University

\*Corresponding author: Ehab El Sayed Abd El Salam, E-mail: dr.ehab\_salam@yahoo.com, Mobile: (020) 01033025334

## ABSTRACT

**Background:** the obstruction of the nasolacrimal excretory system may occur in the proximal puncta, canaliculi, common canaliculus, or more distally within the lacrimal sac or nasolacrimal duct. Nasolacrimal duct obstruction occurs as a congenital or acquired disease. Acquired causes can be numerous.

**Aim of the Work:** to evaluate Dacryocystorhinostomy (DCR) with double silicone tube in the management of recurrent epiphora after failed conventional DCR.

**Patients and Methods:** This is a prospective study which was done on 30 patients with recurrent or persistent acquired epiphora who gave positive past history of previous DCR.

**Results:** Epiphora improved significantly in 27 out of 30 patients (90%) after six month postoperatively.

**Conclusions:** DCR is the gold treatment intervention for acquired nasolacrimal duct obstruction (NLDO) in adults, Silicone intubation (SI) increases success rates and double SI further increases the success rates of DCR for recurrent cases and is considered safe and effective technique.

**Keywords:** DCR, epiphora, NLDO.

## INTRODUCTION

Watering of the eye is an annoying problem embarrassing the patient both socially and functionally. Epiphora, which is defined as watering of the eye due to insufficient drainage of tears through lacrimal passages represent the vast majority of cases with watery eye <sup>(1)</sup>.

The commonest cause of epiphora is nasolacrimal duct obstruction (NLDO), which may be congenital or acquired. Acquired NLDO may be primary or secondary<sup>(2)</sup>.

The primary causes of lacrimal pathway obstruction include acute or chronic inflammation, trauma or congenital malformations. Patients generally present with epiphora and lacrimal sac swelling, purulent secretion, blurred vision and facial pain. Dacryocystitis and recurrent conjunctivitis are typical <sup>(3)</sup>.

Primary or idiopathic acquired nasolacrimal duct obstruction (PANDO) is the commonest cause of NLDO and is defined as a clinical syndrome of complete nasolacrimal duct obstruction without other lacrimal excretory system pathology <sup>(4)</sup>.

The standard surgical procedure for nasolacrimal duct obstruction is dacryo-cysto-rhinostomy (DCR) in which the lacrimal sac is connected directly to the nasal cavity to allow drainage of tears <sup>(5)</sup>.

Although Caldwell was the first to propose an endonasal approach in 1893, it was limited by the technology available at that time. Toti is considered the father of DCR which is external procedure described for the first time, in 1904.

With the advent of rigid nasal endoscopes which facilitated intranasal access to the lacrimal sac, an endoscopic approach became feasible and was first used clinically in the late 1980<sup>(6)</sup>.

## AIM OF THE WORK

It is to evaluate Dacryocystorhinostomy (DCR) with double silicone tube in the management of recurrent epiphora after failed conventional DCR.

## PATIENTS AND METHODS

This is a prospective study which was done on 30 patients attending the outpatient clinic of Ophthalmology department (Al-Azhar University, Damietta). The work was done at the period from March 2016 to April 2017 after an informed consent. **The study was approved by the Ethics Board of Al-Azhar University.**

The following inclusion and exclusion criteria were used:

**Inclusion Criteria:** (1) Patient with recurrent or persistent acquired epiphora who give positive past history of previous DCR. (2) Stable position of both tubes during postoperative follow up period.

**Exclusion Criteria:** Patients with primary acquired epiphora with negative past history of lacrimal surgery, congenital epiphora, involutinal Ectropion, Epiphora secondary to ENT cause (Polyp, Deviated septum and Hypertrophied inferior turbinate) and one or both tube extrusion during follow up period.

The following items were considered:

1- History of watering eyes which may be related to blepharitis or dry eyes, allergies, eye drops, drugs and trauma.

2- History of nasal problems may be an important factor for exclusions.

3- Past history of medical disorder (diabetes mellitus, hypertension, IHD and allergic rhinitis) and their medications and use of blood thinner as well.

4- Past history of previous lacrimal surgery & its details.

5- Examination:

Looking for eyelid malpositions: entropion or ectropion is also easily visible without eyelid manipulation. Looking for patient blinking, both strength and rate. The lower eyelids examined for presence or absence of laxity with the snap test. Scar of previous operation. Amount of epiphora assessment by shirmer test or dye disappearance test.

#### **Preoperative assessment:**

After topical anesthetic is instilled, the lower eyelid punctum was dilated with a lacrimal dilator. The tip of the cannula was then inserted vertically in the ampulla and carefully guided horizontally and medially while maintaining lateral traction on the lower eyelid. The cannula was then advanced to a "hard stop" and withdrawn approximately 1 mm before irrigation of fluid. When gently irrigating, the patient noted the presence or absence of fluid in the nasal passage or pharynx.

To be considered a true functional NLDO, there could not be significant resistance while passing the cannula and a "hard stop" had to be identified in all cases. When this technique was being performed, the cannula was passed in the lacrimal sac beyond the common internal punctum, and consistent pressure was maintained on the syringe while irrigating. Complete reflux through the upper punctum, without evidence of fluid in the nasal passage or pharynx, is diagnostic of a complete NLDO.

All patients receiving blood thinner are reported to their treating cardiologist or internist to stop these medications before surgery and shift to bridging heparin for 2 weeks one before and one after surgery, if possible and safe.

Also, HTN and diabetic patients were reported to their treating doctors for proper control of their medical conditions prior to surgery.

#### **Operative details**

The patient lies in supine position preferably in reverse Trendelenburg position for more efficient haemostasis and dry surgical field as possible.

- General anesthesia with hypotensive technique was advocated in all cases for better visual field.
- After wound marking, a curvilinear incision of about 10-12 mm in length, 3-4 mm from the medial canthus along the nasojugal fold. The skin and subcutaneous tissue are incised with a 15-blade scalpel the orbicularis oculi muscle fibers are separated until the periosteum of the anterior lacrimal crest is identified. The skin and the orbicularis muscle are raised medially and laterally with four traction sutures of 4-0 silk.

- Blunt dissection is carried on to reach the periosteum. A freer's elevator is used to separate the periosteum from the bone and reflect it laterally along with the lacrimal sac to expose the lacrimal sac fossa. All efforts made to preserve the medial canthal tendon and dissected only when needed.
- Once the lacrimal fossa is exposed, identification of maxillo-lacrimal suture, if any, bone punching started at the lacrimal sac fossa. The Kerrison bone punch gently inserted between the bone and the nasal mucosa and the ostium is sequentially enlarged.
- The first step is to create sac flaps. To do this, a Bowman's probe is passed through the lower punctum and bent in such a way to tent the sac as posterior as possible to create a large anterior and small posterior flap. Alternatively fluorescein stained viscoelastic can be injected from the upper punctum to dilate the sac and help in creating flaps. Using the probe as guide, an "H"-shaped incision is made with the help of a number 11 or 15 blade right across the sac from the fundus to the nasolacrimal duct. Flaps are raised and the posterior one is cut.
- The second step is to fashion nasal mucosal flaps. With the help of number 11 blade incisions are made in the nasal mucosa along the bony ostium except anteriorly to have a hinged flap. The large anterior flap is raised.
- It is important to oppose nasal mucosal and sac flap edge to edge. Excess nasal mucosa can be excised in a controlled manner so as to avoid sagging of the flaps that may compromise the tear drainage later.
- After creation and suturing of posterior flaps with 6/0 suture (Vicryl®, ETHICON, polyglycolic acid), double silicone tubes (FCI, France) are inserted one by one, then anterior flaps are sutured with polyglycolic acid 6/0 suture (Vicryl®, ETHICON).

#### **Post-operative follow-up:**

On the third day: Removal of the nasal pack and assessment of the following (wound, edema, cellulitis and pain). One week: (Removal of the stitch, amount of epiphora, ENT bleeding and assessment of the following (wound, edema, cellulitis and pain).

#### **Statistical Analysis of Data**

The collected data were organized, tabulated and statistically analyzed using statistical package for social sciences (SPSS) version 22 (SPSS Inc, Chicago, USA), running on IBM compatible computer. For qualitative data, frequency and percent distributions were calculated. For quantitative data, mean, standard deviation (SD), minimum and maximum were calculated.

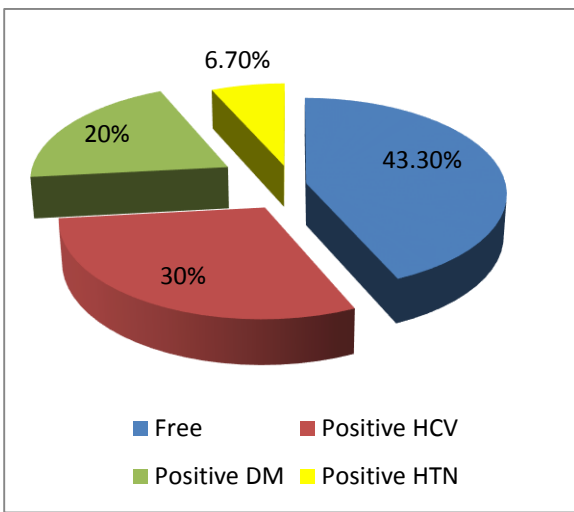
**RESULTS**

The demographic data of the present study were (age;  $49.2 \pm 8.6$  years) and female (83.3%) more affected than male (16.7%) (**table 1**).

**Table (1): Demographic data of studied groups**

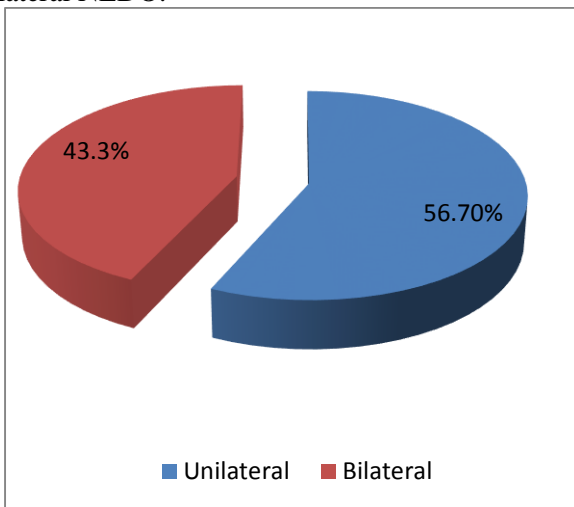
Variable	Mean± SD
Age (years) Mean± SD	49.2 ± 8.6
Sex	
Male	5 (16.7%)
Female	25 (83.3%)

The past history of the study group in the present study was 30% with positive HCV, 20% with DM and 6.7% with HTN (**figure 1**).



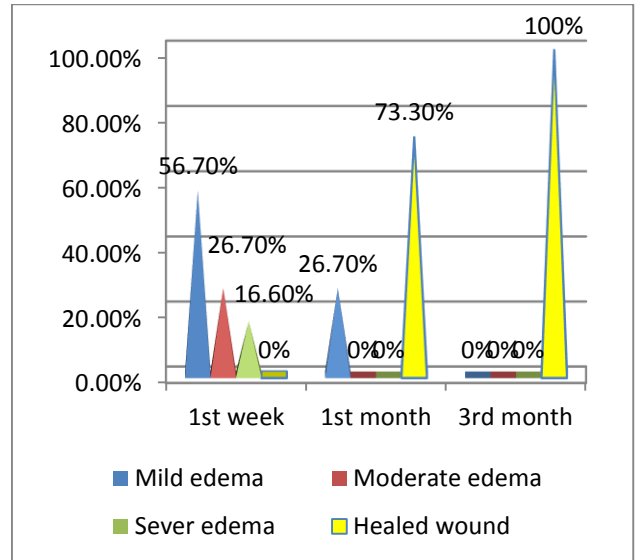
**Figure (1): Past history of the study group.**

Most cases of the study group had unilateral NLDO (56.7%) while 43.3% had bilateral NLDO.



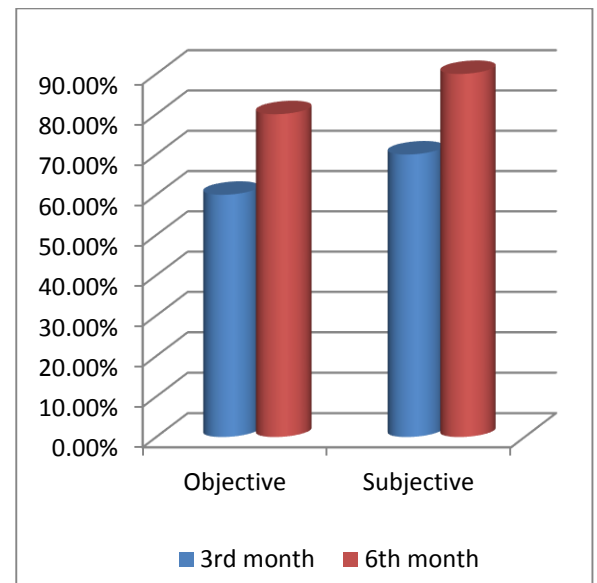
**Figure (2): Laterality among the study group.**

The mild edema (wound edema) at 1st week, 1st month and 3rd month after operation was encountered on 56.7%, 26.7% and 0% of cases respectively. The moderate edema (wound and lower eye lid edema) was encountered on 26.7%, 0% and 0% of cases. The sever edema (wound, upper and lower eye lid edema with narrowing palpebral fissure) was 16.6%, 0% and 0%. The healed wound was encountered on 0%, 73.3% and 100% of cases respectively (**figure 3**).



**Figure (3): Wound state of the study group.**

The objective improvement of epiphora at 3rd month was 60% but at 6th month was 80%. The subjective improvement of epiphora at 3rd month was 70% but at 6th month was 90% (fig. 4).



**Figure (4): Improvement of epiphora after operation of the study group.**

## DISCUSSION

Double silicone intubation is a relatively less invasive procedure, but with a success rate less than that of external and endonasal DCR for partial NLDO (7).

In this study we evaluate DCR with double silicone tube in the management of recurrent epiphora with complete NLDO after failed conventional DCR. In the present study, the NLDO more common in female than male and the mean age in the present work was  $49.2 \pm 8.6$  and these agree with **Andalib *et al.*** (8) who reported that the mean age of NLDO was  $49.45 \pm 19.22$  and noticed no correlation between the increasing age and NLDO.

**Chaudhari *et al.*** (9) found that the incidence of chronic Dacryocystitis was more in the age group 50-60 years. This could be due to more active life and demanding better health and prompt relief at this age.

In the present study, the NLDO is more common in female than male and the mean age in the present work is  $49.2 \pm 8.6$ . Female may be more affected more than male, because of narrow bony nasolacrimal passage and post-menopausal hyperplasia of nasal mucosa.

In contradiction, **Kashkouli *et al.*** (10) and **Andalib *et al.*** (8) reported that gender had no significant association with the accumulation of tight stenosis due to no evidence in favor of the role of sex hormones in pathogenesis of nasolacrimal duct obstruction in adults.

DCR still remains the gold standard treatment for NLD obstruction. Direct visualization of the anatomical structures of nose in external DCR has got advantages over endoscopic DCR. But it has got some disadvantages like cutaneous scar, injury to the angular vein and medial canthal structures, lacrimal pump failure and cerebrospinal fluid (CSF) rhinorrhea. Endonasal DCR has got some advantages; popularity increases due to its equally promising outcome and cosmetic superiority. Lacrimal sac pathology can be directly visualized through the endoscopic procedure and allows immediate diagnosis and management of nasal pathology (11).

In the present study, the subjective success rate of epiphora was 90% at 6 month after operation and this agrees with **Delaney and Khooshabeh** (12) who reviewed the success rate of external DCR for adult patients with partial NLDO and found subjective success rates of 84% at 4 months of follow-up and 70% at 3 years of follow-up. We assume that our higher results of success may be attributed to shorter follow up period (6 months compared to 3 years). **Demerci and Elnor** (13) reported a good success rates (87%) by using double silicone intubation in primary cases of partial NLDO with positive JDTII, despite their much less invasive procedure, our cases

were recurrent with complete NLDO, making intubation alone without DCR of no value. Regarding flap creation many studies have been done to determine the role of flaps on the overall success rate one of these studies done by **Mohamed Al-TaHER** (14) and suggests that flaps don't play that important role in DCR procedures carried out to manage ANLD obstruction and postulate that flapless DCR is a relatively easy, safe and effective procedure in treatment of ANLD obstruction provided that osteotomy of proper size and site was created.

The success of the double bicanalicular silicone intubation relies principally on Poiseuille Law, which states the dependence of resistance to flow to the radius of the path. Placement of two loops of tubing in then asolacrimal system yields four strands passing through the common canaliculus and NLD compared with two strands with conventional single-loop intubation. The theoretical resistance to flow of tears through the NLD can be estimated through the use of Poiseuille Law. The law states that resistance to flow of tears is inversely proportional to the NLD radius to the fourth power (15).

Although, the most common initial treatments of partial LD obstruction were DCR (41%), medical management (31%), and silicone intubation (22%) (16), we believe that DCR with silicone tube is the gold standard treatment for ANLDO.

**Wormald and Tsirbas** (17) assessed the results of lacrimal duct endonasal DCR in adult patients with partial Lacrimal duct (LD) obstruction at a minimum of 12 months' follow-up and reported that 84% of patients had their symptoms resolve after endonasal DCR. In another study, standard endonasal DCR was compared with laser endonasal DCR in adult patients with partial LD obstruction. Of those who underwent standard endonasal DCR, 82% showed resolution or improvement of symptoms, whereas 71% of the laser DCR patients obtained complete or partial success (18). Our study showed better results may be due to more proper exposure of surgical field, meticulous removal of fibrous tissue of previous DCR and shorter follow up period.

**Peterson *et al.*** (19) confirmed that placement of silicone tube for the treatment of congenital NLDO is a safe and effective procedure which comes favour with our results of importance of ST in cases of epiphora due to NLDO.

## REFERENCES

1. **Renato R, Tiana B and Peter-John W (2012):** Endoscopic dacryocysto-rhinostomy. *Braz J Otorhinolaryngol.*, 78(6):113-121.
2. **Boboridis KG, Bunce C and Rose GE (2005):** Outcome of external dacryocystorhinostomy combined with membranectomy of a distal canalicular obstruction. *Am J Ophthalmol.*, 139: 1051-1055.

3. **Burkat CN, Lucarelli MJ (2005):** Tear meniscus level as an indicator of nasolacrimal obstruction. *Ophthalmology*, 112: 344–348.
4. **Caversaccio M, Hausler R (2006):** Insertion of double bicanalicular silicone tubes after endo-nasaldacryocystorhinostomy in lacrimal canalicular stenosis: a 10-year experience. *ORL J Otorhinolaryngol Relat Spec.*, 68: 266–269.
5. **Dolman PJ (2003):** Comparison of external dacryocystorhinostomy with non-laser endo-nasal dacryocysto-rhinostomy. *Ophthalmology*, 110:78–84.
6. **Lester SE, Robson AK and Bearn M (2008):** Endoscopic cold steel versus laser dacryocysto-rhinostomy: completing the audit cycle. *J Laryngol Otol.*, 122: 924-927.
7. **Dareshani S, Saleem T (2013):** To determine the efficiency of probing in partial nasolacrimal duct obstruction (NLD) in adults. *JLUMHS.*, 12(2):79-82.
8. **Andalib D, Nabie R and Kazemi E (2014):** The Effect of Stenosis Nature on Success of Silicone Intubation for Nasolacrimal Duct Stenosis in Adults. *Iranian Journal of Ophthalmology*, 26(3):166-169.
9. **Chaudhari A, Chaudhari P, Ahir HD et al. (2012):** Study of comparison between dacryocystorhinostomy surgery with pawar's implant and conventional dacryocystorhinostomy surgery. *National Journal of Medical Research*, 2(4): 508-513.
10. **Kashkouli MB, Sadeghipour A, Kaghazkanani Ret al. (2010):** Pathogenesis of primary acquired nasolacrimal duct obstruction. *Orbit*, 29(1):11-15.
11. **Khan MK, Hossain MA, Hossain MJet al. (2011):** Comparative Study of external and endoscopic endonasal dacryocystorhinostomy for the treatment of chronic dacryocystitis. *JAFMC Bangladesh*, 2:15-17.
12. **Delaney YM, Khooshabeh R (2002):** External Dacryocysto-rhinostomy for the treatment of acquired partial nasolacrimal obstruction in adults. *Br J Ophthalmol.*, 86:533–235.
13. **Demirci H, Elnor VM (2008):** Double silicone tube intubation for the management of partial lacrimal system obstruction. *Ophthalmology*, 115(2): 383-385.
14. **Mohamed Al-TaHER AA (2012):** Flapless external dacryocystorhinostomy (DCR): do flaps really matter? *AAMJ.*, 10(3):339-351.
15. **Mauffray RO, Hassan AS and Elnor VM (2004):** Double silicone intubation as treatment for persistent congenital nasolacrimal duct obstruction. *Ophthal Plast Reconstr Surg.*, 20:44–49.
16. **Conway ST (1994):** Evaluation and management of “functional” nasolacrimal blockage: results of a survey of the American Society of Ophthalmic Plastic and Reconstructive Surgery. *Ophthal Plast Reconstr Surg.*, 10:185–187.
17. **Wormald PJ, Tsirbas A (2004):** Investigation and endoscopic treatment for functional and anatomical obstruction of the nasolacrimal duct system. *Clin Otolaryngol Allied Sci.*, 29:352–356.
18. **Moore WM, Bentley CR and Olver JM (2002):** Functional and anatomic results after two types of endoscopic endonasal dacryocystorhinostomy: surgical and holmium laser. *Ophthalmology*, 109:1575–1582.
19. **Peterson NJ, Weaver RG and Yeatts RP (2008):** Effect of short-duration silicone intubation in congenital nasolacrimal duct obstruction. *Ophthalmic Plastic and Reconstructive Surgery*, 24 (3): 167–171.