

Arthroscopic Bankart Repair with Subscapularis Augmentation in The Treatment of Recurrent Anterior Shoulder Instability with Bone Loss

Ibrahim A. Hussein, Mohamed Abdel-Aziz Hassan, Samir A. Nematallah

Orthopedic Department, Faculty of Medicine, Al-Azhar University, Cairo

Corresponding author: Samir Ahmed Nematallah. Mobile: 01004649490, Email: drsamirortho@azhar.edu.eg

ABSTRACT

Background: In this study, we focused on the analysis of new published surgical technique in the management of recurrent anterior shoulder dislocation in presence of glenoid bone defect using traditional Bankart repair augmented with subscapularis tendon. **Method:** This prospective study was performed on 30 patients having recurrent anterior shoulder dislocation; these patients were managed between January 2016 and December 2018, Thirty-one shoulders in thirty-one patients had arthroscopic Bankart repair and subscapularis augmentation. One patient was lost to follow up; thirty patients with thirty shoulders were evaluated using American shoulder and elbow surgeons score, the percentage of glenoid bone defect was evaluated using PICO method. **Results:** 30 patients were followed for 22.03 Months range 16 – 24 Months. Only one patient had recurrent dislocation after significant trauma. The American Shoulder and Elbow Surgeon Score (ASES) shows significant improvement in score from Mean \pm SD 13.27 ± 3.24 to 23.47 ± 3.14 after, function Mean \pm SD from 6.23 ± 2.01 to 8.83 ± 0.75 and pain decrease from Mean \pm SD 6.17 ± 1.53 to 1.33 ± 0.80 , with no significant functional changes in ROM even ER at 90 abduction Mean \pm SD changes from 79.00 ± 9.95 to 77.33 ± 7.85 or ER at side Mean \pm SD changes from 68.67 ± 18.14 to 66.33 ± 15.31 .

Conclusion: The procedure of Bankart repair with Arthroscopic Subscapularis Augmentation (ASA) is an effective procedure in the management of recurrent anterior shoulder dislocation associated with GBD $\leq 25\%$ with good results.

Keywords: Bankart repair, Subscapularis augmentation, recurrent anterior shoulder dislocation, and glenoid bone loss.

INTRODUCTION

Recurrent anterior shoulder dislocation is a common injury in young and active patients⁽¹⁾ with an incidence rate of about 1.7%. Without surgical treatment, the recurrence rate in young patients is unacceptably high about 70.3%⁽²⁾. However, after arthroscopic Bankart repair the recurrence rate of 13.1% was still reported⁽²⁾. Different pathologies are involved in the problem of instability; glenoid bone loss, potentially engaging Hill-Sachs defect⁽³⁾, capsular insufficiency⁽⁴⁾ and subscapularis tendon elongation⁽⁵⁾.

Putti and Platt inaugurated an open shoulder soft tissue stabilization procedure, using the subscapularis tendon. This procedure is performed as follows: the release of the subscapularis tendon at 2.5 cm medial of the insertion at the lesser tuberosity, open the capsule and suture the medial border of the lateral stump to the capsule tissue, and at least suture the lateral border of the medial subscapularis tendon laterally. Osmond-Clark⁽⁴⁾ was the first who described the procedure. But osteoarthritis and the limitation of external rotation were reported as late complications⁽⁶⁾. Different modifications of the Putti-Platt procedure were described in the following years⁽⁷⁾. Bristow⁽⁸⁾ and Latarjet⁽⁹⁾ both described a non-anatomical procedure using the conjoint tendon with the attached coracoid, passed the conjoint tendon through the subscapularis tendon, and fixed the bone block at the glenoid^(9,10).

This procedure helps to solve the problem of the GBD, capsular insufficiency, and subscapularis tendon elongation. However, although high complication rates after the early Bristow procedures as well as after the arthroscopic Bristow-Latarjet procedure were reported, their popularity increased^(10, 13). The pathological problems of a stretched capsule and elongation of the

subscapularis tendon are the main problems related to the recurrence of instability⁽⁵⁾. Recently, biomechanical studies have reported that the sling effect of the subscapularis is the main effect of stabilization after the Latarjet procedure⁽¹⁴⁻¹⁶⁾. Therefore, Johnson reported an arthroscopic technique using the subscapularis tendon to address the capsulolabral deficiency⁽¹⁷⁾; this procedure has been developed using the effect of the subscapularis tendon to stabilize the shoulder, thus avoiding a high complication rate, especially the major complication of nerve palsy. However, this procedure was abandoned due to complications related to the metal implant used for fixation of tendon to the glenoid edge.

Recently, four techniques have been described in which the subscapularis tendon was used to treat anterior capsulolabral deficiency.

The first technique, described by Denard *et al.*⁽¹⁸⁾ consisted of a subscapularis flap used to augment the Bankart repair, whereas the second technique, described by Chaudhury *et al.*⁽¹⁹⁾ consisted of tenodesis of the tendon and its advancement and fixation to the medial border of the glenoid neck using multiple anchors. The third technique described by Blasiak *et al.*⁽²⁰⁾ used a split of the subscapularis tendon which was detached from the distal part and fixed at the anterior glenoid rim. The fourth technique was presented by Klungsoyr *et al.*⁽²¹⁾, the sling effect was used to stabilize the shoulder using a hamstring tendon graft and enhancing the anterior rim of the glenoid with the same graft. Maiotti *et al.*⁽²²⁾ Based on the procedure of Johnson⁽¹⁷⁾ a new arthroscopic technique consisting of an upper third subscapularis tenodesis at the anterior border of the glenoid rim combined with the traditional Bankart repair was developed. This technique was

named arthroscopic subscapularis augmentation (ASA).

PATIENTS AND METHOD

This prospective study was performed on 30 patients having recurrent anterior shoulder dislocation.

The study was approved by the Ethics Board of Al-Azhar University.

These patients were managed between Januarys 2016th to December 2018; thirty-one shoulders in thirty-one patients had arthroscopic Bankart repair and subscapularis augmentation. One patient was lost to follow up; thirty patients with thirty shoulders were evaluated at the outpatient clinics of Al-Azhar university hospitals and presented in this study; three patients had controlled epileptic attacks and were free of attacks six months before surgery; One patient had a bilateral presentation but we did only one shoulder (Table 1).

Table (1): Demographic data of the studied cases

		Total no. = 30
Age	Mean ± SD	28.13 ± 7.00
	Range	19 – 45
Gender	Female	2 (6.7%)
	Male	28(93.3%)
Dominance	Non	7 (23.3%)
	Dominant	23(76.7%)
Side	Rt.	21(70.0%)
	Lt.	9 (30.0%)
Number of preoperative dislocations	Mean ± SD	7.30 ±4.98
	Range	3 – 20
Cause of 1 st dislocation	Fits	5 (16.7%)
	Trauma	25(83.3%)
Previous intervention	Reduction	11(36.7%)
	R-UGA	18 (60.0%)
	Bankart	1 (3.3%)
Chronic Disease	No	25(83.3%)
	Yes	5 (16.7%)
GBD (%)	Mean ± SD	14.45 ± 3.58
	Range	10 – 25
Hillsach's	No	13(43.3%)
	Small	11(36.7%)
	Moderate	6 (20.0%)

Inclusion criteria

Patients with recurrent anterior shoulder instability; ≥ 18 and less than 50 years old, GBD between 10% and 25% with or without Hillsach's lesion.

Exclusion criteria

Severe globoid bone loss >25%; <18 and >50 years old; voluntary or multidirectional instability, Preexisting glenohumeral osteoarthritis, Infection, and Uncontrolled epilepsy.

Preoperative assessment; including careful history taking, examinations, laboratory, and radiological investigations.

Also the **patients were assessed preoperatively** using the American Shoulder and Elbow surgeon score (ASES).

As regard to preoperative assessment using the American Shoulder and elbow surgeon-patient self-assessment score; this score evaluates the patients as regards to pain (10 points), current overall function of the shoulder (10 points) and shoulder activity assessment (0-30 points), taking in consideration (0-10) poor, (11-20) good and (21-30) is an excellent result.

Examination including ROM is very important preoperative to compare it with post-operative results; also inspection for any changes or muscle wasting, palpation for any point of tenderness, muscle power testing and grading, preoperative radiological assessment using trauma series x-ray MRI for Bankart lesion associated Hillsach's, rotator cuff tear, SLAP (fig.1) and CT well qualified and cleaver radiologist is very important and cornerstone to assess exactly the GBD.

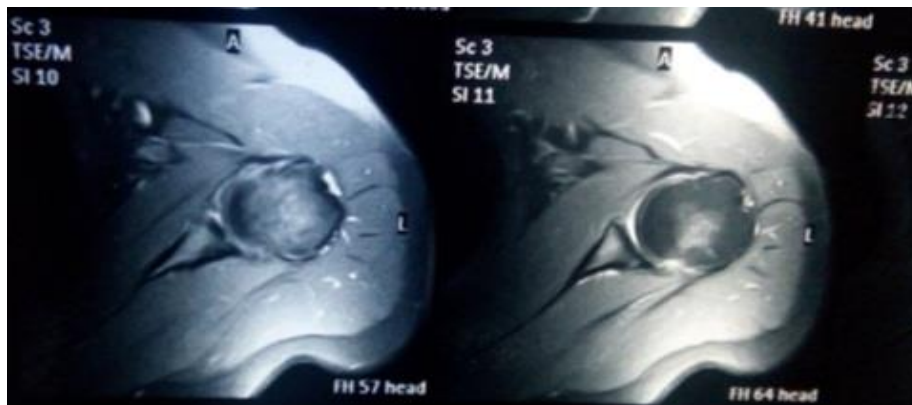


Fig (1): Preoperative MRI shows Bankart lesion and small hillsach's lesion with osseous edema

CT scanning is currently the method of choice for studying glenoid bone defects for recurrent dislocations. Strongly positive apprehension test at minimum degrees of abduction, bone defects shown on plain radiographs, and the need for surgical stabilization are the main indications for performing a CT study (figure 2) (7, 21, 23, and 24).

Isolated glenoid defects are found in 22% of patients with first-time anterior dislocation and in up to 73% of subjects with chronic instability ^(26, 27).

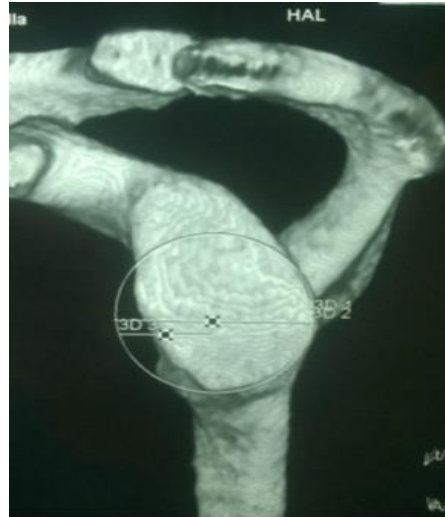

Fig (2): Preoperative 3D-CT with measuring the glenoid bone defect about 15%.

Several methods have been proposed to quantify the extent of the glenoid bone defect; the most accurate ones utilize two-dimensional computed tomography images with multiplaner reconstructions (PICO method) or more sophisticated three-dimensional reconstruction software (fig 3, 4) ⁽²⁵⁾.

Baudi *et al.* ⁽²⁸⁾ developed a simple CT method for identifying and exactly evaluating the extent of the GBD. The advantages of their technique (called PICO) derive from the fact that it combines simple 2D CT examination with subsequent MPR (multiplaner reconstruction) and thus eliminates the need for 3D processing and special software yet can still be used to obtain 3D reconstructions.

We use the PICO method in measuring the percentage of the GBD by its 2D or 3D cuts.

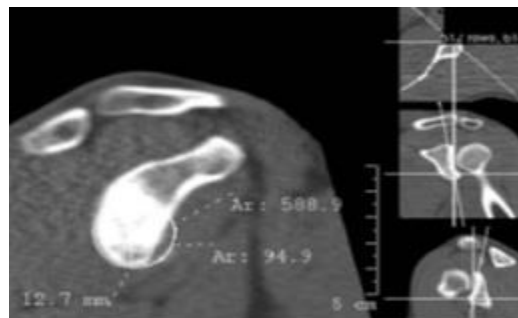


Fig (3): Quantification of glenoid bone loss using the PICO method on 2D CT image of the glenoid with MPR (en face view) ⁽²⁵⁾.

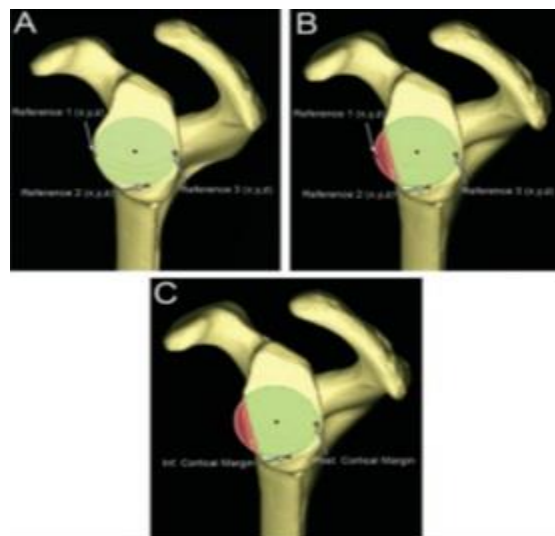


Fig (4): Quantification technique that was used to quantify glenoid bone loss using software (Pico method) ⁽²⁹⁾.

Surgical technique:

All patients receive general anesthesia with endotracheal intubation, the anesthesiologist was asked to use a hypotensive anesthesia technique to maintain the systolic blood pressure between 90-100 mm Hg, and this is a great advantage for the use of general anesthesia as the hypotensive technique allows better visualization.

All of the patients in this study were operated in the beach chair position; the patient is placed supinely on the flat operating table; the table is flexed centrally, the foot portion dropped and the trunk portion elevated to 70 to 90 degrees from the horizon (figure 5).

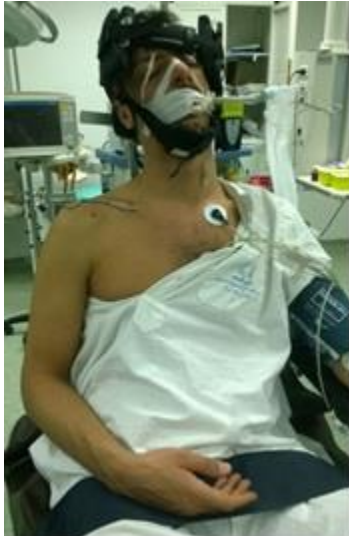

Fig (5): The patient under general anesthesia in the beach chair position.

The first step in accurate portal placement about the shoulder girdle is an identification of the subcutaneous anatomic landmarks; the scapular spine, acromial borders, AC joint, clavicle, and the coracoid process should be clearly identified. The posterior portal site can be localized as the (soft spot) in the triangular region between acromion, glenoid, and humeral head; this point is variable but approximately 2 cm medial and 2 to 3 cm distal to the posterolateral corner of the acromion (figure 6, 7).

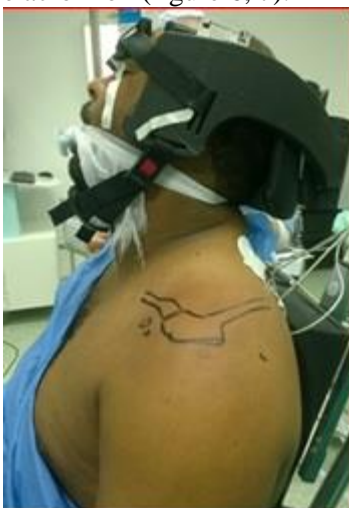

Fig (6): Marking the bony landmarks and portals

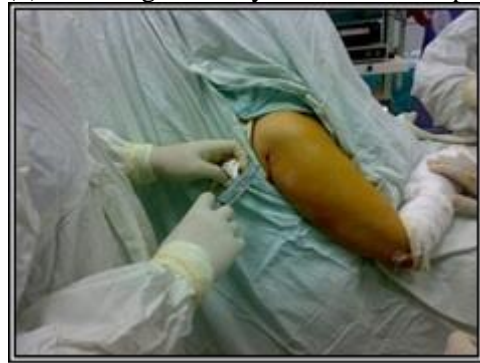

Fig (7): draping the patient and Joint distention with sterile saline using the spinal needle.

Now we start diagnostic shoulder arthroscopy; the biceps tendon is inspected along its intra-articular course, emerging laterally from the tendon sheath and bicipital groove, and inserting into the supraglenoid tubercle where it blends with the superior glenoid labrum (the so-called biceps anchor). Any evidence of deformation, erythema, fraying, tearing, or detachment should be noted; using the biceps tendon anchor to locate the superior labrum, the entire labral complex is visualized circumferentially around the glenoid.

The glenoid and the humeral head articular surfaces are examined for any evidence of instability (Figure 8).

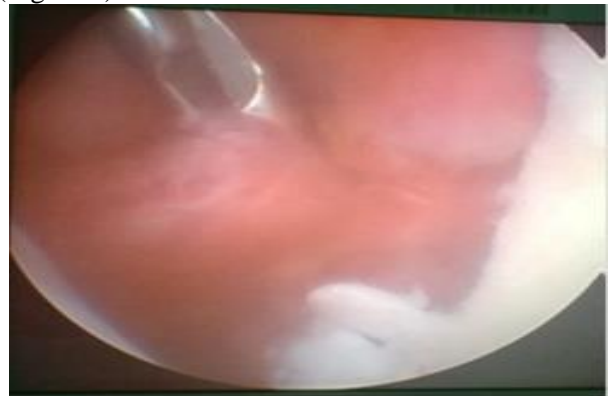


Fig (8): intraoperative arthroscopic photography showing the labral deficiency and glenoid defect.

Anterior portal is located approximately 1 cm lateral to the coracoid process. We can make the anterior portal in two ways; using needle under arthroscopic visualization then open with the scalpel under vision; or by pushing the arthroscopic cannula under direct vision through the rotator interval anteriorly then fix the cannula and withdraw the camera then introduce wire or blunt rod through the cannula to mark anterior point for opening the portal.

Standard anterior and posterior portals are used, an accessory anterior portal (if needed) is first localized with a spinal needle and then set up into the glenohumeral joint just over the superior border of the subscapularis tendon for easily use suture passing devices through the tendon.

Arthroscopic tools from both portals are used alternatively to prepare the glenoid neck, repair the labral tear, and augment the capsular deficiency with Subscapularis tendon.

Suture anchor bone holes are placed on the anterior glenoid edge at the 3 O'clock position in a right shoulder or the 9 O'clock position in a left shoulder; by localizing the proper angle directly with a guide and sleeve.

A lower capsulolabral repair is performed with standard suture anchors; the upper third of the subscapularis tendon which is necessary to augment the capsulolabral deficiency is penetrated with a suture passing device.

knotted anchors are used with the insertion of anchor first then The articular portion of the subscapularis tendon and, if present, the glenoid labrum are perforated from the anterior portal with a penetrator punch; retrieve the threads then push the knot to get tight knot with sliding type or simple half hitch knots for five times (figure 9).

The repair including the closure of the anterior pouch; centering of the humeral head in the glenoid cavity is assessed by arthroscopic examination from the anterosuperior portal.

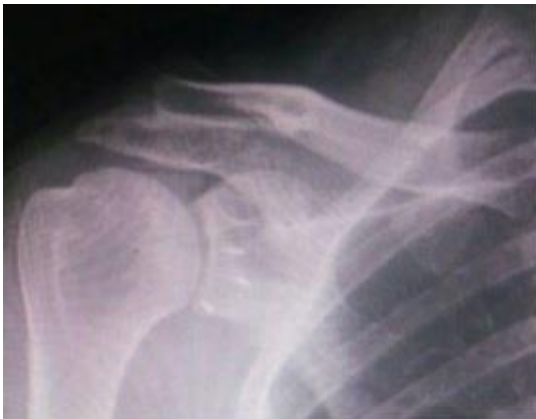

Fig (9): Postoperative plain X-ray AP view shows inserted three anchors at the glenoid.

POSTOPERATIVE REHABILITATION PROTOCOL:

After surgical repair, the shoulder was immobilized in a brace with the arm in 0° of abduction and internal rotation for 4 weeks.

The rehabilitation program consisted of 4 phases,

The first phase: was initiated in the fifth week; using both shoulder passive ROM and active ROM exercises to increase joint mobility.

In the second phase: at 6 to 8 weeks; the aim was the recovery of full ROM.

The third phase: at 8 to 9 weeks; was focused on the recovery of strength and proprioceptive abilities.

In the fourth phase: at 10 weeks; resumption of certain sport-specific activities was permitted.

Return to sports was allowed at 4 months (figure 10)⁽²²⁾.

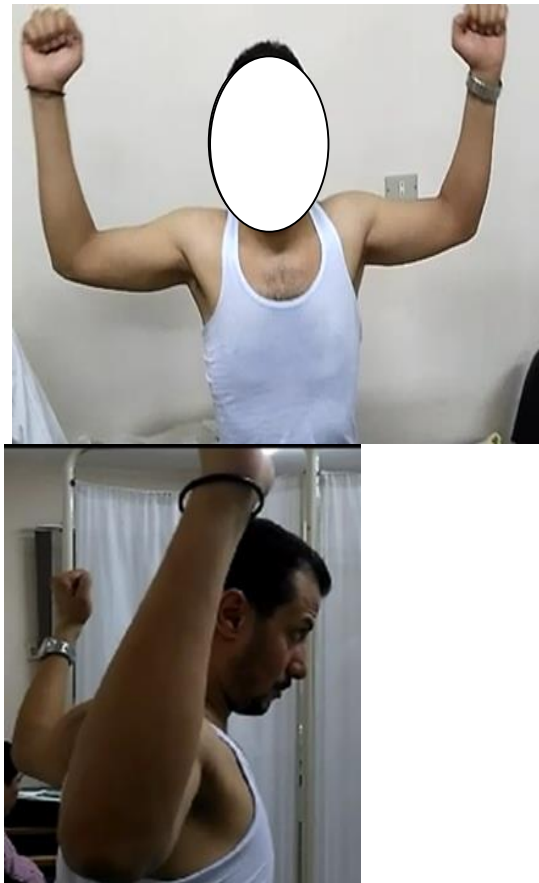

Fig (10): Postoperative photography anterior and lateral view shows minimal affection of ROM.

RESULTS

Thirty patients were available at follow up (mean follow up 22.03 ± 2.68) range 16-24 Months; the mean age was 28 years with range 19-45, all were assessed with ASES the mean score.

The overall average score in relation to main score and function and pain show significant difference as indicated by statistical data, the Main score improved from 13.27 ± 3.24 SD to 23.47 ± 3.14 SD ($P=0.815$) with high significant result, Pain score improved from 6.17 ± 1.53 SD to 1.33 ± 0.80 SD ($P=0.683$) with high significant result, Function score improved from 6.23 ± 2.01 SD to 8.83 ± 0.75 SD ($P=0.158$) with high significant result, On the other hand non-significant results with no marked difference pre-operative and post-operative in ROM. One 3.3% patient had dislocated after significant trauma.

Complications documented were; three cases (10%) had different degrees of recurrent instability, The first case: had recurrent dislocation after an epileptic fit that became controlled for a long period preoperatively; the second case: about six month's post-operative the patient suffered of subluxation, the field that the head of the humerus will get out during working with no true dislocation; third case: show true dislocation after one year of the operative procedure due to significant trauma, those cases now underestimation and discussion about revision surgery.

Fluid extravasation: Three patients had temporary extravasations to the upper arm that relieved through eight hours postoperatively.

Anchor pullout during knot tying: One anchor in one patient shows pullout during knot tying due to osteopenia and maybe the wrong insertion of the anchor, another arthroscopic portal was done for removal of the lost anchor and insertion of a new one.

DISCUSSION

Arthroscopic capsulolabral complex repair became extremely popular as a method for treatment of shoulder instability; although its failure rate has been relatively high⁽³¹⁾.

Several authors have suggested that the ideal candidate for an arthroscopic repair is a patient with a Bankart lesion and no capsular laxity or glenohumeral bone defects⁽³²⁾.

Maiotti (2013)⁽³⁰⁾ put the indications, contraindication, and tips for ASA.

Indications include; recurrent shoulder instability in patients with capsulolabral insufficiency without significant anterior GBD; Failure of primary arthroscopic Bankart repairs.

Contraindications are; significant anterior glenoid bone defects, Osteoarthritis of the glenohumeral joint; Addressed lesions of the subscapularis tendon. And he mention the tips of this procedure which are; view from multiple angles, rasping over the glenoid neck to remove scar tissue and obtain bone bleeding, Fenestrated drill guide is helpful to localize the proper angle of the anchor bone holes, Check the direction and proper depth of the anchor bone hole by using a punch, The tape should be cut with a suture cutter⁽³⁰⁾. Basically; advancement of the subscapularis tendon to the anterior glenoid edge leads to an effective tensioning of the tendon and reduces its slippage upward; so it can act as an anterior stabilizer to the humeral head and prevent recurrence⁽³⁰⁾.

Furthermore; advancement of subscapularis tendon is extremely useful to augment the anterior capsulolabral complex even in the presence of GBD⁽³⁰⁾.

In our study arthroscopic Bankart repair and subscapularis augmentation for anterior shoulder instability was conducted on thirty patients and the assessment was based on the American Shoulder and Elbow surgeons score; Preoperatively the overall average was 8-20 (mean \pm SD 13.27 \pm 3.24) point (poor and fair scores) postoperatively the overall mean score was 18-28 (mean \pm SD 23.47 \pm 3.14) (good and excellent scores). There was a highly significant difference between mean score preoperative and postoperative with a highly significant decrease in the poor score and highly significant increase in good and excellent score. The excellent results were 23 (76.7%); the good results were 7 (23.3%) with no poor

results; our results are relatively similar when compared with previous results (fig. 10).

In our study the preoperative episodes of dislocation ranged between 3 and 20 attacks of dislocation; statistical analysis reveals that there is no significant correlation between the postoperative score and the number of previous episodes.

In our study we used two portals one posterior for the scope and one anterior portal for instruments; we chose the use of a single anterior portal technique to shorten the time of the procedure and avoid suspected comorbidities; the anterior portal facilitates the preparation of the glenoid neck, drilling, passing threads through the tissue and insertion of the anchors; we need to open another portal in one patient when the anchor pulled out from the bone during insertion and entrapped through tissue; another portal help removal of this anchor and reinsertion. We use the metallic (2.7 mm) knotted suture anchors (CONMED) type in all cases with satisfactory results for all patients.

Marco Maiotti et al.⁽³³⁾ at their study assessing the effect of the procedure showed the mean scores were as follows: VAS scale decreased from a mean of 3.5 to 0.5 (P = 0.015), Rowe score increased from 57.4 to 95.3 (P = 0.035), and ASES scores increased from 66.5 to 96.5 (P = 0.021). The mean deficit of external rotation was 8° \pm 2.5° in the ER at side position and 4° \pm 1.5° in the ER at 90° abduction; and concluded that ASA was an effective procedure in restoring joint stability in patients affected by recurrent anterior shoulder instability associated with anterior GBL (<25%), capsular deficiency, and Hill-Sachs lesions, with mild restriction of external rotation⁽³³⁾.

Taking all of this into consideration and if we come to compare the final outcome of this study with the outcome of other studies it will be found to be favorable and relatively similar in results.

In this study 30 cases of recurrent anterior shoulder instabilities was performed; all had Bankart lesion and variable degrees of anterior glenoid bone loss ranging from 10% to 25% and all were operated using metallic (2.7mm) knotted suture anchors (CONMED); the age ranged between 19 and 45 years with an average age 28 years; the follow up period ranged between 16 and 24 months, we applied the American shoulder and elbow surgeon scoring scale for the patients of this study.

Excellent results (76.7%) obtained in 23 cases; good results (23.3%) obtained in 7 patients and no patients were poor results.

Arthroscopic or open shoulder surgery can be performed with the patient in the beach chair position.

Burkhart et al.⁽³⁴⁾ state in *The Cowboy's Companion* that for the surgeon to become an advanced shoulder arthroscopy he or she should use the lateral decubitus position exclusively. However; Wahl and Warren⁽³⁵⁾ state that they exclusively use

the beach chair position for anterior and posterior shoulder procedures; some surgeons advocate for the use of the beach chair position for rotator cuff repair and the lateral position for instability procedures^(34, 35).

We use beach chair position in all our cases but from our work and our observations, we recommend the use of lateral decubitus in shoulder stabilization procedures including ASA.

Limitations of study

We use two anchors only in some patients for the repair because of limited supply, how to get good CT with perfect measure of the GBD and it was challenging to find a well-trained physiotherapist to get perfect result with well-cooperated patient.

CONCLUSIONS

Recurrent anterior shoulder dislocation is an annoying problem for patients; usually, the cause of recurrence is the capsulolabral deficiency, redundancy of the capsule and glenoid bone.

Diagnosis could be done using X-ray pictures, MRI and CT with special views for good assessment and measuring the magnitude of the problem and which solution is better and the exclusion of other pathology.

The treatment of chronic shoulder instability with a poor quality of the anterior capsulolabral tissue is still controversial; the Latarjet procedure is certainly more effective in preventing recurrence than an arthroscopic capsular repair; however, several studies have reported a variety of severe complications related to the Latarjet procedure because of the use of bone augmentation and hardware implantation.

Currently; the Latarjet technique for instability with moderate bone loss from 10 to 20% may be considered as an overtreatment because this new arthroscopic technique combining Bankart repair plus ASA demonstrated similar clinical results at the short-term follow-up.

We recommend arthroscopic subscapularis as an important line of treatment for cases with a recurrent anterior shoulder dislocation associated with GBD 10%-25% especially with good patient selection and good documentation and management of any associated pathology.

This study shows that ASA is an effective mean of treatment of cases of recurrent anterior shoulder dislocation with good improvement of shoulder scores, pain, and function with no marked affection or limitation of movement when the appropriate facilities are available.

RERERENCES

1. **Owens B, Duffey M, Nelson B (2007):** The incidence and characteristics of shoulder instability at the United States

- Military Academy. *The American Journal of Sports Medicine*, 35: 1168–1173.
2. **Gigis I, Heikenfeld R, Kapinas A (2014):** Arthroscopic versus conservative treatment of first anterior dislocation of the shoulder in adolescents. *J. Pediatric Orthopedic*, 34: 421–425.
3. **Purchase R, Wolf E, Hobgood E (2018):** Hill-Sachs “remplissage”: an arthroscopic solution for the engaging hill-sachs lesion. *Arthroscopy*, https://www.researchgate.net/publication/253327871_Hill-Sachs_Remplissage.
4. **Osmond-Clarke H (1948):** Habitual dislocation of the shoulder; the Putti-Platt operation. *J. Bone Joint Surg.*, 19–25.
5. **Symeonides PP (1972):** The significance of the subscapularis muscle in the pathogenesis of recurrent anterior dislocation of the shoulder. *J. Bone Joint Surgery*, 54: 476–483.
6. **Ahmad CS, Wang VM, Sugalski MT, Levine WN, Bigliani LU (2005):** Biomechanics of shoulder capsulorrhaphy procedures. *Journal of Shoulder and Elbow Surgery*, 14: 12–18.
7. **Symeonides PP (1989):** Reconsideration of the Putti-Platt procedure and its mode of action in recurrent traumatic anterior dislocation of the shoulder. *Clin. Orthop. Relat. Res.*, 8:15.
8. **Helfet AJ (1958):** Coracoid transplantation for recurring dislocation of the shoulder. *J. Bone Joint Surg.*, 198;202.
9. **Latarjet M (1954):** Treatment of recurrent dislocation of the shoulder. *Lyon chirurgical*, 49: 994–997.
10. **Artz T and Huffer JM (1972):** A major complication of the modified Bristow procedure for recurrent dislocation of the shoulder. A case report. *J. Bone Joint Surg.*, 1293–1296.
11. **Fee HJ, McAvoy JM, Dainko EA (1978):** Pseudoaneurysm of the axillary artery following a modified Bristow operation: report of a case and review. *J. Cardiovasc. Surg.*, 19: 65–68.
12. **Iftikhar TB, Kaminski RS, Silva I (1984):** Neurovascular complications of the modified Bristow procedure. A case report. *J. Bone Joint Surg.*, 91:952.
13. **Griesser MJ, Harris JD, McCoy BW, Hussain WM, Jones MH, Bishop JY, Miniaci A (2013):** Complications and re-operations after Bristow-Latarjet shoulder stabilization: a systematic review. *Journal of shoulder and elbow surgery*, 22: 286–292.
14. **Giles JW, Boons HW, Elkinson I, Faber KJ, Ferreira LM, Johnson JA, Athwal GS (2013):** Does the dynamic sling effect of the Latarjet procedure improve shoulder stability? A biomechanical evaluation. *Journal of shoulder and elbow surgery*, 22: 821–827.
15. **Wellmann M, Petersen W, Zantop T, Herbolt M, Kobbe P, Raschke MJ, Hurschler C (2009):** Open shoulder repair of osseous glenoid defects: biomechanical effectiveness of the Latarjet procedure versus a contoured structural bone graft. *The American Journal of Sports Medicine*, 37: 87–94.
16. **Wellmann M, de Ferrari H, Smith T, Petersen W, Siebert CH, Agneskirchner JD, Hurschler C (2012):** Biomechanical investigation of the stabilization principle of the Latarjet procedure. *Arch. Orthop. Trauma Surg.*, 132: 377–386.

17. **Johnson LL (1986):** Principle and practice. In *Arthroscopic surgery*: Mosby (Ed.), St. Louis., pp. 1420–1424
18. **Denard PJ, Narbona P, Ladermann A, Burkhart SS (2011):** Bankart augmentation for capsulolabral deficiency using a split subscapularis tendon flap. *Arthroscopy*, 27: 1135–1141.
19. **Chaudhury S, Delos D, Dines JS, Altchek DW, Dodson CC, Newman AM, O'Brien SJ (2014):** Arthroscopic subscapularis bankart technique as a salvage procedure for failed anterior shoulder stabilization. *HSS journal: the musculoskeletal journal of Hospital for Special Surgery*, 10: 73–78.
20. **Blasiak A, Brzoska R, Mojiesz M, Solecki W, Grzegorzewski A (2016):** Outcome Evaluation of Arthroscopic Treatment of the Anterior Shoulder Instability with Use of Extracapsular Stabilization by Using the BLS and “Remplissage” Techniques. <http://www.marcomaiotti.it/wp-content/uploads/2017/09/asa-biomechanics.compressed.pdf>.
21. **Klungsoyr PJ, Guldal F, Vagstad T, Klungsoyr JA (2015):** A new subscapular sling operation to stabilize the shoulder. A cadaver study. *J Exp Orthop.*, 2: 12.
22. **Maiotti M and Massoni C (2013).** Arthroscopic augmentation with subscapularis tendon in anterior shoulder instability with capsulolabral deficiency. *Arthroscopy techniques*, 2: e303–e310.
23. **Maiotti M, Russo R, Zanini A, Schroter S, Massoni C, Bianchedi D (2015):** Arthroscopic Bankart repair and subscapularis augmentation: an alternative technique treating anterior shoulder instability with bone loss. *J Shoulder Elbow Surg.*, 25(6):898-906.
24. **Brain JC, Leonide IK (1998):** The shoulder. <https://www.vitacost.com/.../build-football-ready-shoulders-in-4-weeks-with-this-work>
25. **Paolo B, Gabriele C, Manuela R, Giovanni M, Fabio C (2013):** Struttura complessa di Ortopedia e Traumatologia, Dipartimento Patologia Apparato Locomotore, Azienda ospedaliero assessment of bone defects in anterior shoulder instability. Azienda ospedaliero-universitaria, Policlinico di Modena. *Joints*, 1(1):40-4.
26. **Taylor DC, Arciero RA (1997):** Pathologic changes associated with shoulder dislocations. Arthroscopic and physical examination findings in first-time, traumatic anterior dislocations. *Am J Sports Med.*, 25: 306-311.
27. **Bois AJ, Fening SD, Polster J et al. (2012):** Quantifying glenoid bone loss in anterior shoulder instability: reliability and accuracy of 2-dimensional and 3-dimensional computed tomography measurement techniques. *Am J Sports Med.*, 40: 2569- 2577.
28. **Baudi P (2008):** How to manage bone defects in shoulder instability. <https://www.ncbi.nlm.nih.gov/pubmed/30148653>
29. **Aaron JB, Stephen DF, Josh P, Morgan HJ , Anthony M (2012):** Investigation performed at Cleveland Clinic, Cleveland, Ohio. Quantifying Glenoid Bone Loss in Anterior Shoulder Instability Reliability and Accuracy of 2-Dimensional and 3-Dimensional Computed Tomography Measurement Techniques: *The American Journal of Sports Medicine*, 40:11.
30. **Maiotti M and Massoni C (2013):** Arthroscopic augmentation with subscapularis tendon in anterior shoulder instability with capsulolabral deficiency. *Arthroscopy techniques*, 2:e303-10.
31. **Burkhart SS and De Beer JF (2000):** Traumatic glenohumeral bone defect and their relationship to failure of arthroscopic Bankart repairs: significance of the inverted-pear glenoid and the humeral engaging Hill-Sachs lesion. *Arthroscopy*, 16: 677-694.
32. **Cole JB, L'Insalata J, Irrgang J, Warner JP (2000):** Comparison of arthroscopic and open anterior shoulder stabilization. *J Bone Joint Surgery*, 82:1108-1114.
33. **Maiotti M, Massoni C, Russo R, Schroter S, Zanini A, Bianchedi D (2017):** Arthroscopic subscapularis augmentation of Bankart repair in chronic anterior shoulder instability with bone loss less than 25% and capsular deficiency: clinical multicenter study. *Arthroscopy: The Journal of Arthroscopic & Related Surgery*, 33(5):902-9.
34. **Burkhart SS, Lo IK, Brady PC, Denard PJ (2012):** *The Cowboy's Companion: A Trail Guide for the Arthroscopic Shoulder Surgeon*. Philadelphia, PA, Lippincott Williams & Wilkins. <https://www.amazon.com/Cowboys-Companion-Arthroscopic-Shoulder-Surgeon/dp/1609137973>.
35. **Wahl CJ and Warren RF (2009):** *The Shoulder, General principles*, in Rockwood CA, Matsen FA III, eds: Philadelphia, PA, Saunders, <https://www.elsevier.com/books/rockwood-and-matsen-s-the-shoulder-2-volume-set/matsen/978-1-4160-3427-8>.