

Role of Diffusion-Weighted Magnetic Resonance Imaging in Evaluation of Gynecologic Tumors

Mohamed E. Shabana^a, Medhat M. Refat^a, Magdy E. Setten^b, Sameh A. Aly^a

Abstract

^a Department of Radiodiagnosis, Benha faculty of medicine, Benha University, Egypt.

^b Department of Radiodiagnosis, faculty of medicine, Mansoura University, Egypt.

Correspondence to:
Mohamed E. Shabana,
Department of Radiodiagnosis,
Benha faculty of medicine, Benha
University, Egypt.

Email:
dmshabana2010@yahoo.com

Received: 6 August 2022

Accepted: 18 December 2022

Background: Ovarian tumors are the second most common gynecological tumor and fifth commonest tumor in women and has the highest mortality rate among gynecologic malignancies. It is estimated to comprise 6% of all cancer-related deaths. It is desirable to preoperatively differentiate benign from malignant tumor to decide whether surgery is required, and which type of surgery is appropriate avoiding unnecessary surgery. Magnetic resonance imaging (MRI) has been established as an excellent modality for evaluation of gynecologic disease. However, morphologic MRI imaging has some limitations for lesion detection and characterization. The innovation of newer functional imaging sequences such as diffusion-weighted imaging has addressed many of these issues and enhanced diagnostic capabilities of MRI. **Aim:** To investigate the role of DWI in distinguishing between benign and malignant lesions in light of the increasing recognition of DWI. **Patients & Methods:** The current study is a prospective study that was conducted at diagnostic radiology department of Benha and Mansoura University Hospitals in the period from October 2018 till January 2022. The study included 80 female patients with any age complaining of gynecologic problem like mass lesion, vaginal bleeding or pelvic pain including any type of lesion inflammatory or neoplastic and excluding congenital malformation lesions. Ethical consideration, an informed consent was obtained from patients before enrollment in the study and an approval from research Ethics committee in Benha faculty of Medicine was obtained in 2015 with no code or number -code starts from 2019-. Axial T1-WI, Axial T2-WI, Sagittal T2-WI, and Coronal T2-WI, Gradient-echo sequences (GRE), Diffusion weighted MR images (DWI), ADC and Dynamic Contrast-Enhanced MRI- were all used in the MRI examination. **Results:** We found that the specificity and the accuracy of the DWI results were both 88.5 and 91.3 percent, respectively. ADC revealed a 94.7 percent sensitivity, 91.8 percent specificity, and 92.5 percent accuracy in the identification of malignant lesions with a cutoff value of 1.0075 (10-3mm). **Conclusion:** The addition of DWI to the conventional MRI increased the accuracy of the examination and lesions characterization provided that combined interpretation of both DWI and conventional MRI data. DWI can confirm or exclude potential malignancy in suspicious pelvic masses.

Keywords: Diffusion Weighted Magnetic Resonance Imaging, Diffusion weight imaging, ADC value, Gynecologic Lesions.

Introduction

In terms of gynecological malignancies, ovarian tumors are the second most prevalent and the fifth most common, respectively. They also have the greatest fatality rate (1).

Preoperative differentiation of benign from malignant tumor is important in order to determine if surgery is needed and which sort of surgery is suitable to prevent needless surgery (2).

First-degree relatives with ovarian or breast cancer have a higher chance of developing the illness themselves, which increases the risk even more (3).

In the field of gynecological imaging, magnetic resonance imaging (MRI) has shown to be a very effective diagnostic tool. However, there are certain limits to morphologic MRI imaging when it comes to the identification and characterization of lesions. Many of these concerns have been resolved by the development of newer functional imaging sequences such as diffusion-weighted imaging (DWI) (4).

It indicates that DWI is an effective approach for discriminating benign ovarian epithelial tumors with solid components from malignant ovarian tumors, with high sensitivity and specificity- in the assessment of pelvic area malignancies- tumor identification and characterization. Additionally, DWI prevents additional renal damage since it does not need the use of contrast media (5).

Capillary perfusion and water diffusion are combined in the calculation of the apparent diffusion coefficient (ADC). Each pixel's ADC value is computed and shown as a parametric map. In line with other malignant tumors, the ADC value may help determine the efficacy of treatment

and distinguish between cancerous and healthy tissue (6).

Diffusion-Weighted Magnetic Resonance Imaging (DW-MRI) was used in this research to evaluate its ability to distinguish between benign and malignant gynecological cancers.

Patients and Methods:

The current study is a prospective study that was conducted at diagnostic radiology department of Benha and Mansoura University Hospitals, in the period from October 2018 till January 2022. The study included 80 female patients.

Inclusion criteria including patient with any age complaining of gynecologic problem like mass lesion, vaginal bleeding or pelvic pain including any type of lesion inflammatory or neoplastic. Exclusion criteria are the patient with congenital malformation lesions.

Ethical consideration and informed consent- was obtained from patients before enrollment in the study. An approval from research Ethics committee in Benha faculty of medicine was obtained in 2015 with no code or number -code starts from 2019-.

MRI was performed for all cases using a 1.5-T magnet (siemens medical systems, Germany). Cases were imaged using pelvic phased-array coil with eight channels, in the study October 2018 for January 2022.

The patient is supine and using a pelvic phased-array coil. Patients fasted for 3 hours and received 1 mg of an antispasmodic drug (Glucagen) intravenously immediately before MR imaging to reduce bowel peristalsis. The following imaging sequences were performed:

- Non-Contrast MRI:

- Axial T1-WI.
- Axial T2-WI, Sagittal T2-WI and Coronal T2-WI.
- Gradient-echo sequences (GRE)
- Diffusion weighted MR images (DWI).
- Contrast-Enhanced MRI:

Post contrast T1 fat sat THRIVE (High Resolution Isotropic Volume Examination) images were obtained immediately after manually injected gadolinium at a dose of 0.1 mmol/kg of body weight (maximum, 20 mL). Dynamic postcontrast sequence was accessible for the assessment of all cases, this was followed by injection of 20 mL of normal saline flushing the tube. Finally, axial, sagittal and coronal T1-weighted gradient-echo were acquired.

MR image interpretation was performed by two qualified radiologists who were blinded about each other imaging findings and they were not aware about the pathology, tumor markers or pelvic US data at the time of initial evaluation

DW images were taken in the axial oblique orientation and were inspected for persistent high SI in DWI at $b = 1000$ s/mm² images compared with that of serous fluid (urine in UB or cerebrospinal fluid).

Matched ADC maps were applicable using a Phillips Advantage windows workstation with functional tool software. We measured the ADC values manually applying ROI on both solid and cystic portions of the masses.

For an accurate DWI analysis- to avoid pitfalls in image interpretation- DWI and the derived ADC maps were evaluated in conjunction with morphologic images.

The possible pathology of the ovarian tumors was suggested by MR imaging and DWI, whether benign or malignant

Statistical analysis

We used software (SPSS for Windows, version 10.0.1, 1999; SPSS, Chicago, Ill). Comparison of numerical variables between the study groups was done using Student t test for independent samples. For comparing categorical data, Chi square (χ^2) test was performed. Receiver operator characteristic (ROC) analysis was used to determine the optimum cut off value for the studied diagnostic markers. P values less than 0.05 was considered statistically significant.

Results

This study included 80 female patients with mean age 40.5 years. The majority of patients were between 31 to 50 years old. The mean of tumor size was 49.89. The location of tumor in recruited patients were mainly in Ovaries (48.8%), uterus (38.8%), Cervix (7.5%), pelvic (1.2%), Abdominal wall (2.5%) and vagina (1.25%).

The tumors were solid in the majority of included patients (55%), and cystic in the rest of the cases (45%). The clinical presentations of included patients were chiefly pelvic pain (50%), vaginal bleeding (36.25%) and pelvic mass (13.75%). T2 were high in 51.25% of patients while T1 were low in 77.25% of patients (Table 1).

Contrast-enhanced MRI resulted mainly no enhancement in (53.75%) and enhanced in (46.25%). T1 Fat sat signal was high in (53.75%), low in (43.75%) and isotonic in 2.5% of the cases.

Diffusion Weighted Magnetic Resonance Imaging signal were low in 38.75%, high in 58.75% of the patients. Apparent diffusion coefficient (ADC) was high in 35% and low in 65% of the patients (Table 2).

DWI were not restricted in 70 % and restricted in 30% of included patients (Table 3).

Regarding validity of Diffusion restriction in detecting malignant lesions, Sensitivity was 100.0% while Specificity was 88.5% and Accuracy was 91.3% (Table 4).

With a cutoff point 1.0075 (10-3mm), ADC showed a Sensitivity of 94.7%, Specificity of 91.8% and Accuracy of 92.5% in diagnosis of malignant lesions. It means that ADC values equal 1.0075 (10-3mm) or higher confirm incidence of malignancy (Figure (1))

Table (1): T1 & T2 signal of the studied lesions

	N=80	%
<u>T2 signal</u>		
Iso	4	5.0
Low	35	43.8
High	41	51.2
<u>T1 signal</u>		
Iso	9	11.2
Low	62	77.5
High	9	11.2
<u>T1 post contrast</u>		
Not Enhanced	20	25.0
Enhanced	60	75.0
<u>pattern of enhancement</u>		
No Enhancement	20	25.0
Peripheral enhancement	4	5.0
Minimal enhancement	2	2.5
Homogenous	17	21.2
Heterogeneous	27	33.8
Enhanced	10	12.5

Table (2): Diffusion Weighted Magnetic Resonance Imaging signal (**DWI**) among studied cases

	Frequency	Percent
<u>DWI</u>		
low	31	38.75
high	47	58.75
isotonic	2	2.5
<u>ADC</u>		
low	52	65
high	28	35

Table (3): diffusion and ADC value distribution among studied cases

	N=80	%
<u>DWI</u>		
low	30	37.5
iso	2	2.5
high	48	60.0
<u>ADC</u>		
Low	53	66.2
high	27	33.8
<u>Diffusion restriction</u>		
not restricted	54	67.5
restricted	26	32.5

<u>Pattern Restriction</u>	n=26	
restricted nodules	1	3.8
restricted	18	69.2
peripherally restricted	2	7.7
partially restricted	3	11.5
mild restriction	2	7.7
<u>ADC value (*10⁻³ mm)</u>		
mean±SD	1.24±0.276	

Table (4): Validity of Diffusion restriction in diagnosing studied lesion

Diffusion Restriction	Final diagnosis		Sensitivity %	Specificity %	PPV %	NPV %	Accuracy %
Benign N (%)	Malignant N (%)						
Not Restricted	54(88.5)	0					
Restricted	7(11.5)	19(100)	100.0	88.5	73.1	100.0	91.3

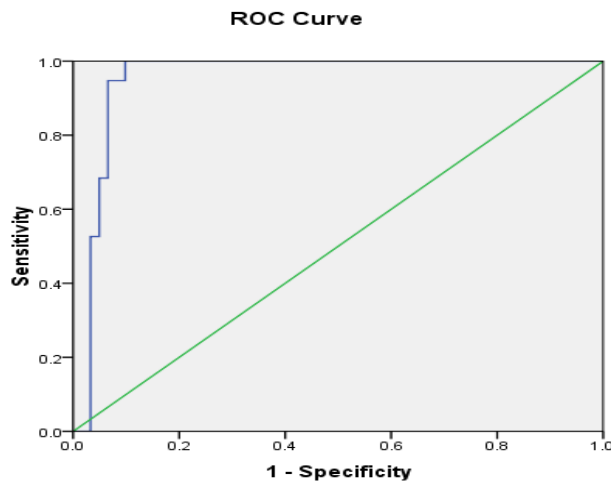


Fig. (1): ROC curve for ADC in differentiating malignant from benign lesions

Discussion

DWI, a functional MRI sequence based on the tiny motion of Radom water molecules, may enhance tissue contrast (Brownian motion). The myometrium and ovaries restrict the usefulness of the ADC, which is produced from two separate P values and aids in the detection of malignant and

noncancerous tissues in the uterine cervix and endometrium (7).

Diffusion-weighted magnetic resonance imaging (DW-MRI) was used to investigate the use of this imaging technique in the diagnosis of gynecological cancers, with an

eye on identifying benign from malignant tumors.

Eighty female patients, with an average age of 40.5 years, took part in this research. The majority of patients were in the age range of 31 to 50 when they arrived at the faculty.

Tumors had an average diameter of 49.89 millimeters. Tumors were most often seen in the ovaries (48.5%), uterus (38.5%), cervical (6%) and pelvic (1.25%) regions in the individuals who were included in clinical trials (1.25 percent).

The majority of patients (55 %) had solid tumors, whereas the remainder had cystic tumors (45%).

Patients with pelvic discomfort (50%), vaginal bleeding (36.25%), and a mass in the pelvis- were the common types of symptoms to be seen (13.75%).

We found that 31.6% (n = 6/19) of the benign ovarian masses included in our analysis had the same DWI signal as all of the malignant ovarian masses (b = 1000).

While only three benign tumors (3 thecomas) had high DWI intensity. A similar research by Takeuchi et al., (8) reported that the solid section of all malignant tumors had high intensity. This may be explained by the high cellularity inside quickly growing malignant tumor tissues.

T2 was found to be elevated in 51.25% of patients, whereas T1 was found to be low in 77.25% of the patients. In contrast-enhanced MRI, the majority of patients (53.75%) had no enhancement, while 46.25 percent had elevated T1 Fat Sat signal. DWI signal was low in 38.75% of the patients and high in 58.75% of the patients. In 35 % of cases, the apparent diffusion coefficient (ADC) had a

high value, whereas in the other 65 %, it was low. Sixty-seven percent of patients were not limited from DWI, whereas 32.5% were. Our investigation indicated that the mean ADC value of pelvic abscess was much lower than that of cystic pelvic tumors. As previously reported by Levy et al., (9) and Nougaret et al., (10) research, discovered that endometrioma (1 case) showed limited diffusion with low mean ADC value. This may be attributed to the under-stress blood products. Restricted diffusion has also been reported by previous investigations, such as Nakayama et al., (11), Sala et al., (12), Levy et al., (9) and Mansour et al., (13). Because of the high keratin content in cystic regions formed from ectodermal portions of developing cell types, this is an understandable observation to make.

ADC exhibited a 94.7% sensitivity, a 91.8 % specificity, and a 92.5 % accuracy in the detection of malignant lesions with a cutoff value of 1.0075 (10-3mm). Malignancy is confirmed if ADC values are more than 1.0075 (10-3mm).

When mature cystic teratomas and endometrial cysts are included, ADC values of the cystic component may discriminate between benign and malignant ovarian cystic tumors, but not when they are omitted.

Although the ADC values of fluid in pelvic cystic tumors were found to be significantly higher than those in pelvic abscesses, our study shows a higher cutoff value because other pathological types like mature cystic teratoma, endometrioma, ovarian torsion, and ectopic pregnancy were included in the study (14). However, our study shows that the cutoff value is higher because other

pathological types like mature cystic teratoma, endometrioma, and ovarian torsion were included.

Among benign and malignant masses, there was a substantial variation in the ADC values of the solid component in Tantawy et al., (15) investigation, which may be attributable to a lack of solid component in certain benign lesions or to histopathological inhomogeneity of the included benign lesions.

By using Diffusion restriction to identify malignant lesions, the current research found that sensitivity was 100%; specificity 88.5; and accuracy 91.3%.

MRI's sensitivity was comparable to DWI's (92.3%), but DWI's specificity was greater than traditional MRI sequences (64.7%), therefore the addition of DWI to MRI is likely to improve examination specificity.

It is now possible to do high-quality diffusion-weighted MR imaging of the whole pelvis without significantly extending the overall imaging duration for a gynecological checkup. Noninvasive Diffusion-weighted MR imaging yields valuable new insights. In the first stages of recognized malignancies, this unique modality helps differentiate between benign and malignant tumors, evaluate therapy response, and determine the existence of disease recurrence (16).

Diffusion-weighted MR imaging may be tricky, so it is critical to understand the possible hazards and compare results with those from anatomic sequences to be sure they are accurate. This new knowledge will help radiologists to better assist doctors caring for women with known or suspected

gynecologic cancers by increasing their comfort level with ADC calculation and manipulation tools (17).

Conclusion

It was shown that the use of DWI in conjunction with conventional MRI data improved both the assessment and the characterization of lesions. Detection of cancer in suspected pelvic tumors may be confirmed or ruled out by DWI.

References:

- 1- **Hasan, Jemal A, Siegel R and Ward E. (2010):** **Cancer statistics, Cancer Clin J;** 60 (5):277–300.3-
- 2- **Nasr E, Hamed I, Abbas I and Khalifaa NM. (2014):** Dynamic contrast enhanced MRI in correlation with diffusion weighted (DWI) MR for characterization of ovarian masses. The Egyptian Journal of Radiology and Nuclear Medicine; 45 (3): 975–985.
- 3- **Lutz AM, Willmann JK, Drescher CW, Ray P, Cochran FV, Urban N et al., (2011):** Early Diagnosis of Ovarian Carcinoma: Is a Solution in Sight? Radiology; 259 (2):329-345.
- 4- **Dhanda S, Thakur M, Kerkar R and Jagmohan P (2014):** Diffusion-weighted Imaging of Gynecologic Tumors: Diagnostic Pearls and Potential Pitfalls. RadioGraphics; 34:1393–1416.
- 5- **Zhang P, Cui Y, Li W, Ren G, Chu C and Wu X. (2012):** Diagnostic accuracy of diffusion-weighted imaging with conventional MR imaging for differentiating complex solid and cystic ovarian tumors at 1.5T. World Journal of Surgical Oncology;10(2):237-245.
- 6- **Bozgeyik Z, Onur MR and Poyraz AK. (2013):** The role of diffusion weighted magnetic resonance imaging in oncologic settings. Quant Imaging Med Surg; 3 (5):269-278.
- 7- **Kim HJ, Lee SY, Shin YR, Park CS and Kim K (2016):** The value of diffusion-weighted imaging in the differential diagnosis of ovarian lesions: A meta-analysis. Plo S one Feb

23;11(2):e0149465. doi:10.1371/journal.pone.0149465. visited 9/6/2021

- 8- Takeuchi M, Matsuzaki K, and Nishitani H (2010):** Diffusion-weighted magnetic resonance imaging of ovarian tumors: differentiation of benign and malignant solid components of ovarian masses. *Journal of computer assisted tomography*; 34(2), 173-176.
- 9- Levy A, Medjhouli A, Caramella C, Zareski E, Berges O, Chargari C et al., (2011):** Interest of diffusion-weighted echo-planar MR imaging and apparent diffusion coefficient mapping in gynecological malignancies: a review. *J Magn Reson Imaging*;33(5):1020–7. doi:10.1002/jmri.22546.
- 10-Nougaret S, Nikolovski I, Paroder V, Vargas HA, Sala E, Carrere S and Lakhman Y (2019): MRI of Tumors and Tumor Mimics in the Female Pelvis: Anatomic Pelvic Space-based Approach. *Radiographics*, 39(4), 1205-1229.**
- 11-Nakayama T, Yoshimitsu K, Irie H, Aibe H, Tajima T, Nishie A, et al., (2005):** Diffusionweighted echo-planar MR imaging and ADC mapping in the differential diagnosis of ovarian cystic masses: usefulness of detecting keratinoid substances in mature cystic teratomas. *J Magn Reson Imag*;22(2):271–8.
- 12-Sala E, Rockall A, Rangarajan D, Kubik-Huch RA. (2010):** The role of dynamic contrast-enhanced and diffusion weighted magnetic resonance imaging in the female pelvis. *Eur J Radiol* ;76(3):367–85.
- 13-Mansour S, Wessam R & Raafat M (2015):** Diffusion-weighted magnetic resonance imaging in the assessment of ovarian masses with suspicious features: strengths and challenges. *Egypt J Radiol Nucl Med* ;46(4):1279–89.
- 14-Chou CP, Chiou SH, Levenson RB, Huang JS, Yang TL, Yu C-C, et al., (2012):** Differentiation between pelvic abscesses and pelvic tumors with diffusion-weighted MR imaging: a preliminary study. *Clin Imag*;36(5):532–8.
- 15-Tantawy MSI, Elrakhawy MM, El-Morsy A, & Saleh G A (2018):** DWI in characterization of complex ovarian masses, would it help? *The Egyptian Journal of Radiology and Nuclear Medicine*, 49(3), 878-883.
- 16-Whittaker C S, Coady A, Culver L, Rustin G, Padwick M, & Padhani AR (2009):** Diffusion-weighted MR imaging of female pelvic tumors: a pictorial review. *Radiographics*, 29(3), 759-774.
- 17-Samy E, Khater H, & Refaat M M (2016):** Role of MRI diffusion in the diagnosis of uterine cervical carcinoma. *Benha Medical Journal*, 33(1), 10.

To cite this article: Mohamed E. Shabana, Medhat M. Refat, Magdy E. Setten, Sameh A. Aly. Role of Diffusion-Weighted Magnetic Resonance Imaging in Evaluation of Gynecologic Tumors. *BMFJ* 2023;40(Radiology):182-190.