

## ORIGINAL ARTICLE

# Management of Open Tibial Diaphyseal Fractures Utilizing Ilizarov External Fixator

Mahmmoud Sallam Mohammed\*, Ebeed Yasin, Ahmed said Abd Ellatief, Hesham Hamed Refae

Orthopedic department, Faculty of Medicine - Aswan University

### ABSTRACT

Keywords: Maintained union. Union rates .open fractures · Tibia · Ilizarov method.

\*Corresponding Author:  
Mahmmoud Sallam  
Mohammed,  
mail :  
Mahmoud.sallam@med.asw  
u.edu.eg.  
Mobile: 01114096403, E-

**Background:** open fractures of the tibia are serious injuries that could be associated with catastrophic complications. **Purpose:** assessment the results of using IEF as a definitive method of fixation of these types of fractures. **Material and method:** cohort study of 30 patients with open diaphyseal tibial fracture treated at the orthopedic department, Aswan University hospital in the period between (March 2019 to May 2021). Patients aged Between 14 and 70 years of age. Closed fractures, Bedridden or neglected patients complaining of Osteoporotic bone were excluded. **Results:** The patients' median age was 32.7 years (18-50Y). The bone repair took an average of 4.3 months. Of an average 12-month follow-up. 122 minutes were spent operating on average (SD = 16.9). 90% of the patients in our study experienced bone union. patients' average period with the Ilizarov external fixator was  $4.43 \pm 1.47$  months, with a range of 3 to 8 months. **Conclusion:** using an Ilizarov external fixator as an adjunctive method for the fixation of open diaphyseal fractures has many advantages, including being a minimally invasive maneuver, bloodless operation, minimal post-operative pain, stable fixation linked to fewer risks of neurological and vascular injury than other maneuvers with a skilled hand, and early rehabilitation.

### INTRODUCTION

Fractures of the tibial shaft have a recorded incidence of 17–21 per 100,000 population, representing 2% of all fractures and 36.7% of all long-bone fractures in adults. (1).

As management of open tibial fracture remains a challenge for the orthopedic surgeon. (2) who has focused on thorough debridement and immediate bony stabilization with tissue cover to enable early mobilization and restoration of optimum function. (3)

The fractured tibia was classified according to AO classification and categorized open injuries into the familiar three categories, based on Gustilo Anderson classification. (4-5).

The best clinical outcome is the golden rule to be achieved together with an acceptable degree of reduction of a fractured bone.

IEF is established as a minimally invasive method that permits effective wound management, early weight bearing, and bone lengthening. (6)

Systemic reviews analyzed the short-term results of open diaphyseal tibia fracture with an Ilizarov external fixator treated with various surgical techniques. (7:17) table 3.

Most studies in these reviews reported the best with IEF in the management of this fracture

Our study aims to assess the results of using IEF as a definite method of fixation of these types of fractures.

## **MATERIALS AND METHODS**

This study is a prospective study of 30 patients with open diaphyseal tibial fracture conducted at the orthopedic department, Aswan University in the period between (March 2019 to May 2021).

The inclusion criteria: Open diaphyseal tibial fractures Of patients aged Between 14 and 70 years of age with exception of closed fractures, Bedridden or neglected patients complaining of Osteoporotic bone, and the lost follow-up cases during the COVID-19 pandemic period.

We used AO/TA classification to classify each tibial fracture and graded it as an open fracture using Gustilo classification.

We applied the ALTAS protocol to all patients.

Detailed personal and medical history was documented for all patients.

### **Surgical techniques**

Spinal anesthesia is used in all cases. The patient was positioned on a radiolucent operating table in the supine position. the limb from thigh to foot sterilized and draped. The fluoroscopy was used during the steps of reduction and pin insertion. The surgery was performed without a tourniquet.

A frame was assembled around the limb as a loose telescoping adjustable frame. (Figure1)

Four rings that were attached to the tibia with K-wires made up the Ilizarov apparatus. (Figure2) The Ilizarov equipment included four rings that were attached to the tibia and fibula with K-wires and two olive wires in the case of concomitant tibial plateau fracture. At the orientation lines for the knee and ankle, two different rings were used (figure 3&4). To obtain consistent and acceptable close anatomical reduction, the placements of the other were changed.

## Post-operative follow-up

Gait training with partial weight-bearing on the operated limb and the use of two forearm crutches was initiated on postoperative day one. Clinical and radiographic follow-up visits were conducted in an outpatient setting at 3week intervals. Throughout treatment, loading of the operated limb was progressively increased until eventually; the crutches could be discarded as full weight-bearing was achieved. IEF was removed once the union of the fracture was confirmed radiographically and clinically. The radiographic criterion of union was the presence of at least three out of four cortices or trabecular bridging in anteroposterior and lateral views. The clinical criteria were the absence of pain, absence of pathological mobility, and dynamization of the Ilizarov apparatus applied once bone union for 4 weeks. Once their Ilizarov external fixator was removed, the patients were advised to walk with two forearm crutches and bear partial weight on the operated limb for 4 weeks.

The Association for the Study and Application of the Method of Ilizarov (ASAMI) bone score and (ASAMI) functional score were evaluated as well at the last follow-up visit (18).

Guarding against Pin tract infection, on each visit we were evaluating the soft tissue for infection and gardening according to Checketts -Otterburn classification (19)

## THE STATISTICAL ANALYSIS

The statistical analysis was conducted with the software program SPSS version26, figures were made in Excel. Quantitative data were presented as "mean and standard deviation" or as "median and interquartile range" while qualitative data were presented as frequency "number and percent (N, %)" distribution.

Mean, Standard deviation ( $\pm$  SD) and range for parametric numerical data, while Median and Interquartile range (IQR) for non-parametric numerical data. Frequency and percentage of non-numerical data. The level of statistical significance was set at  $p < 0.05$ .

## RESULTS

The study included 30 individuals, 28 of whom were male (93.3%) and 2 of whom were female (6.7%).

7 cases had a 23.3% Rt-sided fracture, while 23 cases had a 76.7% Lt-sided fracture.

According to the mode of trauma, 12 of them (or 40%) involved falls from great heights, 10 cases (33.3%) involved motor vehicle accidents, and 8 cases (26.7%) involved traffic collisions.

In two cases of each condition, hypertension and HCV were shown as related morbidities.

Without any corresponding morbidity met 86.6% of the individuals. (Table 2)

The percentage of bone union was 100%.

The mean time to union was  $4.43 \pm 1.47$ , ranging from (3 to 8) months.

As regards the wound care and closure, we performed delayed primary wound closure (at the time of Ilizarov application) in all the patients.

No reporting of any case complicated by leg limb discrepancy.

The procedure was associated with several complications (Table 1).

Pin tract infection was the most common complication associated with the procedure in 5 cases 16.7%, Only two patients 6.6 % had grade 2 infections and the condition was resolved after using proper antibiotics, complete bone union occurred with no long-term complications,

There were 2 cases (6.6 %) complicated with chronic osteomyelitis secondary to pin-tract infection.

2 cases (6.6%) were complicated by sequestered and exposed bone the condition was managed by IEF removal, corticotomy, and bone grafting with plate fixation

Regarding knee and ankle range of motion (ROM), Three patients (10%) had restricted knee flexion  $< 125^\circ$

One patient had complicated extensor lag which represented 3.3%.

Three patients (10%) had ankle ROM  $< 75\%$  of the normal ankle.

This included one patient with pre-operative foot drop which improved but the patient continued to have restricted movements of the ankle

Functional and bone results were made using the criteria proposed by ASAMI

We obtained: excellent results in 15 (50%) and good results in 7 (23.3%), fair results in 5 (16.7%), and poor results in only 3 patients (10% ).

## DISCUSSION

Management of open tibial fractures remains a challenge for orthopedic surgeons.

Management of these fractures has focused on vigorous debridement of the tissue and immediate bony fixation with tissue cover to enable early mobilization and restoration of optimum function.

The IEF is a minimally invasive method that permits effective wound management, early weight bearing, and bone stabilization.

In our study, we assessed the outcome of using IEF as a definitive treatment for 30 participants with open diaphyseal tibial fractures at the trauma unit of the orthopedic department of Aswan University Hospital.

In 20%, 30%, and 26% of patients, the fracture fixation was completed on the first, second, and third day following the trauma, respectively.

In 2021, Zhongguo et al. operated on every patient in their trial on the first day after the trauma.

Twelve incidents (40%) involved falling from a height, ten (33.3%) involved car accidents, and eight (26.7%) involved traffic accidents. As more cases are required to detect this significance, we ascribe our findings that there is no statistically significant difference between MOT and clinical outcomes to the sample size.

Regarding associated injuries in polytrauma patients, we discovered that patients with associated lower limb injuries started bearing weight and showed clinical improvement much later than patients with associated upper limb injuries or patients without associated injuries, which may have influenced the study's clinical outcome.

Due to the increase in the learning curve and hand skills of the surgeons, the operation took anywhere from 150 to 95 minutes. Additionally, by using a fixed team of surgeons, nurses, and workers, the operation took much less time.

We utilized a one-sample t-test, and the mean operating duration was 122 minutes (SD = 16.9). The time it took for the bones to unite and the length of the operation have a substantial positive link (P value 0.001). (table 4)

In 2021, Zhongguo et al. claimed that the duration of their surgery was 110–155 minutes (mean, 123.1 minutes).

The length of the hospital stay was determined by counting the days from the operation to ward release.

The average length of stay in hospitals was 5.33 days (with a range of 2 to 11 days), and the average time between visits was 12 months. The length of stay in hospitals serves as a proxy for patient compliance and recovery.

The average hospital stay in 2005, according to Oçgüder et al., was 16.7 days; the range for the average follow-up period was 19 to 34 months

Early rehabilitation is one of the benefits that the majority of instances received (flexion and extension of the knee, dorsiflexion, and plantarflexion of ankle immediate post-operative, assisted walking after 4 weeks, full weight bearing after the radiological sign of union).

Regarding ankle motion, there is a range from normal to restricted plantar flexion of 6.7% and dorsiflexion of 46.7%.

3 out of 27 patients experienced a loss of mean dorsiflexion of 5 degrees and mean plantarflexion of 10 degrees. 2007 with Demiralp, Bahtiyar, and others.

There was a statistically significant difference in the clinical outcomes of patients with related comorbidities.

Regarding bone healing, the average time to union was 4.431.47 months, with a range of 3 to 8.

The average time for bone healing according to Vasileios P et al in 2021 was 5.5 months. 3.6 months, compared to that of Messner J, et al. in 2018,

The average duration of the union for bone healing was 4.431.47 months, with a range of 3 to 8.

According to Vasileios P et al in 2021, the normal healing time for bones was 5.5 months. 3.6 months, as opposed to Messner J, et al study's from 2018.

Using the ASAMI-proposed criteria, we obtained excellent results in 15 patients, good results in 7, fair results in 5, and poor results in 3 patients.

According to Ashraf A et al. (2014), the functional and bone results were as follows: Excellent results in 16, Good results in 9, Fair results in 2, and one Poor result.

Asad Abdullah M et al. reported in 2020 that the functional and bone results were: Excellent result 29, Good result 12, and Fair result by Hospital for Special Surgery Knee score, and the following results were collected: Excellent in 18 cases, good in 10, two cases fair, and two cases poor.

Regarding the complications, 5 occurrences of pin tract were recorded, one of which was hypertensive. One case was in grade 3, two cases were in grade 2. There were 2 instances of chronic osteomyelitis brought on by pin-tract infections, and there were 2 instances where sequestered and exposed bone made matters worse.

According to a 2008 paper by Yusuf O'Ztu et al., 13 out of 24 patients had severe urinary tract infections; there were no cases of chronic osteomyelitis secondary to pin-tract infection.

The results of our study were compared with previously published papers (table 3)

Two cases involving shortening of the Achilles tendon were complicated by the patient's morbid obesity and resistance to active knee and ankle motion. One of the cases was treated with physiotherapy, and the other with tendon Achilles lengthening.

During limb lengthening with Ilizarov, two patients with nonunion of tibial hypertrophy from 12 instances experienced mild Achilles tendon contracture. As documented by Xu et al., in 2015, both patients responded effectively to treatment with the orthosis and walking drills, and they were free from all symptoms at the end of three months.

Our study's findings were compared to those of earlier, published articles (table 3).

## CONCLUSION

For the fixation of open diaphyseal fractures, the use of an Ilizarov external fixator has many benefits, including being a minimally invasive maneuver, bloodless operation, minimal post-operative pain, stable fixation linked to fewer risks of neurological and vascular injury than other maneuvers with a skilled hand, and early rehabilitation.

## REFERENCES

1. R.J. Weiss, S.M. Montgomery, A. Ahlin, Z. Al Dabbagh, A. Stark, K.A. Jansson Decreasing incidence of tibial shaft fractures between 1998 and 2004: information based on 10,627 Swedish inpatients *Acta Orthop*, 79(2008), pp. 526-533
2. Turen, C. H., & DiStasio, A. J. (1994). Treatment of grade IIIB and grade IIIC open tibial fractures. *The Orthopedic clinics of North America*, 25(4), 561-571.
3. Atif, M., Mohib, Y., Hasan, O., & Rashid, H. (2020). In the cost-conscious era: Ilizarov circular frame or uniplanar external fixator for management of complex open tibia shaft fracture, retrospective cohort study from a level-1 trauma center. *JPMA. The Journal of the Pakistan Medical Association*, 70(2), S20
4. Gustilo RB, Markow RL, Templeman Current concept review: the management of open fractures. *J Bone Joint Surg Am*. 1990;72:299– 303.
5. Meinberg E, Agel J, Roberts C, Karam M, Kellam J. Fracture and Dislocation Classification Compendium-2018. *J Orthop Trauma*. 2018;32 Suppl 1(1): S1-S170.
6. Hamdy, R. C., Rendon, J. S., & Tabrizian, M. (2012). Distraction osteogenesis and its challenges in bone regeneration. *Bone regeneration*, 8, 177-204.
7. Pu, Shaoquan, et al. "Clinical application of nose ring drain technique combined with Ilizarov circular external fixation for Gustilo IIIA Pilon fractures." *Zhongguo Xiu Fu Chong Jian wai ke za zhi= Zhongguo Xiufu Chongjian Waikexue Zazhi= Chinese Journal of Reparative and Reconstructive Surgery* 35.2 (2021): 195-199.
8. OCGUDER, D., et al. "Functional results of the Ilizarov circular external fixator in the treatment of open tibial fractures." *Acta orthopaedica et traumatologica turcica* 39.2 (2005): 156-162.
9. Demiralp, Bahtiyar, et al. "Spiral and oblique fractures of distal one-third of tibia-fibula: treatment results with a circular external fixator." *Annals-Academy Of Medicine Singapore* 36.4 (2007): 267.
10. Messner, J., et al. "Treatment and functional outcomes of complex tibial fractures in children and adolescents using the Ilizarov method." *Bone Joint J* 100.3 (2018): 396-403.
11. Giannoudis, Vasileios P., et al. "Clinical and Functional Outcomes in Patients with Distal Tibial Fracture Treated by Circular External Fixation: A Retrospective Cohort Study." *Strategies in Trauma and Limb Reconstruction* 16.2 (2021): 86.
12. Atef, Ashraf, and Ahmad El-Tantawy. "Management of open infected comminuted tibial fractures using Ilizarov concept." *European Journal of Orthopaedic Surgery & Traumatology* 24.3 (2014): 403-408.



13. Ullah Makhdoom, Asad, et al. "Management of segmental fracture of Tibia treated by Ilizarov external fixation." *Journal of Ayub Medical College Abbottabad* 32.3 (2020): 291-294.
14. Dickson, D. R., et al. "Grade 3 open tibial shaft fractures treated with a circular frame, functional outcome and systematic review of the literature." *Injury* 46.4 (2015): 751-758.
15. Naude, Jaco J., et al. "Functional outcomes and quality of life following complex tibial fractures treated with circular external fixation: A comparison between proximal, midshaft, and distal tibial fractures." *Strategies in Trauma and Limb Reconstruction* 16.1 (2021): 32.
16. Y Öztürkmen, M Karamehmetoglu, H Karadeniz, İ Azboy, M Caniklioglu *Injury* 40 (3), 321-326(2008)
17. <https://www.researchgate.net/journal/The-Journal-of-foot-and-ankle-surgery-official-publication-of-the-American-College-of-Foot-and-Ankle-Surgeons-1067-2516>
18. Testa, Gianluca & Vescio, Andrea & Aloj, Domenico & Costa, Danilo & Papotto, Giacomo & Gurrieri, Luca & Sessa, Giuseppe & Pavone, Vito. (2020). Treatment of Infected Tibial Non-Unions with Ilizarov Technique: A Case Series. *Journal of Clinical Medicine*. 9. 10.3390/jcm9051352.
19. Checketts R, Otterburn M, Mac Eachern A: Pin track infection;(definition, incidence, and prevention. *International Journal Orthopaedic Trauma* 2003, 3(3):16-18).



**Figures:**

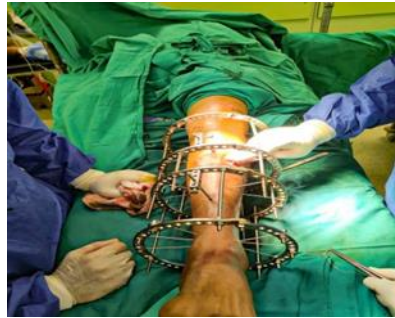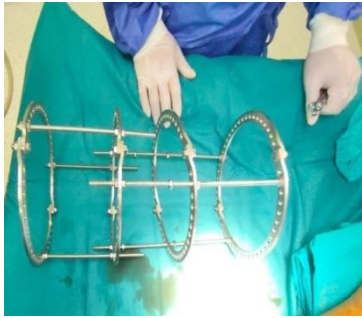


Figure 1: pre-constructed rings assembly. figure 2: Finalization of the assembly

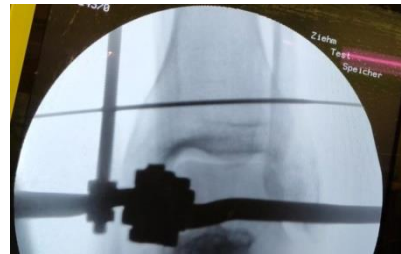
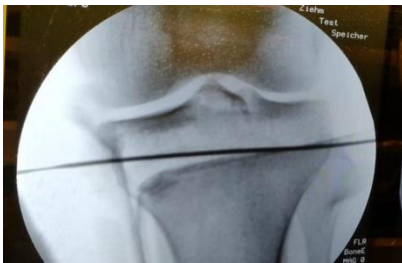
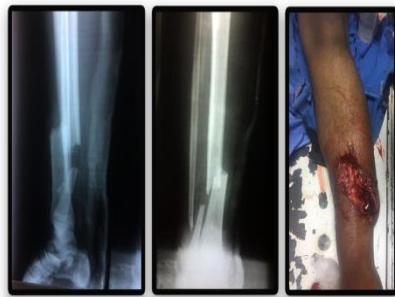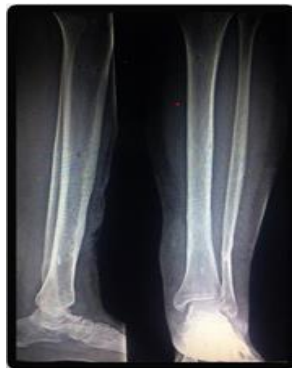Figure 3: The reference k- wire of the knee. figure 4: the reference K- wire of the ankle



**Figure 5 A :** preoperative x-ray finding, OGIII A mid-shaft tibia & fibula



**Figure 5B :** intraoperative fluoroscopy shows good reduction and acceptable alignment & fixation



**Figure 5C:** Three months postoperative follow-up X-showing complete bone union

**Table 1:** Complications of the cases.

	No. (n=30)	%
<b>Complication</b>		
<b>Pin tract infection</b>	<b>3</b>	<b>10.0</b>
<b>Sequestration and exposed bone</b>	<b>2</b>	<b>6.7</b>
<b>Shortened tendon Achilles</b>	<b>2</b>	<b>6.7</b>
<b>Non</b>	<b>23</b>	<b>76.7</b>

**Table 2** baseline characteristics.

	No. (n=30)	%
<b>Age</b>		
<b>Range</b>	<b>16 - 48</b>	
<b>Mean±SD</b>	<b>32.37±10.64</b>	
<b>Median(IQ)</b>	<b>30.5(25 - 45.25)</b>	
<b>Gender</b>		
<b>Male</b>	<b>28</b>	<b>93.3</b>
<b>Female</b>	<b>2</b>	<b>6.7</b>
<b>Side</b>		
<b>RT</b>	<b>7</b>	<b>23.3</b>
<b>LT</b>	<b>23</b>	<b>76.7</b>
<b>Mode of trauma</b>		
<b>Fall from height</b>	<b>12</b>	<b>40.0</b>
<b>MCA</b>	<b>10</b>	<b>33.3</b>
<b>RTA</b>	<b>8</b>	<b>26.7</b>

Associated morbidity		
HCV	2	6.7
HTN	2	6.7
No	26	86.7

**Table 3:** comparison table between our results and other published studies.

	Procure	No. of patient	Type of fracture	Hospital stay	Duration of union	Follow up	Age group	Modified ASAMI	complication	Operative time
Our study	Ilizarov	30	Open fracture	Mean 5.33 Range 2-11	4.3 months	Median 12 month	Median 32.7 years	EX 15 Good 7 Fair 5 Poor 3	Pin tract infection 3 cases	122 minutes, (SD = ±16.9)
Messner J, et al. 2018	Ilizarov	26	Open fracture		3.6	16 month				
D R Dickson, et al . 2015	Ilizarov	22	Grade III open fracture			12 month		EX over half of cases		
Jaco J Naude et al .2021	Ilizarov	45					18-65	Excellent and good > 90%		
Vasileios P, et at. 2021	Ilizarov	168	28% open fracture 63% intraarticular		5.5 month					
Asad Ullah M et al ., 2020	Ilizarov	45	Open fracture OLIVIA OGHIB		5.07 months		Mean 30Y	29 excellent 12 Good 4 Fair		
Yusuf O' ztu' Turkmen et al., 2008	Ilizarov	24	17 cases of open fracture	Mean 3.2 week	9.1 months	28 months		20 excellent 4		

			7 closed segmental fracture					Good	
Oçgüder, D. Ali, et al., 2005	Ilizarov	36	Open tibial fracture	16.7 days (range, 9 to 63 days)		28 months		14 Excellent 11 Good 8 Fair 3 poor	28.4% pin tract infection 2 cases of osteomyelitis.

**Table 4:** Correlation between operation time and time of union.

Operation time (min)		
	r	p
Time of union (month)	0.754	<0.001**