

ASDJ

AINSHAMS DENTAL
JOURNAL

Print ISSN 1110-7642

Online ISSN 2735-5039

AIN SHAMS DENTAL JOURNAL

Official Publication of Ain Shams Dental School

September 2021 • Vol. XXIV

Evaluation of Double OT CAP Attachment in Unilateral Partial Denture Cases with Different Saddle Length An In-Vivo Study

Nehal Shehab Ahmed¹, Shaimaa Lotfy Mohamed², Hany Ibrahim Eid³

Abstract

Aim: The aim of this study was to radiographically evaluate the effect of using double OT Cap attachment on the supporting structures of unilateral partial denture cases with different saddle length using the Digora imaging system.

Methodology: 16 patients with unilateral distal extension partially edentulous lower arches with last standing abutment 4 or 5 were selected in this study. Patients were rehabilitated with a unilateral RPD retained with a double OT Cap attachment where the last abutment is the 2nd premolar in group I & 1st premolar in group II. The lower 4 & 5 on the distal extension side in group I were prepared to receive a ceramo-metallic 2-unit fixed crowns, the same was done for 3&4 in group II. Crowns with their attachments were cemented to the abutment teeth and denture was delivered to the patient. Marginal bone height changes around abutments & residual ridge posteriorly were measured by Digora system. Data were collected at different follow-up intervals tabulated and statistically analyzed by Tukey's post hoc test and t-test for comparison between groups.

Results: Results of this study showed a significant difference as $P < 0.05$ in all intervals regarding overall 1st & 2nd abutment & distal extension ridge, bone changes in group II was significantly higher than group I.

Conclusion: With in the limitation of this study, it could be concluded that attachment retained partial dentures with OT unilateral attachment provide less bone height changes around the abutment & in the posterior area in short saddle cases.

Keywords: Bone loss, Distal extension base, Digora, Double OT cap, lower arch.

1. Assistant lecturer, Removable Prosthodontic Department, Faculty of Dentistry October 6 University
2. Assistant Professor, Oral and Maxillofacial Prosthodontics Department, Faculty of Dentistry Ain Shams University
3. Professor, Oral and Maxillofacial Prosthodontics, Faculty of Dentistry Ain Shams University

Introduction:

Removable partial dentures (RPD) continue to be an important prosthetic consideration in many oral reconstructions, particularly when edentulous ridges posterior to a patient's remaining teeth have to be restored. Prosthetic treatment options for partially edentulous patients include basic conventional removable partial dentures, overdentures, removable partial dentures with attachments or dental implants.⁽¹⁾

Rehabilitation of a partially edentulous arch can be challenging in Kennedy's class II distal extensions to restore esthetics and function successfully. In such a condition, a fixed partial denture cannot be fabricated due to the absence of a distal abutment an implant-supported prostheses can be planned but they are not always feasible due to insufficient bone and cost considerations. So, in such situation, a casted partial denture is largely preferred. These partial dentures are made retentive by the use of retainers and precision attachments.⁽²⁾

In attachment retained unilateral partial denture design, 1st and 2nd premolars are most often used as abutment teeth. The canine and 1st premolar can also be an option. The reasons for this is that the long length saddle acts as the class 1 lever; rigid pole with a fulcrum on one side; such can damage the RPD supporting structures.⁽³⁾

Extra-coronal precision attachments are those that are used to improve the stability and retention of removable unilateral distal extension prostheses. Additionally, it delivers better aesthetics, requires less postoperative adjustments, and improves patient comfort and satisfaction. These attachments are resilient, allowing the prosthesis to move freely and transmit destructive forces or stresses away from the abutments to supportive bone and tissue.⁽⁴⁾

OT unilateral attachment systems are castable attachments used for unilateral or implant-supported RPD without the need for

cross-arch stabilization from the other side of the arch. These attachments have multiple advantages as they provide lateral stability, superior retention, controlled resiliency, no need for milling, overall functional and economical solutions.^(3,5)

Digital intraoral radiographs are useful in cases of radiographic follow up for bone height changes. These devices have the advantages of providing consistent image quality, immediate image viewing, elimination of the darkroom, improved detection, electronic image processing, remote consultation capability, reduced exposure to x-rays, and the elimination of potentially hazardous chemicals.⁽⁶⁾

In direct digital radiography the image is digital so it can be stored on a disc facilitate measurements of bone loss or gain along the root surface, as well as overcoming the limitations of indirectly digitising a film with a camera or scanner. Digora is the cheapest method of assessment and delivers the lowest radiation dose to the patient during exposure.⁽⁶⁾

Hence, this present study was conducted in an attempt to evaluate the effect of using OT unilateral attachments on the bone loss around the posterior abutment in class II distal extension cases in different saddle lengths using the Digora as a digital intraoral radiography.

Material and methods:

Sixteen patients with unilateral distal extension partially edentulous lower arches with last standing abutment 4 or 5 were selected in this study from the outpatient clinic of the Prosthodontic Department, Faculty of Dentistry, Ain Shams University. All patients had mandibular Kennedy class II and maxillary dentulous arch. Both sexes with age range between 40 & 50 were presented in this study. The remaining teeth and abutment had healthy periodontium. The edentulous ridge is covered by healthy firm mucoperiosteum with moderate arch size

and normal size abutments. The selected patients had adequate inter-arch space and free from any systemic diseases.

Alginate impressions were made for both arches and poured into stone to obtain the diagnostic casts which were mounted on the articulator and examined for occlusion, inter-occlusal distance and condition of the remaining teeth. The mesiodistal width of the abutment teeth as well as the distal extension area were measured with a digital caliper on the diagnostic cast to standardize the normal size of teeth & moderate size of ridge. Preoperative peri-apical radiographs were used to evaluate the condition of the abutment and the quality and quantity of bone. Patients were divided into two groups: **group I:** 8 patients rehabilitated with unilateral RPD retained with a double OT Cap attachment where the last abutment is 2nd premolar. **group II:** 8 patients rehabilitated with unilateral RPD with a double OT Cap attachment where the last abutment is the 1st premolar.

Denture construction for group I patients: The lower 1st & 2nd premolars on the distal extension side were prepared with a deep chamfer finish line extend sub-gingivally to receive ceramo-metallic 2-unit fixed crowns. An impression was made with rubber base impression material after preparation of abutments then poured into stone. Removable dies were obtained by sawing. Wax pattern was constructed on the prepared abutments. The plastic pattern of the double OT extra-coronal attachment was joined to the distal surface of the wax pattern of the lower 2nd premolars 1mm away from the gingival margin. The wax pattern and the male portion of the attachment were joined together with wax. Uni-Box was fit exactly on the attachment and flushed smoothly with abutment wax coping. Layer of wax was adapted on the cast residual ridge then the castable connector was joined to Uni- Box by resin.

Spruing, investing, burnout and casting were carried out. The casting was finished except the male portion of the attachment. The finished castings were tried in the patient's mouth and checked for complete seating and proper adaptation of the finish line. Figure (1)

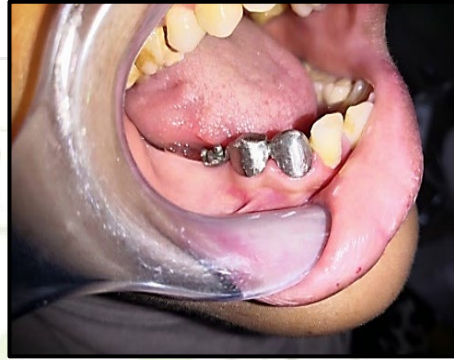

Figure (1): Finished castings tried in the patient's mouth

Porcelain was then fired to the metallic crowns. The veneered crowns with their attachments were temporary cemented to the abutment teeth and an impression was taken using rubber base impression material, poured in dental stone then duplicated. Wax pattern of the partial denture framework was made on the refractory cast. An indirect pick-up was done, the female portion of the extra-coronal attachments were attached to the wax pattern of the denture framework and were inserted into the male portions. Cast procedures were completed and metallic framework was obtained and retentive cap was inserted in the housing. Figure (2)

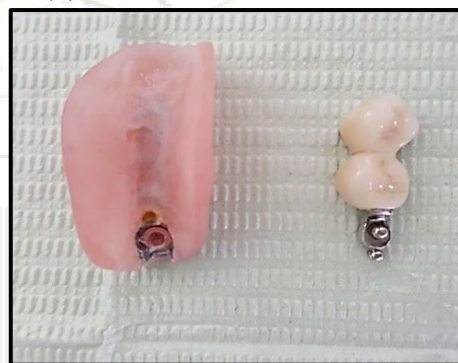


Figure (2) Processed denture after finishing and polishing.

The crowns-attachment assembly was cemented using resin cement. Figure (3)

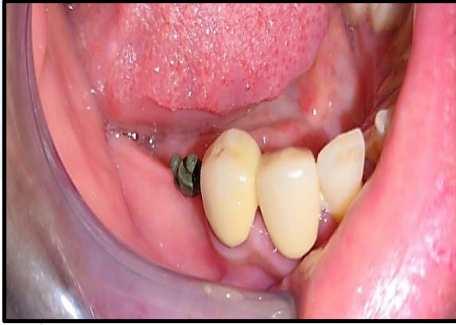

Figure (3) Crowns-attachment assembly cemented using resin cement

Denture processing was carried out in the usual manner. The finished and polished denture was delivered to the patient. Figure (4)

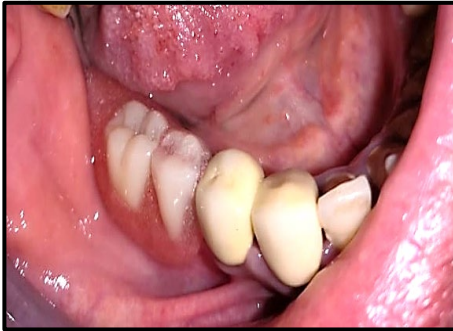

Figure (4) Finished and polished denture delivered to the patient.

Dentures construction for group II patients: The same steps were made as for group I except that the preparation was done for the 1st premolar & canine at the distal extension side by using the same double OT attachment.

Methods of evaluation:

Marginal bone height changes around abutments and at residual ridge posteriorly were assessed & measured at the time of delivery, 6&12 months later. The Digora system, together with imaging plate, periapical film holder & radiographic template were used to standardize the digital images.

a. Construction of the radiographic template:

An alginate impression was made for the mandibular arch and poured into dental stone. A self-cure acrylic resin applied

on the cast to cover the edentulous area and another mix was applied on the areas of the attachments then the anterior bite block was pressed on the soft resin so that the film holder is in a parallel relation to the long axis of the abutment. The finished and polished template was kept in water to be used throughout the study period.

b. Intra-oral direct radiography procedures:

The sensor was inserted in a protective bag then mounted to the film packing plate of the bite block. A long cone was mounted on the X-ray tube and the plastic aiming ring was fixed with the round end of the long cone. The radiographic template with bite block mounted was inserted inside the patient's mouth then assembled to the plastic aiming ring at the end of the cone by the indicator arm. Periapical radiographs were developed and scanned to the image processing software for measuring bone height after calibration of the image.

c. Image analysis for bone height changes around the abutment teeth & distal to edentulous ridge:

Linear measurement in mm was made at each follow up visit following the linear measurement of the Digora system. For (group I and II) a line tangential to the apex and perpendicular to their long axes was drawn then lines were drawn on distal & mesial sides of the last abutment starting from the alveolar crest, till the tangential line at the tooth apex. Same lines were drawn on the adjacent abutment on its mesial and distal surfaces. A horizontal line was then drawn at a distance 10 mm (group I) and 15mm (group II) from apex of last abutment. The 3rd vertical line was drawn from the highest level of the

alveolar crest to the horizontal line & perpendicular on it. Figure (5)

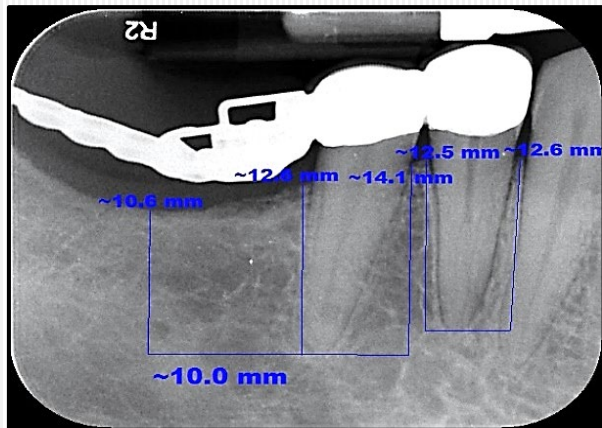


Figure (5) Image analysis by Digora software

Images of each patient were interpreted at each follow-up visit to record bone height changes around abutments and residual ridge. The amount of bone loss was calculated by subtracting the measured distances between each radiographic evaluation made at the time of denture insertion and the recall appointments.

Results:

Data were collected at different follow-up intervals at the time of delivery, 6 & 12 months later, tabulated and statistically analyzed. One-Way ANOVA for mean difference of bone loss in each group, Tukey's post hoc test & Independent t-test for comparison between both groups.

I) The mean, standard deviation, and P value of the Independent t-test of bone height changes between different axial surfaces throughout the time from insertion to 12 months post insertion and their level of significance were presented in Table (1).

Table (1): Comparison between group I and group II regarding bone changes at different interval in mesial & distal surfaces of 1st & 2nd abutment.

		group I		group II		P value
		M	SD	M	SD	
0-6	Mesial surface of 1st abutment	0.16	0.004	0.22	0.005	0.0001*
	Distal surface of 1st abutment	0.15	0.001	0.16	0.004	0.0001*
	Mesial surface of 2nd abutment	0.2	0.005	0.28	0.006	0.0001*
	Distal surface of 2nd abutment	0.36	0.008	0.37	0.008	0.0001*
6-12	Mesial surface of 1st abutment	0.06	0.001	0.32	0.007	0.0001*
	Distal surface of 1st abutment	0.2	0.005	0.36	0.008	0.0001*
	Mesial surface of 2nd abutment	0.145	0.003	0.28	0.006	0.0001*
	Distal surface of 2nd abutment	0.38	0.009	0.37	0.008	0.0001*
0-12	Mesial surface of 1st abutment	0.22	0.005	0.54	0.012	0.0001*
	Distal surface of 1st abutment	0.35	0.005	0.52	0.012	0.0001*
	Mesial surface of 2nd abutment	0.345	0.008	0.56	0.013	0.0001*
	Distal surface of 2nd abutment	0.74	0.017	0.74	0.017	0.0001*

M; mean SD; standard deviation *: significant difference as $P < 0.05$

Table(1) Showed a significant difference in all intervals as $P < 0.05$ regarding all axial surfaces in 1st & 2nd abutment when group I & II were compared together by using Independent t-test. However, group II (last abutment is the first premolar) shows higher bone loss around the abutments than group I (last abutment is the second premolar).

II) The mean, standard deviation, and P value of the Independent t-test for the bone height changes between overall of 1st & 2nd abutment and distal extension ridge throughout the time from insertion to 12 months post insertion and their level of significance are presented in Table (2).

Table (2): Comparison between group I and group II regarding bone changes at different interval in overall of 1st & 2nd abutment & distal extension.

		group I		group II	
		M	SD	M	SD
0-6	Overall 1st abutment	0.155	0.002	0.19	0.004
	overall 2nd abutment	0.28	0.006	0.37	0.008
	Distal extension	0.38	0.004	0.58	0.013
6-12	Overall 1st abutment	0.13	0.003	0.34	0.008
	overall 2nd abutment	0.263	0.006	0.37	0.008
	Distal extension	0.41	0.006	0.64	0.015
0-12	Overall 1st abutment	0.28	0.005	0.53	0.012
	overall 2nd abutment	0.543	0.012	0.74	0.017
	Distal extension	0.79	0.01	1.22	0.028

M; mean SD; standard deviation *: significant difference as $P < 0.05$

Table(2): Showed a significant difference in all intervals as $P < 0.05$ regarding the distal extension part of the ridge when group I & II were compared together by using Independent t-test. However, group II (last abutment is the first premolar) showed higher bone loss than group I (last abutment is the second premolar).

Discussion

Unilateral distal extension partial denture situations have always been an issue due to loss of abutments. These dentures are subjected to continual forces laterally, obliquely and apically, creating torque on abutment teeth and traumatization of the edentulous mucosa, inducing ridge resorption. This is due to the difference in viscoelasticity between the ridge and the periodontal ligaments of the abutment.(7)

Different design distal extension RPD precision or semi-precision attachments have been developed to reduce excessive torque acting on the abutment to protect the abutment teeth and their supporting structures.(8) In this study both groups of patients were rehabilitated with RPD retained by extra-coronal double OT attachment. The attachment has both mechanical and esthetic advantages as it

features elastic retention, which controls the flexure and constructs a resilient and shock absorbing prosthesis as well as reducing the amount of metal display, which will improve aesthetics.(9,10,11) The extra-coronal double OT Unilateral attachment kit features a distinctive two-in-one design that incorporates horizontal and vertical microspheres with the OT cap and OT strategy attachment systems giving lateral stability and distal support to the prosthesis.(5) The double OT attachment system can restore distal extension areas without the need of cross arch extension to the other side of the arch as the support from the RPD and its connection to fixed prosthesis generates cross arch stability during masticatory activity and allows fixed prosthesis-like function.(9,10,12)

Results of this study showed that in both groups the distal abutments adjacent to the distal extension area are the most affected, especially at their distal surfaces. This could be explained by the fact that when occlusal forces are applied to the distal extension RPDs, the extension bases are gently displaced, with greater movements in the direction of soft tissues due to lack of posterior support, causing tensile forces on the abutments in distal direction. This came in line with a study that indicated that the highest strain values obtained from the strain gauges were distal to the terminal abutments.(13)

Extra-coronal resilient attachments, which are resilient and shock-absorbing prostheses, can relieve stress on the terminal abutment by transferring the load on the distal extension edentulous ridge.(14) This could be due to the unique exclusive design of the OT unilateral attachment with the presence of two balls in different planes help to distribute the load more favorably under masticatory force. (5,15) This was in agreement with a recent study by Wang H-Y who recommended the use of extra-coronal

attachments with stress releasing properties in unilateral distal extension cases to properly distribute stresses between abutment and the residual ridge.(14)

In this study bone resorption in distal extension area was higher than that around the distal abutment in both groups, which could be because of the high bony support around the distal premolars as well as the splinting of the last two abutments together that will reduce the stress concentration to the bone around them.(16,17) In addition, resilient retainers are unable to distribute force applied to the artificial tooth efficiently, resulting in a greater load on the residual ridge.(8) This came in agreement to a study that concluded that Stress on the terminal abutment can be reduced by the use of an extra-coronal resilient attachment that allocates more loads onto the distal edentulous ridge.(14) This also came in agreement with Patnogić V who stated that stress levels found both on abutment teeth and on the attachment are lower than the marginal ridge. (3)

Radiographic evaluations in this study showed that the OT unilateral attachment used in group I causes less bone resorption on last standing abutment than that in group II. The increase of bone resorption in group II could be attributed to the yielding of the prosthesis at the free end of the cantilever. It was reported that long saddle recorded significant higher stresses on the abutment and ridge than did the short saddle. When this stress exceeded the natural resistance, bone resorption occurs.(18,19) This finding is in agreement with a study that reported high stress levels on the primary abutments when the long saddle was used, results showed that physiological forces cause a different stress distribution on the abutment teeth and the attachment, depending on the saddle length. The reason for this result lies in the fact that the load point of the force is very close to the attachment when the saddle

is short so the attachment here accepts most of the load and protects the abutments.(3)

On the other hand, the results also showed less bone height resorption at the distal extension base in group I compared to group II this could be due to the length of the cantilever partial denture which is shorter in group I as the fulcrum line is shifted to the end point of the attachment transmitting less stress to the supporting structures when compared with group II. The long length saddle acts as a class I lever, rigid pole with a fulcrum on one side, such can damage the RPD supporting structures. This came in agreement with a study that concluded that lengthening of the lever arm in an attachment retained unilateral distal extension partial denture results in a stress level rise which will result in bone height resorption. (3)

Conclusion

Within the limitation of this study, it could be concluded that attachment-retained partial overdentures with an OT unilateral attachment provide less bone height changes around the abutment and in the posterior area in short saddle cases.

References:

1. Jin X., Sato M., Nishiyama A., Ohyama T. (2004): Influence of loading positions of mandibular unilateral distal extension removable partial dentures on movements of abutment tooth and denture base. *J Med Dent Sci*, 51; p. 155.
2. Mc Craken's removable partial prosthodontics (2011): 12th ed. St Louis: Mosby Co.; p. 103-15. P.6, 21.
3. Patnogić V, Todorovic A, Scepanovic M, Radovic K, Vesnic J, Grbovic A. (2013): Free-end saddle length influence on stress level in unilateral complex partial denture abutment teeth and retention elements. *Vojnosanit Pregl* ; 70(11): 1015–1022.
4. Makkar S, Chabara A and Khare A (2011): Attachment retained removable partial denture: a case report. *Int J of Comp and Digist Syst*, vol.2, p.39.
5. Rhein 83 srl, Catalogue/Technical manual for dentists and dental technicians (2013): Attachments and prefabricated castable components; 14-37.
6. Mohammed N.H., Omar H.M. (2012): Radio densitometric Assessment Of Alveolar Cleft Grafting

Using Two Different Softwares. *J Am Sci*; 8(11):253-260. (1545-1003).

7. Elsayed Gad Eid (2017): Stress analysis of removable partial dentures of distal extension cases fabricated of two recent aesthetic CAD/CAM prosthetic materials versus conventionally manufactured metallic RPDS, *E. Dent. J.*, Vol. 6, 1003:1017.

8. Bhathal M., Batra J., Attresh G., Sambyal SH. (2015): A review on stresses-induced by removable partial dentures. *Int J Contemp, Dent Med Rev*, 050115.

9. Khare A, Makkar S, Roshna T (2011): Full Mouth Rehabilitation with Fixed and Removal Prosthesis using Extracoronary Attachments: A Clinical Report *People's Journal of Scientific Research*, 4(2):47-52.

10. Nugala B, Kumar BS, Sahitya S, Krishna PM. (2012): Biologic width and its importance in periodontal and restorative dentistry. *Journal of Conservative Dentistry: JCD.*;15(1):12-17.

11. Alm Eldeen H.I (2017): The effect of reciprocal arm on the supporting structures of the abutments in cases retained by unilateral attachment. *Egypt. Dent. J.* Vol. 63, 933:939.

12. Sravanthi G, Dinesh B, Taruna M, Prasad V (2014): Unilateral Attachment Retained Distal Extension Removable Partial Denture, *Indian J Dent Adv*; 6(4): 1727-1730.

13. Sahin V, Akaltan F, Parnas L. (2012): Effects of the type and rigidity of the retainer and the number of abutting teeth on stress distribution of telescopic-retained removable partial dentures. *J Dent Sci.*;7(1):7-13.

14. Wang H-y, Zhang Y-m, Yao D, Chen J-h.(2011): Effects of rigid and non-rigid extra-coronary attachments on supporting tissues in extension base partial removable dental prostheses: a nonlinear finite element study. *The Journal of prosthetic dentistry*, 105(5):338-46.

15. Afify M., Helmy M., Abbas N.(2020): Evaluation of biting force of New Design of extracoronary castable precision attachment versus conventional partial denture for treatment of unilateral mandibular distal extension area: A randomized controlled trial. *Maced J Med Sci*; 8(D):23-28.

16. O gata K. (1993): Longitudinal study on torque around the sagittal axis in lower distal-extension removable partial dentures. *J Oral Rehabil*, 20:203-11.

17. Bakke M, Holm B, Jensen BL, Michler L and Moller E. (1999): Unilateral, isometric bite force

in 8-68 year old women and men related to occlusal factor. *Scand. J. Dent. Res.* 98;149-158.

18. ELSyad M.A, Abd El Ghany Kabil A., El Mekawy N.(2017):Effect of Implant Position and Edentulous Span Length on Stresses Around Implants Assisting Claspless Distal Extension Partial Overdentures: An In Vitro Study. *J Oral Implantol.* 43 (2): 100–106.

19. Jones J. D., Turkyilmaz I, and Garcia L. T. (2010): "Removable partial dentures--treatment now and for the future". *Texas Dental Journal*,127, 365.