

Pediatric Maxillofacial Injuries; A single institutional experience

Islam A. Amer

**Original
Article**

Maxillofacial, Head and Neck Surgery Unit, General Surgery Department, Faculty of Medicine, Sohag University, Sohag, Egypt.

ABSTRACT

Background: The most commonly observed emergency, contributing to high morbidity and mortality is pediatric trauma. The purpose of this research is to analysis the incidence and pattern of maxillofacial trauma in children in Upper Egypt and to assess its management regarding to the successful healing with the least complications.

Patients and Methods: This prospective research was performed at the Maxillofacial / Head and Neck Surgery Unit of General Surgery Department of Sohag University Hospitals. All children with maxillofacial trauma during the period from January 2016 to May 2020 and from all governor around sohag that include Qena, Luxor, Aswan and the Red Sea were enrolled . The study included 232 pediatric patients with a total of 298 fractures.

Results: The male: female ratio was 3.3:1. The age group 6 to <12 years was the most common group to be injured by 95 patients (40.9%) and the age group <3 years was the least group to be injured by 8 patients (3.4%). The most common cause of maxillofacial trauma was falling from hight (FFH) with 144 (62.1%) patients, followed by motor car accident (MCA) affecting 67 (28.9%) patients. Mandibular fractures had the highest incidence with 152 (51.0%) followed by Midface fractures with 73 (24.5%). Associated soft tissue injuries were present in 22% of all cases. All the included fractures healed successfully.

Conclusion: FFH was the essential cause for maxillofacial injuries. Males and parasymhesial fractures showed the highest predominance. International guidelines should be followed for the determination of the treatment of choice either conservatively or surgically and the treatment of choice is dependent on fracture morphology, patient characteristics and surgeon experience and skill. The post traumatic follow up helps to avoid harmful draw backs.

Key Words: Children, fall from height, fracture, mandible, maxillofacial trauma.

Received: 14 March 2021, **Accepted:** 12 April 2021

Corresponding Author: Islam A. Amer, MD, Maxillofacial, Head and Neck Surgery Unit, General Surgery Department, Faculty of Medicine, Sohag University, Sohag, Egypt, **Tel.:** 00201017766441, **E-mail:** dr.islamamer1981@gmail.com

ISSN: 2090-0740, 2021

INTRODUCTION

The most commonly observed emergency, contributing to high morbidity and mortality is the pediatric trauma.^[1,2] Trauma is characterized, as a body injury caused by an external mechanical force and it is one of the main morbidities and a leading cause of death.^[3]

Maxillofacial fractures are a worldwide injury that can happen solitarily or in conjunction with other injuries including cranial, spinal, and upper and lower body injuries that require urgent evaluation for potential emergency interventions.^[4] Because of their higher cranial mass-to-body ratio, children are highly vulnerable to craniofacial trauma. In children under 16 years, the incidence of facial fractures is 1:14% and in those younger than 5 years, it is 0.87:1%.^[5]

The common causes of this injury are mainly fall from a height, road traffic injuries, sports accidents, and physical violation. Diagnosis depends essentially on clinical and

radiographic evaluations. Trauma management involves treating the soft tissues and/or the bone trauma together with the emergency care of other life threatening injuries.^[6]

Compared to adults, the occurrence of maxillofacial trauma in children is less, but because of the major difference in children's facial morphology, they need to be treated as a special category of maxillofacial surgery patients. These variations include, children age, the small dimensions of the bones, the small size of the paranasal sinuses, the capacity for growth, the existence of tooth germs in the jaws during primary and mixed dentition, and a faster healing process together with cooperation difficulties, and most of cases need to be operated under general anaesthesia than adult.^[7]

The place and pattern of the fracture depend on the interrelationship between the causative instrument, its momentum, and the particular anatomical characteristics

of the stage of development of the child. infants (under the age of 2) are more common to experience frontal region injuries, while older children are more vulnerable to chin, lip, cheek, and nasal region injuries.^[8]

Pediatric fractures are less frequent than soft tissue injuries and display varying clinical presentations depending on the causative instrument and the phase of bone maturation.^[9] The most frequent injuries in pediatric trauma are mandibular fractures, with the Condylar region being the most common broken site.^[10]

Concomitant soft tissue injuries and facial fractures take place in 29:56% of the cases. Appropriate and early washing, debridement, and closure of the wound together with an antibiotic prophylaxis should be performed for the treatment of these injuries.^[11] Acrylic splints with perimandibular wiring should be considered for the treatment of mandibular fractures in young age group, open reduction and internal fixation is favored in the older children, and biodegradable plates can also be used in older pediatric age.^[12]

The purpose of this research is to analysis pattern, different treatment modalities and possible complications in paediatric maxillofacial trauma at Sohag University Hospitals in Egypt.

PATIENTS AND METHODS:

This retrospective research was performed at the Maxillofacial / Head and Neck Surgery Unit of General Surgery Department of Sohag University Hospitals, in the period from January 2016 to May 2020.

A full history was obtained from all the patients or their parents including items of the personal history as name, age, sex and Residence. These data also included mode of trauma that was categorized into FFH, MCA, assault from others, animal kick, and sport related injuries. The children were classified into 4 groups depending on their age: Group A (1 <3 years), Group B (3 <6 years), Group C (6 <12 years), and Group D (12 ≤16years).

All the patients were brought to the ED (emergency department) of Sohag University Hospitals by their relatives and full resuscitation was done according to ATLS protocols. Clinical examinations were performed and they were assessed by investigations either laboratory or radiological that were done especially for poly-traumatized patients.

Laboratory: such as

- Complete blood count, Prothrombin time and concentration, Serum glucose, and Serum creatinine.

Radiological: Such as

- X-rays (with panoramic images if needed), FAST (Focused assessment with sonography for trauma) scan, CT brain and 3D face.

Classification of maxillofacial injuries:

Types of recorded maxillofacial trauma were categorized into soft tissue injuries and maxillofacial fractures.

The fractures were allocated to mandibular, midface, fronto-orbital fractures, and dento-alveolar fractures:

- The **mandibular fractures** were classified as stated by Killey^[13] into condyle, ramus, angle, body, symphyseal, and parasymphyseal.

- The **midface fractures** were also subdivided as Le Fort I, II, and III types, zygomatic complex, naso-orbital-ethmoidal (NOE), and nasal fractures.^[52]

- The **fronto-orbital fractures** include frontal bone fracture, lateral orbital wall fracture, medial orbital wall fracture, supra-orbital wall fracture, and infra-orbital wall fracture.^[53]

- **Dento-alveolar fractures:**

Although, all of these sites may be fractured isolated or combined with another type, one bone may include many fractures in different anatomical sites as mandible may be fractured in two different sites like condyle and parasymphysis.^[54]

Concomitant injuries:

Facial fractures are usually caused by a severe trauma, so there can be other associated injuries. These injuries include Neurocranial, Ophthalmological, Cardiothoracic, Orthopedic, or Abdominal injuries.

Midface and mandible fractures have the greatest risk of concomitant injuries due to high-energy impact mechanisms needed to induce these fractures.

Inclusion criteria:

All patients with any maxillofacial trauma isolated or associated with other injuries, were eligible for the study.

Exclusion criteria:

Patients with maxillofacial trauma aging above 16 years old were not enrolled in the study.

Treatment protocol:

A variety of factors should be considered when deciding a regimen of care for pediatric patients with facial injury. They include:

1. The patient's age: to optimize growth and development.
2. The anatomic site: to improve shape and function.
3. The severity of the injury (displacement, comminution, and the number of injuries):
4. The time passed since the infliction of the injury: best to be managed within 4 days.
5. Concomitant injury: to determine anesthesia fitness and duration of the operation.
6. The surgical approach (if intervention is required) : closed versus open.

In case of stable bones, particularly when the fractures are non-displaced or greenstick fractures, non-operative (conservative) management may be possible and observation alone is adequate to avoid complications. It is associated with cautious instructions for the parents and close follow-up in outpatient clinics.

Arch Bar wiring is a line of treatment for:

- Dento-alveolar injuries,
- Mandible and maxilla fractures (with minimal displacement), and can be associated with maxillo-mandibular fixation (MMF).

Open reduction and rigid internal fixation (ORIF) by plates and screws are recommended for markedly displaced fractures. Many of fracture cases may require mixed lines of treatment (ORIF + MMF).

Special instructions were ordered for the patients and parents about the importance of oral hygiene in the case of fracture mandible.

In pediatric trauma cases, soft tissue injuries necessitate prompt care of the wounded tissue following standard wound care procedures and removal of any particles from the dermis, immunization against tetanus, and debridement of the contused wound margins. The steps of management are almost the same as for adults, except that care should be begun within hours, as recovery happens faster.

Postoperative evaluation:

Post-operative evaluation and follow up are very important in the pediatric population due to the good healing power and crucial complications that may occur such as infection, wound dehiscence, malocclusion, and TMJ ankylosis.

The follow up of our patients was done at 7th, 15th, 30th days, and at end of the 2nd month and the 3rd month, in outpatient's clinic of Maxillofacial / Head and Neck Surgery Unit of General Surgery Department of Sohag University Hospitals.

All these previous data were recorded, tabulated and statistically analyzed.

RESULTS:

Fractures were managed either conservatively or through surgical intervention according to the guidelines, and depending on the type of injury, patients' ages, and the concomitant injuries. Performed surgical interventions included closed reduction with mono-fixation, maxillo-mandibular fixation (MMF), or the open reduction and internal rigid fixations (ORIF).

Sociodemographic characteristics

232 children with 298 fractures were managed at Maxillofacial / Head and Neck Surgery Unit of General Surgery Department of Sohag University Hospitals due to maxillofacial trauma. Their age varied from 2: 15 with a median of 7 years old at the time of presentation in the emergency room.

In our study, out of the 232 patients treated in our unit, there were 178 (76.7%) males, and 54 (23.3%) females with a male: female ratio of 3.3: 1 (Table 1).

The group A (1 to <3 years group) was the least group to be injured; 8 patients (3.4%), in group B (3 to < 6 years group) the number of patients was 72 patients (31.0%), group C (6 to <12 years group) was the most vulnerable to be injured; 95 patients (40.9%), and lastly the number of the patients in group D (12 to ≤16 years group) was 57 patients (24.6%) (Figure 1).

Regarding the patient's residence, 163 (70.3%) patients were from Sohag governorate, 55 (23.7%) patients were from Qena governorate, and 14 (6%) patients were from Aswan governorate (Figure 1).

Mode of Trauma:

The most prevalent cause of maxillofacial injuries among all the studied patients and among all the age groups was falling from height (FFH); 144 (62.1%) patients. Motor car accident (MCA) affected 67 (28.9%) patients, followed by animal kick in 12 patients (5.2%), sport related injury in eight patients (3.4%), and assault from others in one patient (0.4%) (Table 2).

Trauma due to assault occurred only in age group 12: 16 years, whereas in the age group < 3 years, the mode of trauma was FFH.

Type of Injuries:

We found in our study that out of 232 patients: (Table 3).

- Solitary soft tissue wounds such as abrasions and lacerations without bone affection were present in 23 (9.9%) children.
- A total of 181 (78.0%) patients had isolated fractures.
- All the rest of the injuries; 28 (12.1%) patients had both soft tissue and bone injuries.

Concomitant injuries:

Abdominal surgical injuries were the most frequently associated injuries. Most of these injuries that were found in 36 (15.5%) patients were in the form of intra-abdominal collections and only one patient underwent splenectomy. The second most common associated injury was orthopedic injury in 32 (13.8%) patients, then neurological injury in 23 (9.9%) patients, Cardiothoracic injury in 8 (3.4%) and finally four patient (1.7%) displayed ophthalmic injury in the form of rupture globe (Table 4).

Anatomic site of the fractures:

298 fracture sites in 209 children were reported during the period of the study. Mandibular fractures were the most common fractures 152 (51.0%), followed by 73 (24.5%) midfacial fractures, 45 (15.1%) fronto-orbital fractures and the least common fractures were dento-alveolar fractures by only 28 (9.4%) fractures (Figure 2).

Types of mandibular fractures:

The parasymphiseal fracture was the most common mandibular fracture by 64 fractures (42.1%), followed by Condyle 36 (23.7%), Symphysis 20 (13.2%), Angle 16 (10.5%), body 12 (7.9%), and ramus 4 (2.6%) with no reported coronoid fractures (Table 6).

Types of Midface fractures:

Nasal fracture were the most prevalent type of midfacial fractures by 35 fractures (47.9%), ZMC by 22 (30.1%), Le fort III by 8 (11%), Le fort I by 4 (5.5%), NOE by 4 (5.5%), and no cases with Le fort II fracture were reported (Table 6).

Types of Fronto-orbital fractures:

Supraorbital fractures were the most frequent fronto-orbital fractures type by 18 fractures (40.0%), followed by infraorbital fractures by 19 fractures (42.2%), frontal bone by 4 (8.9%), and lateral orbital wall fractures by 4 (8.9%) (Table 6).

Management of soft tissue injury:

All soft tissue injuries, 51 (22%), whether being isolated or combined with fractures were managed by suturing.

Treatment of Pediatric Facial Fractures:

Out of the 298 fractures, 84 fractures (28.2%) were treated by conservation, 28 fractures (9.4%) needed open reduction and internal fixation (ORIF) only, and 74 fractures (24.8%) needed maxillo-mandibular fixation. Moreover, 62 fractures (20.8%) were managed by combination of ORIF and MMF, and titanium mesh was used in 10 (3.4%) fractures. Twenty-four fractures were managed by Arch bar and out of 35 nasal fractures, 16 fractures were managed by CR (Table 7).

Out of 35 nasal fractures, 16 fractures were treated using closed reduction and external fixation. The rest (19 fractures) were managed by conservation (Table 8).

Postoperative complications:

The follow up showed that out of the 232 patients, only 12 patients suffered from complications postoperatively. 8 (3.4%) patients of them displayed infection and four patients of 205 mandibular fracture (1.9%) patients displayed malocclusion (Table 9, Figure 3).

Table 1: demographic data

	Group D	Group F	P value
Age	25.2±5.3	26.5±7.5	0.65
Sex	17;13	16;14	0.23
Weight	45.7±4.7	46.6±5.8	0.76
Height	150.5±6.5	151.8±6.4	0.67
ASA 1/11	22/8	24/6	0.45

Table 2: comparison between two groups as regard intubation score, success, intubation time and satisfaction score.

	Group D	Group F	<i>P value</i>
Intubation score			
Vocal cord movement			
1/2/3/4	21/9/0/0	15/8/7/0	0.03
Limb movement			
1/2/3/4	17/6/4/3	13/8/5/4	0.5
Cough	5	7	0.6
Success	30	30	No significant
Intubation time	3.6±4.3	5.3±6.5	0.02
Satisfaction score (1-4)	25/5/3/2	20/4/3/3	0.32

Table 3: comparison between two groups as regard post intubation score, Ramsay sedation score and Spo2

	Group D	Group F	<i>P value</i>
Post intubation score 1	25	5	0.006
Post intubation score ≥ 2	5	25	0.001
Ramsay sedation score (RSS)	3 ± 0.642	2.5± 0.547	0.0007
Spo2 ≤ 94	6	23	0.006
Spo2 ≥ 95	24	7	0.005

Table 4: Haemodynamic changes between two groups including (HR, MAP) at times in baseline, initiation of fiberoptic and one minute post-intubation.

Mean blood pressure (MBP)	Group D	Group F	<i>P value</i>
Base line	95.5±5.7	95.4±8.2	0.65
At the initiation of fiberoptic	96.4±7.6	97.4±5.4	0.74
One minute after intubation	97.7±6.2	117.6±4.3	0.003
Heart rate(HR)	Group D	Group F	<i>P value</i>
Base line	74.4±7.8	75.3±6.4	0.87
At the initiation of fiberoptic	73.4±6.8	77.5±4.3	0.34
One minute after intubation	72.4±5.4	114.4±4.3	0.008

Table 5: comparison between 2 groups as regard cortisol level

	Group D	Group F	<i>P value</i>
Cortisol level at time of induction Nano/ml	266.7±211.22	270.4±160.23	0.67
Cortisol level after 20 min	270.6±155.72	269.8± 150.4	0.85

Table 6: Adverse events and satisfaction data between group (D) and group (F) during fiberoptic intubation. Data are expressed as median (IQR [range]) or number (proportion).

	Group D (n=20)	group F (n=20)	<i>p value</i>
Airway obstruction score; 1/2/3	(20/5/5)	(15/8/7)	0.007
Hypoxia	0	1	0.31
Temporary hemodynamic support			
Atropine	2	0	0.15
E30940134	1	0	0.31
Hoarseness	4	4	1
Sore throat	2	5	0.21

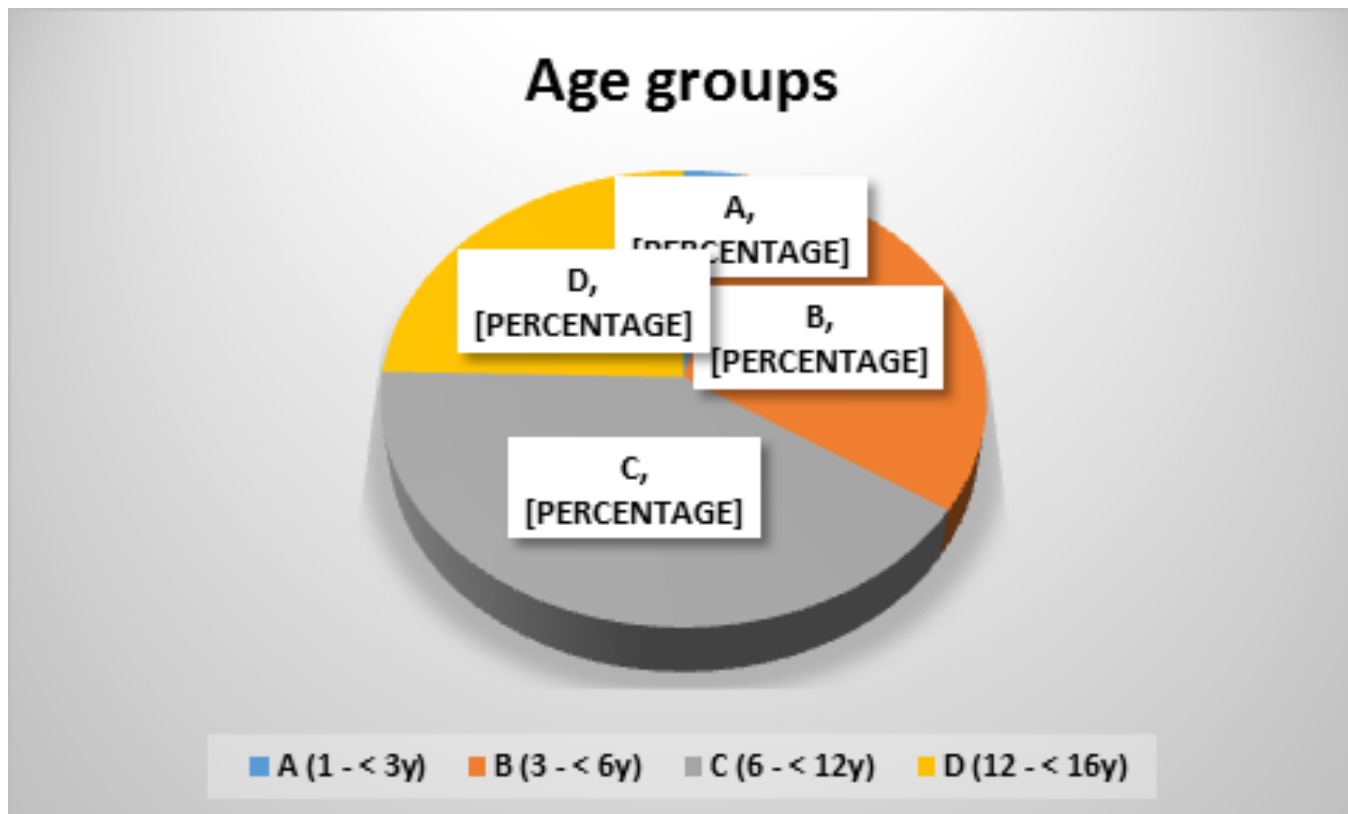


Fig. 1: Age group of the studied patient

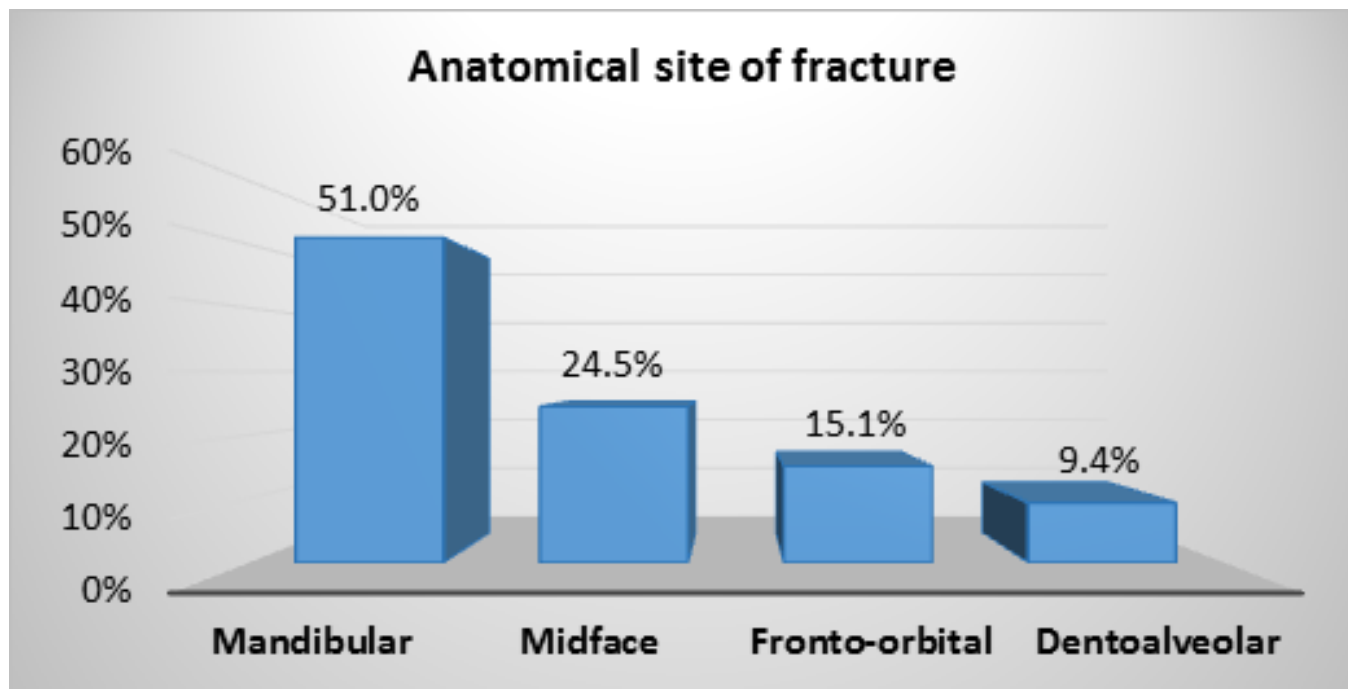


Fig. 2: Anatomical site of fractures in the studied patients

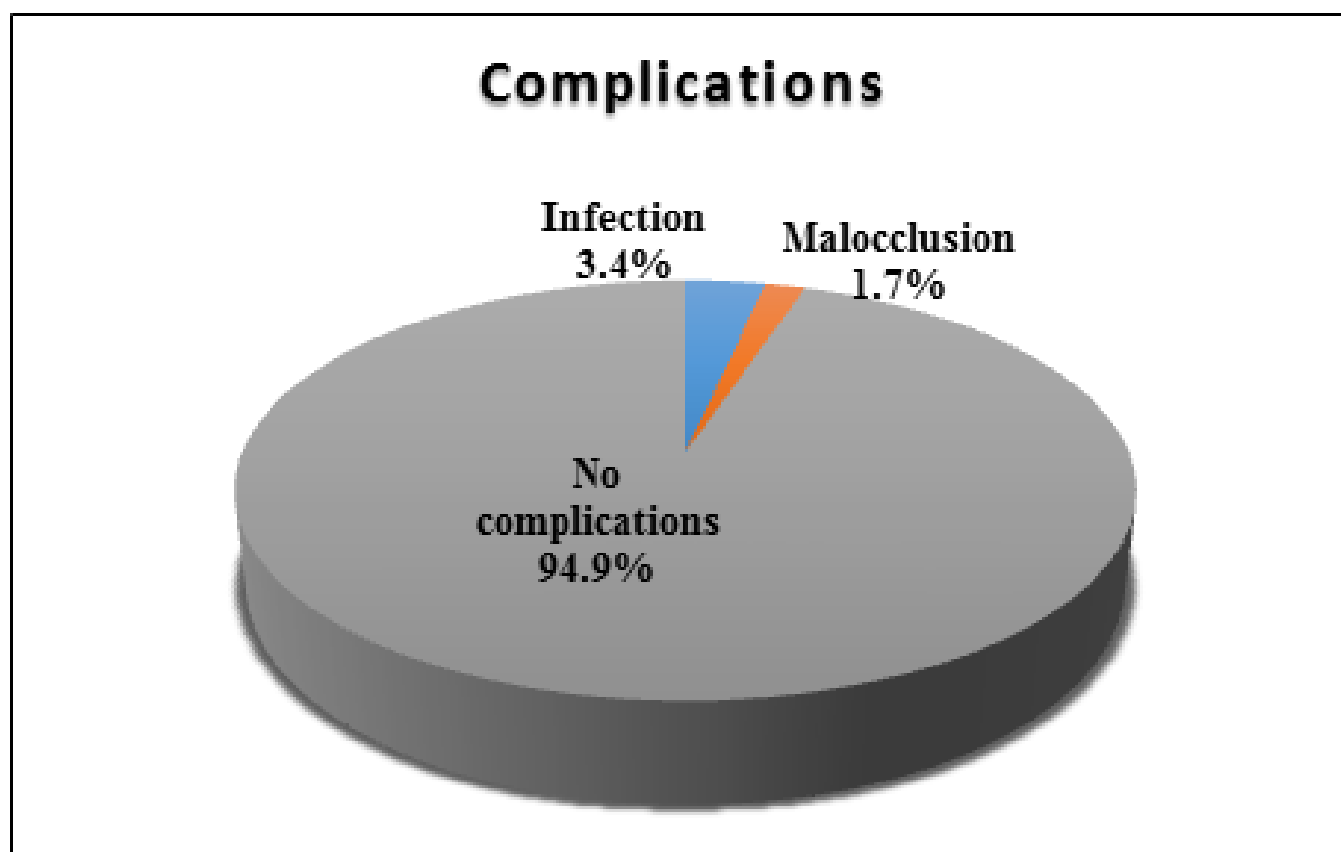


Fig. 3: complications among of maxillofacial trauma the studied patient

DISCUSSION

The most frequently seen injury in the emergency room that contributes to high morbidities and mortalities is the pediatric trauma.^[1,2] The significant position and function of the human face contribute to the significance of facial trauma and its effect on essential functions as well as the quality of life.^[6]

The findings of the current research represented that relative to others, Category A (1 to <3 years) had the lowest incidence of facial injury and reflected (3.4 percent) of pediatric maxillofacial trauma. This may be attributed to the secured environment and surroundings. This is in accordance with earlier studies which stated that maxillofacial fractures in children below 5 years had the least incidence among pediatric facial trauma cases^[14,5], and^[8]. As a consequence of increased risk-taking activity with a decrease in the parental control, this incidence increases among older children (15). Thus, the most injured group was Group C (6 to <12 years) representing (40.9%); 95 patients. This also agreed with^[12,16] and^[17] who have reported a peak incidence within this range.

The predominance of males with pediatric injuries that was represented in 178 (76.7%) patients out of 232 patients with male: female ratio of 3.3:1 is in agreement

with other studies of facial injuries^[14,18,19,3,8,20,21] and^[22]. The cause is that boys are usually more tumultuous than girls and spend a lot of time outdoors.

Causes and incidence of maxillofacial injuries vary among different countries possibly due to variant social, cultural, and environmental factors.^[18]

In our study, FFH was responsible for (62.1%) of pediatric maxillofacial injuries and was the major cause for pediatric maxillofacial trauma in Upper Egypt. This agrees with other public studies as^[18,5,16,8,1,23,21] and^[11]. In children up to 6 years age), falls at home were the most prevalent. In older children with more outdoor exposure, falls occur outside the safe area of the home supervised by the parents.

Other studies, as^[19] and^[24] confirmed that Road Traffic Accidents (RTA) were the main reason for pediatric facial trauma. However, in this study they comprised a little percentage representing (28.9%) of the injuries and were observed to be the second cause of injuries as stated also in^[25] and^[18].

In the present study, the percentage of sports related injuries was (3.4%) and occurred in the age

group of 12-16 years. In accordance with this finding, a previous study stated that this type of facial trauma occurred in children 10–14 years of age. As physical activities develop since childhood, an increase in the level of exercise and outdoor exposure make older children more vulnerable to trauma associated with sports^[26].

Interpersonal abuse is not common in children compared to adults and accounted for only one patient (0.4%) out of 232 patients. These injuries are more frequent in adolescents.^[8]

There were 12 (5.2%) incidence of animal caused injuries. Such injuries happened in rural areas where the patients deal with farm animals found in their community. This comes in line with prior researches^[27,28] and^[29].

Out of the 232 patients, there were 163 (70.3%) patients from Sohag governorate where our unit is located within its university hospitals. So, the most of patients were from this governorate. From Qena governorate, there were 55 (23.7%) patients, and 14 (6.0%) patients were from Aswan governorate. This may be due to presence of other centers within these two far governorates that can manage facial trauma in their pediatric population.

Maxillofacial fractures a worldwide injury that can happen solitarily or in conjunction with other injuries including cranial, spinal, and upper and lower body injuries that require urgent evaluation for potential emergency interventions^[4]. The range of associated injuries in the literature varied from 10% to 88%, according to the type of the facial fracture^[30].

In our study, abdominal surgical injuries were the most frequent concomitant injuries in the children. Most of these injuries that were found in 36 (15.5%) patients were in the form of intra-abdominal collections and only one patient underwent splenectomy indicating the high velocity injury that impacted that patient. The second common associated injury was orthopedic injury in 32 (13.8%) patients, then neurological injury in 23 (9.9%) patients, Cardiothoracic injury in 8 (3.4%) and finally four patients (1.7%) with ophthalmic injury in the form of ruptured globe.

Solitary soft tissue wounds as abrasions and lacerations without bone affection were observed in 23 (9.9%) patients, and 28 (12.1%) patients had combined soft tissue and bone injuries. Thus, soft tissue injury in pediatric trauma was present in 22% of the children and this is in line with other studies e.g.^[18] that reported soft tissue injury in 26% and^[27] that reported soft tissue injury in 10.57% of their

cases. All the patients were managed according to the international guidelines by suturing primarily under general or local anesthetization after cleansing the wound, tetanus immunization and excision of contused wound margins with administration of antibiotics.

Excluding isolated soft tissue injuries, 298 facial bone fractures were found in 209 patients (90.1%). Some patients were represented with more than one fracture.

In this research, mandibular fracture was the most frequent facial bone fracture; 152 (51.0%) patients. This comes in line with other public researches as^[27,14,18,6,34,8,35,36,37] and^[38]. Other types of fracture were 73 (24.5%) midfacial fractures, 45 (15.1%) fronto-orbital fractures, and the least common fractures were dento-alveolar fractures by only 28 (9.4%) fractures. However, other studies counted that the dentoalveolar fractures was the most frequent type of facial fractures as in^[3] and^[11].

The present research didn't conflict with these studies because dentoalveolar fractures are the simplest maxillofacial fractures and could be managed by Eric Arc bars and don't require management in an experienced tertiary center like our center. Moreover,^[21] reported that dentoalveolar fractures was present in 12.3% of Jordanian children and this percent is similar to ours.

We found that the parasymphysis was the most common location to be fractured in the mandible by 64 (42.1%) fractures out of the 152 mandibular fractures followed by the condyle that was reported in 36 fractures (23.7%), then the symphysis by 20 fractures (13.2%).

Many studies reported that the condylar area is the most frequent fractured region in the mandible as^[27], and^[3].

This variance can be attributed to the fact that accidental falls is the most common cause for the fracture in this research. When children fall, the parasymphyseal and symphyseal regions are the main regions to be injured. Then, the force is transmitted to the condyle. Because of the high condylar vascularization and the thin neck in children, they become poorly resistant to the impact.^[27]

The midface fractures constituted 73 (24.5%) while the fronto-orbital fractures were found in 45 fractures (15.1%) of the studied cases. This is also in line with the observations of other authors^[28] and^[39] who explained that the high elasticity of the mid-facial bones and their protected site between the protrusions

of the mandible and the cranium are the main causes of the low incidence of their fracture.

According to this study, the midface fractures were more common in the oldest children and the nasal fracture was the most frequent type by 35 fractures (47.9%), followed by ZMC by 22 fractures (30.1%), Le fort III by 8 (11%), Le fort I in 4 (5.5%), NOE by 4 (5.5%), and no cases with Le fort II fracture were recorded. In accordance with these findings, previous researchers⁽⁴⁰⁾ stated that the nasal fractures were the most frequent type in their study on patients of 5–17 years old. Another study had also stated the the low incidence of ZMC^[41]. This differs from the observation of^[42] who mentioned that amongst the midface fractures zygomatic complex fractures were reported to be most frequent. In pediatric population, zygomatic complex fractures are usually greenstick fractures of the lateral wall and floor of the orbit without displacement or functional defect. The rare occurrence of NOE fractures was also reported previously at an incidence of 1-8% of the children^[20].

Most of the fractures were not dangerous and were treated by conventional closed reduction like maxillomandibular fixation and follow up. Only severe displaced fractures were treated surgically.

Conservation was used for 84 (28.2%) fractures, followed by 74 (24.8%) fractures were managed by MMF alone, 62 (20.8%) fractures were managed by MMF with ORIF, 28 (9.4%) fractures were managed by only ORIF, and a titanium mesh was used in management of 10 (3.4%) fractures.

In this context, some authors preferred the conservative treatment in children as ORIFs have their negative influence on skeletal growth and unerupted teeth and another operation is required for removing the plates.^[43] Other authors preferred the open reduction to achieve a rapid management, prevent a period of MMF, and avoid any discrepancy or TMJ ankylosis.^[34]

Depending on the current results, the treatment of pediatric facial fractures could be defined according to the degree of the fracture displacement and the age of the child. The conservative treatment or closed technique methods provide good results when they are used for minimally displaced fractures. they are (conservation or closed technique) the treatment of choice, for many reasons:

- Children have a high ability for spontaneous readjustment by growth if the normal functions are preserved.

- The closed reduction is easy to perform and need no resources.

- Open reduction requires a well-qualified anesthetic team, and proper equipment.

The patients who were treated conservatively, were advised to avoid any facial trauma and to use liquid or puree diet. For the patients treated using closed techniques, the same techniques of the adults were used. 3–4 weeks of MMF were prescribed for them to prevent occlusal discrepancies. The current methods of management were efficient and matched with other international success rates.^[27,44]

ORIFs were carried out in 30.2% of the children. Most of them were older than 10 years of age, and suffered from highly displaced fractures. In these patients, the surgical intervention was mandatory to stabilize the concomitant fractures and allow rapid mobilization. (20.8%) of them were treated by combination with short period of MMF to stabilize the fracture in all sides and most of them had concomitant condylar fractures. In addition, physiotherapy was advised to be conducted as early as possible for condylar fractures to avoid TMJ ankylosis.

The treatment of nasal fractures was also similar to that in adults and aimed to restore the normal appearance. Displaced nasal fractures were reduced either immediately or few days after the edema resolve. To avoid further distortion with the child growth, closed reduction and external fixation were preferred.^[45] Out of the 35 nasal fractures, 16 fractures were managed by closed reduction and external fixation. The rest (19 fractures) were managed by conservation

This comes in agreement with^[46] who suggested that the early reduction of pediatric nasal bone fractures was associated with better satisfaction rates. They also suggested that closed reduction should be performed wherever possible and if open reduction is indicated, it should be as conservative as possible.

Small titanium plates were preferred for the fixation of facial fractures in children as they had better mechanical characteristics and small size. Despite difficult application, these plates can be totally removed if required, even after many years.^[47]

The titanium plates removal is advocated 6 months to 1 year after the repair specially if in the cranium or mandible.^[48]

In this research, titanium mini or micro plates were used with subsequent removal after the healing of the fractures. The fractures were exposed by careful dissection to avoid destroying the teeth buds or the neurovascular structures. Absorbable internal fixation may be more beneficial as it provides rapid mobilization without a second surgery for the removal of the plates^[49]. However, it wasn't used in this study due to their high costs.

Postoperative complications such as infection, osteomyelitis, nerve injuries, non-union, and malunion, or major occlusal discrepancies were not common in the current research as only 8 (3.4%) patients with postoperative infection and 4 (1.7%) patients with malocclusion that treated conservatively by persistence of MMF with elastics for another 2 weeks were reported. The high osteogenic potentials, the rapid healing process, and the early treatment are the possible causes to limit the complications in children. Additionally, a standard regimen of parenteral antibiotics from the time of admission till two 2 days after the surgery followed by oral antibiotics, for an additional 5 days was followed. Analgesic and anti-inflammatory medications were prescribed for all patients postoperatively. Mouthwash was added for mandibular fracture patients in addition to strict instructions about teeth cleaning. Furthermore, a long term follow-up was provided to these children.

However, restricted mouth opening (RMO) was the most frequent complication that was observed in the cases of fracture mandible. This is also in line with other studies that indicated that children are vulnerable to this problem. The mandible was hypomobile after the period of MMF, and the muscles became atrophic and "tight."^[50,51]

This RMO was overcome by prescribing physiotherapy after the release of MMF. Opening and excursive exercises were demonstrated to set typical and ideal inter incisal mouth opening that is typically 40 mm of maximum inter incisal mouth opening in adults. Physiotherapy was continued for 4 weeks postoperatively.

CONCLUSION

From the medico legal point of view, fall from height is the most frequent cause for maxillofacial fractures especially in younger pediatric age unlike adults where these fractures are more common and are caused mainly by assaults. Regarding the medical responsibilities, following the international guide lines to determinate the management protocol according to the age and the type of the fracture in children is mandatory to achieve the healing with avoiding serious complications on the growth and shape of the bone in the future as seen in the follow up of the patients.

ACKNOWLEDGEMENTS

Special thanks to residents, assistant lectures and all staff members in general surgery department and maxillofacial, head and neck surgery unit in Sohag university hospitals for their help and their support.

CONFLICT OF INTEREST

There are no conflicts of interest.

REFERENCES

1. Gassner R, Tuli T, Hächl O, Moreira R, Ulmer H. Craniomaxillofacial trauma in children: a review of 3,385 cases with 6,060 injuries in 10 years. *Journal of oral and maxillofacial surgery.* 2004;62(4):399-407.
2. Sethi RK, Kozin ED, Fagenholz PJ, Lee DJ, Shrimme MG, Gray ST. Epidemiological survey of head and neck injuries and trauma in the United States. *Otolaryngology--Head and Neck Surgery.* 2014;151(5):776-84.
3. Kumaraswamy S, Madan N, Keerthi R, Singh DS. Pediatric injuries in maxillofacial trauma: a 5 year study. *Journal of maxillofacial and oral surgery.* 2009;8(2):150-3.
4. Emshoff R, Schöning H, Röthler G, Waldhart E. Trends in the incidence and cause of sport-related mandibular fractures: a retrospective analysis. *Journal of oral and maxillofacial surgery.* 1997;55(6):585-92.
5. Wymann NME, Hölzle A, Zachariou Z, Iizuka T. Pediatric craniofacial trauma. *Journal of oral and maxillofacial surgery.* 2008;66(1):58-64.
6. Karim T, Khan AH, Ahmed SS. Trauma of facial skeleton in children: An indian perspective. *Indian Journal of Surgery.* 2010;72(3):232-5.
7. Kyrgidis A, Koloutsos G, Kommata A, Lazarides N, Antoniadis K. Incidence, aetiology, treatment outcome and complications of maxillofacial fractures. A retrospective study from Northern Greece. *Journal of Cranio-maxillo-facial Surgery.* 2013;41(7):637-43.
8. Zimmermann C, Troulis M, Kaban L. Pediatric facial fractures: recent advances in prevention, diagnosis and management. *International journal of oral and maxillofacial surgery.* 2005;34(8):823-33.
9. Kambalimath H, Agarwal S, Kambalimath DH, Singh M, Jain N, Michael P. Maxillofacial injuries in children: a 10 year retrospective study. *Journal of maxillofacial and oral surgery.* 2013;12(2):140-4.

10. Ghosh R, Gopalkrishnan K, Anand J. Pediatric facial fractures: a 10-year study. *Journal of maxillofacial and oral surgery*. 2018;17(2):158-63.
11. Haug RH, Foss J. Maxillofacial injuries in the pediatric patient. *Oral Surgery, Oral Medicine, Oral Pathology, Oral Radiology and Endodontics*. 2000;90(2):126-34.
12. Killey HC. *Fractures of the Mandible*: J. Wright; 1971.
13. Al Shetawi AH, Lim CA, Singh YK, Portnof JE, Blumberg SM. Pediatric Maxillofacial Trauma: A Review of 156 Patients. *Journal of oral and maxillofacial surgery : official journal of the American Association of Oral and Maxillofacial Surgeons*. 2016;74(7):1420 e1-4.
14. Boffano P, Rocchia F, Zavattero E, Dediol E, Uglešić V, Kovačić Ž, *et al*. European Maxillofacial Trauma (EURMAT) in children: a multicenter and prospective study. *Oral surgery, oral medicine, oral pathology and oral radiology*. 2015;119(5):499-504.
15. Aniruth S. Maxillofacial fractures in children attending the Red Cross War Memorial Children's Hospital: University of the Western Cape; 2005.
16. Oji C. Fractures of the facial skeleton in children: a survey of patients under the age of 11 years. *Journal of cranio-maxillo-facial surgery*. 1998;26(5):322-5.
17. Bhardwaj Y, Kumar D. Pediatric Maxillofacial Trauma Outcomes Based on a Survey of 65 Patients: A Prospective Study of Etiology, Incidence and Methods of Treatment. *Journal of maxillofacial and oral surgery*. 2015;14(3):687-92.
18. Arvind RJ, Narendar R, Kumar PD, Venkataraman S, Gokulanathan S. Maxillofacial trauma in Tamil Nadu children and adolescents: A retrospective study. *Journal of pharmacy & bioallied sciences*. 2013;5(Suppl 1):S33.
19. Baumann A, Troulis M, Kaban L. Facial trauma I: midfacial fractures. In: Kaban LB, Troulis MJ, editor *Pediatric Oral and Maxillofacial Surgery* Philadelphia, PA: Saunders. 2004:425-40.
20. Qudah MA, Bataineh AB. A retrospective study of selected oral and maxillofacial fractures in a group of Jordanian children. *Oral Surgery, Oral Medicine, Oral Pathology, Oral Radiology, and Endodontology*. 2002;94(3):310-4.
21. Anderson P. Fractures of the facial skeleton in children. *Injury*. 1995; 26(1):47-50.
22. Lida S, Matsuya T. Pediatric maxillofacial fractures: their etiological characteristics and fracture pattern. *Journal of cranio-maxillo-facial surgery: official publication of the European Association for Cranio-Maxillo-Facial Surgery*. 2002; 30(4):237-41.
23. Wang BS, Smith SL, Pereira KD. Pediatric head and neck trauma from all-terrain vehicle accidents. *Otolaryngology-Head and Neck Surgery*. 2007;137(2):201-5.
24. Jung T, De Silva H, Konthasingha P, Tong D. Trends in paediatric maxillofacial trauma presenting to Dunedin Hospital, 2006 to 2012. *New Zealand dental journal*. 2015;111(2).
25. O-Lee T, Koltai PJ. *Pediatric facial fractures. Pediatric Otolaryngology for the Clinician*: Springer; 2009. p. 91-5.
26. Khalifa GA, El-Kilani NS, Nasr TA. Clinical outcomes of Pediatric Maxillofacial Fractures Management in Three Hospital Series in Egypt. *Journal of Oral and Maxillofacial Surgery, Medicine, and Pathology*. 2017;29(6):511-7.
27. Kaban LB, Bouchard C, Troulis MJ. A protocol for management of temporomandibular joint ankylosis in children. *Journal of Oral and Maxillofacial Surgery*. 2009 Sep 1;67(9):1966-78.
28. Almahdi HM, Higzi MA. Maxillofacial fractures among Sudanese children at Khartoum Dental Teaching Hospital. *BMC research notes*. 2016;9(1):120.
29. Munante-Cárdenas JL, Olate S, Asprino L, de Albergaria Barbosa JR, de Moraes M, Moreira RW. Pattern and treatment of facial trauma in pediatric and adolescent patients. *Journal of Craniofacial Surgery*. 2011;22(4):1251-5.
30. Eggensperger Wymann NM, Hölzle A, Zachariou Z, Iizuka T. Pediatric Craniofacial Trauma. *Journal of Oral and Maxillofacial Surgery*. 2008;66(1):58-64.
31. Morales JL, Skowronski PP, Thaller SR. Management of pediatric maxillary fractures. *Journal of Craniofacial Surgery*. 2010;21(4):1226-33.
32. Ryan ML, Thorson CM, Otero CA, Ogilvie MP, Cheung MC, Saigal GM, *et al*. Pediatric facial trauma: a review of guidelines for assessment, evaluation, and management in the emergency department. *Journal of Craniofacial Surgery*. 2011;22(4):1183-9.

33. Hatf DA, Cole PD, Hollier Jr LH. Contemporary management of pediatric facial trauma. Current opinion in otolaryngology & head and neck surgery. 2009;17(4):308-14.
34. Iatrou I, Theologie-Lygidakis N, Tzerbos F. Surgical protocols and outcome for the treatment of maxillofacial fractures in children: 9 years' experience. Journal of Cranio-Maxillofacial Surgery. 2010;38(7):511-6.
35. Ferreira PC, Amarante JM, Silva PN, Rodrigues JM, Choupina MP, Silva AC, *et al.* Retrospective study of 1251 maxillofacial fractures in children and adolescents. Plastic and reconstructive surgery. 2005;115(6):1500-8.
36. Iida S, Matsuya T. Paediatric maxillofacial fractures: Their aetiological characters and fracture patterns. Journal of craniomaxillofacial surgery. 2002;30(4):237-41.
37. Thorén H, Hallikainen D, Iizuka T, Lindqvist C. Condylar process fractures in children: a follow-up study of fractures with total dislocation of the condyle from the glenoid fossa. Journal of oral and maxillofacial surgery. 2001;59(7):768-73.
38. Zachariades N, Papavassiliou D, Koumoura F. Fractures of the facial skeleton in children. Journal of Cranio-Maxillo-Facial Surgery. 1990;18(4):151-3.
39. Kumar GA, Dhupar V, Akkara F, Kumar SP. Patterns of maxillofacial fractures in Goa. Journal of maxillofacial and oral surgery. 2015;14(2):138-41.
40. Cavalcanti AL, Melo T. Facial and oral injuries in Brazilian children aged 5–17 years: 5-year review. European Archives of Paediatric Dentistry. 2008;9(2):102-4.
41. Albeshir H, Ahmed SW, Awaji M, Albalawi S, Samman M, Alahmadi H. Pediatric maxillofacial injuries in madinah-a retrospective study. Journal of Public Health Policy and Planning. 2018;2(2):73-80.
42. Adams CD, Januszkiewicz JS, Judson J. Changing patterns of severe craniomaxillofacial trauma in Auckland over eight years. Australian and New Zealand Journal of Surgery. 2000;70(6):401-4.
43. Meier JD, Tollefson TT. Pediatric facial trauma. Current opinion in otolaryngology & head and neck surgery. 2008;16(6):555-61.
44. Owusu JA, Bellile E, Moyer JS, Sidman JD. Patterns of pediatric mandible fractures in the United States. JAMA facial plastic surgery. 2016;18(1):37-41.
45. Braun TL, Xue AS, Maricevich RS, editors. Facial Trauma: Differences in the Management of Pediatric Facial Trauma. Seminars in plastic surgery; 2017: Thieme Medical Publishers.
46. Yilmaz MS, Guven M, Kayabasoglu G, Varli AF. Efficacy of closed reduction for nasal fractures in children. British Journal of Oral and Maxillofacial Surgery. 2013;51(8):e256-e8.
47. Bos RR. Treatment of pediatric facial fractures: the case for metallic fixation. Journal of oral and maxillofacial surgery. 2005;63(3):382-4.
48. Kellman RM, Tatum SA. Pediatric craniomaxillofacial trauma. Facial Plastic Surgery Clinics. 2014; 22(4): 559-72.
49. Hoffmeister B. Pediatric maxillofacial trauma. Maxillofacial Surgery (Third Edition): Elsevier; 2017. p. 193-9.
50. Niezen E, Stuive I, Post W, Bos R, Dijkstra P. Recovery of mouth-opening after closed treatment of a fracture of the mandibular condyle: a longitudinal study. British Journal of Oral and Maxillofacial Surgery. 2015;53(2):170-5.
51. Duan D, Zhang Y. A clinical investigation on disc displacement in sagittal fracture of the mandibular condyle and its association with TMJ ankylosis development. International journal of oral and maxillofacial surgery. 2011;40(2):134-8.
52. Cornelius CP, Audigé L, Kunz C, Buitrago-Téllez CH, Rudderman R, Prein J. The comprehensive AOCMF classification system: midface fractures-level 3 tutorial. Craniomaxillofacial trauma & reconstruction. 2014 Dec;7(1_suppl):68-91.
53. Merville, L.C., Derome, P. and de Saint Jorre, G., 1983. Fronto-orbito-nasal dislocations: Secondary treatment of sequelae. Journal of maxillofacial surgery, 11, pp.71-82.
54. Natu, S.S., Pradhan, H., Gupta, H., Alam, S., Gupta, S., Pradhan, R., Mohammad, S., Kohli, M., Sinha, V.P., Shankar, R. and Agarwal, A., 2012. An epidemiological study on pattern and incidence of mandibular fractures. Plastic surgery international, 2012.