

Spheno-Orbital En plaque Meningioma; Surgical strategy and Proptosis result

Mostafa M. Aboelkhir ¹MD ; Mohammad A. Albialy ¹MD ; Mansor ALi Hendawey ¹MD .

*Corresponding Author:

Mostafa M. Aboelkhir

mostafaaboeikhir81@gmail.com

Received for publication December 06, 2022; Accepted December 31, 2022; Published online December 31, 2022.

doi: 10.21608/aimj.2022.179118.2354

Citation: Mostafa M. Mohammad A. and Mansor A. . Spheno-Orbital En plaque Meningioma; Surgical strategy and Proptosis result. AIMJ. 2022; Vol.3-Issue12 : 1-6.

¹Neurosurgery Department, Faculty of Medicine, Al-Azhar University, Cairo , Egypt.

ABSTRACT

Background: Spheno-orbital en plaque meningioma (SOEMs) are complex lesions that primarily originate in the sphenoid wing with extensive hyperostosis and may involve the orbit and cavernous sinus, making a gross total resection difficult and posing a high risk of postsurgical morbidity and recurrence.

Aim of the work: To assess outcome and CSF leakage incidence according to type of dural graft in CM-I patients.

Patients and methods: a series of 13 consecutive patients with SOEM presented by proptosis and hyperostosis who underwent surgical excision by frontotemporal craniotomy, clinical, radiological, surgical technique and follow up was reviewed and analyzed.

Results: In this series of 13 consecutive patients, 11 were women and 2 were men. The age range was from 35-63 years with a mean of 46.3 years. Tumors were located on the right side in 9 patients (69%) and the left side in 4 patients (31%). Cavernous sinus (CS) and superior orbital fissure (SOF) invasion in 4 cases (31%). Gross total excision grades I and II were obtained in 6 cases (46%), near total excision grades III in 3 cases (23%), and partial excision grade IV in 4 cases (31%). 11 cases (85%) show improvement of proptosis (7 patients, 54% have a complete resolution of proptosis and 4 cases, 31% have partial resolution of proptosis) and 2 cases show no improvement of proptosis after a long follow-up period.

Conclusion: The decision for each case of Spheno-orbital en plaque meningioma should be individualized depending on the extension of the lesion to the surrounding structures. Extension to the CS and SOF should be considered the surgical limit for excision. Early presentation and surgery enable gross total resection, rapid improvement, and more stable follow-up.

Keywords: meningioma; en plaque; cavernous sinus; superior orbital fissure; proptosis and hyperostosis.

Disclosure: The author has no financial interest to declare in relation to the content of this article. The Article Processing Charge was paid for by the author.

Authorship: The author has a substantial contribution to the article.

Copyright The Author published by Al-Azhar University, Faculty of Medicine, Cairo, Egypt. Users have the right to read, download, copy, distribute, print, search, or link to the full texts of articles under the following conditions: Creative Commons Attribution-Share Alike 4.0 International Public License (CC BY-SA 4.0).

INTRODUCTION

Spheno-orbital en plaque meningiomas (SOEMs) are a type of sphenoid wing meningioma distinguished by extensive hyperostosis along the sphenoid wing extending to the orbit (also known as intraosseous meningiomas) and a small sheet-like soft dural mass typically located at the anterior concavity of the middle cranial fossa.^{1,2}

This lesion may extend to the CS, SOF, skull base foramina, and pterygoid plate, giving its complex nature, challenges, and difficulty in achieving a complete resection, demonstrating a high recurrence rate of between 35 and 50%.^{3, 4,5} Just 2-9% of meningiomas are SOEMs that have extended into orbit⁵.

Proptosis and visual impairment are the main presenting symptoms. Several methods were reported for the surgical resection of SOEMs (6). However, the main objectives of these procedures ought to be to improve proptosis and visual symptoms.^{7,8}

This series has reviewed our experience dealing with these complex lesions as regards clinical aspects, surgical techniques, and follow-up.

PATIENTS AND METHODS

This series conducted on 13 consecutive patients with SOEM who underwent surgical procedures for excision at Al-Azhar university hospitals from the period between 2018 to 2021. Patients were selected on clinical and radiological basis as follow.

Inclusion criteria: On MRI, all patients should have proptosis and hyperostosis at the base of the anterior and middle cranial fossas, including the sphenoid wing and the orbit, and a carpet-like soft tissue (figure 1) component at the sphenoid wing (which may be a thin sheet not clearly identified and appears just as a dural thickening and enhancement).

Exclusion criteria: This study excluded absence of proptosis, patients with primary optic nerve sheath meningiomas, clinoidal meningiomas, non-hyperostotic or en-mass sphenoid wing meningioma, and cavernous sinus meningiomas with secondary orbital involvement.

All patients were subjected to full clinical evaluation with stress on proptosis (unilateral, non-pulsatile, and non-reducible), vision, and ocular motility.

Preoperative imaging in the form of MRI with contrast to evaluate the soft tissue component and its extension to the CS and SOF was done. A CT scan of the orbit and skull base is performed to evaluate the degree of hyperostosis, orbital wall involvement, and infra-temporal area.

As regards the surgical technique, each patient had frontotemporal craniotomy with extradural drilling of the sphenoid ridge, the orbital roof, and lateral orbital wall, including de-roofing of the lateral part of SOF (figure 2). All of the hyperostotic bone was removed using a high-speed drill and bone ronguers (extensive deroofing of SOF was done in one case, which was associated with 3rd nerve palsy). Drilling of all hyperostotic bones was hindered by hyperostosis extending into the infratemporal fossa.

For all patients, after opening of the dura, the soft compartment following the sphenoid ridge and the concavity of the greater wing were removed with its dural attachment after good exploration of the optic nerve and carotid artery (figure 2). In some cases, the

intraorbital soft tissue component was removed (2 cases of recurrence).

In cases where the CS and SOF were invaded, the extent of resection was stopped at this level and the decision was made to follow up these patients. Using the Simpson Grading System, the grade of the tumor excision was assessed. The dura was replaced by either an artificial graft or a natural graft (facia lata or pericranial graft). Reconstruction of the drilled temporal and orbital bones was not performed routinely, except for some cases with extensive drilling by titanium mesh (figure 2).

Uneventful recovery for all patients with immediate clinical assessment and postoperative CT scan was done for all cases, histopathology for all patient was reviewed. Late clinical and radiological follow up was done for all patient at variable periods ranging from 6months to 2years

Patients' clinical data, investigations, surgical techniques, and data on clinical and radiological follow-up have been collected, evaluated, and analyzed.

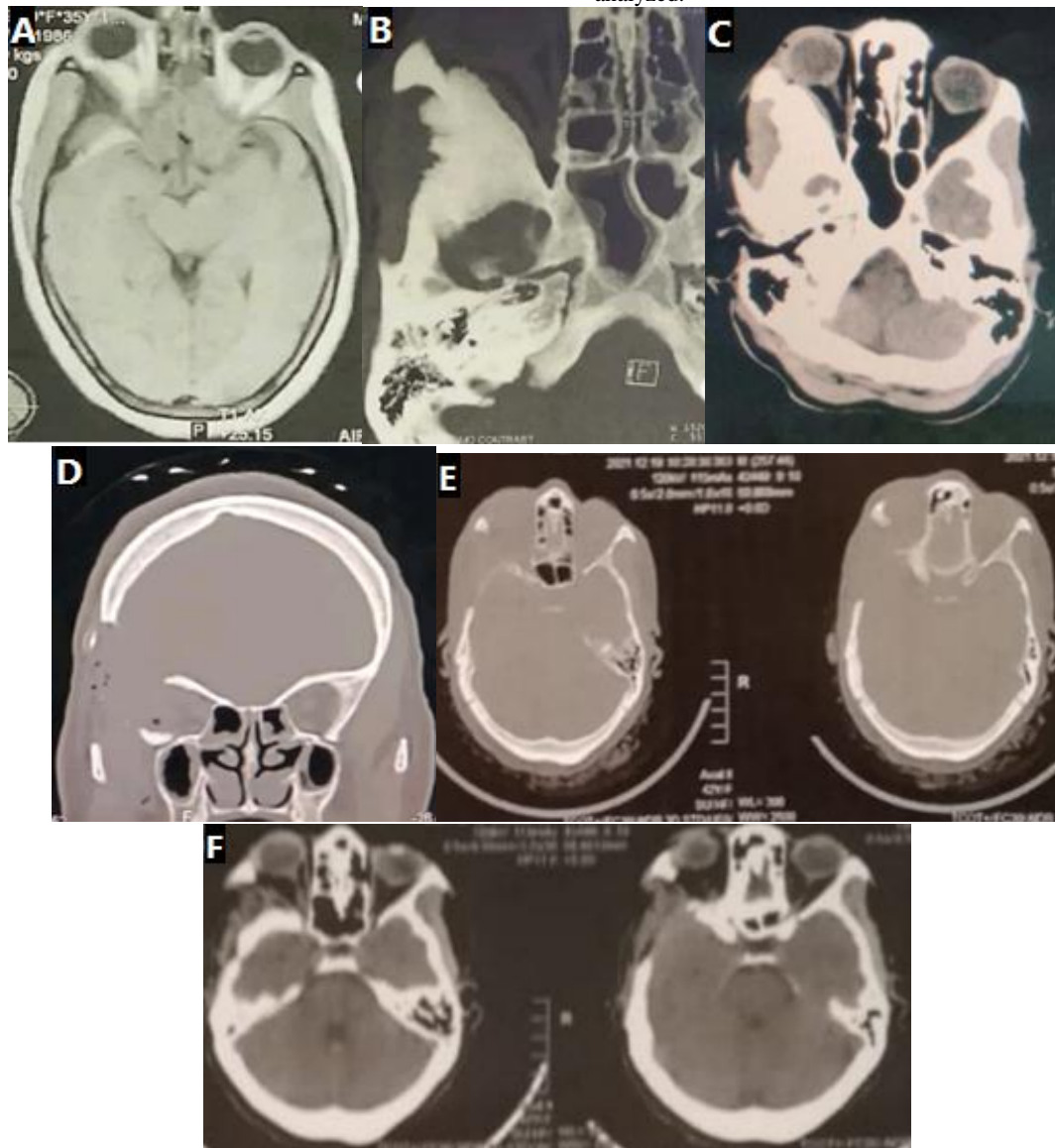


Fig. 1: preoperative and postoperative images of a 45-year-old female patient presented with proptosis and headache, subjected to excision through a right frontotemporal craniotomy with good results and improvement of proptosis. A: MRI T1 contrast showing proptosis and thin enhancing sheet of tumor

along the concavity of greater wing of sphenoid. B, C: CT brain bone and brain window showing proptosis and hyperostosis of sphenoid wing. D, E, F: CT brain coronal axial and brain window showing the extent of resection with improvement of proptosis.

RESULTS

Thirteen patients with SOEMs underwent surgical excisions were studied: 11 were female and 2 were male (ratio 5.5:1), age range from 35 to 63 years (mean age:46.3 years). proptosis was the main presenting symptoms present in 100% of cases, other symptoms including visual diminution in 4 cases (31%), limitation of ocular motility and diplopia in 5 cases (38%), headache in 9 cases (69%) and temporal fossa swelling 4 cases (31%). The duration of symptoms varied from 5 to 30 months, with a mean of 12.5 months (the longer the duration, the worse the visual symptoms).

Most of tumor located at right side (9 cases 69%), 4 (31%) on left side. enhancing soft tissue mass was clearly observed radiologically in 9 cases (69%), cavernous sinus and SOF invasion in 4 cases (31%).

The extent of resection was assessed using the Simpson grading system as follows; gross total excision grades I and II were performed in 6 cases (46%), near total excision grade III was performed in 3 cases (23%), and partial excision grade IV was performed in 4 cases (31%). Dural substitution was done in all cases, and frontotemporal and orbital reconstruction (figure2) were done in 4 cases by titanium mesh plate. According to the World Health Organization, the histopathology of all cases was grade I meningiomas.

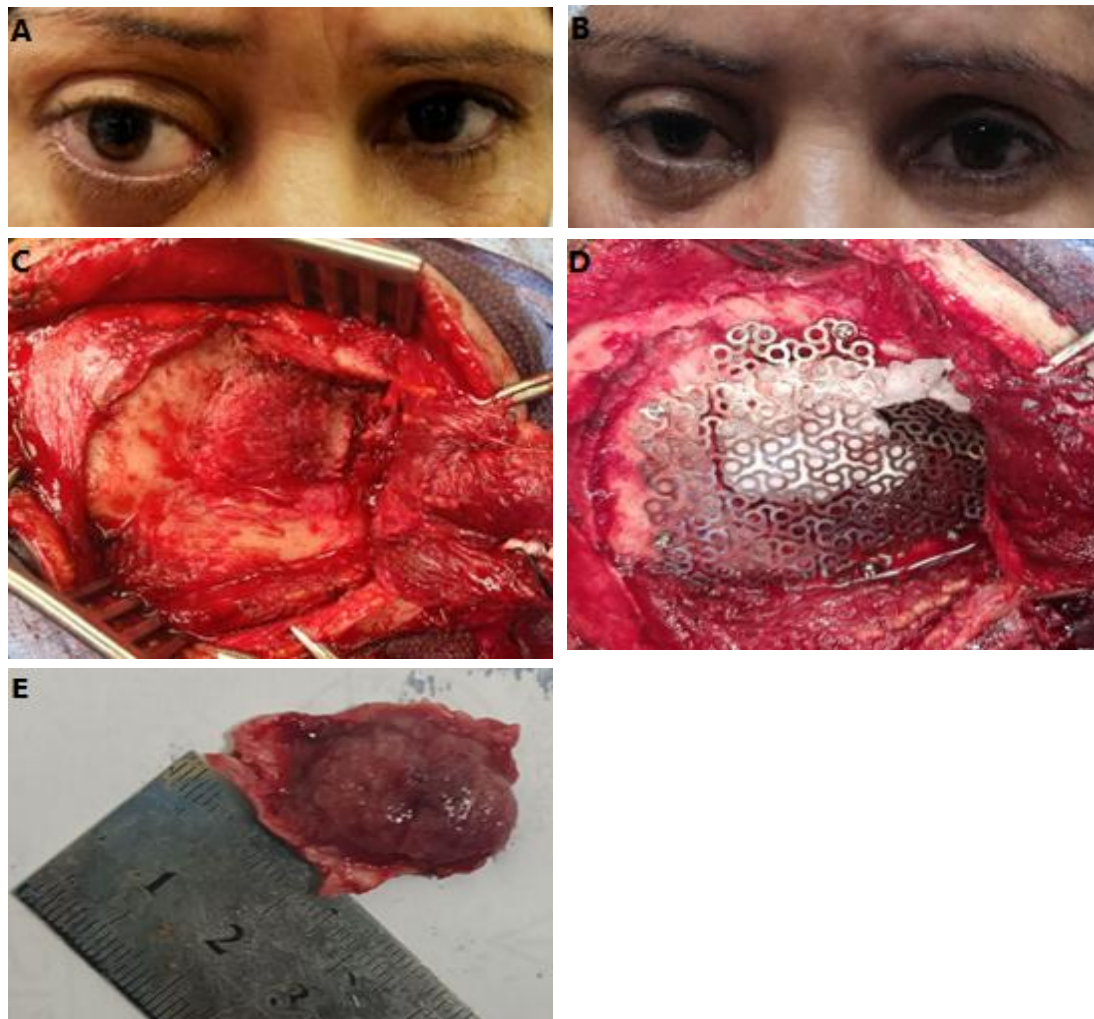


Fig. 2: A female patient, 43 years old with proptosis and headache, is subjected to removal through right frontotemporal craniotomy and reconstruction with a titanium mesh plate with good results. A, B: photos of the patient pre and postoperatively, respectively, revealing the right eye's proptosis with improvement of proptosis. C, D, E: intraoperative photos showing the tumor filling the temporal fossa, reconstruction after removal, and the size of the intradural component.

Two cases developed subgaleal CSF collections, which were managed conservatively and improved. One patient developed 3rd nerve palsy and partially improved during follow up. This occurred in a case with extensive drilling of SOF, which may be owing to the drilling process's thermal and mechanical effects. No mortality happened in this series.

Ocular motility and diplopia significantly improved postoperatively which could be occurred by a mechanical compression rather than nerve palsies.

The duration of follow-up ranged from 9 to 33 months (mean 20.6 months). 11 cases (84.6%) show improvement of proptosis (8 patients (61.5%) have a complete resolution of proptosis and 3 cases (23.1%) have partial resolution) with patient cosmetic satisfaction, and 2 (15.4) cases show no improvement after a long follow-up period with long-standing proptosis preoperative (one of them was recurrent with a long history before the first surgery). No cases developed enophthalmos during a follow-up period.

4 patients with CS and SOF involvement subjected to partial excision 2 of them show a tumor recurrence in follow up period, reoperated again with maximizing the extent of bony resection and removal of intraorbital soft tissue component, with more or less stable follow up.

DISCUSSION

SOEMs are a particular type of meningioma and defined as sheet or nodular-shaped tumors that produce adjacent large hyperostosis⁹ Cushing and Eisenhardt were the first to use the term, distinguishing it from en-mass¹⁰. Such tumors are mostly considered bone diseases since their presentation and diagnosis are primarily affected by the extent of bone invasion, with intradural involvement having a limited effect.⁹

Pathology demonstrates meningiomatous cells invade the haversian canals, not only a bony reaction, hence hyperostotic bone must be considered part of the neoplastic processes.^{9,11}

Patients are mostly affected in their 4th or 5th decade of life, and women are 3 to 6 times more likely than men to be affected^{1,5}. In this series, the main age (46.3) ranged from 35 to 63 years, and 11 cases were female and 2 were male (ratio 5.5:1).

Instead of using their histological morphology, radiographic appearance is used to diagnose SOEMs, which is based on their growth pattern^{12,13}. Because

of the risk of visual function loss, gross total resection is all but impossible when SOEMs extend into the cavernous sinus and engage the ocular muscles. Subtotal resection followed by postsurgical radiotherapy was advised by some authors.⁹

The extent of resection of SOEMs was variable between different series. Schick, Mirone, and colleagues, achieved a high gross total resection of 60- 82% respectively^{1,5}. In a series reported by Jaaskelainen and colleagues, 15% of cases with orbital extension and 50% of those with hyperostosis had gross total resection.¹⁴

According to Some authors, the goal of surgery was to relieve symptoms rather than to completely remove the tumor. In 24% of their cases, Ringel and colleagues achieved gross total resection, and in 60% of cases with sub-total resection, which showed a stationary course^{15,24}. It is not advisable to achieve radical tumor excision at the cost of a higher rate of morbidity. Resection, on the other hand, ought to be as complete as possible to prevent the future recurrence risk.⁹

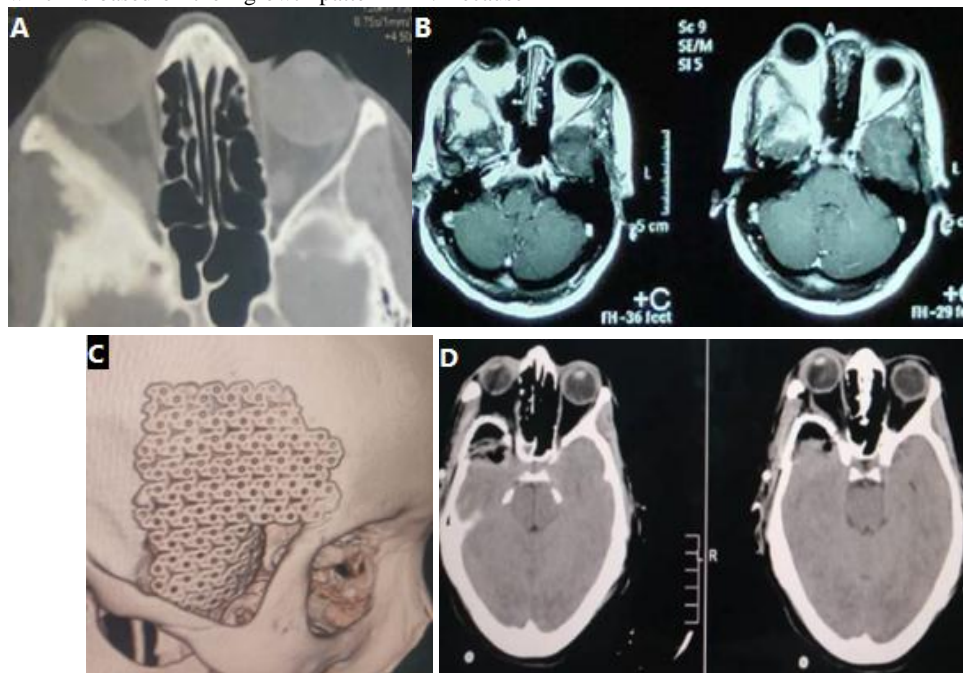


Fig. 3: radiology of patient in figure 2. A, B: CT skull bine window and MRI brain showing proptosis and hyperostosis. C, D: post-operative CT skull 3D and brin denoting the pattern of mesh reconstruction and proptosis improvement.

In this series, we achieved gross total excision grades I and II in 6 patients (46%), near total grades III in 3 cases (23%), and partial excision grades IV in 4 cases (31%). The cavernous sinus soft tissue extension, SOF, and infratemporal extension of the hyperostotic bone were the major factors limiting extensive total resection.

It seems that drilling the orbital roof wall just beyond the orbital rim and the lateral orbital wall will be sufficient to adequately decompress the periorbital and enable removal of the intraorbital soft tissue extension that is lateral and superior to the globe without having to remove the orbital rim.^{1,5,13}

In our series, we have adequate decompression of the globe without having to remove the orbital rim that has been lifted for adequate support of the globe and periorbital.

There is no consensus about the reconstruction of the removed bone. Some researchers recommend orbital wall reconstruction and frontotemporal craniotomy because cosmetic defects, enophthalmos, and transmitted pulsation to the globe may occur as a result of the extensive removal of affected bone and dura mater during treatment.^{5,9,16}

However, some authors reported examples of orbital wall and roof excision without reconstructing, and no complications occurred. Others think that reconstruction is unnecessary as long as the orbital margins and orbital floor are intact.^{1,13,17}

In this series, reconstruction was not routinely performed, except for 4 cases where reconstruction was done by titanium mesh plate. No cases developed enophthalmos or orbital pulsation.

Many postsurgical complications have been reported following SOEM resection, involving visual deterioration, ophthalmoplegia, facial numbness, hemiplegia, hematomas, CSF leak, collection, and harm to the trigeminal nerve.^{5,13,18,19}

The mortality reported after resection of SOEMs was around 6% in some series. A vascular insult is the primary factor in mortality that has been documented in the literature.^{13,14}

In this series, 2 cases developed subgaleal CSF collections which were managed conservatively and improved, other patient developed 3rd nerve palsy, which partially improved during follow up (a case with extensive drilling of SOF). In general 3rd nerve palsy might be caused by the thermal and mechanical effects of the hyperostotic bone drilling process, may be vascular injury of perforators that feed the third nerve, or surgical manipulation of the

tumor's cavernous sinus part. No mortality happened in this series.

Many series reported a good improvement of proptosis postoperative ranging from 73.5% in a series, 84% and 87% in other^{5,12,25}. Jesus and Toledo reported proptosis improvement in 100% of their patients (4). In this series proptosis improved in (84.6%) 11 cases (8 patients (61.5%) have a complete resolution of proptosis and 3 cases (23.1%) have partial resolution) with patient cosmetic satisfaction and 2 (15.4%) cases shows no improvement after a long follow up period with long standing proptosis preoperative (one of them was recurrent with long history before the first surgery), and may be explained by laxity and elongation of ligament, capsule and muscles from prolonged proptosis preoperative.

The role of irradiation for hyperostotic meningioma en plaque and skull base lesions, remain debatable. Some authors recommend postoperative radiation for incompletely resected or WHO grade II and III to control the recurrence rate^{9,20,21}. In this series all cases were WHO grade I lesions and no cases referred to radiation.

According to some studies, it is unlikely for visual acuity to recover after decompression when it is severely impaired preoperatively (5,22). In the **Simas et al.** series, the only two patients who underwent decompression of the optic canal exhibited a permanent postsurgical morbidity⁹, which may be due to excess mechanical and thermal effects from the drilled thickened bone. As a result of the risk of worsening visual function, the researchers suggest that the indication for optic canal decompression ought to be cautious and judicious^{5,9,22}.

All-over recurrence rates in some series have reached 35-50%^{5,23} and seem to be due to complex anatomy leading to incompletely removed tumors. However, some authors reported more or less stationary courses after subtotal resection^{16,24}. In a more recent series, recurrence rates were fewer than 10% with more aggressive and earlier surgical resection and seemed to be inversely related to the surgical extent of resection.^{1,3,11} However, the variable natural history of these tumors and slow growth makes it hard to estimate the true rate of recurrence^{5,9}.

In this series, we have 2 recurrent cases subjected to first partial resection. They underwent second surgery and we have tried to maximize the resection as much as possible with the removal of the intraorbital soft tissue component, which shows a more or less stationary course, but long-term follow-up for these cases was needed.

CONCLUSION

SOEMs are unique pathologies characterized by excessive bone hyperostosis and a small sheet-like dural soft tissue mass. The decision for each case should be individualized depending on the extension of the lesion to the surrounding structure. Extension

to the CS and SOF should be considered as the surgical limit for excision. Early presentation and surgery enable gross total resection, rapid improvement, and more stable follow-up. Long-standing proptosis before surgery may be related to less improvement in proptosis.

Conflict of interest : none

REFERENCES

- Schick U, Bleyen J, Bani A, Hassler W. Management of meningiomas *en plaque* of the sphenoid wing. *J Neurosurg.* 2006; 104:208-14.
- Al-Mefty O, Abdulrauf SI, Haddad GF. Meningiomas. In: Winn HR, editor. *Youmans & Winn Neurological Surgery.* 6th ed. Philadelphia: Saunders. 2011; p. 1426-49.
- Shrivastava RK, Sen C, Costantino PD, Della Rocca R. Sphenoorbital meningiomas: surgical limitations and lessons learned in their long-term management. *J Neurosurg.* 2005; 103:491-6.
- Jesus O, Toledo MM. Surgical management of meningioma *en plaque* of the sphenoid ridge. *Surg Neurol.* 2001; 55:265-9.
- Mirone G, Chibbaro S, Schiabello L, Tola S, George B. *En Plaque* sphenoid wing meningiomas: recurrence factors and surgical strategy in a series of 71 patients. *Neurosurgery.* 2009; 65(Suppl 6):100-8.
- Day JD. Cranial base surgical techniques for large sphenocavernous meningiomas: technical note. *Neurosurgery.* 2000; 46(3):754-9.
- Talacchi A, DeCarlo A, D'Agostino A, Nocini P. Surgical management of ocular symptoms in sphenoorbital meningiomas. Is Orbital reconstruction really necessary? *Neurosurg Rev.* 2014; 37:301-10.
- Scarone P, Leclercq D, Héran F, Robert G. Long-term results with exophthalmos in a surgical series of 30 sphenoorbital meningiomas. *J Neurosurg.* 2009; 111:1069-77.
- Simas NM, Farias JP. Sphenoid wing *en plaque* meningiomas: Surgical results and recurrence rates. *Surg Neurol Int.* 2013; 4:86.
- Cushing H, Eisenhardt L. *The Meningiomas: Their Classification, Regional Behavior, Life History, and Surgical End Results.* Springfield: Charles C. Thomas. 1938; 248:59.
- Bikmaz K, Mrak R, Al-Mefty O. Management of bone-invasive, hyperostotic sphenoid wing meningiomas. *J Neurosurg* 2007; 107:905-12.
- Honeybul S, Neil-Dwyer G, Lang DA, Evans BT, Ellison DW. Sphenoid wing meningioma *en plaque*: a clinical review. *Acta Neurochir (Wien).* 2001;143: 749-58.
- Elborady, M.A., Nazim, W.M. Spheno-orbital meningiomas: surgical techniques and results. *Egypt J Neurol Psychiatry Neurosurg.* 2021; **57**: 18. <https://doi.org/10.1186/s41983-021-00276-6>
- Jaaskelainen J, Ohman J, Kotilainen P, Munyao N, Randell T, Hernesniemi J. Sphenoidal wing meningioma- outer and middle. In: Kaye AH, PMcl B, editors. *Operative Neurosurgery.* London: Churchill Livingstone. 2000. p. 587-604.
- Ringel F, Cedzich C, Schramm J. Microsurgical technique and result of a series of 63 sphenoorbital meningiomas. *Neurosurgery.* 2007; 60(Suppl 2): 214-22.
- Leake D, Gunnlaugsson C, Urban J, Marentette L. Reconstruction after resection of sphenoid wing meningiomas. *Arch Facial Plast Surg.* 2005; 7(2): 99-103.
- DeMonte F, Tabrizi P, Culpepper SA, Suki D, Soparkar CN, Patrinely JR: Ophthalmological outcome after orbital entry during anterior and anterolateral skull base surgery. *J Neurosurg.* 2002; 97:851-6,.
- Pamir MN, Belirgen M, Ozduman K, Kiliç T, Ozek M. Anterior clinoidal meningiomas: analysis of 43 consecutive surgically treated cases. *Acta Neurochir (Wien).* 2008; 150(7):625-36.
- Chaichana KL, Jackson C, Patel A, Miller NR, Subramanian P, Lim M, et al. Predictors of visual outcome following surgical resection of medial sphenoid wing meningiomas. *J Neurol Surg B.* 2012; 73:321-32.
- Iwai Y, Yamanaka K, Ikeda H. Gamma knife radiosurgery for skull base meningioma: long- term results of low-dose treatment. *J Neurosurg.* 2008; 109:804-10.
- Gorman L, Ruben J, Myers R, Dally M. Role of hypofractionated stereotactic radiotherapy in treatment of skull base meningiomas. *J Clin Neurosci.* 2008; 15:856-62.
- Li Y, Shi JT, An YZ, Zhang TM, Fu JD, Zhang JL, et al. Sphenoid wing meningioma *en plaque*: Report of 37 cases. *Chin Med J (Engl).* 2009; 122:2423-7.
- Maroon JC, Kennerdell JS, Vidovich DV, Abla A, Sternau L: Recurrent sphenoorbital meningioma. *J Neurosurg.* 1994; 80:202-8.
- Terrier LM, Bernard F, Fournier HD, Morandi X, Velut S, Hénaux PL, et al. Spheno-orbital meningiomas surgery: multicenter management study for complex extensive tumors. *World Neurosurg.* 2018; 112: e145-e156.
- Oya S, Sade B, Lee JH. Sphenoorbital meningioma: surgical technique and outcome. *J Neurosurg.* 2010; 114:1241-9