

## The Surgical Outcome of Chronic Rhinosinusitis with Emphasis on Rhinogenic Headache

Mohamed Khalil Eloby<sup>1,\*</sup> M.B.B.Ch, Salaheddin Saeed Ali<sup>1</sup> MD. and Mohamed Kamel Alawady<sup>1</sup> MD.

*\* Corresponding Author:*

Mohamed Khalil Eloby  
[alaaeloby@gmail.com](mailto:alaaeloby@gmail.com)

Received for publication June 09, 2022; Accepted December 31, 2022; Published online December 31, 2022.

**Citation:** Mohamed K., Salaheddin S, and Mohamed K. The Surgical Outcome of Chronic Rhinosinusitis with Emphasis on Rhinogenic Headache. AIMJ. 2022; Vol.3-Issue 12 : 66-73.

**doi:** 10.21608/aimj.2022.130707.1976

<sup>1</sup>Department of Otorhinolaryngology, Faculty of Medicine, Al-Azhar University, Cairo, Egypt.

### ABSTRACT

**Background:** Chronic rhinosinusitis (CRS) is a chronic inflammatory condition that affects the nose and sinuses. CRS is caused by a number of variables, including genetics, the state of the sinonasal microbiome, infections, and environmental factors.

**Aim of the study:** To keep track of the results. of sinus surgery and to evaluate headache severity, duration, and frequency.

**Patients and Methods:** A prospective study was conducted at Al-Azhar University Hospitals. We targeted 60 Patients of both sexes between the ages of 18 and 65. Three groups were formed : Group (1): Chronic Rhinosinusitis with or without concha bullosa, Group (2): Chronic Rhinosinusitis with or without hypertrophy turbinate, and Group (3): Chronic Rhinosinusitis with or without deviated septum.

**Result:** A total of 60 patients, significant difference found regarding nasal obstruction between the groups. Based on Visual Analogue Scale (VAS), the intensity of pain in the group1revealed a highreduction from  $6.25 \pm 1.87$  (Preoperative) to  $2.88 \pm 1.01$  (3 months aftertreatment) and  $1.54 \pm 1.21$  (6 months following therapy ent). In group 2 the intensity of pain revealed a high reduction from  $5.87 \pm 0.911$  (Preoperative) to  $3.01 \pm 1.39$  (3 months following therapy) and  $1.33 \pm 0.935$  (6 months following therapy). In group 3 The level of discomfort was shown to be significantly reduced from  $6.48 \pm 1.72$  (Preoperative) to  $2.51 \pm 0.993$  (3 months after treatment) and  $1.59 \pm 1.13$  (6 months after treatment).

**Conclusion:** The surgical removal of contact points in the nasal cavity can help with headache relief. The severity, duration, and frequency of contact point headaches are the highest. Chronic rhinosinusitis, rhinogenic headache, and sinus surgery are all terms used to describe chronic rhinosinusitis.

**Keywords:** Chronic Rhinosinusitis; Rhinogenic Headache; Sinus surgery.

**Disclosure:** The authors have no financial interest to declare in relation to the content of this article. The Article Processing Charge was paid for by the authors.

**Authorship:** All authors have a substantial contribution to the article.

**Copyright** The Authors published by Al-Azhar University, Faculty of Medicine, Cairo, Egypt. Users have the right to read, download, copy, distribute, print, search, or link to the full texts of articles under the following conditions: Creative Commons Attribution-Share Alike 4.0 International Public License (CC BY-SA 4.0).

### INTRODUCTION

Chronic rhinosinusitis (CRS) is a long-term inflammatory condition that affects millions of people around the world. CRS is caused by a number of variables, including genetics, the state of the sinonasal microbiome, infections, and environmental factors. Asthma, allergic rhinitis, bronchiectasis, and some types of immunodeficiency are all comorbidities of CRS. Based on endotypes and phenotypes, CRS can be split into subtypes. Infectious CRS is an example of this. Infectious CRS is usually caused by a chronic bacterial infection, which usually starts with a viral upper respiratory tract infection. Difficult-to-treat or recurring CRS can be caused by antibody deficiency in the gut. Antibiotics, topical or oral corticosteroids, and nasal

saline irrigations can all be used to treat infectious CRS.<sup>1,2</sup>

Surgery is normally reserved for individuals who have failed to respond to medicinal treatment. CRS is a clinical syndrome characterised by rhinologic symptoms as well as indications of sinus inflammation on nasal endoscopy, computed tomographic (CT) imaging, or both. Although the basic phenotypic diagnostic criteria have been established, the specific diagnostic criteria and treatment approach are still evolving as our knowledge of CRS grows.<sup>3,4</sup>

Patients with face pain can be difficult to diagnose. The frequency of referred pain and overlap in symptoms between different illnesses provide

therapeutic challenges; painful stimuli affecting face structures are largely transferred by afferents in the trigeminal nerve to the spinal tract in the brain stem. The lateral wall of the nose is the most sensitive part, and when it is activated by an impacted nasal septum, it can result in referred trigeminal discomfort and persistent headache.<sup>5</sup>

The most prevalent cause of this disease entity is sinusitis, which causes referred headache and face pain over the area of the affected sinus and may be coupled with relevant nasal and sinus symptoms, such as nasal obstruction, purulent rhinorrhea, posterior nasal drip, and hyposmia.<sup>6</sup> Many persons with facial pain that suggests sinus disease have intranasal pathology rather than sinusitis, according to comprehensive examinations; the middle turbinate, which is near to other mucosal surfaces, has been linked as a possible source of contact point rhinogenic pain.<sup>7,8</sup>

This prospective study will examine the effect of surgical treatment on pain alleviation in patients with CRS, measuring the intensity, duration, and frequency of headaches.

### PATIENTS AND METHODS

A prospective study was conducted in the Department of Otolaryngology, Al-Azhar University Hospital. We recruited 60 individuals of both sexes between the ages of 18 and 65. They were evaluated clinically and radiologically for differences in the nose. The duration of the study ranged from 6–12 months.

The 60 cases were split up into 3 groups: Group (1): Chronic Rhinosinusitis with or without concha bullosa, Group (2): Chronic Rhinosinusitis with or without hypertrophy turbinate and Group (3): Chronic Rhinosinusitis with or without deviated septum.

Inclusion criteria: (1) Patients with chronic rhinosinusitis associated with facial pain, Headache with or without nasal obstruction.

(2) Chronic rhinosinusitis with concha bullosa, with turbinate hypertrophy, or with deviated septum.

Exclusion criteria:(1) Patients with other causes as Tension headache, neurological causes, hypertension, temporomandibular jaw Joint disorders, ophthalmic causes such as thermal errors, glaucoma.

(2) patients with previous nasal surgery, perforated nasal septum and insufficient nasal valve.

(3) acute sinonasal inflammation, craniofacial malformation, and Patients with paranasal sinus mucocoeles and pyocoeles, as well as sinonasal malignancies.

Pre-Operative:

Each patient in this study was subjected to the following:

History taking asked about

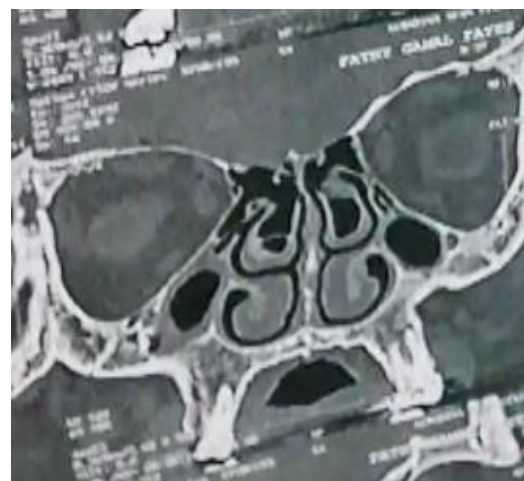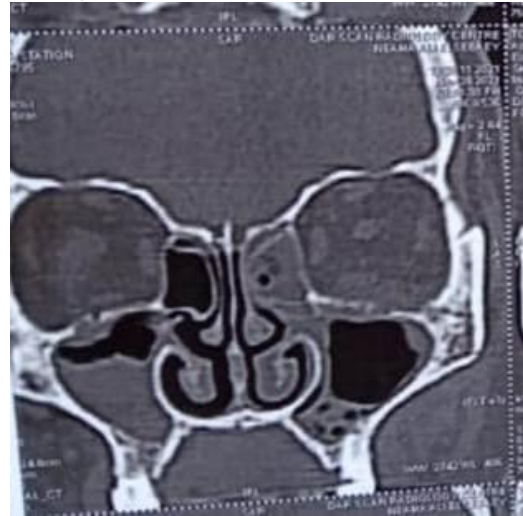
Headache (A Visual Analogue Scale (VAS) was used to assess the severity of the headache, with 0 indicating no discomfort and 10 indicating the worst headache imaginable. The start, course, length, site of pain, and radiation of headaches were all examined. The kind and severity of the discomfort).

Nasal obstruction (mild, moderate, severe).

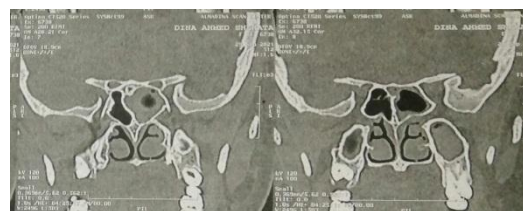
Nasal discharge (present or absent).

Thorough clinical examination:

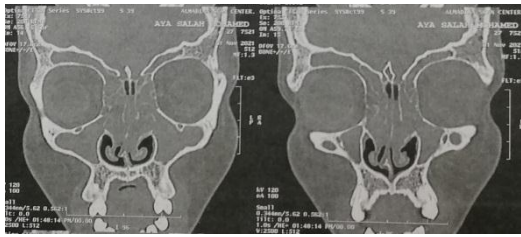All patients underwent diagnostic nasal endoscopy, for confirmation of the diagnosis, using a 0° and 30° rigid nasal endoscope after applying a nasal decongestant. Radiological assistant by CT nose and paranasal sinus (PNS) to confirm the endoscopic examination and the extent of the impact of the sinuses, and ear and throat examination.



**Fig. 1:** CT scan showing ethmoid and maxillary sinusitis with concha bullosa.



**Fig. 2:** CT scan showing sphenoid and maxillary sinusitis and nasal turbinate enlargement.



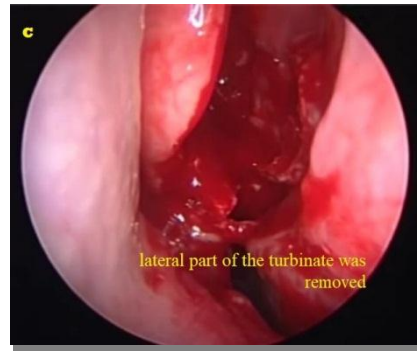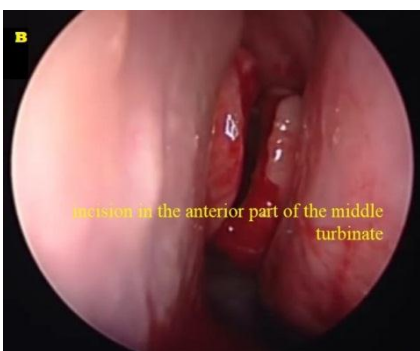
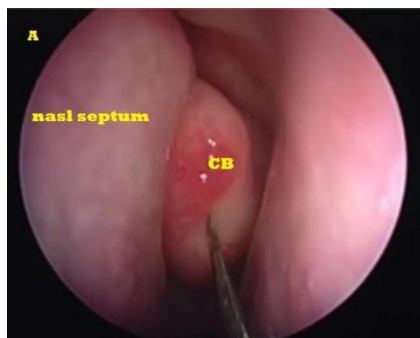**Fig. 3:** CT scan showing ethmoid and maxillary sinusitis with deviated septum.

**Operative technique:**

All patients underwent Hypotensive Anesthesia.

A 3 ml syringe was used to infiltrate the lateral nasal wall near the uncinate and the axilla of the middle turbinate with 1 percent lidocaine and 1:100,000 epinephrine. Following that, cotton pledgets soaked in oxymetazoline were put in the middle meatus. In Group (1): Chronic Rhinosinusitis with concha bullosa.

**Excision of concha bullosa:** If concha bullosa present excision of concha bullosa was the first step to have a better view of the lateral nasal wall. A sharp sickle knife was used to make an incision in the anterior region of the central turbinate, and the lateral half of the turbinate was removed.

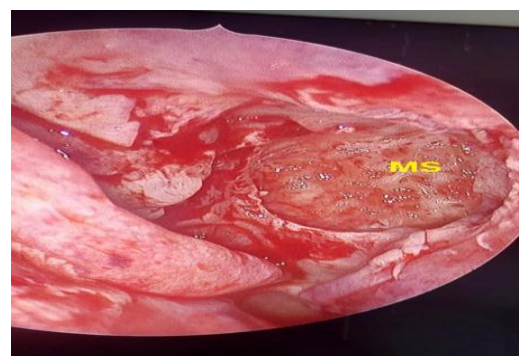
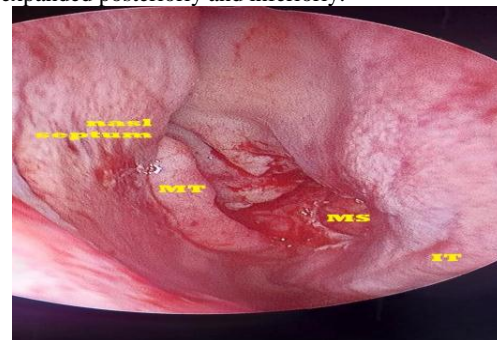


**Fig. 1:** Excision of concha bullosa

**Uncinectomy:** To access the uncinate process medialized from the lamina papyracea, the middle turbinate was gently medialized using a Freer elevator.

The uncinate was sliced inferiorly using a backbiter. The free edge of the uncinate was grabbed and removed with Blakesley forceps. Biting devices were used to remove the rest of the uncinate process until the maxillary ostium could be seen.

**Maxillary antrostomy:** After removing the uncinate, the natural ostium of the maxillary sinus was visible. To avoid harm to the orbit superiorly and the nasolacrimal duct anteriorly, the ostium was expanded posteriorly and inferiorly.



**Figure (2):** Maxillary antrostomy by ESS. The endoscopic finding after widening of the right maxillary sinus (MS), middle turbinate (MT), inferior turbinate (IT).

**Ethmoidectomy** If your sinuses are infected, The ethmoid bulla was the first cell discovered in the ethmoid sinus. This big cell was pierced on both the medial and inferior sides.

The lamina papyracea was identified. The dissection was continued backwards until the basal

lamella was reached and pierced. The middle and superior turbinate medially, as well as the lamina papyracea laterally, were used to dissect posterior ethmoid cells found posterior to the basal lamella. Sphenoidotomy: The sphenoid ostium was found either transnasally medial to the middle turbinate or in the infero-medial region of the posterior ethmoid if the sinus was involved. To get a better view of the spheno-ethmoidal recess and the sphenoid ostium, the inferior section of the superior turbinate was often excised..

By gently running a probe over the face of the sphenoid, the ostium was identified. Once the ostium was reached, the probe was able to glide into it. The ostium was enlarged inferiorly once it was identified. Frontal sinusotomy: If the frontal sinus was damaged, it was treated last to avoid bleeding from the frontal recess area obstructing visualisation while working on more posterior and inferior cells.

The outflow of the frontal sinus was impeded by the posterior wall of agger nasi cells. To remove the impediment, it was meticulously dissected. To gain access to the frontal recess, the superior section of the uncinata was excised.

Group (2) In cases of Chronic Rhinosinusitis with Turbinate Hypertrophy, partial turbinectomy was done. The turbinate was compressed then reduced by cutting parallel to the lower edge. After the medial fracture of the turbinate performed with a Boise elevator to medialize the inferior turbinate, It was squeezed from both the front and the back. By cutting a strip from the turbinate's flaccid bottom edge with scissors, the size of the turbinate was reduced. A piece of bone may be removed if necessary. Finally, the remaining turbinate is moved laterally.

If there was any bleeding encountered, bipolar cautery was used for hemostasis.

Endoscopic sinus surgery was done as previously explained for affected sinuses (Uncinectomy, Maxillary antrostomy, Ethmoidectomy, Sphenoidotomy, Frontal sinusotomy) Only the affected sinuses were operated on.

Group (3): Chronic Rhinosinusitis with deviated septum: Septoplasty Done through

Local anaesthetic insertion with 1 percent lidocaine and adrenaline (1:100,000) in the submucoperichondrial plane bilaterally until mucosa is thoroughly blanched.

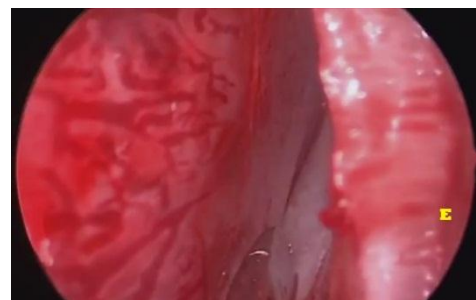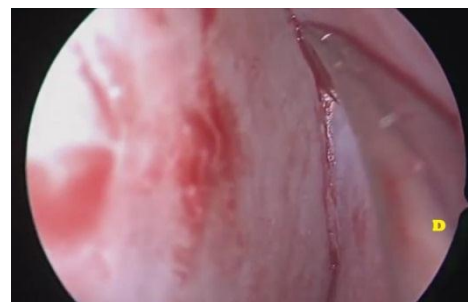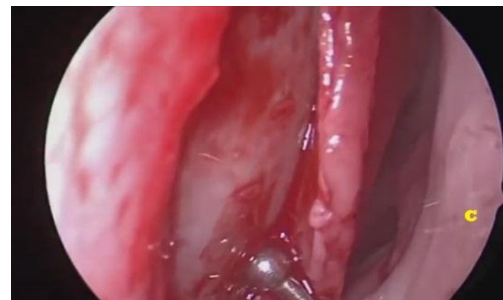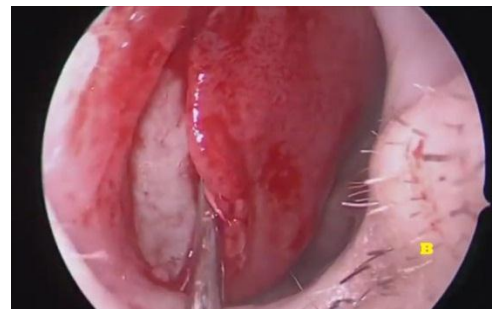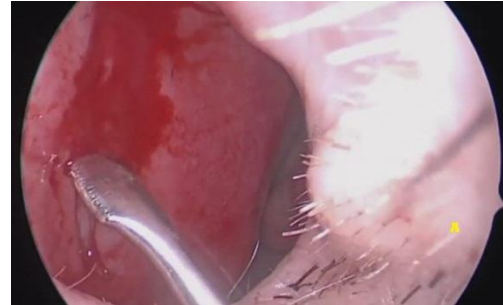
A 15-blade incision was made down to cartilage on the caudal margin. A hemi-transfixion or Killian's incision was commonly utilised.

The quadrangular cartilage and vomer bones were then revealed using dissecting scissors and Freer elevators to create a submucoperichondrial plane and dissect posteriorly.

The same incision is then used to raise a second flap on the opposite side. A chunk of cartilage was removed using a blade, a Freer elevator, or Blakesley forceps. An 'L-strut' structure of quadrangular cartilage is kept to keep the nasal dorsum and tip stable (dorsal and caudal edges).

The cartilage that has been removed must be preserved. To straighten other places, pieces of the original cartilage could be modified and inserted inside the septal cavity. The mucochondral flaps were repositioned against the septum. silicone splints were requested. They were size-appropriate, for easy removal, placed adjacent to the septum and fastened

with silk threads on an outpatient clinic. Splints are intended to keep turbinates free of adhesions. An antibiotic cream has been placed through the nose. Endoscopic sinus surgery was done as previously explained for affected sinuses (Uncinectomy, Maxillary antrostomy, Ethmoidectomy, Sphenoidotomy, Frontal sinusotomy) Only the affected sinuses were operated on.



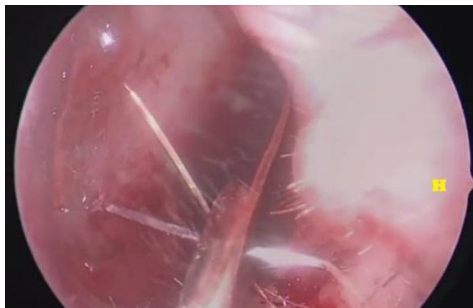
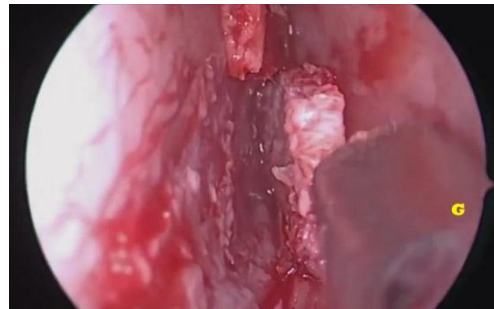
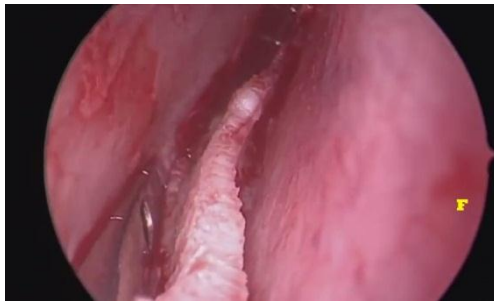

Figure (3): Submucosal Resection, Killian’s incision (A). Create a sub-mucoperichondrial plane (B). Raising Mucoperichondrial Flap (C). Dissect posteriorly to reveal the quadrangular cartilage (D).second flap on the contralateral side (E). Incise the deviated piece of the septum and remove it (F). Sutures are used to secure the mucoperichondrial flaps in place against the septum (H).

Any remaining bony septations were removed at the end of the treatment, and hemostasis was achieved. A nasal pack that dissolves was used.

**Post-operative assessment:**

All Patients were followed post-operative for 3 months and 6 months for assessment of improvement of: (1) According to VAS, there is a headache (where 0 indicates no pain and 10 indicate the worst headache imaginable). (2) Nasal Obstruction in each group. (3) Nasal Discharge. (4) Quality of Life.

Follow-up after the operation Has been accomplished by: (1) Clinical examination. (2) Endoscopic examination. (3) Radiologically by CT nose and PNS

Statistical Analysis: SPSS 22.0 for Windows was used to gather, tabulate, and statistically analyse all of the data (SPSS Inc., Chicago, IL, USA). Frequencies and relative percentages were used to depict qualitative data. For parametric data, mean SD (standard deviation) was used, and for non-parametric data, median and range were used. To compare more than two dependent categories of normally distributed variables, the one-way ANOVA test was used. Significant was defined as a P value of less than 0.05.

**RESULTS**

Characteristics of the study groups' demographics and clinical data showed that in the group1 the mean age 40.35 years, the number of females was 8constitute 40% and the number of males was 12 and they constituted 60%. In group 2 the mean age 39.82 years, the number of females was 9 constitute 45% and the number of males was 11 and they constituted 55%. that in the group 3 the mean age 37.51 years , the number of females was 10 constitute 50% and the number of males was 10 and they constituted 50%.

	Group 1(n=20)	
	N	%
CRS with Concha bullosa	5	20%
CRS Without concha bullosa	15	80%
	Group 2(n=20)	
	N	%
CRS with Turbinate hypertrophy	18	90%
CRS Without turbinate hypertrophy	2	10%
	Group 3(n=20)	
	N	%
CRS with Deviated septum	12	60%
CRS Without deviated septum	8	40%

**Table 1:** number of CRS patient associated with Concha bullosa or turbinate hypertrophy or deviated septum among the studied groups

Concha bullosa prevalence among group 1 was 20%. While turbinate hypertrophy prevalence among group 2 was 90%. Moreover, deviated septum prevalence among group 3 was 60% (Table 2).

	1st Group (n= 20)		2nd Group (n= 20)		3rd Group (n= 20)		P
	N	%	N	%	N	%	
Location							.861
Frontal	9	45	8	40	10	50	
Temporal	6	30	7	35	7	35	
Parietal	4	20	5	25	6	30	
Occipital	3	15	4	20	3	15	
Periorbital	2	10	1	5	1	5	
Time of attack							.981
Whole day	5	25	7	35	6	30	
Afternoon	7	35	6	30	6	30	
Morning	5	25	3	15	4	20	
Evening	3	15	4	20	4	20	
Headache duration in hours Mean ± SD	5.23 ± 2.38		4.76 ± 1.41		5.78 ± 2.19		.292

**Table 2:** Headache or facial pain feature among the studied groups

Headache features and headache duration were comparable between the three groups without statistically significant difference found (Table 2)

Analogue Visual Scale	1st Group	2nd Group	3rd Group	F	P
Preoperative Scale Mean ± SD	6.25 ± 1.87	5.87 ± 0.911	6.48 ± 1.72	.782	.463
3 months post operative Scale Mean ± SD	2.88 ± 1.01	3.01 ± 1.39	2.51 ± 0.993	1.03	.365
6 months post operative Scale Mean ± SD	1.54 ± 1.21	1.33 ± 0.935	1.59 ± 1.13	.316	.730
P	<00. 001	<00. 001	<00 .001		

**Table 3:** pre-and post-operative care VAS between the three groups.

A Visual Analogue Scale (VAS) was used to assess the headache, with 0 indicating no pain, 1-3 mild discomfort, and 4-6 significant pain, 7-9 sever pain and 10 indicates the worst headache imaginable.

In terms of preoperative and postoperative VAS, there was no significant difference among the groups studied. Furthermore, in each group, there is a significant reduction in postoperative VAS. (Table 3).

	Group 1 (n=20)				Test	P
	Preoperative		Postoperative			
CRS Patients with Concha bullosa	(n=5)		(n=5)			
Headache intensity (VAS) Mean ± SD	5.87 ± 1.36		0.625 ± 0.894		4.83	<0.001
Nasal obstruction	3	60%	1	20%	1.97	.036
Nasal discharge	5	100%	1	20%	8.36	.002
CRS Patients without Concha bullosa	(n=15)		(n=15)			
Headache intensity (VAS) Mean ± SD	5.65 ± 1.52		1.67 ± 1.12		2.17	.003
Nasal obstruction	8	53.3%	5	33.3%	1.12	.091
Nasal discharge	15	100%	3	20%	17	.000

**Table 4:** Pre and postoperative clinical evaluation among group 1 (CRS with or without concha bullosa)

There was a significant reduction regarding VAS in both subgroups, but In cases with concha bullosa, the reduction was even greater. Moreover, there is a significant relief in nasal obstruction and nasal discharge in patients with concha bullosa (Table 4).

	Group 2 (n=20)				Test	P
	Preoperative		Postoperative			
CRS Patients with Turbinate hypertrophy	(n=18)		(n=18)			
Headache intensity (VAS) Mean ± SD	6.53 ± 1.41		1.81 ± 0.938		14	.000
Nasal obstruction	18	100%	2	11.1%	29	.000
Nasal discharge	16	88.9%	1	5.6%	25	.000
CRS Patients without Turbinate hypertrophy	(n=2)		(n=2)			
Headache intensity (VAS) Mean ± SD	6.37 ± 0.811		1.5 ± 0.707		7.4	.021
Nasal obstruction	0	--	0	--	--	1
Nasal discharge	2	100%	0	--	6	.025

**Table 5:** Pre and postoperative clinical evaluation among group 2(CRS with or without Turbinate hypertrophy). There was a significant reduction regarding VAS in both subgroups. Moreover, there is a significant relief in nasal obstruction and nasal discharge in both subgroups (Table 5)

	Group 3 (n=20)				Test	P
	Preoperative		Postoperative			
CRS Patients with deviated septum	(n=12)		(n=12)			
Headache intensity (VAS) Mean ± SD	6.75 ± 1.51		1.15 ± 0.645		14	.000
Nasal obstruction	10	83.3%	0	--	16	.000
Nasal discharge	12	100%	3	25%	10	.000
CRS Patients without deviated septum	(n=8)		(n=8)			
Headache intensity (VAS) Mean ± SD	5.3 ± 1.2		0.853 ± 0.619		9	.000
Nasal obstruction	1	12.5%	0	--	1.08	.305
Nasal discharge	8	100%	0	--	17	.000

**Table 6:** Pre and postoperative clinical evaluation among group 3 (CRS with or without deviated septum) There was a significant reduction regarding VAS in both subgroups, but the reduction was more significant in patients with deviated septum. Moreover, there is a significant relief in nasal obstruction and nasal discharge in patients with deviated septum (Table 6).

### DISCUSSION

The purpose of this research was to follow up on the findings of a previous investigation. sinus surgery, investigate the effect of surgical pain treatment in CRS patients, and evaluate headache severity, duration, and frequency. According to the results of the current investigation, there was a substantial difference between the three groups regarding headache duration and headache frequency.

In the study, concha bullosa prevalence among group 1 was 20%. While turbinate hypertrophy prevalence among group 2 was 90%. Moreover, deviated septum prevalence among group 3 was 60%.

While in the study of Wee et al.<sup>9</sup> Septal deviation was found in 76 percent (31/41) of patients, as was a septal spur in 61 percent (25/41), inferior turbinate hypertrophy in 51 percent (21/41), nasal discharge in 49 percent (20/41), contact point in 42 percent (17/41), nasal polyp in 27 percent (11/41), and postnasal drip in ten percent (4/41).

The present study showed that there is a significant decrease in postoperative VAS in all the three groups. In group 1(Chronic Rhinosinusitis with or without concha bullosa); In cases with concha bullosa, the reduction was even greater.. Moreover, there is a significant relief in nasal obstruction and nasal discharge in patients with concha bullosa. In group 2 (Chronic Rhinosinusitis with or without hypertrophy turbinate); there is a significant relief in nasal obstruction and nasal discharge in both subgroups. In group 3(Chronic Rhinosinusitis with or without deviated septum); the reduction was more significant in patients with deviated septum. Moreover, there is a significant relief in nasal obstruction and nasal discharge in patients with deviated septum.

A total of 60 patients, significant difference found regarding nasal obstruction between the groups. Based on Visual Analogue Scale (VAS), The severity of pain in group 1 was reduced significantly, from 6.25 1.87 (preoperative) to 2.88 1.01 (postoperative). (After 3 months of treatment,) and 1.54 ± 1.21 (6

months after treatment). In group 2 the intensity of pain revealed a high reduction from  $5.87 \pm 0.911$  (Preoperative) to  $3.01 \pm 1.39$  (3 months after treatment) and  $1.33 \pm 0.935$  (After 6 months of treatment.). In group 3 the intensity of pain revealed a high reduction from  $6.48 \pm 1.72$  (Preoperative) to  $2.51 \pm 0.993$  (3 months after treatment) and  $1.59 \pm 1.13$  (6 months after treatment)

According to our findings, Bektas et al.<sup>10</sup> reported that after endoscopic sinus surgery, all patients experienced a decrease in the degree of facial pain. Complete alleviation was observed by 19 individuals (52.7%). The difference in VAS pain scores before surgery (mean 8.62) and after surgery (mean 2.11) was statistically significant ( $p = 0.0000$ ).

Our findings were backed up by a research by Wee et al.<sup>9</sup>, who found that the most prevalent type of headache was stabbing or squeezing, with the frontal part of the head being the most common site. The attack occurred at various times. Nasal obstruction and rhinorrhea were frequently accompanied by headache, and stress was the most prevalent exacerbating cause.

According to the findings of the current investigation, about 75% of the patients showed facial pain in frontal and temporal area. While about 30% of patients suffered from pain throughout the day, 50% of patients experienced daytime pain and 18% night time.

In the study of Peric et al.<sup>11</sup> The face pain did not improve in five ( $n = 5$ ) cases (11.90%). Before surgery, three of these patients had septal deviation and two had concha bullosa. The reduction in headache severity after surgical excision of mucosal contacts was greater in patients with concha bullosa ( $p = 0.000$ ) and septal spur ( $p = 0.000$ ) than in individuals with septal deviation ( $p = 0.01$ ). At 6 months, One year, and two years after surgery, the same pattern of decreasing pain severity was seen..

Also, wee et al.<sup>9</sup> found that the surgery's overall success rate in reducing headaches, as measured by the VAS score, was around 80%. After surgery, 24 of 41 patients (58.5%) reported complete relief from headaches, while 9 patients (22.0%) reported a decrease in headache intensity. In contrast, 6 patients (14.6 percent) said their headache intensity remained the same after surgery, and 2 patients (4.9 percent) said their headaches got worse. In the resolved and improved groups, the postoperative VAS score was considerably lower than the preoperative score. The current study showed that nasal obstruction of Group 2 scored much higher than groups 1 and 3. Otherwise, the distributions of the rest clinical presentation were comparable between the groups without statistically significant difference found. The distributions of the clinical presentation were comparable postoperatively with statistically significant difference found regarding nasal obstruction only.

### CONCLUSION

In comparison to local medical treatment options, surgical surgery for contact point headache produced much better results. The surgical removal of contact points in the nasal cavity can help with headache relief. Patients with mucosal contacts linked with septal spur had the most severe, long-lasting, and

frequent contact point headaches. The outcomes of surgical therapy are better in cases of headache caused by a septal spur and concha bullosa than in those caused by a nasal septal deviation.

Conflict of interest : none

### REFERENCES

1. Bose S, Grammer LC, Peters AT. Infectious Chronic Rhinosinusitis. *J Allergy Clin Immunol Pract.* 2016; 4(4):584-9.
2. Albirmawy OA, Elsharif HS, Shehata EM, et al. Middle turbinate evacuation conchoplasty in management of contact-point rhinogenic headache in children. *Int J Clin Pediatr.* 2010;1:115–23
3. Swain SK, Behera IC, Mohanty S, et al. Rhinogenic contact point headache—frequently missed clinical entity. *Apollo Med.* 2016; 13:169–73
4. Kohanski MA, Toskala E, Kennedy DW. Evolution in the surgical management of chronic rhinosinusitis: Current indications and pitfalls. *Journal of Allergy and Clinical Immunology.* 2018; 141 (5): 1561-9.
5. Stackpole SA, Eldelstein DR. Anatomic variant of paranasal sinus and their implication for sinusitis. *Curr Op Otolaryngol Head Neck Surg.* 2014; 4:1–6.
6. Hsueh-Hsin S, Chiche H, Shiang F. Non sinusitis-related rhinogenic headache: a ten-year experience. *Am J Otolaryngol Head Neck Med Surg.* 2012; 29:326–32.
7. Landrigan GP, Kirkpatrick DA. Intra nasal xylocaine: a prognostic aid for pre-operative assessment of facial pain of nasal origin. *J Otolaryngol.* 2012; 21:126–128.
8. Behim F, Behim B, Behim D. Surgical management of contact point headache. *Headache.* 2011; 45:204–10.
9. Wee, J. H., Lee, J. E., Hong, S. L., Shin, J. M., & Kim, D. Y. Prospective Study on the Characteristics and Postoperative Improvement of Rhinogenic Headache. *Journal of Rhinology.* 2015; 22(1), 6-10.
10. Bektas, D., Alioglu, Z., Akyol, N., Ural, A., Bahadir, O., & Caylan, R, Surgical outcomes for rhinogenic contact point headaches. *Medical Principles and Practice.* 2011; 20(1), 29-33.
11. Peric, A., Rasic, D., & Grgurevic, U, Surgical treatment of rhinogenic contact point headache: an experience from a tertiary care hospital. *International Archives of Otorhinolaryngology.* 2016; 20, 166-71.