

CBCT ASSESSMENT OF THE INTEGRATION OF XENOGRAFT MIXED WITH PLASMA RICH IN GROWTH FACTORS (PRGF) IN DIRECT MAXILLARY SINUS LIFT SURGERY: CASE SERIES STUDY

Nesrine Khairy * and Noha Saleh Abu-Taleb**

ABSTRACT

Objectives: The study aimed to evaluate the effect of plasma rich in growth factors (PRGF) mixed with xenograft in direct maxillary sinus lift using cone-beam computed tomography (CBCT). CBCT was used for analysis of bone quantity and quality at the future implant site.

Methods: Twenty patients of both sexes (16 females and 4 males) with missing maxillary first or second molar teeth, bone height ≤ 4 mm, and crestal ridge width of at least 5 mm were included. A blood sample was collected from each patient that was subjected to centrifugation to obtain the PRGF preparation. Direct maxillary sinus lift with lateral approach was performed and xenograft mixed with PRGF was used as sinus graft. Bone height, bone width, graft volume and bone grey value/density were assessed using CBCT scan immediately after surgery and after 6 months.

Results: After 6 months, there was 13.22 % decrease in total bone height (TBH) that was statistically significant. Also, there was a decrease in the crestal, middle, and apical bone widths which was significant at the middle bone width (MBH). Graft volume (GV) decreased by 20.98%; however, this decrease was statistically non-significant. Bone grey value/density showed a significant increase of 25.47 % in residual ridge density (RRD) and 21.09 % in residual ridge and graft density (RRGD).

Conclusion: PRGF combined with xenograft increased the bone height, established middle and apical bone widths required for the implant support. Additionally, the used graft improved the bone density as measured by the grey value on CBCT scans.

KEYWORDS: Bone density; Cone-beam computed tomography; Maxillary sinus augmentation; Plasma rich in growth factors.

* Associate Professor, Oral and Maxillofacial Surgery Department, Faculty of Dentistry, Cairo University, Cairo, Egypt

** Associate Professor, Oral and Maxillofacial Radiology Department, Faculty of Dentistry, Cairo University, Cairo, Egypt

INTRODUCTION

Bone-integrated oral implants have shown long-term predictable results. The greatest failure rate in implants was found among those placed in the posterior region of the upper jaw due to the anatomical characteristics of the region which include quality and amount of present bone. ⁽¹⁾

After extraction of maxillary posterior teeth maxillary sinus pneumatization often occurs. This in turn decreases the available bone height required for dental implant placement. Consequently, a variety of surgical approaches have been developed for ridge augmentation in maxillary posterior region including both direct and indirect sinus lift procedures. ⁽²⁾

Different types of biomaterials have been used for maxillary sinus floor augmentation including autograft, allograft, xenograft, alloplast, and growth factors. The selection of the ideal graft material has been a subject of controversy over the years. Autogenous bone graft is considered the golden standard in augmentation procedures due to its osteoinductive, osteogenic and osteoconductive characteristics. However, the use of autogenous bone grafts is associated with risk of donor site morbidity and unpredictable graft resorption. ⁽³⁾

SmartBone is a xenogenic bone graft produced by combining natural bovine bone mineral structures with bioresorbable polymers and cell nutrients. This new concept of biomaterial assembly allows the patient's cells to grow quickly and efficiently into SmartBone providing osteoconduction, osteogenesis and finally a perfect integration. Bioactive polymers give SmartBone great loading resistance, high volumetric stability as well as guarding against premature bone resorption. ⁽⁴⁻⁵⁾

Plasma rich in growth factors (PRGF) is an autologous human platelet concentrate. It is considered a source rich in growth factors. It was introduced in 1998 by Marx et al. ⁽⁶⁾ Combined with

an autologous bone graft, it was used to reconstruct mandibular defects. Their research showed that PRGF addition to bone grafts accelerated the rate of bone maturation, and radiographically increased bone density when compared to bone graft by itself. PRGF contains growth factors that help to initiate the migration of undifferentiated stem cells to the site and triggering their proliferation. ⁽⁷⁾ Moreover, PRGF may have the potential to induce growth and differentiation of mesenchymal stem cells (MSCs) which can accelerate bone repair. ⁽⁸⁻⁹⁾ However, there is limited evidence on the effects of PRGF, used alone or in combination with bone grafting materials, on bone regeneration in maxillary sinus augmentation. ⁽¹⁰⁾

In implant dentistry, cone beam computed tomography (CBCT) allows for 3D volumetric jawbone imaging at lower dose, reasonable cost, and isotropic voxels with sub-millimeter resolution that provide precise measurements required for implant site assessment. ⁽¹¹⁻¹³⁾ During implant planning, CBCT is highly required for detecting the proximity of vital anatomic structures; evaluating bone height, width, and morphology; and guiding the use of more complicated surgical techniques such as bone grafting. ^(14,15) Postoperatively, CBCT is important when there is a clinical need for postsurgical monitoring of cases that required bone grafting and sinus augmentation prior to implant insertion. ⁽¹³⁾

Therefore, the aim of the present study was to evaluate the effect of PRGF mixed with xenograft in direct maxillary sinus lift. CBCT was used for analysis of the bone quantity (bone height, bone width, and graft volume) and quality (bone grey value/density) at the future implant site.

PATIENTS AND METHODS

Study design

This study was conducted on twenty patients of both sexes (16 females and 4 males) with age

range from 24 to 54 years (mean 39 years). Patients were collected from the Department of Oral and Maxillofacial Surgery, Faculty of Dentistry, Cairo University. All patients were informed about the risks and benefits of the study, and they signed written consent to participate.

Inclusion criteria

Patients with missing maxillary first or second molar teeth, bone height ≤ 4 mm, crestal ridge width of at least 5 mm, age >18 years, and proper oral hygiene.

Exclusion criteria

Patients with acute or chronic sinusitis, pathologic condition at the area of surgery, uncontrolled systemic disease that might affect the surgery or bone healing or implant osseointegration, patients with history of chemotherapy and/or radiotherapy, and patients treated with anticoagulants. Heavy Smokers and pregnant females were also excluded from the study.

Preoperative assessment

Clinical, and radiographic examinations as well as evaluation of diagnostic casts were done for each patient included in the study. Panoramic images were acquired preoperatively to assess proximity of the implant site to the maxillary sinus border, the residual ridge height, and the presence of maxillary sinus septa. Panoramic radiographs were acquired using Planmeca Proline CC panoramic x-ray machine (Planmeca, Helsinki, Finland). Clinical measurements and ridge mapping were done using caliper to determine the crestal ridge width, as well as evaluation of diagnostic casts on hinge articulator to assess the inter-arch relationship

Surgical phase

- All patients received 2 g of Amoxicillin/clavulanic acid (Augmentin1g, Medical Union

Pharmaceuticals (MUP) - ARE) and 8 mg dexamethasone (SigmaTec Pharmaceutical Industries. ARE) 1 hour before surgery and they were asked to rinse the mouth with Chlorhexidine (Hexitol %0.12, the Arab drug company (ADCO) –ARE) for 1 minute.

- Surgeries were done under local anesthesia articaine HCl %4 (Septanest SP, Septodont Pharmaceutical Industries, France).
- The PRGF preparation started with collection of sixty ml of venous blood from the patient into tubes containing sodium citrate anticoagulant.
- The PRGF was separated by centrifugation of the collected blood (1-80, Delta lab company, China) at 1800 rpm for 8 minutes.
- The 1 mL plasma fraction located above the RBCS fraction, not including the buffy coat, was aspirated, and transferred to 2 dishes where 50 μ L of calcium chloride were added for each 1 ml of the preparation.
- The xenograft was then added and mixed with the preparation in one of the dishes, the preparation in the other dish was used as a membrane to cover the lateral window, both dishes were incubated in a heated water bath at 37°C for 40 minutes. ⁽¹⁶⁾ **(Figure 1a)**
- The xenograft (2-1mm particle size) (SmartBoneMicroships, IBI SA, Mezzovico-Vira, Switzerland) was mixed with PRGF. **(Figure 1b)**
- Direct maxillary sinus lift with lateral approach was performed as follows: A full thickness mucoperiosteal flap was raised exposing the lateral bone wall of the antrum, where a bony window was created, with the inferior cut made 2 mm above the antral floor, using a diamond round bur on a handpiece and surgical motor (Implantmed drive unit, W&H Dentalwerk, Bürmoos Salzburg, Austria). After completing

the osteotomy, the Schneiderian membrane was gently separated from the surrounding bone using sinus lift currettes (ACE sinus lift kit, ACE surgical Supply Co., Inc. USA). As the dissection continued, the membrane was elevated from the floor, lateral wall, medial wall, and antero-posteriorly to provide a large compartment for graft placement. (**Figure 1c**)

- Then the mix was packed into the elevated sinus (**Figure 1d**) and the PRGF membrane was used to cover the window on the lateral wall of the sinus. The surgical site was closed using interrupted 0-3 vicryl suture. (**Figure 1e**)

Postoperative instructions and follow up:

Following the primary sinus lifting, postoperative cold application, prophylactic antibiotics, and analgesics were recommended for all patients. All patients were evaluated for postoperative pain, oedema, infection, or nose bleeding one week postoperatively. Further, periodic recall follow-up visits

were requested 1, 3, and 6 months postoperatively.

CBCT imaging

This was performed twice: Immediately after the sinus lift surgery (immediate postoperative) which acted as baseline for the assessment of graft healing, and after 6 months follow up period (6 months postoperative). CBCT image acquisition was performed using Planmeca Promax 3D-Mid CBCT machine (Planmeca, Helsinki, Finland). Scan specifications: (FOV: 20x10 cm, voxel size: 0.4 mm, tube current: 8 mA, tube voltage: 90 kV, exposure time: 13.5 s, and DAP: 6.3mGyxcm²).

Image analysis

For image analysis, data were exported anonymously to ensure the observer blindness to the patient data. Image analysis was performed using Planmeca Romexis viewer version 4.6.0.R, Helsinki, Finland. CBCT images analyzed quantitatively for the bone height, bone width, and graft volume and qualitatively for bone quality (grey value/density).

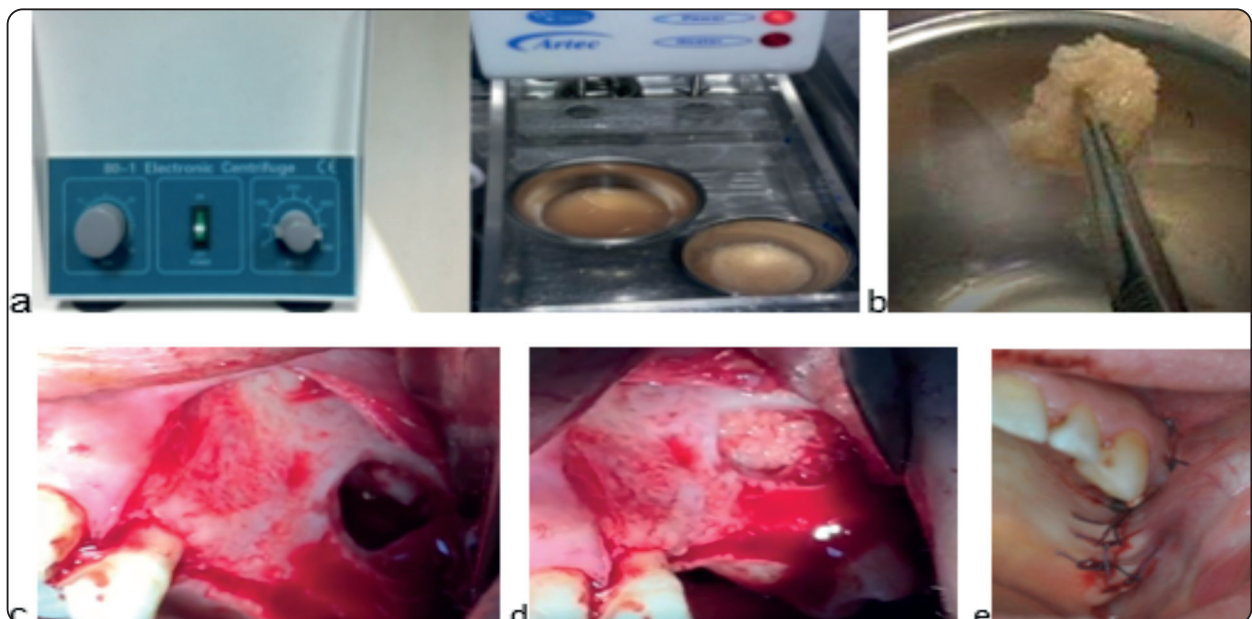


Fig. (1): A photograph showing a) The centrifuge (left) and the hot water path (right) containing a dish of the PRGF mixed with xenograft, b) Xenograft in PRGF matrix, c) The osteotomy outline with sinus lifting, d) The application of the mix in lifted sinus, e) The interrupted 3-0 vicryl suture.

Quantitative analysis

Bone height

At first, reorientation of the CBCT images was performed to obtain corrected sagittal and coronal cuts for proper measurement of bone height and width. On the main software screen, the axial cut at the level of the alveolar crest was selected. To acquire corrected sagittal and coronal views of the implant site, oblique planar reformatted images were constructed by adjusting the coronal and sagittal planes. This was performed by rotating the lines representing the sagittal and coronal planes on the axial cut. For standardization of the CBCT cuts used for image analysis, fixed anatomical landmarks were set in the CBCT images to serve as reference points for immediate postoperative and follow up comparison.

The future implant sites were guided by the adjacent teeth as follows: the distance between the center of premolar roots or planned implant was adjusted to be 7mm, distance between the center of molar roots or planned implant was 8mm. These distances were set at the sagittal slices.

On the corrected coronal cuts, three heights were assessed: residual ridge height (RRH), graft height (GH), and total bone height (TBH). RRH was measured as the distance between the alveolar crest to the floor of the maxillary sinus at the center of the planned site where the future implant will be placed. In case of irregular or knife edge ridge, measurements were taken after considering trimming of the alveolar ridge till a minimum of 6 mm ridge width became available. GH was measured as the distance between the maxillary sinus floor to the uppermost part of the graft. TBH was measured as the distance between the alveolar crest to the uppermost part of the graft. (Figure 2a)

Bone width

This was assessed on the coronal plane. The bone height was divided into three equal parts, then

the buccolingual bone width was measured from the outer surface of buccal plate to the outer surface of lingual plate at three levels along the bone height: at the crest, at the middle third, and at the apical third [crestal bone width (CBW), middle bone width (MBW), and apical bone width (ABW)]. (Figure 2b)

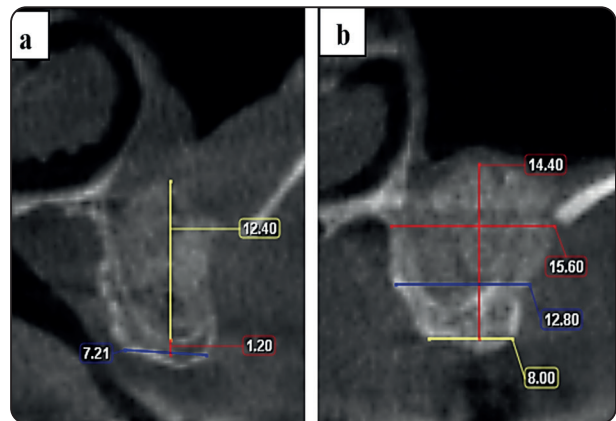


Fig. (2): Reformatted coronal CBCT images revealing: a) Bone height, measured after considering trimming of the alveolar crest: Residual ridge height (red vertical line) and graft height (yellow vertical line). b) Bone width: measured at three levels along the bone height: at the crest, at the middle third, and at the apical third.

Graft volume (GV)

For volumetric assessment, automatic segmentation of the bone graft was performed as follows: On the tool bar, the region of interest (ROI) was defined by using an “ellipsoid” shape on the image at the graft area. The ROI was adjusted manually to occupy the whole graft by scrolling through the cuts in the axial, sagittal, and coronal planes. Two steps were performed to calculate the GV: thresholding and region growing. **Thresholding:** This comprised choosing a certain grey value that was close to that of the graft. The preset threshold for bone was selected and the option “always include values lower than seed value” was chosen from the advanced options to ensure complete graft inclusion. **Region growing:** This comprised selection the graft region only for volume calculation. To obtain this, a seed point was

selected by clicking the cursor in a point within the graft. The graft region was automatically filled, according to the threshold level, with a certain color and the calculated graft region volume was then displayed in cm³. **Figure (3)**

Qualitative analysis:

Bone quality (Grey value /Density)

The bone quality/density/grey value was measured at two sites: at the residual ridge and at the residual ridge and graft. **Residual ridge density (RRD)**: a rectangular region of interest (ROI) was selected with dimensions 4mm x 1.6mm placed on the residual ridge at the center of the planned implant site. **Residual ridge and graft density (RRGD)**: a rectangular region of interest (ROI)

was selected with dimensions 4mm x10mm placed on the residual ridge and graft at the center of the planned implant site. The software displayed the average grey value of the selected region. **(Figure 4)**

Since the aim was to evaluate the change in the bone grey value / density after the 6 months follow up, and since the grey values obtained from CBCT scans are not reliable for comparison as the Hounsfield units (HU) in CT scans, a trial was made to allow for the comparison between the immediate postoperative and 6 months follow up bone grey values as follows: At the immediate postoperative CBCT scans, a fixed rectangular area (1.6mm x1.6mm) at the enamel of the tooth adjacent to the future implant was selected. The average grey value at this area recorded. At the 6

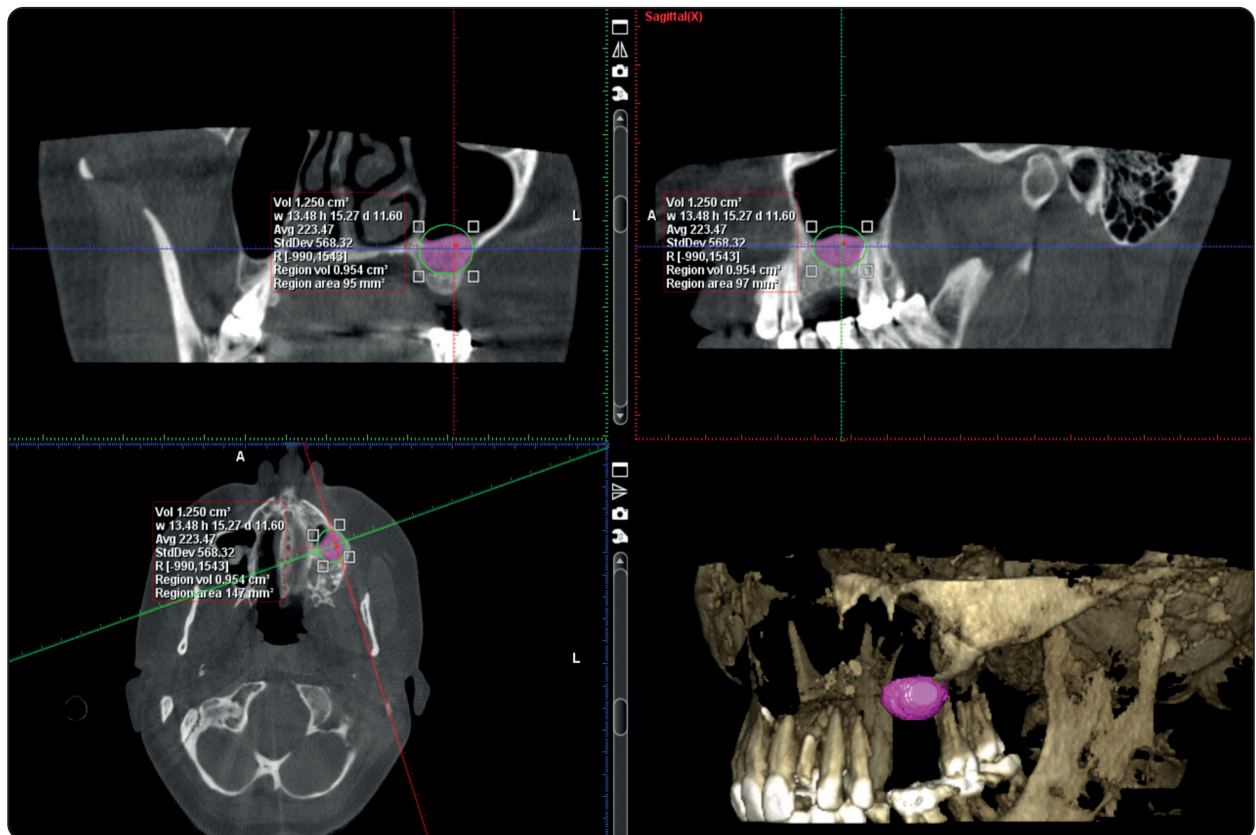


Fig. (3): CBCT images revealing volumetric assessment of the graft using Planmeca Romexis viewer 4.6.0.R: Reformatted Coronal, sagittal and axial sections and 3D volume rendered image revealing the automatic segmentation of the bone graft with manual adjustments to include all the graft. The region volume was counted as the graft volume.

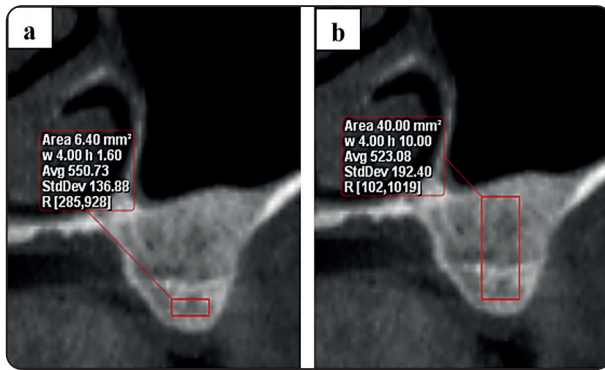


Fig. (4): Reformatted coronal CBCT images revealing bone grey value (bone density): (a) Residual ridge density: Average grey value at a rectangular region of interest (ROI) with dimensions 4mm x 1.6mm placed on the residual ridge at the center of the planned implant site. (b) Residual ridge and graft density: Average grey value at a rectangular region of interest (ROI) with dimensions 4mm x10mm placed on the residual ridge and graft at the center of the planned implant site.

months follow up scans, the same area was selected, and the average grey value was also recorded. The immediate postoperative grey value of the enamel was divided by the 6 months follow up one resulting in a factor. This factor was then multiplied by the average postoperative density/grey value of the implant site to correct for the unreliable grey value obtained by the CBCT. The percent change in the bone grey value / density after the 6 months follow up was then calculated.

All the parameters were measured twice by one experienced radiologist at one month interval to evaluate the intra-observer reliability of measurements.

Statistical analysis

Quantitative data was presented as minimum, maximum, mean, and standard deviation (SD). Student t-test was used for comparison between the immediate postoperative and 6 months follow up values. Pearson correlation coefficient was used to assess intra-observer agreement. The results were considered statistically significant if the p value

was less than 0.05. The percent change in the bone height, width, volume and density/grey value was calculated as follows:

$$\frac{6 \text{ months follow up - immediate post operative}}{\text{immediate post operative}} \times 100$$

Statistical analysis was performed using SPSS (Statistical package for the social sciences- IBM® SPSS® Statistics Version 20 for Windows, IBM Corp., Armonk, NY, USA).

RESULTS

For the clinical results, only five of the twenty patients showed a small membrane perforation that was managed by folding the sinus membrane on itself in the process of sinus membrane elevation and by the placement of PRGF membrane under the perforated sinus membrane. No fenestration, graft rejection or any other complication occurred in any of the patients at the host site during the 6 months post-operative follow up period, and normal wound healing was observed. All the patients committed to the scheduled visits and none of the patients was excluded from the study.

There was perfect intra-observer agreement regarding TBH, CBW, MBW, ABW, GV, RRD, and RRGD where Pearson correlation coefficients were 0.93, 0.94, 0.92, 0.97, 0.93, 0.99, and 0.99 respectively ($p < 0.05$).

Descriptive statistics of all the CBCT study parameters are shown in **table 1**. Shaded areas in table 1 represent data that were not assessed. In the 6 months postoperative images, the residual ridge became integrated with the graft in some cases that the maxillary sinus floor was not apparent which prevented the separate assessment of the RRH and the GH; therefore, the TBH was taken for comparison.

Comparison between the study parameters at immediate postoperative and 6 months postoperative

are shown in **table 2**. Regarding the bone height, there was a 13.22 % decrease in TBH after 6 months postoperatively that was statistically significant. Regarding the bone width, there was a decrease in CBW, MBW and ABW which was significant for the MBW (6.49 %). Similarly, GV showed a 20.98 %

decrease after 6 months postoperatively; however, this decrease was statistically non-significant. On the other hand, the bone grey value/density showed a significant increase where there was a 25.47 % increase in the RRD and 21.09 % increase in the RRGD.

TABLE (1): Descriptive statistics of the CBCT imaging study parameters

Parameters		Immediate postoperative				6 months postoperative			
		Minimum	Maximum	Mean	SD	Minimum	Maximum	Mean	SD
Bone height (mm)	RRH	1.05	3.6	2.25	0.83				
	GH	8	12.4	9.78	1.22				
	TBH	10.81	14.84	12.72	1.17	8.41	13.20	11.04	1.24
Bone width (mm)	CBW	6.00	8.01	6.42	0.54	6.00	8.01	6.30	0.50
	MBW	6.85	11.60	9.32	1.18	6.99	10.80	8.72	0.87
	ABW	6.45	14.00	10.82	1.76	8.44	13.69	10.73	1.34
Graft volume (cm ³)	GV	0.94	1.47	1.18	0.17	0.85	1.05	0.93	0.06
Bone quality (Grey value/ density)	RRD	10.17	514.50	236.72	133.56	139.65	549.10	317.62	104.91
	RRGD	234.24	418.92	326.29	61.09	314.67	544.81	413.55	65.81

RRH: Residual ridge height, GH: Graft height, TBH: Total bone height, CBW: Crestal bone width, MBW: Middle bone width, ABW: Apical bone width, GV: Graft volume, RRD: Residual ridge density, RRGD: Residual ridge and graft density, SD: Standard deviation, Shaded areas are not applicable

TABLE (2): Comparison between the mean and SD of the study parameters in immediate postoperative and 6 months postoperative CBCT images

Parameters		Immediate postoperative		6 months postoperative		% Change	P-value
		Mean	SD	Mean	SD	Mean	
Bone height (mm)	TBH	12.72	1.17	11.04	1.24	13.22	0.00001*
Bone width (mm)	CBW	6.42	0.54	6.30	0.50	1.96	0.147
	MBW	9.32	1.18	8.72	0.87	6.49	0.009*
	ABW	10.82	1.76	10.73	1.34	0.79	0.406
Graft volume (cm ³)	GV	1.18	0.17	0.93	0.06	20.98	0.490
Bone quality (Grey value/ density)	RRD	236.72	133.56	317.62	104.91	25.47	0.00001*
	RRGD	326.29	61.09	413.55	65.81	21.09	0.00001*

*TBH: Total bone height, CBW: Crestal bone width, MBW: Middle bone width, ABW: Apical bone width, GV: Graft volume, RRD: Residual ridge density, RRGD: Residual ridge and graft density, SD: Standard deviation, *: Significant (P-value < 0.05)*

DISCUSSION

PRGF is an autologous platelet concentrate that has been used combined with graft materials in maxillary sinus augmentation.⁽¹⁷⁾ PRGF has several advantages: No immunological matters are considered as it is an autologous preparation obtained from patient's own blood.⁽¹⁸⁾ Neutrophils, which express matrix-degrading enzymes that could destroy surrounding injured or healthy cells, are eliminated from the PRGF.⁽¹⁸⁾ Calcium chloride used during PRGF preparation acts as clot activator where it provides a sustained physiological release of the stored growth factors.⁽¹⁹⁾ In addition, it is possible to derive different formulations upon centrifugation, all have different therapeutic potentials.⁽²⁰⁾ Further, it is a safe cost-effective treatment.⁽¹⁸⁾

In general, PRGF as a platelet concentrate releases various growth factors that help to initiate the migration, proliferation and differentiation of mesenchymal stem cells which accelerate bone healing.⁽⁸⁾ When mixed with the different bone grafts, PRGF was reported to enhance the induction of osteoblasts and increase vascularization, this subsequently accelerated bone formation that resulted in upgraded healing periods of the bone tissue in previous studies.^(16,18,21) Yet its definitive effect on bone regeneration, used alone or combined with bone grafting materials in maxillary sinus augmentation procedures is still debatable.⁽¹⁰⁾

The present study was conducted to evaluate the possible assistance of using PRGF in conjunction with the xenogenic bone for maxillary sinus augmentation. The study sample comprised cases with RRH less than or equal 4 mm. Based on a systematic review, using the lateral window technique with a sinus graft for maxillary sinus augmentation is advocated when the RRH is less than 5 mm and dental implants in these cases are inserted 4 to 12 months after the augmentation process, depending on the graft material used.⁽³⁾

Therefore, in the present study, the direct lateral window technique was performed, and the graft was followed up for 6 months before implant insertion.

As stated by a recent systematic review, the most common complication of the lateral window technique is perforation of the Schneiderian membrane.⁽²²⁾ Although minor perforations occurred in 5 of 20 sinuses (25%) in the present study, no signs or symptoms of infection involving maxillary sinuses or grafts were observed in the follow-up period. In a recent similar study by Dragonas et al.,⁽¹⁷⁾ using PRGF mixed with bovine bone and lateral window sinus augmentation procedure, 36% of the sinuses included had Schneiderian membrane perforation during sinus augmentation; yet this was not associated with implant failure in their study. The membrane, being redundant on its superior reflection, is usually self-sealing.⁽²³⁾ Moreover, The PRGF acted like adhesive for the xenograft particles which being enriched with autogenous growth factors preventing their granules from spreading and facilitating the administration and adaptation into the sinus, it also helped to avoid the uncontrolled displacement of the graft materials into the sinus cavity in the case of unnoticed Schneiderian membrane perforation.⁽¹⁶⁾ This was realized in our study where the PRGF when added to the SmartBone graft created a sticky paste that facilitated the graft insertion and manipulation.

No other complication occurred in any of the patients at the host site during the 6 months post-operative follow up period, and normal wound healing was observed. This was in accordance with Del Fabro et al.⁽²⁴⁾ who concluded that using PRGF during maxillary sinus augmentation improved the clinical symptoms as pain, swelling, and bleeding as well as daily activities as mouth opening, chewing, speaking, and sleeping, during the first week postsurgical period.

To date, CBCT mainly has been used to assess the volume and the resorption rate of

the maxillary sinus graft with a high degree of accuracy. ⁽²⁵⁾ Regarding the bone height, the mean pre-operative RRH was 2.25 mm, the immediate postoperative TBH (RRH and GH) was 12.72 mm, and the postoperative 6 months follow up TBH was 11.04 mm. The increased bone height was 8.78 mm after 6 months period which was approximately four times the RRH. Dragonas et al. ⁽¹⁷⁾ reported mean initial ridge height of 3.9 mm and ridge height of 15.64mm after lateral window sinus augmentation. The bone height increase in their study was 11.73mm after 6 months from the graft surgery.

In the present study, there was a significant decrease in TBH between immediate and 6 months postoperative assessments with a mean decrease of 13.22 %. Studies used the lateral window technique showed variable results; Comuzzi et al. ⁽²⁶⁾ reported 9.7% mean change in the cranio-caudal graft dimension assessed using periapical radiographs. Kim et al. ⁽²⁷⁾ stated a significant decrease in bone height of approximately 6.85%, 6 months after surgery, assessed using panoramic radiographs. Using panoramic radiographs too, Hatano et al. ⁽²⁸⁾ reported a decrease in the overall bone graft height during the first 2–3 years postoperatively; however, only minor changes occurred subsequently. In general, respiration causes pneumatization and air pressure inside the maxillary sinus, ⁽²⁹⁾ this pressure may promote the sinus graft resorption leading to decrease in the bone height. ⁽³⁰⁾ It worth mentioning that, once graft remodeling has occurred during graft healing in the first six months, the graft dimensions tend to become stable with minimal changes over time. ⁽²⁶⁾ Despite using the same surgical approach, differences in the percentages of graft height decrease among studies may be related to the graft material used, time of implant placement, and the radiographic assessment method.

Regarding the bone width changes, there was a decrease in CBW, MBW and ABW after 6 months which was significant for the MBW (9.32 mm and

8.72 mm immediate postoperative and after 6 months respectively) where the mean width decreased by 0.6mm. This was consistent with Hu et al. ⁽³¹⁾ where the middle part of the ridge underwent a significant resorption (0.39 ± 1.12 mm), measured using CBCT scans, at both native and reconstructed bones before and after implant surgery. After ridge augmentation, the augmented bone particles undergo resorption and remodeling, together with the blood clot, the fibrin glue, and the soft tissue pressure all contribute to the reduction in the graft width. ⁽³²⁾ In the present study, the significant decrease in bone MBW, in our opinion, may be attributed to the site of the surgical procedure where the lateral osteotomy window was performed almost at the middle part of the ridge that was accompanied by the greatest postsurgical healing resorption.

It is worth noting that, since the RRH of the selected cases was less than or equal 4mm, therefore, the used graft material not only built bone height, but also established enough bone width required for implant support along the middle and apical bone height.

In the present study, GV showed a decrease after 6 months postoperatively (1.18 cm³ and 0.93 cm³ respectively) with a mean of 20.98% graft volume reduction; however, this decrease was statistically non-significant.

In a systematic review ⁽³³⁾, it was stated that bone substitutes as bovine bone used alone or in combination with other materials cause graft volume reduction of 18%-23% which is consistent with our study. Generally, volume changes of the maxillary sinus graft material occur due to sinus pneumatization and graft consolidation (vascularization and integration). ⁽³⁴⁾

A limitation of CBCT is the absence of standardized Hounsfield units as applied to CT imaging, the fact that makes it impossible to assess the actual bone density or even to compare the grey value changes of bone among individuals or in the

follow up within the same individual in a certain period.^(13,35)

In the present study, we tried to manage this by introducing a method for the follow up of the bone grey value changes via comparing the changes that occurred in a fixed anatomical structure (tooth enamel). This allowed calibration of the 6 months follow up bone grey value changes. By simple calculations, the percent change in the bone grey value after the 6 months follow up period was obtained.

In the present study, RRD was measured to assess the effect of the graft material on the normal bone. For the RRGD, this was measured at a selected region 4mm x10mm placed on the residual ridge and graft at the center of the planned implant site to evaluate the density of crestal 10 mm of trabecular bone, which is the most important area for osseointegration.⁽³⁶⁾

In our study, the bone grey value/density showed a significant increase where there was a 25.47 % increase in the RRD and 21.09 % increase in the RRGD. This denoted that together with improving the bone density at the graft region, PRGF may also have a remote regenerative effect of the on the normal bone.

To date, no radiologic studies have been done to evaluate the bone density changes using PRGF in maxillary sinus augmentation. Previous studies in this regard comprised histologic and histomorphometric analysis and they reported conflicting results; where three studies reported positive effect of the PRGF, which concurred with our results, and one study opposed. Anitua et al.⁽¹⁸⁾ reported higher than 25% of newly formed bone when a mixture of deproteinized bovine bone (DBB) and PRGF was used. Analysis of their histologic sections revealed newly formed vital bone rich in osteocytes and numerous blood

vessels. In a split mouth study on five patients using the same graft material, Anitua et al.⁽¹⁶⁾ revealed that this mix increased vascularization and bone formation after 5 months compared with DBB alone. Similar results were obtained by Elsharkawy et al.⁽²¹⁾ when xenograft (SmartBoneMicroships) was mixed with PRGF, their histologic specimens after 6 months healing period revealed well-formed new bone trabeculae lined by osteoblasts together with well vascularized marrow cavities which was similar to using autogenous bone only and superior to using xenograft alone. However, contradictory results were reported by Batas et al.⁽³⁷⁾ who stated that DBB mixed with PRGF did not enhance bone formation compared with DBB alone after 6 months post-operative follow up.

A limitation of our work is that it is a case series study, addressing the effect of PRGF on the sinus graft with no control group. The presence of control group where xenograft only is used would further clarify the actual effect of PRGF in maxillary sinus augmentation. In addition, the radiological findings needed to be correlated with histological findings to support the results. Long-term assessment of graft changes after sinus augmentation using PRGF is also recommended.

CONCLUSION

From the present study results it can be concluded that, PRGF combined with Smartbone xenograft improved insertion and manipulation of the graft into the sinus cavity after sinus membrane elevation using direct sinus lift surgery. The used graft material increased the bone height, established accepted middle and apical bone width for the implant support. In addition, the used graft greatly improved the bone density as measured by the grey value on CBCT scans both at the graft region and at the initial residual ridge denoting the remote effect of the PRGF on bone formation.

REFERENCES

- Pjetursson, B.E., Tan, W.C., Zwahlen, M., Lang, N.P. (2008): Systematic review of the success of sinus floor elevation and survival of implants inserted in combination with sinus floor elevation. *Clin Periodontol.*, 35 (Suppl 8): 216–240.
- Gandhi, Y. (2017): Sinus Grafts: Science and Techniques-Then and Now. *J Maxillofac Oral Surg.*, Jun;16(2): 135-144.
- Starch-Jensen, T., Jensen, J.D. (2017): Maxillary Sinus Floor Augmentation: a Review of Selected Treatment Modalities. *J Oral Maxillofac Res.*, Sep 30;8(3): e3.
- Pertici, G., Rossi, F., Casalini, T., Perale, G. (2014): Composite polymer-coated mineral grafts for bone regeneration: material characterisation and model study. *Annals of Oral & Maxillofacial Surgery*, Feb 14;2(1):4.
- Abuelnaga, M.S., Elbokle, N.N., Khashaba, M.M. (2018): Evaluation of custom made xenogenic bone grafts in mandibular alveolar ridge augmentation versus particulate bone graft with titanium mesh. *Egyptian Journal of Oral and Maxillofacial Surgery*, 9(2): 62-73.
- Marx, R. E., Carlson, E. R., Eichstaedt, R. M., Schimmele, S.R., Strauss, J.E., Georgeff, K.R. (1998): Platelet-rich plasma: Growth factor enhancement for bone grafts. *Oral Surg Oral Med Oral Pathol Oral Radiol Endod.*, 85: 638-46.
- Kevy, S.V., Jacobson, M.S. (2004): Comparison of methods for point of care preparation of autologous platelet gel. *J. Extra Corpor. Technol.*, 36 (1), 28–35.
- van den Dolder, J., Mooren, R., Vloon, A.P., Stoeltinga, P.J., Jansen, J.A. (2006): Platelet-rich plasma: quantification of growth factor levels and the effect on growth and differentiation of rat bone marrow cells. *Tissue Eng.*, Nov;12 (11): 3067–73.
- Solakoglu, Ö, Heydecke, G., Amiri, N., Anitua, E. (2020): The use of plasma rich in growth factors (PRGF) in guided tissue regeneration and guided bone regeneration. A review of histological, immunohistochemical, histomorphometrical, radiological and clinical results in humans. *Ann Anat.*, Sep;231:151528.
- Dragonas, P., Schiavo, J.H., Avila-Ortiz, G., Palaiologou, A., Katsaros, T. (2019): Plasma rich in growth factors (PRGF) in intraoral bone grafting procedures: A systematic review. *J Craniomaxillofac Surg.*, Mar;47(3):443-53.
- Scarfe, W.C., Farman, A.G., Sukovic, P. (2006): Clinical applications of cone-beam computed tomography in dental practice. *J Can Dent Assoc.*, 72(1):75-80.
- Ludlow, J.B., Ivanovic, M. (2008): Comparative dosimetry of dental CBCT devices and 64-slice CT for oral and maxillofacial radiology. *Oral Surg Oral Med Oral Pathol Oral Radiol Endod.*,106(1):106–14.
- Jacobs, R., Salmon, B., Codari, M., Hassan, B., Bornstein, M.M. (2018): Cone beam computed tomography in implant dentistry: recommendations for clinical use. *BMC Oral Health.*, May 15;18(1):88.
- Tyndall, D.A., Price, J.B., Tetradis, S., Ganz, S.D., Hildebolt, C., Scarfe, W.C., American Academy of Oral and Maxillofacial Radiology. (2012): Position statement of the American Academy of Oral and Maxillofacial Radiology on selection criteria for the use of radiology in dental implantology with emphasis on cone beam computed tomography. *Oral Surg Oral Med Oral Pathol Oral Radiol.*, 113(6):817-26.
- Tischler, M. (2008): In-office cone beam computerized tomography: Technology review and clinical examples. *Dent Today*, 27(6):102, 104, 106.
- Anitua, E., Prado, R., Orive, G. (2012): Bilateral sinus elevation evaluating plasma rich in growth factors technology: a report of five cases. *Clin Implant Dent Relat Res.*, 14(1):51- 60.
- Dragonas, P., Foote, M., Yu, Q., Palaiologou, A., Maney, P. (2020): One-year implant survival following lateral window sinus augmentation using plasma rich in growth factors (PRGF): a retrospective study. *Med Oral Patol Oral Cir Bucal.*, Jul 1;25(4):e474-e480.
- Anitua, E., Prado, R., Orive, G. (2009): A lateral approach for sinus elevation using PRGF technology. *Clin Implant Dent Relat Res.*, 11: e23-31.
- Tsay, R.C., Vo, J., Burke, A., Eisig, S.B., Lu, H.H., Landesberg, R. (2005): Differential growth factor retention by platelet rich plasma composites. *J Oral Maxillofac Surg.*, 63:521-28.
- Anitua, E., Sánchez, M., Orive, G., Andía, I. (2007): The potential impact of the preparation rich in growth factors (PRGF) in different medical fields. *Biomaterials*, 28: 4551-60.
- Elsharkawy, R.T., Khairy, N., Elsharkawy, R.T. (2019): A 6-month histologic and histomorphometric assessment

- of xenograft or xenograft combined with plasma rich in growth factors versus autogenous bone in sinus augmentation: A randomized controlled trial. *EDJ*, July; 65: 2067-76.
22. Testori, T., Weinstein, T., Taschieri, S., Wallace, S.S. (2019): Risk factors in lateral window sinus elevation surgery. *Periodontol 2000.*, Oct;81(1):91-123.
 23. Mellonig, J.T., Triplett, R.G. (1993): Guided tissue regeneration and endosseous dental implants. *Int J Periodontics Restor Dent.*, 13:109-19.
 24. Del Fabbro, M., Corbella, S., Ceresoli, V., Ceci, C., Taschieri, S. (2015): Plasma Rich in Growth Factors Improves Patients' Postoperative Quality of Life in Maxillary Sinus Floor Augmentation: Preliminary Results of a Randomized Clinical Study. *Clin Implant Dent Relat Res.*, 17:708-16.
 25. Umanjec-Korac, S., Wu, G., Hassan, B., Liu, Y., Wismeijer, D. (2014): A retrospective analysis of the resorption rate of deproteinized bovine bone as maxillary sinus graft material on cone beam computed tomography. *Clin Oral Implants Res.*, Jul;25(7):781-85.
 26. Comuzzi, L., Tumedei, M., Piattelli, A., Tartaglia, G., Del Fabbro, M. (2022): Radiographic Analysis of Graft Dimensional Changes after Lateral Maxillary Sinus Augmentation with Heterologous Materials and Simultaneous Implant Placement: A Retrospective Study in 18 Patients. *Materials (Basel)*, Apr 22;15(9):3056.
 27. Kim, D.H., Ko, M.J., Lee, J.H., Jeong, S.N. (2018): A radiographic evaluation of graft height changes after maxillary sinus augmentation. *J Periodontal Implant Sci.*, Jun 28;48(3):174-81.
 28. Hatano, N., Shimizu, Y., Ooya, K. (2004): A clinical long-term radiographic evaluation of graft height changes after maxillary sinus floor augmentation with a 2:1 autogenous bone/xenograft mixture and simultaneous placement of dental implants. *Clin Oral Implants Res.*, Jun;15(3): 339-45.
 29. Chanavaz, M. (1990): Maxillary sinus: anatomy, physiology, surgery, and bone grafting related to implantology—eleven years of surgical experience (1979–1990). *J Oral Implantol.*, 16:199-209.
 30. Hürzeler, M.B., Kirsch, A., Ackermann, K.L., Quiñones, C.R. (1996): Reconstruction of the severely resorbed maxilla with dental implants in the augmented maxillary sinus: a 5-year clinical investigation. *Int J Oral Maxillofac Implants*, 11:466-75.
 31. Hu, K.F., Lin, S.W., Lin, Y.C., Jeng, J.H., Huang, Y.T., Liu, P.F., Tseng, C.J., Chou, Y.H. (2021): Using Cone-Beam Computed Tomography to Assess Changes in Alveolar Bone Width around Dental Implants at Native and Reconstructed Bone Sites: A Retrospective Cohort Study. *J. Pers. Med.*, Oct 8;11(10):1011.
 32. Mordenfeld, A., Johansson, C.B., Albrektsson, T., Hallman, M. (2014): A randomized and controlled clinical trial of two different compositions of deproteinized bovine bone and autogenous bone used for lateral ridge augmentation. *Clin Oral Implants Res.* Mar;25(3):310-20.
 33. Shanbhag, S., Shanbhag, V., Stavropoulos, A. (2014): Volume changes of maxillary sinus augmentations over time: a systematic review. *Int J Oral Maxillofac Implants*, 29: 881–92.
 34. Tepper, G., Haas, R., Zechner, W., Krach, W., Watzek, G. (2002): Three-dimensional finite element analysis of implant stability in the atrophic posterior maxilla: a mathematical study of the sinus floor augmentation. *Clin Oral Implants Res.*, Dec;13(6):657-65.
 35. Pauwels, R., Jacobs, R., Singer, S.R., Mupparapu, M. (2015): CBCT-based bone quality assessment: are Hounsfield units applicable? *Dentomaxillofac Radiol.*, 44(1):20140238.
 36. Misch, C.E. (2007): *Contemporary Implant Dentistry*. 3rd ed. St. Louis: Mosby Elsevier.
 37. Batas, L., Tsalikis, L., Stavropoulos, A. (2019): PRGF as adjunct to DBB in maxillary sinus floor augmentation: histological results of a pilot split-mouth study. *Int J Implant Dent.*, Apr 1;5(1):14.