

GUIDED BONE REGENERATION USING PATIENT SPECIFIC TITANIUM VS. POLYETHER-ETHER KETON (PEEK) MESHES FOR HORIZONTAL MAXILLARY RIDGE AUGMENTATION: A HISTOMORPHOMETRIC STUDY

Ayman Gouda *^{ID}, Mohamed Mounir **^{ID}, Nada Noureldin***^{ID}
Omar El Khatib ***^{ID} and Samy Mounir ****^{ID}

ABSTRACT

Background: guided bone regeneration (GBR) is considered a predictable method when used to treat 3D alveolar defects prior to implant placement. The aim of this study was to compare the histomorphometric outcomes following GBR of 3D bone defects in the maxilla using a 3D patient specific milled titanium mesh vs. a 3D patient specific, milled PEEK meshes.

Material and methods: split mouth study was conducted on 8 patients (16 alveolar ridge) suffering from 3D maxillary alveolar defects. GBR was performed using an equal mixture of autogenous and xenogenic bone grafts loaded on either patient specific milled Titanium mesh (control group) or patient specific milled PEEK mesh (test group). Implant placement and core biopsied was carried out 6 months following alveolar ridge augmentation.

Results: Wound healing was uneventful for all cases except one patient in each group were the meshes were exposed. There was a statistically significant difference between both groups (P value = 0.000).

Conclusion: These results showed that patient specific milled Titanium meshes provide a superior osteoinductive and osteoconductive properties compared to milled PEEK meshes. yet further studies using larger sample size is needed.

KEYWORDS Titanium mesh, PEEK mesh, Guided bone regeneration, maxillary reconstruction

* Lecturer Oral and Maxillofacial Surgery, Faculty of Dentistry, Cairo University, Cairo, Egypt

** Associate professor Oral and Maxillofacial Surgery, Faculty of Dentistry, Cairo University and New Giza University, Cairo, Egypt

*** Lecturer Oral pathology, Faculty of Dentistry, Cairo University, Cairo, Egypt

**** Demonstrator Oral and Maxillofacial Surgery, Faculty of Dentistry, Cairo University, Cairo, Egypt

***** Associate Professor Oral and Maxillofacial Surgery, Faculty of Dentistry, October University for Modern Sciences and Arts (MSA) University, 6th of October City, Egypt

INTRODUCTION

The Rapid and promising developments in the fields of dental implants, surgical approaches and biomaterials have made osseointegrated implants to be a successful therapeutic procedure with highly predictable results that are widely used in modern dentistry in the oral rehabilitation of patients suffering from either total or partial tooth loss.¹ However, the presence of simultaneous alveolar defect may render the correct positioning of a prosthetically driven implant a challenging procedure that may compromise the optimal phonetic, functional and aesthetic outcomes.^{2,3}

Various surgical manoeuvres have been used to overcome such defects and facilitate implant placement. This includes, among others, guided bone regeneration (GBR) using either resorbable or non-resorbable barrier membranes that improves the predictability and long-term stability of newly formed bone.⁴ The scientific rationale for GBR is to facilitate the formation of new bone by placing a mechanical barrier that allows the incorporation of bone forming cells - osteoblasts - into the defect area while preventing surrounding connective tissue from invading the defect, thus excluding undesirable soft tissue cells from growing into the bony defects.⁵

Titanium meshes possess a proven track record of success in achieving predictable bone regeneration, this can be attributed to their rigidity, ability to conform to the defect's shape and maintain its shape overtime.^{6,7} On the other hand, the time required to shape the titanium mesh to fit the defect greatly increases the intraoperative time which is considered to be a major drawback of its use. In-order to overcome such problem, Titanium mesh can be either preshaped on a sterolithographic model (STL) of the patient's jaw or even a custom made 3D printed titanium devices can be used.^{8,9}

Poly-ether-ether-keton (PEEK) - a high-performance thermoplastic material- that was invented by a group of English scientists in 1978

and took about a decade to make its way into the medical field of vertebral surgery.¹⁰ PEEK has one of the best biocompatibility as it is non-allergic and non-toxic with highly stable chemical and physical properties.¹¹ These superior properties have enabled this material to gain a foothold in the field of oral and maxillofacial reconstruction.

The aim of this study was to compare the histomorphometric outcomes following GBR of 3D bone defects in the maxilla using a 3D custom-made milled titanium mesh vs. a 3D patient specific, milled PEEK meshes.

PATIENT AND METHODS

Study setting

The authors designed a uni-center randomized comparative clinical split mouth study that was conducted on 8 patients who had a bilateral severe 3D alveolar defect in the upper jaw following teeth loss. The patients' maxillary alveolar ridge should be less than 6 mm in height - measured from the alveolar crest to the basal bone- and less than 2 mm in width in order to be enrolled in this study. Patients with any systemic or local disease that may affect normal bone healing and predictable outcome were excluded from this study. Informed consents were obtained from all the participants only after the surgical procedures, risks and benefits were thoroughly explained to them. The study was granted the approval of the ethics and research committee at Cairo University.

Patient grouping and randomization

The patients were recruited from the outpatient clinic of the Oral and Maxillofacial Surgery Department - Cairo University. Patients were randomly divided into two equal groups who underwent 3D ridge augmentation using either a patient specific milled titanium mesh (control group) or a patient specific milled peek mesh (study

group) utilizing a 50:50 mixture of autogenous bone harvested from the anterior iliac crest of each individual patient and xenogenic bone (Bio-Oss, Geistlich Pharma, Switzerland). The choice of whether the alveolar defect (left or right) would be included in the study or control group was determined randomly using special computer software. Patients who participated in the study were provided with a total of 32 dental implants during the second stage surgery.

Preoperative Preparation

The patients' medical and dental histories were briefly checked, followed by clinical examination of all patients. Clinical measurements were performed both visually and with calipers to ensure the patient met the initial inclusion criteria before any further investigations (figure 1). The alveolar ridge measurements were evaluated radiographically using CBCT (figure 2) after excluding the existence of any lesions in them via a Periapical radiographs.

Virtual Planning and Manufacturing Techniques

DICOM files of all patients were imported in specialized software (mimics 19, Materialize NV, Belgium). A 2 mm thick perforated meshes of PEEK (for the study group) or Titanium (for the control group) were designed to cover all alveolar bone surfaces (buccal, crestal, and palatal) while leaving

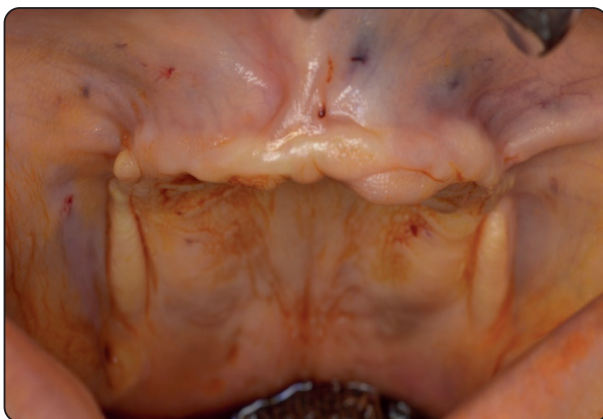

Fig. (1) Preoperative photo showing the presence of bilateral maxillary alveolar defects

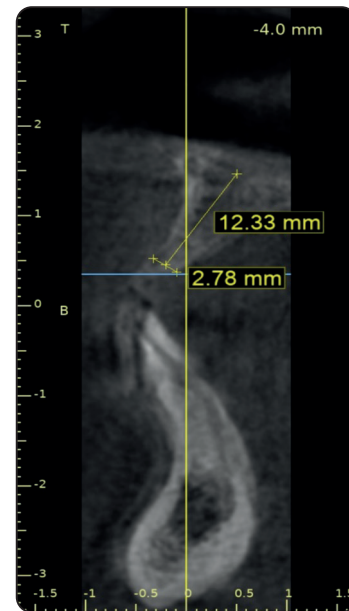

Fig. (2) showing pre-operative CBCT

the required space for the planned particulate graft site between the defective alveolar bone and the inner aspect of the designed mesh (Figure 3). Fabrication method was done using five axis milling machine from medically grade PEEK and titanium blocks to manufacture the final form of the customized mesh.

Titanium meshes were sterilized via autoclave; on the other hand, 2.4% glutaraldehyde (Cidex, Johnson & Johnson Co., Washington, DC) was used for PEEK grids applying cold sterilization technique.

Intraoperative Surgical Procedures (Both Groups)

All surgical procedures were carried out under general anaesthesia by a two teams approach. A Bovidine-Iodine surgical scrub (Betadine, Purdue Products L.P., Washington, DC) was used to scrub and drape the patients in the standard manner. Autologous particulate spongy bone harvesting was performed by the first team from the anterior iliac crest using trap door technique. A resorbable vicryl suture material was used to close the donor site in a layered fashion.

Intra-orally, the second team worked simultaneously to prepare the recipient site. Firstly, adequate haemostasis was achieved by injecting

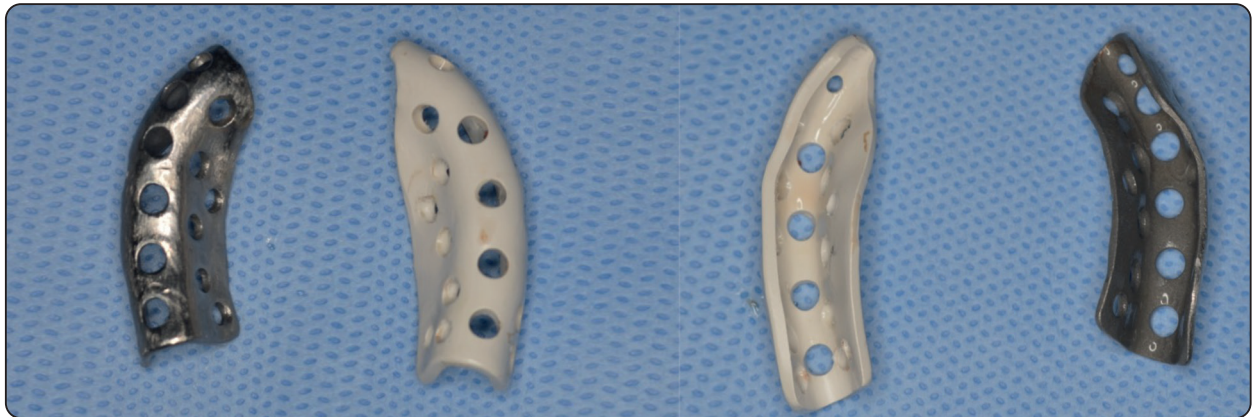


Fig. (3) Showing the smoothness of the outer and fitting surfaces of the milled Ti mesh and PEEK mesh

local anaesthesia (articaine 4%, septodont, France), then a full thickness labial and palatal mucoperiosteal flap was performed. The flap design included a paracrestal incision and then depending on defect size and location either a one or two vertical releasing incisions were used. Regardless of flap design, flap reflection was done until the entire facial cortical plate of the alveolar bone was exposed (Figure 4). Afterwards a small rounded surgical bur was used to induce bleeding points (decortication) to expose the underlying marrow to facilitate graft consolidation.

For both groups, the patient specific milled titanium and PEEK meshes were fixed on the palatal side of the defect in the control and test groups

respectively using 3-4 micro titanium screws. The 50:50 mixture bone graft was then applied in the gap between the fitting surfaces of the meshes and the facial surface of the alveolar defect (Figure 5), the meshes in both groups were then covered by Collagen membrane (Bio-Gide, Geistlich Pharma, Switzerland). In-order to ensure a tension free closure of the flap, a sharp 15 C surgical blade was used to perform periosteal scoring on its inner side. Flap closure was carried out by single interrupted sutures using prolene 4-0 (Ethicon US LLC, Washington, D.C). A week after surgery, patients were called to remove the suture. The wounds were carefully examined for any sign of inflammation or infection.

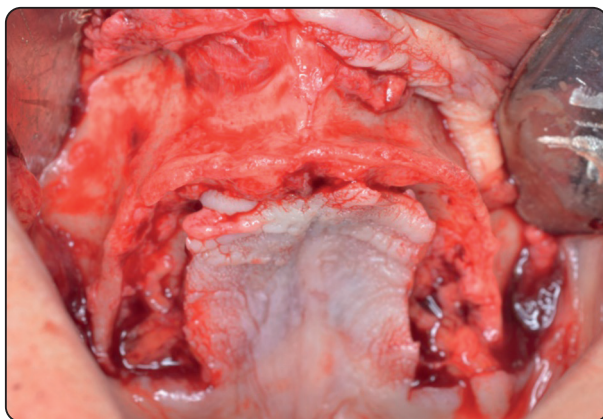


Fig. (4) Exposure of the entire facial and palatal aspects of the bilateral alveolar defects

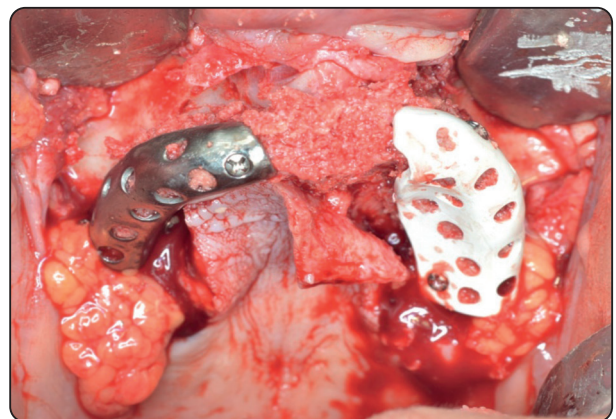


Fig. (5) 3D Customized Ti and Peek meshes fixed in place using 3-4 micro titanium screws with the bone graft filling the gap between them and the alveolar defects

Second-stage surgery (after 6 months)

A transcortical bone biopsies were collected from the grafted alveolar defects using a 3mm diameter trephine bur followed by implant placement (figure 6). Biopsy samples were fixed immediately in 10% buffered formalin.

Specimen processing

Specimen decalcification was performed by suspension in EDTA 10% solution for one week with regular change of the solution on daily base. The specimens were then dehydrated using ascending alcohol, followed by clearing in xylol. Then, it was embedded in paraffin wax to form a blocks that were sectioned longitudinally into a 5 micron thick sections using microtome. Sections were stained using Masson Trichrome stain for histomorphometric analysis.

Histomorphometric analysis

An image analyzer computer system (using software Leica QWin 500) was used to perform histomorphometric analysis. Newly formed bone areas and bone substitute remnants were measured as a percentage of the total area at a 40X power field.

Statistical analysis

SPSS12 (Statistical Package for the Social Sciences - IBM Corp., Armonk, NY) was used

to perform the statistical analysis. Data were represented as mean \pm standard deviation. Variables between the two groups were compared with each other using Student's t-test. If the p-value was less than 0.05, the results were considered to be statistically significant.

RESULTS

This split mouth study was conducted on 8 patients suffering from bilateral alveolar defects. A 3D correction of the alveolar defects were carried out using patient specific milled titanium mesh (for the control group) and patient specific milled PEEK mesh (study group). For both groups, the alveolar defects were grafted with an equal mixture of xenograft and autogenous bone.

Clinical results

None of the patients in either group reported any complications during the recovery period and the 6-month follow-up period except for one patient in each group who showed mesh exposure 16 and 30 days after surgery in the control group and the test group respectively (figure 7), however, both patients showed favourable response to saline irrigation and were completely cured by secondary intention. Implant insertion and core biopsies harvesting were carried out 6 months after defects augmentation which was confirmed by obtain a CBCT scan.

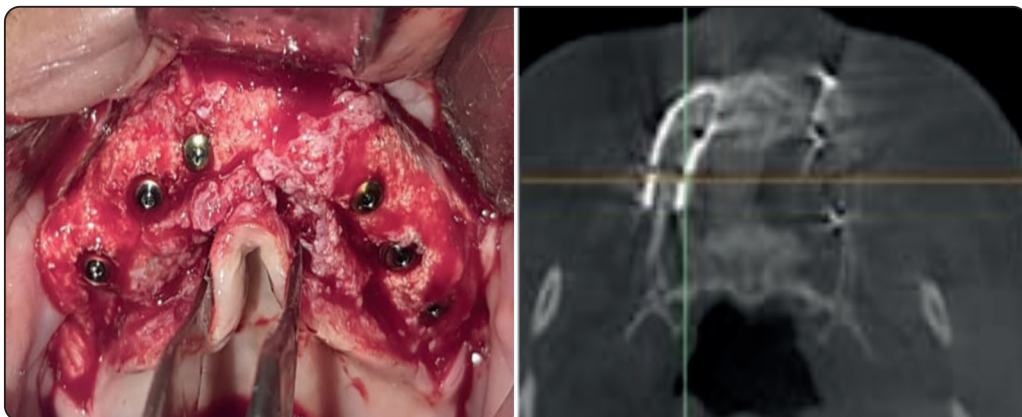


Fig. (6) Showing post-operative condition of the alveolar ridge both clinically and radiographically .

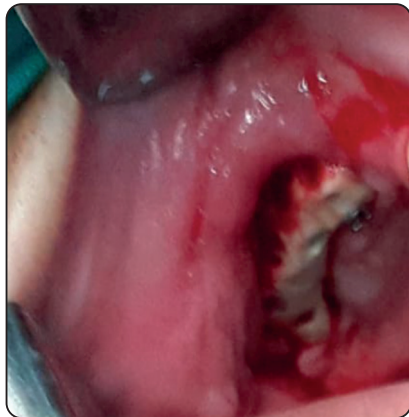


Fig. (7) Showing membrane exposure in PEEK group

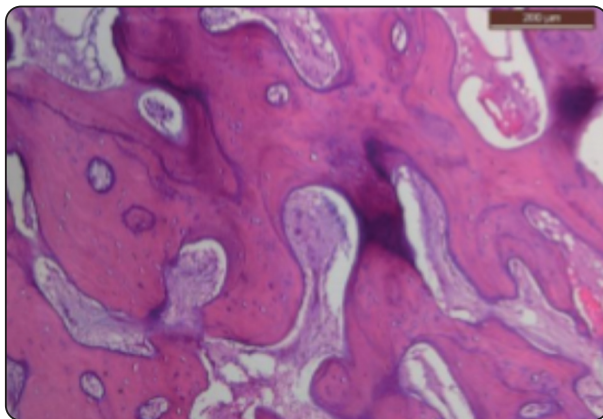


Fig. (8) Microscopic picture of core biopsy taken from Ti group showing trabeculae of lamellar bone with interfering bone marrow (magnification 40X)

Histological results

Type and quality of formed bone

The histological examination of the core biopsies obtained from both groups shows a noticeable difference in the bone quality between them. Mature and organized lamellar bone was detected in the control group (figure 8) while on the other hand the test group showed a less mature woven bone with interfering xenograft particles. (Figure 9)

Bone area percentage

The histomorphometric analysis of the samples (table 1) showed that the percentage of newly formed bone was higher in the Ti (control) group compared to that of the PEEK (study) group (26.25 ± 4.35 vs. 19.5 ± 2.38) (figure 10). The difference between the two groups was statistically significant (P value 0.000)

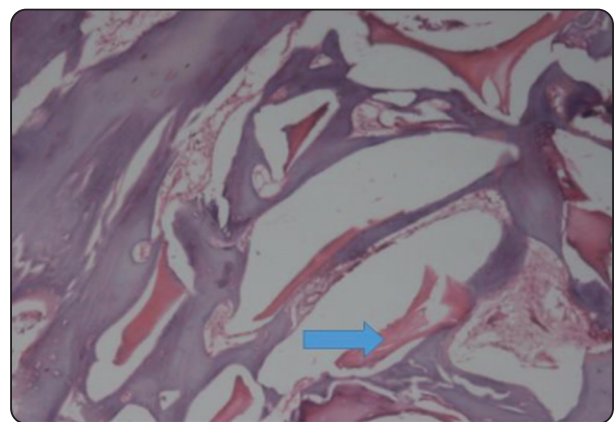


Fig. (9) microscopic picture of core biopsy taken from PEEK group showing trabeculae of woven bone with interfering xenograft particles (magnification 40X)

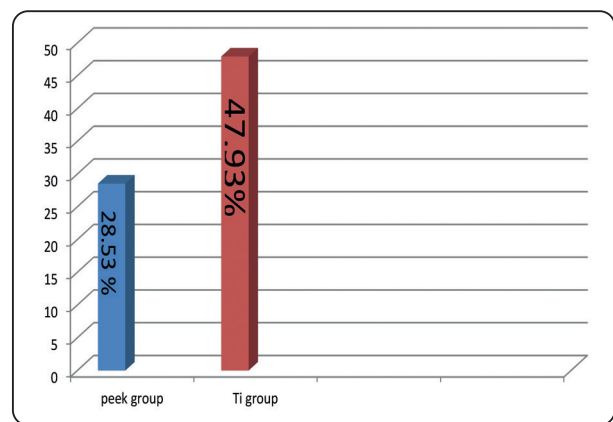


Fig. (10) Bar chart showing the mean of bone area percentage gained in both groups

TABLE (1): descriptive statistics and comparison between groups for bone area percentage (student's t-test)

Percentage of mature bone	Mean SD	SE	95% confidence interval	P value
Study	28.53 ± 5.92^b	1.87	(-24.06,-14.75)	0.000*
Control	47.93 ± 3.48^a	1.10		

Significance level $P < 0.05$, *significant

Means with different superscript letters are significantly different

DISCUSSION

Despite the fact that short implants can be used in the case of atrophic alveolar ridge, yet this approach usually fails to meet the criteria of the successful prosthetically driven implants that aim to restore the function and aesthetics of missing dentition.¹²⁻¹⁴ This explains the surgeons' ongoing search for different clinical solutions to overcome the obstacle of having inadequate alveolar bone through various surgical approaches that include, but not limited to, distraction osteogenesis, bone grafting procedures, guided bone regeneration (GBR) and the use of osteoinductive biomedical materials such as bone morphogenic protein and stem cells.^{15,16}

The limitations of distraction osteogenesis¹⁷ and the limited applicability of the osteoinductive approach in reconstructing alveolar defects¹⁸ renders GBR with or without bone grafting to be the most commonly used technique to restore an adequate alveolar bone volume with a high rate of success.¹⁹⁻²¹ The success of GBR depends on the presence of several properties in the used barriers such as: (1) biocompatibility, (2) cell occlusiveness, (3) ease of handling and (4) the ability to create and maintain space.²²

Ti mesh is one of the most commonly used barriers in GBR, although it took about two decades after its introduction in reconstructing large bony defects to find a foothold in the augmentation of maxillary and mandibular defects.^{23,24} The superior mechanical properties of the Ti mesh represented in its rigidity prevents its collapse and enables it to preserve the created space which provide excellent stability of the grafted bone which in turn increases the predictability of using Ti mesh in GBR.^{6,7}

According to the traditional method, Ti mesh was cut and shaped intra-operatively to correspond to the planned reconstructed alveolar ridge, this not only consumes a great deal of time but also results in sharp margins and edges that increase the risk of tissue injury. The latter – along with Ti stiffness-

explains the high incidence of Ti mesh exposure that may theoretically jeopardize the formation of new bone.^{25,26} However the smooth surface of the Ti mesh renders it less susceptible for bacterial infection.²⁷

Several attempts were made to overcome these drawbacks of Ti through pre-fitting the Ti mesh on a 3D stereolithographic model prior to the surgical procedure. Such approach showed a significant reduction in intraoperative time, yet Ti exposure remained a common occurrence even when this technique was applied.^{28,29}

In this study, we proposed a new method for shaping Ti mesh by building a 3D custom made mesh rather than shaping it on a 3D model. Again this resulted in a marked reduction in the intraoperative time; however Ti mesh exposure was still noticed in one patient from the Ti GROUP that was managed conservatively via daily saline irrigation and strict oral hygiene instructions. This incidence did not affect the final outcome as new bone formation was confirmed and dental implant was inserted in as planned. This confirms the findings of previous studies in which Ti mesh exposure was managed conservatively without the need for mesh removal owing to the smooth surface of the Ti mesh that makes bacterial infection less liable to occur.^{6,27} The occurrence of mesh exposure even while utilizing a 3d custom made mesh could be explained by the fact that although creating a 3D custom made Ti mesh may have overcome the sharp margins, yet the inherited stiffness of Ti mesh is still a factor that cannot be overlooked while dealing with causes of Ti mesh exposure.^{30,31}

Having a modulus of elasticity that is very close to that of the human cortical bone enabled PEEK to avoid stress shielding and ensure better healing of native bone compared to titanium. This feature along with its biocompatibility, and stability – both chemically and physically-has made PEEK an ideal material to be widely used in various medical fields

such as orthopedics, spinal surgery, trauma, dental implants and maxillofacial reconstruction.^{32,33}

In this study, a 3D custom made PEEK mesh was evaluated as a barrier in GBR procedure for the correction of alveolar defect. Mesh exposure was recorded in one patient that occurred 30 days postoperatively, however, this complication did not affect the final outcome as it was successfully managed conservatively-as in the Ti group- via daily saline irrigation and strict oral hygiene measures. This favourable response can be attributed to the smoothness of the external surface of the milled PEEK mesh.⁴

On comparing the percentage of newly formed bone areas in both the Ti and Peek group, the results showed a significant difference between both groups for the favour of the Ti group. This is consistent with the results of Ragni et al³⁴ in which they reported superior osteoinductive and osteoconductive properties of Ti spinal cages compared to those of Peek cages. The superior osteogenic properties observed in the Ti group can be contributed to Ti macroporosity which enables it to allow the diffusion of extracellular nutrients through the membrane.²⁷ In their study, Ragani et al³⁴ noticed a marked reduction in cell proliferation in the peek cage group which he attributed this to the formation of a biofilm layer that prevents bony growth into the cages.

CONCLUSION

These results showed that patient specific milled Titanium meshes provide a superior osteoinductive and osteoconductive properties compared to milled PEEK meshes. Yet further studies using larger sample size is needed.

Conflict of interest

No conflict of interest.

Source of funding: study was self-funded, no financial support was provided.

REFERENCES

1. Marco Rasia dal Polo , Pier-Paolo Poli , Davide Rancitelli , Mario Beretta , Carlo Maiorana: Alveolar ridge reconstruction with titanium meshes: A systematic review of the literature *Med Oral Patol Oral Cir Bucal*. 2014 Nov 1;19(6):e639-46. doi: 10.4317/medoral.19998.
2. De Santis D, Cucchi A, Rigoni G, Longhi C. Short implants with oxidized surface in posterior areas of atrophic jaws: 3- to 5-year results of a multicenter study. *Clin Implant Dent Relat Res*. 2015;17(3):442–52.
3. Malchiodi L, Ghensi P, Cucchi A, Pieroni S, Bertossi D. Peri-implant conditions around sintered porous-surfaced (SPS) implants. A 36-month prospective cohort study. *Clin Oral Implants Res*. 2015;26(2):212–9.
4. Mounir M, Shalash M, Mounir S, Nassar Y, El Khatib O. Assessment of three dimensional bone augmentation of severely atrophied maxillary alveolar ridges using prebent titanium mesh vs customized poly-ether-ether-ketone (PEEK) mesh: A randomized clinical trial. *Clin Implant Dent Relat Res*. 2019 Oct;21(5):960-967. doi: 10.1111/cid.12748. Epub 2019 Mar 20. PMID: 30895678.
5. Liu J, Kerns DG. Mechanisms of guided bone regeneration: a review. *Open Dent J*. 2014 May 16;8:56-65. doi:10.2174/1874210601408010056. PMID: 24894890; PMCID: PMC4040931.
6. Her S, Kang T, Fien MJ. Titanium mesh as an alternative to a membrane for ridge augmentation. *J Oral Maxillofac Surg*. 2012;70(4):803–10. 9.
7. Dal Polo Rasia M, Poli PP, Rancitelli D, Beretta M, Maiorana C. Alveolar ridge reconstruction with titanium meshes: a systematic review of the literature. *Med Oral Patol Oral Cir Bucal*. 2014;19(6):e639–46.
8. De Moraes PH, Olate S, Albergaria-Barbosa JR. Maxillary reconstruction using rhBMP-2 and titanium mesh. Technical note about the use of stereolithographic model. *Int J Odont*. 2015;9(1):149-152.
9. Sumida T, Otawa N, Kamata YU, et al. Custom-made titanium devices as membranes for bone augmentation in implant treatment: clinical application and the comparison with conventional titanium mesh. *J Craniomaxfac Surg*. 2015;43(10):2183-2188.
10. Skirbutis G, Dzingutė A, Masiliūnaitė V, Šulcaitė G, Žilinskas J. PEEK polymer's properties and its use in prosthodontics. A review. *Stomatologija*. 2018;20(2):54-58. PMID: 30531169.

11. Panayotov IV, Orti V, Cuisinier F, Yachouh J. Polyetheretherketone (PEEK) for medical applications. *J Mater Sci Mater Med.* 2016 Jul;27(7):118. doi: 10.1007/s10856-016-5731-4. Epub 2016 Jun 3. PMID: 27259708.
12. Malchiodi L, Giacomazzi E, Cucchi A, Ricciotti G, Caricasulo R, Bertossi D, Gherlone E. Relationship between crestal bone levels and crown-to-implant ratio of ultra-short implants with a microrough surface: A prospective study with 48 months of follow-up. *J Oral Implantol.* 2019;45(1):18–28.
13. Rossi F, Lang NP, Ricci E, Ferraioli L, Baldi N, Botticelli D. Long-term followup of single crowns supported by short, moderately rough implants - a prospective 10-year cohort study. *Clin Oral Implants Res.* 2018;29(12):1212–9.
14. Rocchietta I, Ferrantino L, Simion M. Vertical ridge augmentation in the esthetic zone. *Periodontol.* 2018; 77(1):241–55.
15. Egusa H, Sonoyama W, Nishimura M, Atsuta I, Akiyama K. Stem cells in dentistry – part I: stem cell sources. *J Prosthodont Res* 2012;56:151–65.
16. Egusa H, Sonoyama W, Nishimura M, Atsuta I, Akiyama K. Stem cells in dentistry – part II: clinical applications. *J Prosthodont Res* 2012;56: 229–48.
17. Le B, Rohrer MD, Prasad HS. Screw “Tent-Pole” grafting technique for reconstruction of large vertical alveolar ridge defects using human mineralized allograft for implant site preparation. *J Oral Maxillofac Surg* 2010;68:428–35.
18. Ferretti C, Ripamonti U, Tsidis E, Kerawala CJ, Mantalaris A, Heliotis M. Osteoinduction: translating preclinical promise into clinical reality. *Br J Oral Maxillofac Surg* 2010;48:536–9
19. Hammerle CHF, Jung RE, Feloutzis A. A systematic review of the survival of implants in bone sites augmented with barrier membranes (guided bone regeneration) in partially edentulous patients. *J Clin Periodontol* 2002;29:226–31.
20. Donos N, Kostopoulos L, Karring T. Alveolar ridge augmentation by combining autogenous mandibular bone grafts and non-resorbable membranes. *Clin Oral Implants Res* 2002;13:185–91.
21. Donos N, Kostopoulos L, Tonetti M, Karring T. Long-term stability of autogenous bone grafts following combined application with guided bone regeneration. *Clin Oral Implants Res* 2005;16:133–9.
22. Scantlebury TV. 1982-1992: a decade of technology development for guided tissue regeneration. *J Periodontol.* 1993 Nov;64(11 Suppl):1129-37. doi: 10.1902/jop.1993.64.11s.1129. PMID: 8295101.
23. Boyne PJ, Cole MD, Stringer D, Shafiqat JP. A technique for osseous restoration of deficient edentulous maxillary ridges. *J Oral Maxillofac Surg.* 1985 Feb;43(2):87-91. doi: 10.1016/0278-2391(85)90054-0. PMID: 3881576.
24. Boyne PJ. 1997. Reconstruction of the maxilla and mandible. Hanover Park, IL: Quintessence. p. 37–52
25. Machtei EE. The effect of membrane exposure on the outcome of regenerative procedures in humans: a meta-analysis. *J Periodontol.* 2001;72: 512–6. 11.
26. Corinaldesi G, Pieri F, Sapigni L, Marchetti C. Evaluation of survival and success rates of dental implants placed at the time of or after alveolar ridge augmentation with an autogenous mandibular bone graft and titanium mesh: a 3- to 8-year retrospective study. *Int J Oral Maxillofac Implants.* 2009; 24:1119–28.
27. Jegham H, Masmoudi R, Ouertani H, Blouza I, Turki S, Khattech MB. Ridge augmentation with titanium mesh: A case report. *J Stomatol Oral Maxillofac Surg.* 2017 Jun;118(3):181-186. doi: 10.1016/j.jormas.2017.03.001. Epub 2017 Mar 28. PMID: 28363847.
28. Cucchi A, Bianchi A, Calamai P, Rinaldi L, Mangano F, Vignudelli E, Corinaldesi G. Clinical and volumetric outcomes after vertical ridge augmentation using computer-aided-design/computer-aided manufacturing (CAD/CAM) customized titanium meshes: a pilot study. *BMC Oral Health.* 2020 Aug 5;20(1):219. doi: 10.1186/s12903-020-01205-4. PMID: 32758217; PMCID: PMC7409710.
29. Ciocca L, Fantini M, De Crescenzo F, Corinaldesi G, Scotti R. CAD-CAM prosthetically guided bone regeneration using preformed titanium mesh for the reconstruction of atrophic maxillary arches. *Comput Methods Biomech Biomed Engin.* 2013;16(1):26-32. doi: 10.1080/10255842.2011.601279. Epub 2011 Sep 19. PMID: 21923559.
30. Boudet C. Platelet-rich fibrin in mesh exposure repair. *Dentistry today.* 2014; 33(1):112–3. PubMed PMID: 24660440
31. Lizio G, Corinaldesi G, Marchetti C. Alveolar ridge reconstruction with titanium mesh: a three-dimensional evaluation of factors affecting bone augmentation. *Int J Oral Maxillofac Implants.* 2014;29(6):1354–63. PubMed PMID: 25397798

32. Rao, P.J.; Pelletier, M.H.; Walsh, W.R.; Mobbs, R.J. Spine interbody implants: Material selection and modification, functionalization and bioactivation of surfaces to improve osseointegration. *Orthop. Surg.* 2014, 6, 81–89. [CrossRef] [PubMed]
33. Kurtz, S.M.; Devine, J.N. PEEK biomaterials in trauma, orthopedic, and spinal implants. *Biomaterials* 2007, 28, 4845–4869. [CrossRef] [PubMed]
34. Ragni E, Perucca Orfei C, Bidossi A, De Vecchi E, Francaviglia N, Romano A, Maestretti G, Tartara F, de Girolamo L. Superior Osteo-Inductive and Osteo-Conductive Properties of Trabecular Titanium vs. PEEK Scaffolds on Human Mesenchymal Stem Cells: A Proof of Concept for the Use of Fusion Cages. *Int J Mol Sci.* 2021 Feb 27;22(5):2379. doi: 10.3390/ijms22052379. PMID: 33673509; PMCID: PMC7956826.