

EPIDEMIOLOGICAL STUDY OF FRONTAL SINUS FRACTURES AND OUTCOME OF MANAGEMENT

Hamada Abdel Hie Hamid Mahran*^{ID}, Mohamed Mostafa Elshamaa**^{ID},
Mohamed Yehia Abdelfattah***, Mohammed Nahed Attia Mohammed****^{ID},
Alaa Abdelhamid*****^{ID} and Samir Ali Elborolusy**^{ID}

ABSTRACT

Fractures of the frontal sinus usually occur due to high-velocity trauma. They constitute 5-15% of all facial fractures. The most common etiologies of frontal bone fractures are motor vehicle accidents, falls, falling objects, assaults, and penetrating objects. Treatment guidelines for frontal sinus fractures aren't universal since many factors should be considered before choosing a treatment plan for every patient. Complications of frontal sinus fractures are numerous and can be subdivided depending on chronicity, into acute (less than 6 weeks), and chronic (more than 6 weeks).

Patients and methods: A retrospective study included 256 patients diagnosed with frontal sinus fractures. Age ranges from 7 to 73 years, all cases were treated at Assiut University Hospitals. Records of all patients including demographic data, mechanism of injury, associated injuries, general condition, presence of CSF leakage, treatment plan, the result of treatment, and follow-up data for 5 years were collected from the maxillofacial outpatient clinic.

Results: Regarding the most common causes of frontal sinus fractures, road traffic accidents were the most common cause of frontal sinus fractures accounting for 125 patients (49%), followed by being hit by hard objects in 53 patients (21%), falling from height in 44 patients (17%), and other injuries in 34 patients (13%). For fracture patterns, About 121 (47.2%) patients had isolated frontal sinus fractures, 85 (22.6%) patients had other facial injuries, and 50 (19.5%) patients were polytraumatized with other orthopedic fractures. Moreover, 135 patients (53%) had anterior table fractures, 79 patients (31%) had both anterior and posterior table fractures and (16%) of patients had posterior table fractures. In this study, 95 patients (37.1%) were treated conservatively, and 161

* Lecturer of Maxillofacial Surgery, General Surgery Department, Faculty of Medicine, Assiut University, Egypt.

** Lecturer, Oral and Maxillofacial Surgery Department Faculty of Dentistry, Beni-Suef University, Egypt.

*** Lecturer, Oral Biology Department, Faculty of Dentistry, Beni-Suef University, Egypt.

**** Lecturer, Oral and Maxillofacial Surgery Department, Faculty of Dentistry, Assiut University, Egypt.

***** Professor, Department of Periodontology and Oral Medicine, Qassim College of Dentistry, Qassim University, Saudi Arabia.

patients (62.8%) had surgical interference. The surgical approach was bicoronal in 139 patients (54.2%), and trans laceration in 22 patients (8.5%). Open reduction and internal fixation using titanium mini plates and screws were done for 102 patients (39.8%), and reconstruction using titanium mesh was done for 59 patients (23%). Most common complication occurred following treatment of frontal sinus fractures was Chronic headaches in 51 patients (20%) whereas the least complication happened was Meningitis in only Two patients (0.7%).

Conclusion: Road traffic accidents are the most common etiology, so they can be significantly reduced by simple measures like compulsory seat belts and using a helmet. Great effort should be paid for proper evaluation and planning of the treatment for every patient. Teamwork is required for the proper management of such cases

KEYWORDS: Frontal sinus, Fracture.

INTRODUCTION

Frontal sinuses are located in the frontal bone, medial and superior to the orbits. They begin to develop around the age of 5 years and reach full development around the age of 12 years. They consist of bony anterior and posterior tables(walls). they drain medially, and inferiorly into the middle meatus or ethmoid infundibulum through the frontonasal recess or duct. The average size of the frontal sinus is 10 ml. ⁽¹⁾

Fractures of the frontal sinus usually occur due to high-velocity trauma. ⁽²⁾ they constitute 5-15% of all facial fractures. ^(3,4)

The most common etiologies of frontal bone fractures are motor vehicle accidents, falls, falling objects, assaults, and penetrating objects. ⁽⁵⁾

Gonty *et al.* ⁽⁶⁾, proposed a classification system for frontal sinus fractures, it depends mainly on the site of the fracture ;

Type 1: Fractures of the anterior wall

- Isolated to anterior table
- Associated with supraorbital rim fractures
- Accompanied by naso-ethmoidal complex fractures.

Type 2: Anterior and posterior walls fractures

- Linear fractures: (a) transverse and (b) vertical

- Comminuted fractures: (a) comprising both tables and (b) accompanied by naso-ethmoidal complex fracture.

Type 3: Posterior table fractures

Type 4: Very severe comminuted fractures of the entire frontal area, involving the ethmoid bone, orbit, and nasal base.

Treatment guidelines for frontal sinus fractures aren't universal. Also, many factors to be considered before choosing a treatment plan for every patient, such as the general condition of the patient, concomitant injuries, the presence of intracranial hemorrhage, the presence of CSF leak, and nasofrontal duct obstruction. Non-displaced anterior table fractures require conservative management, displaced anterior table fractures require open reduction and internal fixation of the fractured segments, comminuted anterior table fractures may require reconstruction using titanium mesh, non-displaced posterior table fractures to be treated conservatively, displaced posterior table fractures require cranialization of the frontal sinus with nasofrontal duct obliteration. ^(7,8)

Complications of frontal sinus fractures are numerous and can be subdivided depending on chronicity, into acute (less than 6 weeks), and chronic (more than 6 weeks). Complications include frontal sinusitis, pneumocephalus, cerebrospinal fluid leak, visual disturbances, meningitis, mucocele,

mucopyocele, osteomyelitis, brain abscess, poor aesthetics, extrusion of graft material, chronic frontal headaches, hypoesthesia of the supraorbital region, diplopia, and facial deformity. ⁽⁹⁾

PATIENTS AND METHODS

Study sample and design

A retrospective study included 256 patients diagnosed with frontal sinus fractures. Age ranges from 7 to 73 years, all diagnosed with frontal sinus

fractures either isolated frontal sinus fractures or associated with other injuries. All cases were treated at Assiut University Hospitals, from January 2008 to December 2018.

Records of all patients including demographic data, mechanism of injury, associated injuries, general condition, presence of CSF leakage, treatment plan, the result of treatment, and follow-up data for 5 years were collected from the maxillofacial outpatient clinic.

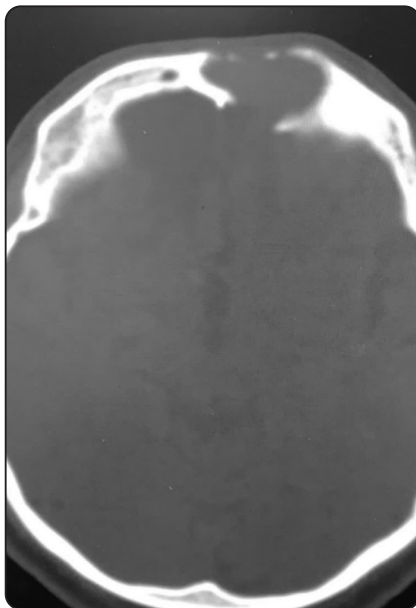


Fig. (1): Axial view, CT scan, showing left frontal mucocele

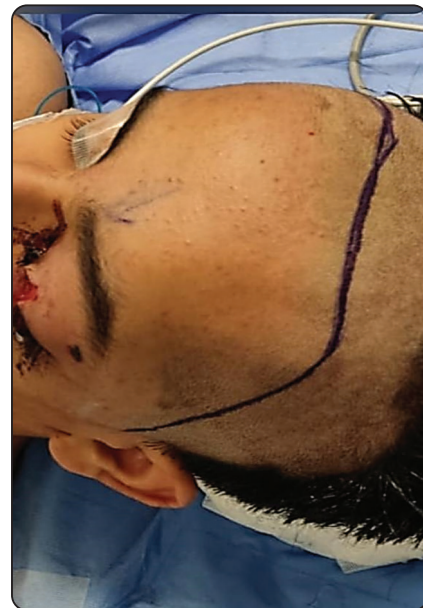

Fig. (2): Coronal approach for exposure of frontal sinuses

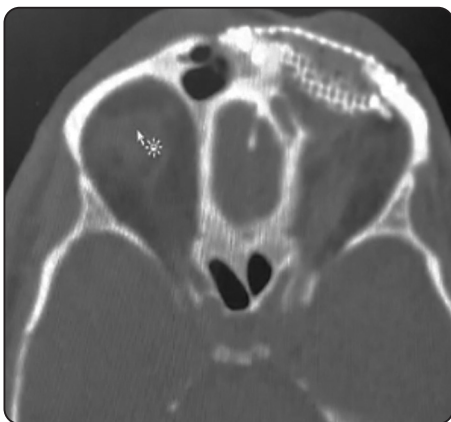


Fig. (3): Axial view, CT scan, showing reconstruction of the anterior wall of the frontal sinus and floor of the left frontal sinus using titanium mesh

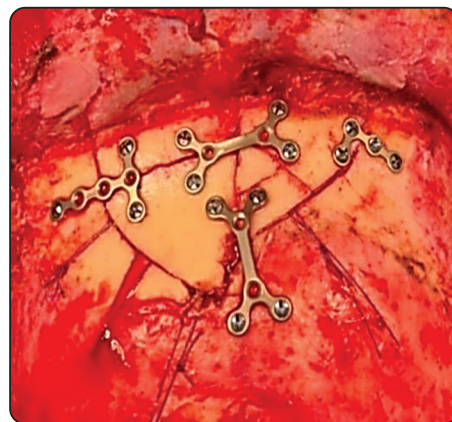


Fig. (4): Open reduction internal fixation of fractured anterior wall of frontal sinus using mini plates and screws

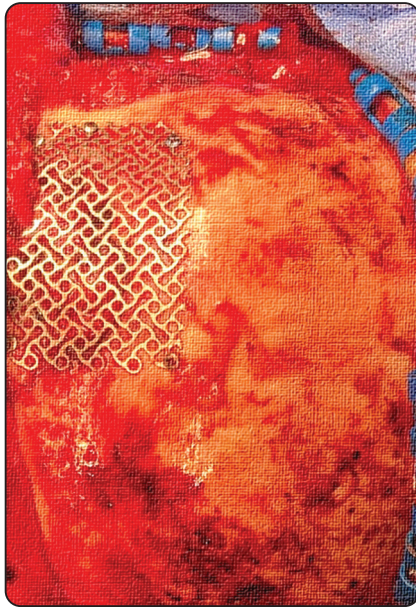

Fig. (5): Reconstruction of the anterior wall of the frontal sinus using titanium mesh and screws

The decision for surgical interference for frontal sinus fracture and its timing was taken by both neurosurgeon and maxillofacial surgeon, according to the hospital policy.

Exclusion criteria:

Cases with incomplete or missed data, a patient who refused our treatment plan, and patients who died before interference in the emergency section.

RESULTS

Data of the patients

In this study, the total number of patients presented to Assiut University Hospitals from January 2008 to December 2018, with frontal sinus fractures, were 256 patients. The male patients were 210 (82 %), and the female patients were 46 (18 %), with male to female ratio of 4:1. The ages of the patients in this study ranged from 7 To 73 years, with a mean of 40.

The study was approved by the Faculty of dentistry Beni-Suef University Research Ethics

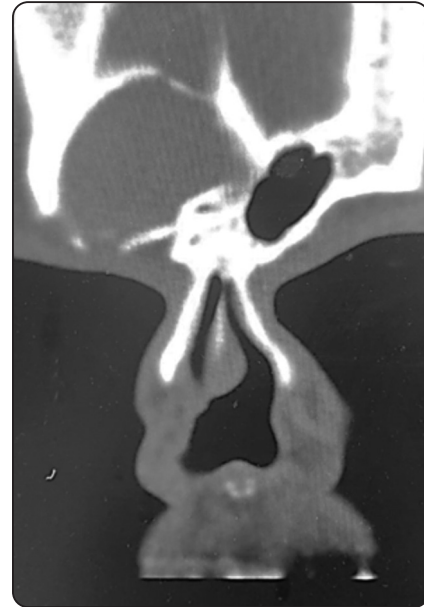

Fig. (6): Coronal view, CT scan, showing frontal mucocele

Committee (FDBSUREC) under the IORG #: IORG0010018..

Etiology

Road traffic accidents were the most common cause of frontal sinus fractures accounting for 125 patients (49 %), followed by being hit by hard objects in 53 patients (21%), falling from height in 44 patients (17%), and other injuries in 34 patients (13%).

Fracture pattern

About 121 (47.2%) patients had isolated frontal sinus fractures, 85 (22.6%) patients had other facial injuries, and 50 (19.5%) patients were polytraumatized with other orthopedic fractures. Moreover, 135 patients (53%) had anterior table fractures, 79 patients (31%) had both anterior and posterior table fractures and (16%) of patients had posterior table fractures.

Treatment modalities

In this study, 95 patients (37.1%) were treated conservatively, and 161 patients (62.8%) had

surgical interference. The surgical approach was bicoronal in 139 patients (54.2%), and trans laceration in 22 patients (8.5%). Open reduction and internal fixation using titanium mini plates and screws were done for 102 patients (39.8%), and reconstruction using titanium mesh was done for 59 patients (23%).

Complications

The patients were followed up for 5 years at the maxillofacial outpatient clinic for detection of the outcomes and complication rates.

Complications were recorded as follows:

- Chronic headaches in 51 patients (20%).
- Pneumocephalus in 34 patients (13.2%).
- Cerebrospinal fluid leak in 22 patients (8.5%).
- Meningitis in 2 patients (0.7%).
- Visual disturbances in 19 Patients (7.4%).
- Poor aesthetics in 3 Patients (1.1%).
- Frontal mucocele in 5 patients (1.9%).
- Osteomyelitis in 3 patients (1.1%).

DISCUSSION

Frontal sinus fractures are common facial injuries. The male populations were more affected than females with a ratio of 4:1, this is in agreement with other studies.^(10,11) The high ratio of affected males may be explained by the social patterns in the region of Upper Egypt, where women are not exposed to traffic accidents, outdoor activities, and industrial work.

In this study, the most common etiology was road traffic accidents accounting for 49% of patients, this is in agreement with other studies.^(12,13) The second and third causes were direct injury by hard objects for (21%) of patients and falling from height for (17%), this may be explained by the industrial character of the community, which includes a big number of

workers in this field, other causes including sports injuries, interpersonal violence account for (13%) of patients.

In our series, we found that (53%) of patients had isolated anterior table fractures, (31%) had both anterior and posterior table fractures, and (16%) had posterior table fractures. These findings are near to studies of Banica,⁽⁵⁾ Gonty,⁽⁶⁾ and Garbino.⁽¹⁷⁾

Frontal sinus fractures have a common interest between neurosurgeons, maxillofacial surgeons, and ENT surgeons, which is why the decision for surgical interference was combined between all. In this study (62.8%) of patients had surgical interference and (37.1%) of patients managed conservatively.

The presence of frontal laceration was used as an approach for intervention in (8.5%) of patients, and in (54.2%) of patients, we used the bicoronal flap. In (28.5%) of patients, we did complete cranialization of the frontal sinus, and in (34%) of patients we did open reduction internal fixation of the anterior table. These results are comparable to other studies, such as in the Pollock series, which reported (35%) cranialization and (38%) observation for all cases,⁽¹⁴⁾ and Sakas series, which reported (58%) surgical interference (42%) observation.⁽¹⁵⁾

In this study, 19 patients (7.4%) had visual disturbances, in the form of diplopia, blurred vision, retinal detachment, lens displacement unilateral vision loss, or the most devastating complication complete blindness in 2 patients (0.7%). Visual complications can be attributed to associated orbital roof fractures, fracture of the lesser wing of the sphenoid, post-traumatic orbital volume discrepancies, orbital hematoma, and orbital apex syndrome.⁽¹⁶⁾

Of the most serious complications of the frontal sinus, fractures are cerebrospinal fluid leakage. it is presented by CSF rhinorrhea, detection of B-2-transferrin is confirmatory. (17) In most situations

it is transient, but sometimes it is persistent and requires sinus cranialization and repair of the dura. Unrecognized or untreated CSF leak can lead to meningitis, encephalitis, and subdural abscess. (18) In this study, 22 patients (8.5%) were reported to have CSF leak, 7 patients healed spontaneously, 9 patients were managed endoscopically by ENT surgeons, 6 patients were managed surgically by cranialization of the frontal sinus, dural repair, and obliteration of the nasofrontal duct.

Several intracranial complications can be encountered with frontal sinus fractures including pneumocephalus, intracranial hemorrhage, brain abscess, meningitis, and chronic headache. (19)

In this study, 51 patients (20%) reported chronic headaches, no frank cause could be detected for them, and all were managed conservatively by medications. 34 patients (13.2%) reported pneumocephalus, all managed conservatively with spontaneous resolution. 2 patients (0.7%) had meningitis, one of them had 2 days post-operative meningitis, and the other one had meningitis one year postoperative. Both of them were managed conservatively, using IV antibiotics, and resolved. Chen, (16) in his series, mentioned that (1.3%) of patients had meningitis, the lower percentage in our series could be due to the routine administration of IV antibiotics for all patients and our teamwork for proper management.

Moreover, in this study Three patients (1.1%) had osteomyelitis of the frontal bone and skull base, all referred to ENT for management endoscopically, two patients improved, and the other patient died 2 days after endoscopic sequestrectomy.

Mucocele is defined as a benign, expansile, cystic mass resulting from retention of secretions, in cases where drainage is blocked. (20) Mucoceles commonly occur in the frontal and ethmoidal sinuses, whereas mucoceles in maxillary and sphenoidal sinuses are relatively rare. Mucocele can erode surrounding bone and can spread intracranially, and intraorbital. It can develop years after the original frontal sinus

trauma. The most common signs and symptoms of frontal sinus mucocele are frontal swellings, pain, exophthalmos, diplopia, and nasal congestion depending on the site and size of the mucocele. (21)

In this study, five patients (1.9%) had frontal sinus mucoceles at one, one, three, and four years of follow-up. All patients had clinical manifestations confirmed by a CT scan. Three of these patients had a history of surgical treatment, but the other 2 patients had a history of conservation, meaning that a blocked nasofrontal duct can be associated with minimally displaced fractures. Patients were referred to the ENT department, for endoscopic drainage, which was successful for 4 patients, but one patient was operated on surgically by a mixed team of neurosurgeons, maxillofacial, and ENT surgeons, through a bicoronal approach.

No cases diagnosed with brain abscess may be explained by our protocol of starting IV antibiotics for all cases of frontal sinus fractures.

CONCLUSION

Frontal sinus fractures are uncommon facial fractures. Road traffic accidents are the most common etiology, so they can be significantly reduced by simple measures like compulsory seat belts and using a helmet. Great effort should be paid for proper evaluation and planning of the treatment for every patient. Teamwork is required for the proper management of such cases.

REFERENCES

1. Cakur B, Sumbullu MA, Durna NB. Aplasia and agenesis of the frontal sinus in Turkish individuals: a retrospective study using dental volumetric tomography. *Int J Med Sci.* 2011 Apr 08;8(3):278-82.
2. Schultz JJ, Chen J, Sabharwal S, Halsey JN, Hoppe IC, Lee ES, et al. Management of frontal bone fractures. *J Craniofac Surg* 2019; 30:2026-2029.
3. Banks C, Grayson J, Cho DY, Woodworth BA. Frontal sinus fractures and cerebrospinal fluid leaks: a change

- in surgical paradigm. *Curr Opin Otolaryngol Head Neck Surg* 2020; 28:52-60.
4. Dedhia RD, Morisada MV, Tollefson TT, Strong EB. Contemporary management of frontal sinus fractures. *Curr Opin Otolaryngol Head Neck Surg* 2019; 27:253-260.
 5. Banica B, Ene P, Dabu A, Ene R, Cirstoiu C. Rationale for management of frontal sinus fractures. *Maedica(Bucur)*. 2013 Sep;8(4):398-403.
 6. Gonty AA, Marciani RD, Adornato DC. Management of frontal sinus fractures: a review of 33 cases. *J Oral Maxillofac Surg*. 1999 Apr;57(4):372-9; discussion 380-1.
 7. Jeyaraj P. Frontal Bone Fractures and Frontal Sinus Injuries: Treatment Paradigms. *Ann Maxillofac Surg*. 2019 Jul-Dec;9(2):261-282.
 8. Vincent A, Wang W, Shokri T, Gordon E, Inman JC, Ducic Y. Management of Frontal Sinus Fractures. *Facial Plast Surg*. 2019 Dec;35(6):645-650.
 9. Dalla Torre D, Burtscher D, Kloss -Brandstatter A, Rasse M, Kloss F. Management of frontal sinus fractures-treatment decision based on metric dislocation extent. *J Craniomaxillofac Surg*. 2014 Octo;42(7):1515-9.
 10. Kamath RAD, Bharani S, Hammannavar R, Ingle S, Shah AG. Maxillofacial trauma in Central Karnataka, India: an outcome of 95 cases in a Regional Trauma Care Centre. *Craniomaxillofac Trauma Reconstr* 2012; 5:197-204.
 11. Kar IB, Mahavoi BR. Retrospective analysis of 503 maxillofacial trauma cases in Odisha during the period of Dec 04-Nov 09. *J Maxillofac Oral Surg* 2012; 11:177-181.
 12. Al-Khateeb T, Abdullah FM. Craniomaxillofac injuries in the United Arab Emirates: a retrospective study. *J Oral Maxillofac Surg* 2007; 65: 1094-1101.
 13. Mendes M, Borba M, Sawazaki R, et al. Maxillofacial trauma and seat belt: a 10 year-retrospective study. *Oral Maxillofac Surg* 2013; 17:21-25.
 14. Pollock RA, Hill JL, Davenport DL, Snow DC, Vasconez HC. Cranialization in a cohort of 154 consecutive patients with frontal sinus fractures (1987-2007): review and update of a compelling procedure in the selected patient. *Ann Plast Surg*. 2013 Jul;71(1):54-9.
 15. Sakas DE, Beale DJ, Ameen AA et al. Compound anterior cranial base fractures: classification using computerized tomography scanning as a basis for selection of patients for dural repair *J Neurosurgery* 1998 8803471-477. Doi: 10.3171/ Jns. 1998.88.3.0471
 16. Chen KT, Chen CT, Mardini S, Tsay PK, Chen YR. Frontal sinus fractures: a treatment algorithm and assessment of outcomes based on 78 clinical cases. *Plast Reconstr Surg* . 2006; 118:457-468.
 17. Rohrich RJ, Hollier LH. Management of frontal sinus fractures: changing concepts. *Clin Plast Surg* . 1992; 19:219-232.
 18. Rice DH. Cerebrospinal fluid rhinorrhea: diagnosis and treatment. *Curr Opin Otolaryngol Head Neck Surg*. 2003; 11:19-22.
 19. Garbino G, Roccia F, Benech A, Caldarelli C. Analysis of 158 frontal sinus fractures: current surgical management and complications. *J Craniomaxillofac Surg*. 2000; 28:133-139.
 20. Carvalho BV, Lopes CC, Correa JB et al. Typical and atypical presentations of paranasal sinus mucocele at computer tomography. *Radiol Bras*. 2013;46(06):372-375.
 21. Topdag M, Iseri M, Sari F, Erdogan S, Keskin IG. Paranasal sinus mucoceles: our clinical experiments. *Int J Clin Exp Med*. 2015;8(10):18518-18522.