

The diagnostic function of office hysteroscopy and three-dimensional (3D) endometrial volume measurement in the evaluation of women with perimenopausal bleeding

Mohamed Ezz El-Din Mohamed Nafad^{1,*} M..B.B.Ch, Abd El-Moneam Mohamed Zakaria¹ MD and Ahmed Taha Abdel Fattah¹ MD.

*Corresponding Author:

Mohamed Ezz El-Din Mohamed Nafad
Dr.m.ezz85@gmail.com

Received for publication June 11, 2022; Accepted December 31, 2022; Published online December 31, 2022.

doi: 10.21608/aimj.2023.144105.1986

Citation: Mohamed E. , Abd El-Moneam M. and Ahmed T. The diagnostic function of office hysteroscopy and three-dimensional (3D) endometrial volume measurement in the evaluation of women with perimenopausal bleeding. AIMJ. 2022; Vol.3-Issue12 : 154-159.

¹Obstetrics and Gynecology Department, Faculty of Medicine, Al-Azhar University Cairo, Egypt.

ABSTRACT

Background: In the peri- and postmenopausal years, abnormal uterine bleeding (AUB) is the most prevalent reason for gynecological appointments.

Aim of the work: To detect the role of office hysteroscopy and three-dimensional (3D) endometrial volume measurement in the evaluation of women with perimenopausal bleeding.

Patients and methods: This study was conducted at Al-Azhar University in Al Hussein university hospital from March 2017 to October 2019 Obstetrics and Gynecology department. The research included 100 studied cases complaining of perimenopausal bleeding at the outpatient clinic.

Results: hyperplasia followed by complex endometrial hyperplasia and only 1 case of endometrial carcinoma was discovered. In group 2 most common endometrial histopathology was discovered proliferative endometrium then secretory endometrium and 6 cases of atrophic endometrium.

Conclusion: In cases of perimenopausal bleeding, this study demonstrated the diagnostic value of office hysteroscopy and three-dimensional (3D) ultrasonographic endometrial volume measurement, and showed that combining those 2 modalities of diagnosis had led to increase the ability & sensitivity of diagnosis and With perimenopausal women with irregular uterine bleeding, the capacity to rule out significant intrauterine disease to minimize further operative interventions, especially for surgically high-risk patients.

Keywords: Diagnostic; Endometrial volume; Office hysteroscopy; Perimenopausal bleeding.

Disclosure: The authors have no financial interest to declare in relation to the content of this article. The Article Processing Charge was paid for by the authors.

Authorship: All authors have a substantial contribution to the article.

Copyright The Authors published by Al-Azhar University, Faculty of Medicine, Cairo, Egypt. Users have the right to read, download, copy, distribute, print, search, or link to the full texts of articles under the following conditions: Creative Commons Attribution-Share Alike 4.0 International Public License (CC BY-SA 4.0).

INTRODUCTION

Abnormal uterine bleeding (AUB) is the most prevalent reason for gynecological appointments in women in their peri- and postmenopausal years, accounting for roughly 15% of all visits. An endometrial pathology (polyps, submucous myomas, endometrial hyperplasia, and endometrial carcinoma) should always be suspected, and evaluation appears to be required, aside from systemic, iatrogenic, or hormonal age-related reasons.¹ Endometrial pathology can now be diagnosed and treated using well-established procedures such as clinical examination, transvaginal ultrasound (TVS), 3D ultrasonography, and hysteroscopy.²

Endometrium which is the inner mucous uterine layer is soft, spongy, and composed of tissue resembling embryonic connective tissue. The

endometrial epithelium is columnar and gland forming (tubular glands that open into the cavity of the uterus) with a specialized spindle shape stromal cells (Progenitors of decidual cells).³

The secretory and ciliated cells make up the endometrial epithelium, and they are easily distinguished using scanning electron microscopy (SEM). During the cycle, the shape of ciliated cells does not change substantially. Secretory cells, on the other hand, have microvilli (MV) and undergo hormone-dependent changes.⁴

During the secretory phase, the concentration of these ciliated cells at gland openings, as well as the ciliary beat pattern, influence the mobilization and dispersion of endometrial secretions. Cell surface MV are cytoplasmic extensions that serve to expand the active surface of cells and are also a response to estradiol.⁵

3D ultrasonic tomography combines the benefits of ultrasound, such as safety, ease of use, and low cost (in comparison to MRI and CT), with the benefit of the third dimension. Traditionally, the investigator's brain is responsible for generating a 3D image from 2D parts.⁶

The storage of high-quality two-dimensional images on a computer with a powerful software package for this purpose is required for the generation of three-dimensional ultrasound images. With each rotation of the transducer, up to 240 pictures, spaced 1 mm apart, can be stored. The computer will include a volume in the shape of a truncated cone, saved on a hard disc after the storage is complete.⁷

The main benefit of hysteroscopy is that it can detect intracavitary abnormalities like leiomyomas and polyps that transvaginal sonography or endometrial samples could miss.⁸ In fact, several experts recommend hysteroscopy as the primary diagnostic method for irregular uterine bleeding. It is very accurate in detecting endometrial cancer, although it is less accurate in detecting endometrial hyperplasia. As a result, some doctors advise combining hysteroscopy with endometrial biopsy or curettage.⁹

Endometrial volume measurement is more accurate than endometrial thickness measurement in diagnosing endometrial disease in women with postmenopausal hemorrhage.¹⁰ Furthermore, 3D US enhanced ultrasound diagnostic accuracy in determining myometrial and cervical invasion in endometrial cancer.¹¹

The goal of the study was to see how office hysteroscopy and three-dimensional (3D) ultrasonographic measurements of endometrial volume affected endometrial volume and if those methods could predict malignant conditions and hyperplasia of the endometrium and if they could exclude serious intrauterine pathology in perimenopausal women with irregular uterine bleeding to minimize further operative interventions, especially for surgically high-risk patients or not?

PATIENTS AND METHODS

This research was conducted at Al Azhar University in Al Hussein university hospital from March 2017 to October 2019 Obstetrics and Gynecology department. The research includes a hundred cases complaining of perimenopausal bleeding at the outpatient clinic.

Inclusion criteria: Perimenopausal bleeding, Age 40-50 years, having any type of bleeding for more than 3 months, such as menorrhagia or metrorrhagia, not known to have general causes of bleeding, no Organic Uterine or ovarian lesions, and Bleeding is not caused by a complication of contraception.

Exclusion criteria: General causes of bleeding, irregular use of hormones, using any type of I.U.D, known to have a contraindication for office hysteroscopy e.g. cervical stenosis, Any abnormal lesion that alters the endometrium during pregnancy.

After selection of all cases, They are subjected to a thorough history taking and general examination, as well as a local pelvic examination, office

hysteroscopy, transvaginal 2D pelvic ultrasound, 3D endometrial volume measurement, and then dilatation and curettage (D&C) or hysteroscopic guided biopsy for focal endometrial lesions under general anesthesia after a written consent obtained and pathological examination of the specimens obtained.

Patients were classified into 2 groups according to the results of pathological examination of the specimens obtained by D&C. Group 1 patient with hyperplasia and malignant conditions. Group 2 patients with normal endometrium or other causes of abnormal uterine bleeding.

Preoperative evaluation of both groups involved the following:

History: A systematic history of age, parity, menstrual and obstetric history, hormone treatment, hypertension, diabetes, and current anticoagulant usage acquired utilizing a validated study technique.

Examination: General including blood pressure and pulse and temperature - Pelvic and bimanual examination.

Examining ultrasound images and videotapes, as well as analyzing ultrasound images and videotapes: Toshiba Femi O 5 (Toshiba Medical Solutions Inc., Ultrasound Division, Japan) equipped with a 6.5 MHz transvaginal transducer was used for transvaginal 2D sonography. Endometrial volume acquisition in 3D was performed utilizing a GE Voluson 730 Expert ultrasound system (GE Healthcare, Zipf, Austria) with a transvaginal 5- to 9-MHz volume transducer up to 2 days before curettage. The examinations were saved digitally on an internal disc drive for use in the virtual organ computer-aided analysis (VOCAL) program for further measures. The polygonal area's 2D outlines in each plane can be defined either automatically or manually. There are three different planes in which measurements can be taken (A, B, and C). A plane, the longitudinal view, was used in this study.

Hysteroscopy: All patients have a diagnostic hysteroscopy in the outpatient clinic using the hysteroscopic approach hysteroscopy was used in this study is Karl Storz (Germany). The light source used in this study was a Circon Acmi G71A/Germany metal halide automated light source with a 150 Watt lamp.

Attaching plastic bags of saline or glycine solution to the uterus provides continual uterine distention.

Under manometric control, the infusion pressure was raised to 100-120 mm HG using a pneumatic cuff. A single-chip video was used to monitor the procedure, and the image was shown on a monitor that was viewable to the operator. With a focal length ranging from f 70 to f 140, the camera is either a Karl Storz Germany or a Wisap Autocontrol Germany.

Hysteroscopic picture which appears on the monitor is transmitted through the optic from the camera which is fitted on the eyepiece where the panoramic diagnostic hysteroscopy could be performed with better visualization and accuracy.

Analytical statistics: When statistically suitable, data were presented in terms of range, mean standard deviation (SD), frequencies (number of cases), and relative frequencies (percentages). The Student t-test for independent samples when data are normally distributed and the Mann Whitney U test for independent samples when data are not normally distributed are used to compare quantitative variables between study groups. The Chi square (X²) test was

used to compare categorical data. When the anticipated frequency is less than 5, an exact test is employed instead. Statistical significance is defined as a probability value (p value) less than 0.05. Microsoft Excel version 7 (Microsoft Corporation, NY, USA) and SPSS (Statistical Package for the Social Science; SPSS Inc., Chicago, IL, USA) version 13 for Microsoft Windows were used to do all statistical computations.

RESULTS

This research was conducted at Al Azhar University, Al Hussein hospital Obstetrics and Gynecology unit from March 2017 to October 2019. The study included 100 patients complaining of perimenopausal bleeding at the outpatient clinic. Patients were selected according to the criteria mentioned before and they were divided into 2 groups: Group 1: cases with hyperplasia and malignant conditions. Group 2: patients with normal endometrium or other causes of abnormal uterine bleeding

Variables	1stGroup (N=50.0)	2ndGroup(N=50.0)	P value
Age (years)	49.4 ± 1.22	48.57 ± 1.54	0.122 NS
Parity	3.12 ± 1.6	3.04 ± 1.41	0.713 NS

Table 1: Age and Parity in the two groups

There were no statistically significant differences between the two groups as regard age and parity. Table (1)

	1stGroup	2ndGroup	3rdGroup
Menorrhagia	20	11	31
Metrorrhagia	11	10	21
Menometrorrhagia	13	15	28
Polymenorrhoea	6	14	20
Total	50	50	100

Table 2: Bleeding pattern in both groups.

Menorrhagia was the most common bleeding pattern, followed by menometrorrhagia, metrorrhagia, and polymenorrhoea. Table (2)

Type of endometrial histopathology			
Group 1	Type of endometrial histopathology	13	62%
	Complex endometrial hyperplasia	18	36%
	Endometrial carcinoma	1	26%
Group 2	Endometrial carcinoma	28	56%
	Secretory endometrium	16	32%
	Atrophic	6	12%

Table 3 : Number of different endometrial histopathology In both groups

In group 1 Simple endometrial hyperplasia was the most frequent endometrial histopathology, followed by complicated endometrial hyperplasia and only 1 case of endometrial carcinoma was discovered. In group 2 most common endometrial histopathology was discovered proliferative endometrium then secretory endometrium and 6 cases of an atrophic endometrium. Table (3)

Endometrial thickness (mm)	1 st Group (N=50.0)	2ndGroup(N=50.0)	P value
	15.37 ± 2.27	11.90 ± 2.97	0.001 S

S=significant

Table 4: Endometrial thickness in both groups

There was a high statistical significance as regards endometrial thickness in comparison to both groups. Table (4)

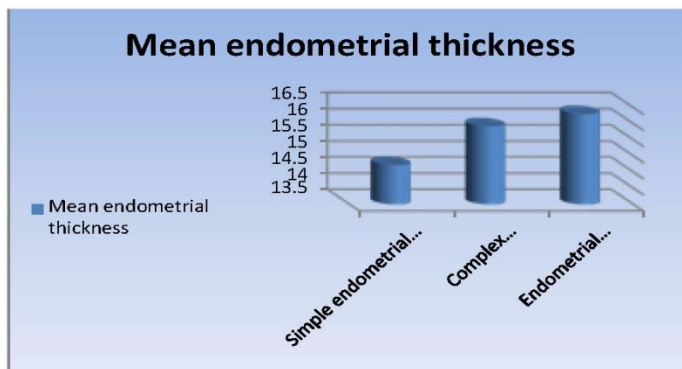


Fig. 1 : Endometrial thickness in Group1

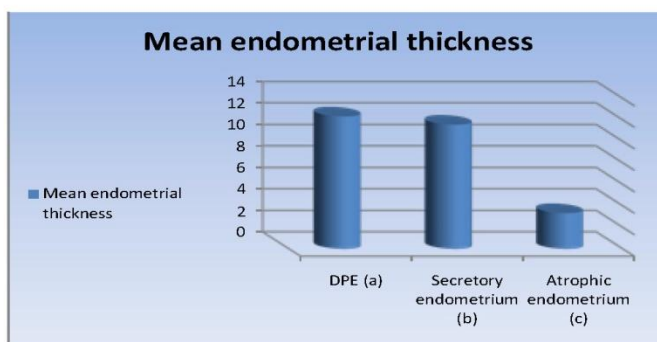


Fig. 2: Endometrial thickness in Group two

	1 st Group (N=50.0)	2 nd Group (N=50.0)	P value
Endometrial volume (cc2)	14.11 ± 2.1	7.67 ± 1.8	0.001 S

Table (5): Endometrial volume in both groups

There was a high statistical significance as regard endometrial volume in comparison of both groups. Table (5)

PATIENTS		Pathology					Total	
		Secretory endometrium	DPE	Atrophic	SHE	CEH		EC
Group 1	Predictive				25	16	1	42
	non-predictive				6	12	0	8
	Total				31	18	1	50
Group 2	Predictive	12	22	4				38
	non predictive	14	6	2				12
	Total	16	28	6				50

Table 6: Office hysteroscopy results in both groups

DISCUSSION

Our research was conducted at Al Azhar University, Al Hussein Hospital, Obstetrics and Gynecology unit from March 2017 to October 2019. The study included 100 patients complaining of perimenopausal bleeding at Al Hussein outpatient clinic. To see how office hysteroscopy and three-dimensional (3D) ultrasonographic endometrial volume measurement work together as a diagnostic tool and if those diagnostic methods could predict malignant conditions and hyperplasia of the endometrium. All of the patients that were chosen had a general checkup, a local pelvic examination, and a transvaginal 2D pelvic ultrasound in the office,

three-dimensional endometrial volume measurement, and then dilatation and curettage (D&C) or hysteroscopic guided biopsy for focal endometrial lesions and pathological examination of the specimens obtained.

Those studied cases were split into two groups based on the endometrial histopathology in Group 1: patients with hyperplasia and malignant conditions. Group 2: patients with other causes of abnormal uterine bleeding or with normal endometrium

The average age in our study was 49.4 ± 1.22 years in group 1, and 48.57 ± 1.54 years in group 2. The age of our patients was comparable to other

studies. In the study by Ahmed et al.,¹² the mean age was 43.5+ 6.12 years & according to a study by (De Franciscis et al.,⁹ The average age was 49.6 ± 4.2 years.

The mean parity in our research was 3.12 ± 1.6 in group 1 and 3.04 ± 1.41 years in group 2. Our patients' parity was comparable to that of the research by Ahmed et al.,¹² where the mean parity was 3.43+2.81

Menorrhagia was the most common bleeding pattern, accounting for 31% of the cases investigated, followed by menometrorrhagia (28%), metrorrhagia (21%), and polymenorrhoea (20%). Compared to the study done by Abo Haemila F,¹³ Menorrhagia (40%) was the most common bleeding pattern, followed by menometrorrhagia (22.8%), metrorrhagia (34.2%), and polymenorrhoea (34.2%). (2.8 percent).

In our study Simple endometrial hyperplasia was the most frequent endometrial histopathology, followed by complicated endometrial hyperplasia & only 1 case of endometrial carcinoma was discovered in group 1. And in group 2 the most common endometrial histopathology was disordered proliferative endometrium then secretory endometrium and 6 cases of atrophic endometrium were discovered. In the study done by M. Odeh,¹⁴ the histopathology In 90 (62%) of the patients, the endometrium was normal; 26 (17.9%) had an endometrial polyp; 18 (12.5%) had hyperplasia with or without type, and 11 had cancer (7.6 percent).

In our research, we found that there was a high statistical significance as regards endometrial thickness in comparison to both groups; In group 1 endometrial thickness was 15.37 ± 2.27mm, while in group 2 it was 11.90 ± 2.97mm. In the study done by M. Odeh,¹⁴ The mean endometrial thickness in premenopausal individuals was 115.5 mm in the normal group and 15.5 15.2 mm in the pathologic group (and showed also statistical significance P.Value < .001), and in the same study the cases with cancer had an average endometrial thickness of 15.4 mm, while patients with hyperplasia had an average endometrium thickness of 15.5 mm. In comparison to the normal group, hyperplasia was associated with a substantially thicker endometrial.

As regards the measurement of endometrial volume, There was a significant statistical significance in our research in comparison of both groups; in group 1 endometrial volume was 14.11 ± 2.1cc, while in group 2 it was 7.67 ± 1.81cc. Also, endometrial volume was significantly different when used to compare atrophic endometrium and other benign endometrial pathology (disordered proliferative endometrium, secretory endometrium). However, it was not significantly different when used to compare different histopathologies in group 1. In a study by Kurjak & Kupesic,¹⁵

the endometrial volume The volume in patients with hyperplasia (mean 7.82 7.60 cc) was substantially higher than the volume in patients with polyps (mean 2.63 2.12 cc). This was not discovered

in the current research. In research by M. Odeh, the endometrial volume in premenopausal individuals was 6.87 6.3 cc in the normal group and 13.79 13.2 cc in the pathologic group.

As regards the results of hysteroscopy, it showed the highest statistical significance in the ability to differentiate between groups 1 and 2. In group 1 it was able to detect 82% of hyperplasia cases and 100% of endometrial cancer cases while in group 2 it was able to detect 76% of cases. In a major study of hysteroscopies done on premenopausal and postmenopausal cases, Globe et al.¹⁶ A sensitivity of 100% and a specificity of 86% were discovered. The hysteroscopic diagnosis of adenomyosis or hyperplasia in cases when the histology diagnostic revealed normal endometrium contributed to the reduced specificity. Marret et al.¹⁷ suggested that; Premenopausal women with ultrasonographic anomalies and/or uterine hemorrhage, as well as individuals at high risk for endometrial cancer, should have a hysteroscopy. Mukhopadhyay et al.¹⁸ while evaluating 85 perimenopausal Transvaginal sonography, hysteroscopy, and endometrial biopsy were used to diagnose individuals with abnormal uterine bleeding and found that hysteroscopy is the most specific and sensitive for diagnosing polyps but less specific for endometrial hyperplasia.

In our study we had noted that combining the 2 diagnostic modalities of three dimensional endometrial volume measurement and office hysteroscopy had lead to increase the ability of diagnosis and sensitivity of diagnosis compared to the histopathological findings being the gold standard for diagnosis.

In contrary to ur research, Laganà AS et al.,¹⁹ A recent cross-sectional study was conducted to determine the concordance between the supposed diagnosis acquired using 3D sonohysterography (SHG) and the diagnostic hysteroscopy (HYS); to see if the 3D SHG has the precision required to be used as a diagnostic screening tool in cases of suspected endometrial abnormalities, they Concluded that despite the diagnostic accuracy and mini-invasiveness of 3D SHG, They recommended that while it cannot replace hysteroscopy in the diagnosis of endouterine disease, it could be used as a screening tool to refer individuals for hysteroscopic confirmation.

A recent review made by Sotirios et al.,²⁰ to determine whether components of the 3D US uterine assessment are supported by a high degree of evidence and, as a result, should be adopted into current clinical practice. They discovered that 3D ultrasound could be a beneficial tool for assessing the uterus. The current goal should be to highlight the features of 3D ultrasound that are the most evidence-based and beneficial to patients and to incorporate these into standard clinical practice.

A previous study made by Yela et al.,²¹ compared Ultrasonography had a sensitivity of 99.0 percent, specificity of 19.0 percent, PPV of 96.1 percent, NPV of 50.0 percent, and accuracy of 95.3 percent, while hysteroscopy had a sensitivity of 96.7 percent,

specificity of 86.9%, PPV of 99.2 percent, NPV of 58.8 percent, and accuracy of 95.3 percent.

CONCLUSION

In cases of perimenopausal bleeding, this study demonstrated the diagnostic value of office hysteroscopy and three-dimensional (3D) ultrasonographic endometrial volume measurement and showed that combining those 2 modalities of diagnosis had led to an increase in the ability & sensitivity of diagnosis and the ability to exclude serious intrauterine pathology in perimenopausal women with irregular uterine bleeding to minimize further operative interventions, especially for surgically high-risk patients.

Conflict of interest : none

REFERENCES

- Whitaker L, Critchley H.O, Abnormal uterine bleeding, *Best Practice & Research Clinical Obstetrics & Gynaecology*. 2016; 34: 54–65.
- Arya S, Plavsic S.K, Preimplantation 3D ultrasound: current uses and challenges, *Journal of perinatal medicine*. 2017; 45(6): 745–758.
- Paterson-Brown S. Applied anatomy, in Basic Science in Obstetrics and Gynaecology. Elsevier. 2010; 57–95. doi:10.1016/B978-0-443-10281-3.00009-9.
- Aunapuu, M. Changes in morphology and presence of pinopodes in endometrial cells during the luteal phase in women with infertility problems: a pilot study, *Medicina*. 2018; 54(5): 69.
- Taylor HS, Pal L, Sell E, Speroffs clinical gynecologic endocrinology and infertility. *Lippincott Williams & Wilkins*. 2019.
- Belitsos P, Papoutsis D, Rodolakis A, Mesogitis S, Antsaklis A, Use of Three-Dimensional Power Doppler Ultrasound for the study of cervical cancer and precancerous lesions. *Ultrasound Obstet Gynecol*. 2012; doi: 10.1002.
- Zettinig O. Advanced Ultrasound Imaging Techniques for Computer Assisted Interventions, 2017.
- Han D. Clinical Diagnosis of Endometrial Polyps Using Multioperator Algorithm Combined with Hysteroscopy, Scientific Programming. Edited by G. Ramirez. 2021; 1–5. doi:10.1155/2021/6254873.
- De Franciscis P. Concordance between the hysteroscopic diagnosis of endometrial hyperplasia and histopathological examination, *Diagnostics*. 2019; 9(4): 142.
- Morales C. The Value of Endometrial Volume as Estimated by Three-Dimensional Ultrasound for Detecting Endometrial Cancer in Postmenopausal Women: A Systematic Review and Meta-Analysis, *EMJ*. 2020; 1(1): 79–88.
- Liu M. Application of transvaginal three-dimensional power Doppler ultrasound in benign and malignant endometrial diseases, *Medicine*. 2019; 98(46): e17965. doi:10.1097/MD.000000000017965.
- Ahmed M.T, Mohamed AH, El Tammamy EA, Comparative Study between the Diagnostic accuracy of 3D Ultrasound and Hysteroscopy in patients with premenopausal uterine bleeding, *Al-Azhar International Medical Journal*. 2022; 3(2): 71–5. doi:10.21608/aimj.2022.104507.1646.
- Abo Haemila F, Youssef D, Hassan M, Soliman A, Mossad M, A prospective comparative study of 3-D ultrasonography and hysteroscopy in detecting uterine lesions in premenopausal bleeding. *Middle East Fertility Society Journal*. 2005; 10(3):238-43.
- Odeh M, Vainerovsky I, Grinin V, Three-dimensional endometrial volume and 3-dimensional power Doppler, 2007.
- Kurjak A and Kupesic S, Three-dimensional ultrasound and power Doppler in assessment of uterine and ovarian angiogenesis: a prospective study. *Croat Med J*.1999; 40: 51-8.
- Golbe, L. I., Lazzarini, A. M., Duvoisin, R. C., Iorio, G. D., Sanges, G., Bonavita, V., & la Sala, S, Clinical genetic analysis of Parkinson's disease in the Contursi kindred. *Annals of Neurology: Official Journal of the American Neurological Association and the Child Neurology Society*. 1996; 40(5), 767-75.
- Marret, H., Fauconnier, A., Chabbert-Buffet, N., Cravello, L., Golfier, F., Gondry, J., ... & behalf of the CNGOF, O, Clinical practice guidelines on menorrhagia: management of abnormal uterine bleeding before menopause. *European Journal of Obstetrics & Gynecology and Reproductive Biology*. 2010;152(2), 133-7.
- Mukhopadhyay, D., & Riezman, H, Proteasome-independent functions of ubiquitin in endocytosis and signaling. *Science*. 2007; 315(5809), 201-5.
- Laganà AS, Ciancimino L, Mancuso A, Chiofalo B, Rizzo P, Triolo O, 3D sonohysterography vs hysteroscopy: a cross-sectional study for the evaluation of endouterine diseases. *Arch Gynecol Obstet*. 2014; 290(6):1173-8. doi: 10.1007/s00404-014-3366-6. Epub 2014 Jul 15. PMID: 25022557.
- Sotirios H, Kannamannadiar J, Kamal O, Tin-Chiu Li, Assessment of the uterus with three-dimensional ultrasound in women undergoing ART, *Human Reproduction Update*. 2017; 23(2): 188–210, <https://doi.org/10.1093/humupd/dmw040>
- Yela DA, Patricia H, Cristina L, Comparison of endometrial assessment by transvaginal ultrasonography and hysteroscopy. *Int J Gynecol Obstet*. 2018; 143: 32–6. DOI: 10.1002/ijgo.12567