

INVESTIGATION ON ENTEROCOCCUS INFECTION IN BROILER CHICKENS

HESHAM AHMED HAMMAM¹; MOSTAFA ABDELMOTELEB SHEHATA²;
HEBATALLAH ABDELHALIM¹ AND OMAR AMEN²

¹ Poultry Diseases Department, Animal Health Research Institute, Assiut, Egypt

² Avian and Rabbit Diseases Department, Faculty of Veterinary Medicine, Assiut University, Egypt

Received: 22 November 2022; **Accepted:** 8 December 2022

ABSTRACT

Enterococcus species (Enterococcus spp.) are considered one of the most common pathogens causing economic losses in poultry production. To isolate and identify *Enterococcus spp.*, 110 broiler chickens (some diseased and others recently dead) were collected aged from 1 to 45 days, also 65 dead in shell chicken embryos were collected from different farms and Balady hatcheries in Assiut province. Four samples were taken from each bird from 110 broiler chickens (liver, spleen, heart), (intestines), (joints), (brain) and the samples from dead shell chicken embryos were cultured on Brain heart infusion broth then inoculated broth cultured on KF streptococcal agar and bile esculine agar. *E. hirae* was isolated from (liver, spleen and heart) at a rate of (66.2%), intestine (66.7%), joint (81.8%), brain (66.7%) and dead in shell chicken embryos (44.1%), *E. durans* was isolated from (liver, spleen and heart) with a percentage of (22%), intestine (14.3%), joint (18.2%), brain (33.3%) and was (41.2%) from dead in shell chicken embryos, *E. faecalis* was isolated at a rate of (11.8%) and (19%) from (liver, spleen, heart) and intestine respectively but the percentage of dead in shell chicken embryos was (14%) and did not isolate from joint or brain. we used *E. hirae* isolate in this experiment because it is the largest percentage of isolation. Four days-old broiler chicks were infected by I/V inoculation (wing vein), I/T inoculation, and contact chicks for each of them the mortality rates were 100%, 90% and 60% for I/V, I/T and in both contact chicks respectively. We found that *E. hirae* isolates were sensitive to neomycin, ampicillin, streptomycin, penicillin g, and amoxicillin and resist tetracycline, erythromycin and tylosin.

Key Words: Enterococci, *E. hirae*, *E. durans*, *E. faecalis*.

INTRODUCTION

Poultry meat products constitute an excellent source of high quality, One of the most significant food processing industries for the production of poultry. (Eldaly *et al.*, 2019). Because this genus was recently

separated from the Lancefield group D streptococci, there is little information about the history of illnesses caused by *Enterococcus spp.* (Gross, and Domermuth 1962). *Enterococci* are Gram-positive cocci in smears from blood, liver, spleen or other lesions, facultative anaerobic organisms, they are capable of cellular respiration in both oxygen-rich and oxygen-poor environments, they are not capable of forming spores (Borst *et al.*, 2017). *Enterococci* considered one of the lactic acid bacteria have a high degree of

Corresponding author: Hesham Ahmed Hammam
E-mail address: hhammam185@gmail.com
Present address: Poultry Diseases Department,
Animal Health Research Institute, Assiut, Egypt

environmental adaptability. They can grow at high salt concentrations of up to 6.5% NaCl and can withstand a wide range of pH values (4.8 to 9.6) and temperatures (10 to 45 °C). Most of them have the ability to hydrolyze esculin when 40% bile salts are present; this ability is employed for phenotypic identification methods. (Lebreton *et al.*, 2014). The route of transmission is likely a combination of vertical and horizontal transmission, several researchers have failed to confirm vertical transmission from breeder flock (Robbins *et al.*, 2012). *E. faecalis*, *E. cecorum*, *E. hirae*, *E. faecium* and *E. durans* have an important role in avian pathology (Dolka *et al.*, 2017). *Enterococcus* species (*Enterococcus spp.*) are considered one of the most common pathogens due to high mortality, retardation of growth, as well as the economic cost for the preventive and therapeutic use of antimicrobials, Moreover, condemnations in the slaughterhouse (Rehman *et al.*, 2018), *Enterococcus sp.* Could be isolated from broiler chickens with arthritis, osteomyelitis, lameness, and endocarditis (Avbersek *et al.*, 2021).

So, this work is conducted for the isolation, identification and serotyping of *Enterococcus spp.* as well as studying the pathogenicity of the isolated *Enterococcus* in broiler chickens and studying the sensitivity of the isolated organism to different antimicrobial agents.

MATERIALS

1. Samples for bacterial isolation:

A total of 110 diseased and freshly dead broiler chickens (1 to 45 days old) were collected from different farms in Assiut governorate, also 65 dead shell chicken embryos were collected from different Balady hatcheries in Assiut governorate.

The birds were examined for PM lesions. Samples from (liver, spleen, heart), intestine, joints and brain were collected.

2-Media used:

a) Liquid media: Brain Heart infusion broth (BHI) broth, Nutrient broth and 6.5% NaCl broth.

b) Selective plating solid media: KF (Kenner Fecal) streptococcal agar, Bile esculine azide agar: (*Enterococcus* selective media, Biolife), MacConky's agar, sheep blood agar.

c) Nutrient slope agar (for isolate preservation)

3- Stain, Reagents and Solutions:

-Sugar fermentation medium:

Peptone water contains 1% sugar (Mannitol, Sorbitol, Sucrose, Arabinose and lactose).

-Media used for Motility test: semisolid agar media(0.5% agar) (Oxoid/England)

- Gram's stain, Bromo cresol purple for sugar fermentation test, 30% hydrogen peroxide for catalase test, Buffered peptone, glucose, dipotassium phosphate, α -Naphthol 5%, 95% ethanol and 40% potassium hydroxide for Vogues Proskauer test, Iodine solution (for detection of starch hydrolysis by enterococcus organisms), McFarland standard for adjusting the turbidity of inoculum used in pathogenicity test, litmus milk and 4% Gelatin for gelatin hydrolysis test.

(4) **Birds used for pathogenicity test:** Forty-Five (one day old) from the Agriculture college farm of Assiut University were used.

(5) Antimicrobial sensitivity discs:

Streptomycin (10 μ g), Neomycin (10 μ g), Enrofloxacin (5 μ g), Oxacillin (5 μ g), Amoxicillin (10 μ g), Penicillin G (10 IU), Ampicillin (10 μ g), Cotrimoxazole (25 μ g), Tylosine (15 μ g), Erythromycin (15 μ g), Oxytetracycline (30 μ g), Doxycycline (30 μ g), Tetracycline (30 μ g).

METHODS

1-Bacteriological examination:

1. Isolation:

Four samples were collected from each bird, the first one was pooled sample (liver, spleen, heart), the second one was intestinal content, the third one was from joints and the fourth one was from the brain. The swabs were inoculated into BHI broth and incubated aerobically at 37° C for 24 hrs. Also, swabs from dead in-shell chicken embryos were taken under aseptic conditions and inoculated into BHI broth and incubated aerobically at 37 °C for 24 hrs. Then, a loopful from the enrichment broth was streaked onto the surface of selective plating medium (KF) Streptococcal agar, bile esculine azide agar, sheep blood agar and MacConky's agar media No.2 and incubated aerobically at 37°C for 24-48hrs.

2-Identification and serotyping of the isolated organism:

Tolerance tests, including growth at 10°C and 45°C, growth in 6.5% sodium chloride and hydrolysis of bile esculine agar media, were done to differentiate between *Enterococcus spp.* and *streptococcus spp.* Then the positive cases of colonies to be *Enterococcus* were examined for their morphology, films from colonies were stained by Gram's stain and biochemical reactions were done according to Connie and George (1995). Also, to differentiate between *Enterococcus spp.* biochemical tests include the Catalase test, Motility test, Gelatin hydrolysis test and Voges proskaur test were done according to (Baily and Scott's 1994) and (Facklam and Teixeira 1998), litmus milk test according to (Schierl and Blazevic 1981) Sugar fermentation test according to (Facklam and Collins 1989).

3-Pathogenicity test:

Due to the high percentage of isolated *E.hirae*, we used it for experimental infection, Forty-five one-day-old broiler chicks were used. Five chicks from them were tested for being free from *Enterococcus* infection, and

the other birds were infected experimentally with isolated *E.hirae* according to (El-Sukhon and Abdul-Aziz 1993). At four day old, chicks were divided into five groups as follow:

Group 1: 10 chicks were inoculated intravenously (I/V through wing vein) with 0.1 ml of saline suspension prepared from an 18-hour-old BHI broth culture in a concentrate equivalent to No.2 MacFarland opacity tubes.

Group 2: 5 chicks were kept with those of group I as contact birds.

Group 3: 10 chicks were inoculated intratracheally (I/T) with 0.1 ml from an 18-hour-old BHI broth culture in a concentrate equivalent to No.2 MacFarland opacity tubes.

Group 4: 5 chicks were kept with group 3 as contact birds.

Group 5: 10 chicks were left as untreated control.

Reisolation of *E.hirae* from experimentally infected birds was done.

4-Antimicrobial Susceptibility Test: The determination of the sensitivity of the isolated organism against different antibiotics discs was done according to (Bauer *et al.*, 1966).

RESULTS

Clinical signs of naturally infected birds showed: depression, lethargy, ruffling feathers, fine head tremors, loss of body weight and lameness, PM examination revealed: Septicemia, splenomegaly, hepatomegaly, enlarged kidneys, congestion of subcutaneous tissue, arthritis, omphalitis and enlarged yolk sacs in infected chicks.

Bacteriological examination and biochemical reactions revealed:

growth of colonies on KF agar media, MacConkey's agar No.2 and sheep blood agar with no haemolysis, the colonies grew at 10°C and at 45°C, also grew in 6.5%NaCl broth and hydrolysis of bile esculine agar plates giving black colour, Gram's stain

showed gram-positive cocci, occurring singles, in pairs or short chains. Biochemical tests showed that the isolated organism was catalase-negative, non motile, non pigmentad, positive for esculine hydrolysis, lactose and sucrose, liquefying gelatin, positive starch hydrolysis and decolourized litmus milk.

According to some biochemical tests and sugar fermentation tests we could serotype *Enterococcus* spp. into *E.hirae*, *E. durans* and *E.faecalis* from broiler chicks and dead in-shell chickens embryos as in table 1,2,3,4

Table 1: Showing the result of sugar fermentation test.

Test	<i>E.hirae</i>	<i>E.durans</i>	<i>E.faecalis</i>
Sucrose	+ve	-ve	-ve
Mannitol	-ve	-ve	+ve
Sorbitol	-ve	-ve	+ve
L-arabinose	-ve	-ve	-ve

Table 2: Showing the number (No.) and percentage of isolated *Enterococcus* spp. from naturally affected birds.

Source	Liver, spleen, heart	Intestine	Joint	Brain
No. of isolated <i>Enterococcus</i> spp	68/110	63/110	11/110	9/110
%	61.8%	57.3%	10%	8.2%

Table 3: Showing Serotyping of *Enterococcus* spp. of naturally affected birds.

<i>Enterococcus</i> serotype	Liver, spleen, heart	Intestine	Joint	Brain
<i>E.hirae</i>	66.2%	66.7%	81.8%	66.7%
<i>E.durans</i>	22%	14.3%	18.2%	33.3%
<i>E. faecalis</i>	11.8%	19%		

Table 4: Showing Serotyping of *Enterococcus* spp. isolated from dead in-shell chicken embryos

<i>Enterococcus</i> serotype	Dead in-shell chicken embryos
<i>E.hirae</i>	44.1%
<i>E.durans</i>	41.2%
<i>E.faecalis</i>	14.7%

Results for pathogenicity test:

In general, clinical signs noticed in chicks infected with isolated *E.hirae* were huddling together, depression, lethargy, ruffling feathers (Fig.1), drooped wings, lameness, setting on hock, locomotor disturbance and clear nervous signes (Fig.2,3) and later an emaciation, mortality illustrated in table (5

and lesions were septicemia (Fig.4) air sacculitis (Fig.5), enteritis, enlargement of liver with petechial hemorrhages, pericarditis, enteritis, opaque air sacs, congestion of kidneys, the ureters filled with urates (Fig. 6), arthritis and enlargement of hock joint (Fig. 7).

Table 5: Showing mortality rate of experimentally infected chicks.

Group no	No. of inoculated chicks	Route of inoculation	No. of deaths/day post inoculation							Total no. of dead	Mortality rate
			1 st	2 nd	3 rd	4 th	5 th	6 th	7 th		
1	10	I/V injection	7			1		1	1	10	100%
2	5	Contact to IV injected chicks				1	1	1		3	60%
3	10	I/T injection	4	1	1	1	1	1		9	90%
4	5	Contact to I/T injected chicks			1	1	1			3	60%
5	10	Control									

We could reisolate *E.hirae* from (liver, spleen, heart), intestine, joint and brain of experimentally infected chicks.

Results of antibiotic sensitivity test:

Table 6: Showing antibiotic sensitivity test:

Antibiotic	Sensitivity
Neomycin	+++ve(sensitive)
Ampicillin	+++ve(sensitive)
Streptomycin	++ve(moderate)
Pencillin G	++ve(moderate)
Amoxicillin	++ve(moderate)
Tetracycline	-ve(resistant)
Oxytetracycline	-ve(resistant)
Doxycycline	-ve(resistant)
Erythromycin	-ve(resistant)
Tylosine	-ve(resistant)
Oxacillin	-ve(resistant)
Enrofloxacin	-ve(resistant)
Co trimoxazole	-ve(resistant)

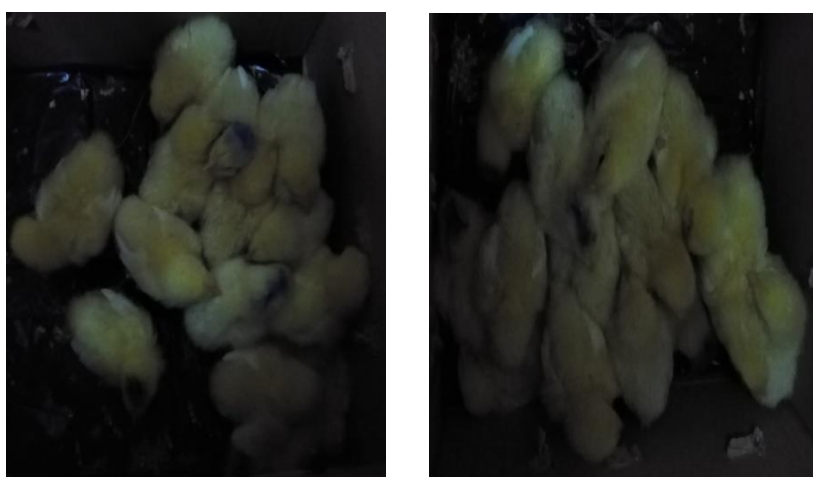


Fig. (1) Huddling together and ruffling chicks showing depression, feather after intratracheal and intravenous inoculation with *E.hirae* in experimentally infected chicks



Fig.(2) Locomotors disturbance in experimentally infected chicks

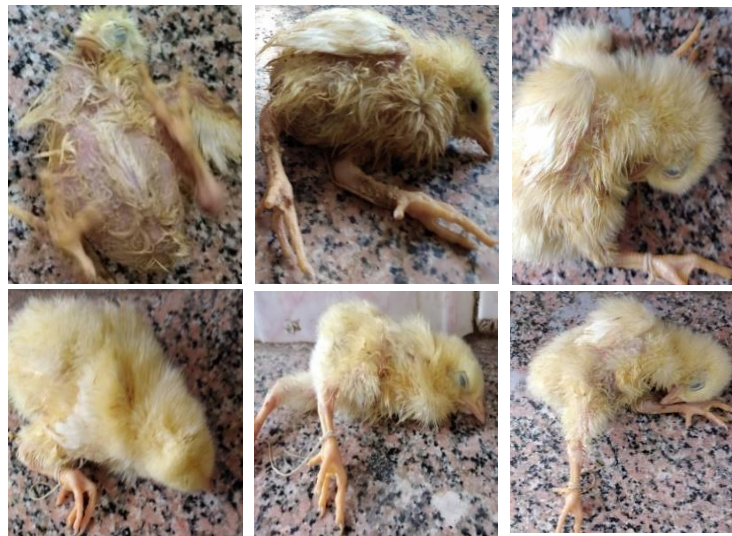

Fig. (3) Nervous signs in experimentally infected chicks

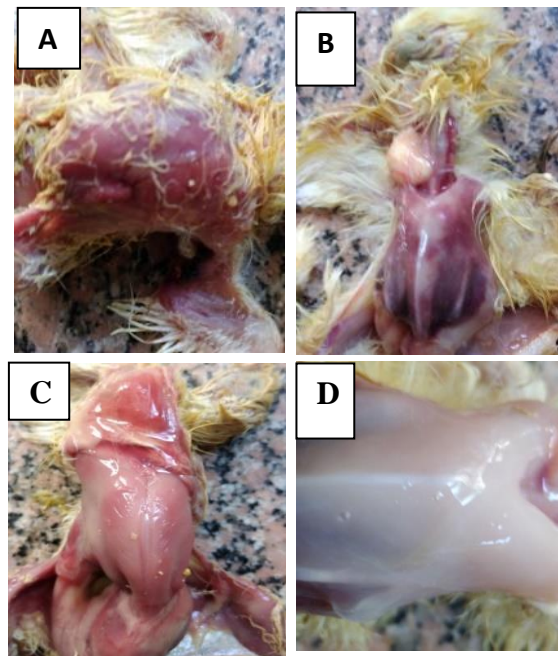


Fig.(4) Congestion of carcasses of experimentally infected chicks
A – I/V Inoculation; B – I/ T inoculation; C – contact bird; D – control bird

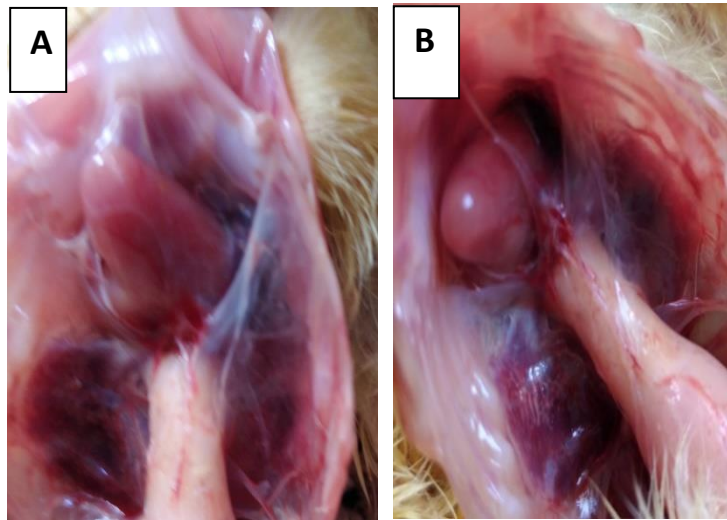


Fig.(5) Airsacculitis (A) and endocarditis (B) in experimentally infected chicks

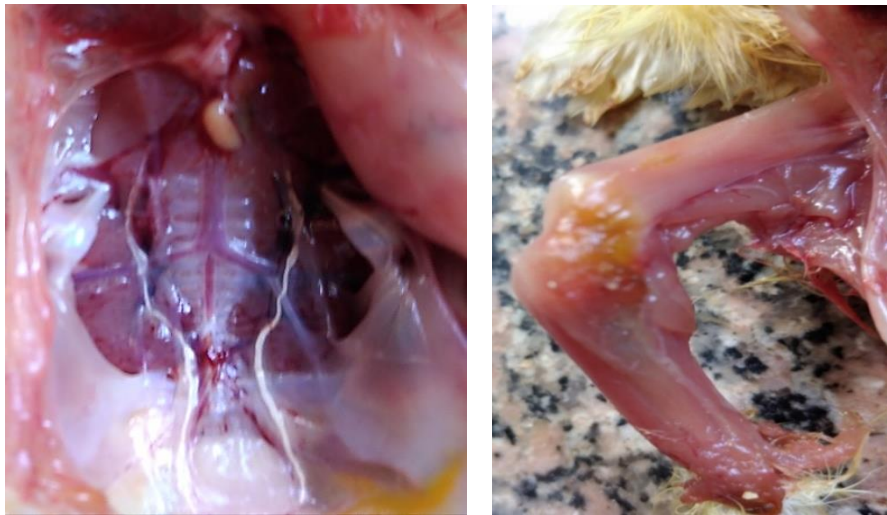

Fig.(6) Congestion of the kidney and the ureters filled with urates

Fig.(7) Gelatinous material on hock joint in experimentally infected chicks

DISCUSSION

Enterococcus spp. in poultry can result in two distinct clinical forms of the disease, acute and subacute/chronic. In the acute form, clinical signs are related to septicemia, mild head tremors and often, only dead birds are found. In the subacute/chronic form, loss of body weight and lameness, infected birds die if not treated (Smyth and McNamee, 2008). There are few studies on *Enterococcosis* in broiler chickens, so this study was conducted for isolation, identification and serotyping of the *Enterococcus spp.*, studying the

pathogenicity of the isolated *Enterococcus* in broiler chickens and Studying the sensitivity of the isolated organism to different antimicrobial agent. In our work PM finding were septicemia, splenomegaly, hepatomegaly, enlargement of kidneys, congestion of subcutaneous tissue, air sacculitis, arthritis, omphalitis and enlarged yolk sacs in infected chicks. this picture is agree with that observed by (Gilmore *et al.*, 2002). We also in agreement with (Schleifer and Kilpper 1984, 1987), (Devriese and Pot, 1995), (Ruzauskas *et al.*, 2009) and (obeng *et al.*, 2013) who mentioned that the genus

Enterococcus are gram-positive cocci that are cultivated in 6.5% NaCl and bile esculine agar. These criteria were used to differentiate the *Enterococcus spp.* from *Streptococcus spp.*

Bacteriological examination revealed that *Enterococcus spp.* were isolated from naturally infected birds at the rate of (61.8% from liver, spleen and heart), (57.3% from intestine), (10% from joint), (8.1% from brain) and (52% from dead in shell chicken embryos). Our results agree with (Velkers *et al.*, 2011) who stated that a higher percentage of *Enterococcus* was isolated from the liver at a percentage of 75%. However, we differ from them in that we isolated less *Enterococcus* from joints at a rate of 10 %, this percent was less than they reported (60%). We agree with Quin *et al.*, (1994) who reported that the initial identification of *Enterococcus spp.* is done by sugars fermentation tests. We agree with Osman *et al.*, 2019 who showed that it is remarkable to point out that the phenotypic virulence factor gelatinase activity among *E. faecalis* isolates have also been found in *E. durans* and *E. hirae*.

In our work, *E. durans* was detected from (liver, spleen, heart), brain at the percentage of 22% and 33.3%, respectively while (Hebatallah Abdel Halim 2008) reported that *E. durans* was detected at a percentage 66.6% from (livers and spleens) of birds and at a rate of 27.7% from brains. She could isolated *E. durans* from dead chicken embryos at a percentage of 70.8%, but in our study we isolated *E. durans* at rate 41.2% from dead chicken embryos.

Liu *et al.* (2013) recorded that the most predominant species isolated was *E. faecalis* 82% then *E. durans* 0.4%. Also, (Maasjost *et al.*, 2015) mentioned that majority of *Enterococcus* isolates were belonged to *E. faecalis* 88%. but in our study *E. hirae* was the predominant species (66.2%), *E. durans* (22%) then *E. faecalis* (11.8%). In this study *E. faecalis* was isolated from intestine at a percentage 19%, this agree with Ruzauskas

et al. (2009) who isolated *E. faecalis* at the rate of 17.5% from intestine of broilers in Lithuanian poultry farms.

In this work the bacteriological examination samples of dead chicken embryos in shell revealed that the percentage of *E. hirae*, *E. durans* and *E. faecalis* were 44.1%, 41.2% and 14.7%. Nearly similar result was obtained from (Olsen *et al.*, 2012) which observed that 15% of the chicks positive for *E. faecalis*. In a similar work (Pesavento *et al.*, 2014) explained that the most generally recognized species were *E. faecalis* (74.7%), *E. hirae* (4.6%). the isolation of *Enterococcus spp.* From in shell dead chicken embryos indicates that *Enterococcus* is transferred vertically, this result is agree with (Al aboudi *et al.*, 1992).

In our experiment, clinical signs noticed in chicks infected with the isolated *E. hirae* were depression, nervous signs, lethargy, ruffling feathers, clustering together, drooped wings, lameness, sitting on hock and then decreased growth rates, PM lesions of experimentally infected chicks revealed the picture of septicemia, air sacculitis, enteritis, enlarged liver with petechial hemorrhages, distended heart, some birds showed nervous signs before death. Some birds have congested kidneys and ureters were filled with urates, this result is similar to that observed in naturally infected broiler chickens and agree with the study reported by (Hebatallah Abdel Halim, 2008) and (Cardona *et al.*, 1993), But El-Sukhon and Abdul-Aziz, 1993 could not succeeded either in reproducing signs nor mortality in chicks experimentally infected with *E. hirae* but our experiment revealed mortality rates (100%) for I/V inoculated chicks, (60%) for I/V contact chicks, (90%) for I/T inoculated chicks and (60%) for I/T contact chicks. chadfield *et al.* (2005) in their study described experimental infection in broiler chickens inoculated intravenously with *E. hirae*, PM lesions showed enlarged liver, spleen and endocarditis The challenge strain were also isolated from liver, spleen and hock joints.

The study of (Ruzauskas *et al.*, 2009) observed that the common or high-level of resistance was related to tetracycline, tylosin and flouroquinolones, we also found that our isolates were resistant to them. In the reading of (Osman *et al.*, 2019) majority of their isolates (> 90%) were resistant to erythromycin, oxytetracycline and doxycycline, we agree with them in this result. Our findings are comparable with (Avberšek *et al.*, 2021) who proved that the suitable drug for the treatment of *Enterococcus* in broiler chickens is amoxicillin. Other studies have reported low resistance to amoxicillin, high resistance to enrofloxacin and erythromycin (Stepien-Pysniak *et al.*, 2016; Jong *et al.*, 2018). (Diarra *et al.*, 2010) found in their isolates from Canada, resistance to tetracycline, streptomycin, penicillin, erythromycin and tylosin at a significantly higher frequency. In our study we found that *E.hirae* was sensitive to penicillin and streptomycin and resistance to tetracycline, erythromycin and tylosine. Some studies afford evidence for dissemination of resistant *Enterococci* from animals to man due to the exchange of resistance genes between poultry and human *Enterococci* (Van den Bogaard *et al.*, 2002). Multidrug resistance is common among *Enterococci* and presents a formidable treatment problem (Donabedian *et al.*, 2003). Food animals are implicated as reservoirs for antibiotic resistant *Enterococci*, following the use of antimicrobial growth promoters and prophylactics (Bates *et al.*, 1993) and (Waites *et al.*, 2006).

CONCLUSION

This study reveals the significant incidence of *Enterococcus spp.* in broiler chickens.

The tested isolates were completely sensitive to Neomycin and Ampicillin.

Inadequate management of hatcheries and breeding flocks can cause bacterial infections or the death of developing embryos, high mortality, morbidity rates in broilers and high

condemnation rates in slaughterhouses. Adequate biosecurity measurements on the farm and controlled conditions in the hatchery are necessary for the prevention of *Enterococcus* in broilers.

REFERENCES

- Alaboudi, A.R.; Hamed, D.A.; Basher, H.A. and Hassen, M. (1992): "Potential pathogenic bacteria from dead in shell chicken- embryos". Iraqi J. Vet. Sci. 5: 109 -114.
- Avbersek, Jana, Jasna Mi unovi, Neva Semrov and Matjaz Ocepek (2021): "Surveillance of the source of poultry infections with *Enterococcus hirae* and *Enterococcus cecorum* in Slovenia and *E. hirae* antibiotic resistance patterns." The New Microbiologica 44(4): 210-216.
- Bailey and Scott's (1994): "Differentiation among selected *Enterococcus spp.* and *Streptococci* and related genera". In: Diagnostic Microbiology. Section 26 p. 345, 9th Edition. Edited by: Ellen, J.B.; Lance, p. R. and Sydney F.M.
- Bauer, A.W.; Kirby, M.M.; Sherris, J.C. and Truck, M. (1966): "Antibiotic susceptibility testing by a standardized single disk method". Am J Clin Pathol; 45: 493-496.
- Bates, J.; Jordens, Z. and Selkon, J.B. (1993): "Evidence for an animal origin of vancomycin-resistant *Enterococci*". Lancet. 342, 490-491.
- Borst, L.B.; Suyemoto, M.M.; Sarsour, A.H.; Harris, M.C.; Martin, M.P.; Strickland, J.D.; Oviedo, E.O. and Barnes H.J.; (2017): "Pathogenesis of *Enterococcal* spondylitis caused by *Enterococcus cecorum* in broiler chickens." Veterinary Pathology 54(1): 61-73.

- Cardona, C.J.; Bickford, A.A.; Charlton, B.R. and Cooper, G.L. (1993): "Enterococcus durans infection in young chickens associated with bacteremia and encephalomalacia". Avian Diseases 37(1):234-239.
- Chadfield, M.S.; Bojesen, A.M.; Christensen, J.P.; Juul-Hansen, J.; Saxmose Nielsen, S. and Bisgaard, M. (2005): "Reproduction of sepsis and endocarditis by experimental infection of chickens with *Streptococcus gallinaceus* and *Enterococcus hirae*". Avian Pathology 34(3), 238-247.
- Connie, M.R. and George, M. (1995): "Classification of *Streptococcus* and *Enterococcus*". In: Diagnostic Microbiology. P. 343-344.
- Dolka, Beata; Mariola Golebiewska-kosakowska; Krzysztof Krajewski; Piotr Kwiecinski; Tomasz Nowak; Jaroslaw Szubstarski; Jaroslaw Wilczynski and Piotr Szeleszczuk (2017): "Occurrence of *Enterococcus* spp. in poultry in Poland based on 2014-2015 Data." Med Weter 73(4): 220-224.
- Donabedian, S.M.; Thal, L.A.; Hershberger, E.; Perri, M.B.; Chow, J.W.; Bartlett, P.; Jones, R.; Joyce, K.; Rossiter, S. and Gay, K. (2003): "Molecular characterization of gentamicin-resistant *Enterococci* in the United States: evidence of spread from animals to humans through food". J. Clin. Microbiol. 41, 1109-1113.
- Devriese, L.A. and Pot, B. (1995): "The genus *Enterococcus*". In: The genera of lactic acid bacteria. pp. 327-367.
- Diarra, M.S.; Rempel, H.; Champagne, J.; Masson, L.; Pritchard, J. and Topp, E. (2010): "Distribution of antimicrobial resistance and virulence genes in *Enterococcus* spp. and characterization of isolates from broiler chickens". Appl. Environ. Microbiol. 76, 8033-8043.
- Eldaly Elsaid, M Rasha and Reham Ragab Abo Elazam (2019): "Prevalence of *Enterococcus* species in chicken meat in Sharkia governorate." Egyptian Journal of Applied Science 34(issue, 12): 317-323.
- El-Sukhon, S.N. and Abdul-Aziz, T.A. (1993): "Experimental infection of chicks with *Enterococcus hirae*". The Veterinary Record, 133(6), 144.
- Facklam, R.R. and Teixeira, L.M. (1998): "*Enterococcus*". In: Topley & Wilson's in Microbiology and Microbiol infections chapter 29. p. 674 Vol. 2. Edited by Leslie Collier Balows, A. and Sussman, M, 9thEdition.
- Gilmore, Michael S, Phillip S Coburn, Sreedhar R Nallapareddy, and Barbara E Murray. (2002): "*Enterococcal* virulence." The *Enterococci*: pathogenesis, molecular biology, and antibiotic resistance, Washington, D.C., ASM Press.: 301-354.
- Gross WB. and Domermuth CH. (1962): "Bacterial endocarditis of poultry." American Journal of Veterinary Research 23: 320-329.
- Hebatallah Abdel Halim M. (2008): "*Enterococcus durans* infection in chicks". Ass. Univ. Bull. Environ. Res. Vol. 11 No. 2: 25-34.
- Jong, De, A.; Simjee, S.; El Garch, F.; Moyaert, H.; Rose, M.; Youala, M.; Dry, M. and Group, E.S. (2018): "Antimicrobial susceptibility of *Enterococci* recovered from healthy cattle, pigs and chickens in nine EU countries (EASSA Study) to critically important antibiotics" Chinese Journal of Veterinary Medicine 23(5): 9-10.
- Lebreton, Francois, Rob J.L. Willems, and Michael S Gilmore (2014):

- "*Enterococcus* diversity, origins in nature, and gut colonization." In: Gilmore MS, Clewell DB, Ike Y, Shankar N, editors. *Enterococci: from commensals to leading causes of drug resistant infection* Boston: Massachusetts Eye and Ear Infirmary; pg: 1-47. PMID: 24649513.
- Liu, Y.; Liu, K.; Lai, J.; Wu, C, Shen, J. and Wang, Y. (2013): "Prevalence and antimicrobial resistance of *Enterococcus* species of food animal origin from Beijing and Shandong Province, China", *Journal of Applied Microbiology*, 114(2), 555-563.
- Maasjost, J.; Muhldorfer, K.; Cortez de Jackel, S. and Hafez, HM. (2015): "Antimicrobial susceptibility patterns of *Enterococcus faecalis* and *Enterococcus faecium* isolated from poultry flocks in Germany." *Avian Diseases* 59(1): 143–148.
- Obeng, AS.; Rickard, H.; Ndi, O.; Sexton, M. and Barton, M. (2013): "Comparison of antimicrobial resistance patterns in *Enterococci* from intensive and free range chickens in Australia", *Avian Pathology*, 42, 45- 54.
- Olsen, R.H.; Christensen, H. and Bisgaard, M. (2012): "Transmission and genetic diversity of *Enterococcus faecalis* during hatch of broiler chicks". *Vet. Microbiol.* 160, 214–221.
- Osman Kamelia, M.; Jihan Badr, Ahmed Orabi, Ayman Elbehiry, Aalaa Saad, Mai, D.S Ibrahim and Mai H Hanafy (2019): "Poultry as a vector for emerging multidrug resistant *Enterococcus spp.*: first report of vancomycin (van) and the chloramphenicol-florfenicol (Cat-Fex-Cfr) resistance genes from pigeon and duck Faeces." *Microbial Pathogenesis* 128: 195–205.
- Pesavento, G.; Calonico, C.; Ducci, B.; Magnanini, A. and Nostro, A. Lo. (2014): "Prevalence and antibiotic resistance of *Enterococcus spp.* isolated from retail cheese, ready-to-eat salads, ham, and raw meat". *Food Microbiol.* 41, 1–7.
- Quin, PJ.; Carter, ME.; Markey, BK. and Carter, GR. (1994): "The Streptococci and related cocci" *Clinical Veterinary Microbiology*. Spain: Wolfe Publishing. Chapter 9; p. 127–136.
- Rehman, Muhammad Attiq; Xianhua Yin; Rahat Zaheer; Noriko Goji; Kingsley K. Amoako; Tim McAllister; Jane Pritchard; Edward Topp and Moussa S. Diarra (2018): "Genotypes and phenotypes of *Enterococci* isolated from broiler chickens." *Frontiers in Sustainable Food Systems*: 83. <https://doi.org/10.3389/fsufs.2018.00083>
- Robbins, Kabel M.; Mitsu Suyemoto, M.; Roberta L Lyman; Michael P Martin; John Barnes, H. and Luke B Borst I. (2012): "An outbreak and source investigation of *Enterococcal* spondylitis in broilers caused by *Enterococcus cecorum*." *Avian Diseases* 56(4): 768–773.
- Ruzauskas, M.; Siugzdiniene, R.; Spakauskas, V.; Povilonis, J.; Seputiene, V.; Suziedeliene, E.; Daugelavicius, R. and Pavilonis, A. (2009): "Susceptibility of bacteria of the *Enterococcus* genus isolated on Lithuanian poultry farms". *Vet. Med.*, 1, 54(12), 583-588.
- Schleifer, K.H. and Kilpper-Balz, R. (1984): "Transfer of *Streptococcus faecalis* and *Streptococcus faecium* to the genus *Enterococcus* nom. rev. as *Enterococcus faecalis* comb. nov. and *Enterococcus faecium* comb. nov." *Int. J. Syst. Evol. Microbiol.* 34, 31–34.

- Schleifer, K.H. and Kilpper-Balz, R. (1987): "Molecular and chemotaxonomic approaches to the classification of *Streptococci*, *Enterococci* and *Lactococci*: a review". Syst. Appl. Microbiol. 10, 1–19.
- Smyth, J.A. and McNamee, P.T. (2008): "*Staphylococci*, *Streptococci* and *Enterococci*", in: Patison M, McMullin PF, Bradbury JM, Alexander DJ. (Eds) Poultry Diseases, 6th edn, Philadelphia, Saunders, Elsevier Limited. 191–199.
- Stępień-Pyśniak, D.; Marek, A.; Banach, T.; Adaszek, Ukasz, Pyzik, E.; Wilczyński, J.A.W. and Winiarczyk S.A.W. (2016): "Prevalence and antibiotic resistance of *Enterococcus* strains isolated from poultry. Acta Vet. Hung. 64, 148–163.
- Van den Bogaard, A.E.; Willems, R.; London, N.; Top, J. and Stobberingh, E.E. (2002): "Antibiotic resistance of *Faecal Enterococci* in poultry, poultry farmers and poultry slaughterers." J. Antimicrob. Chemother. 49, 497–505.
- Velkers, F.C.; van de Graaf-Bloois, L.; Wagenaar, J.A.; Westendorp, S.T.; Van Bergen, M.A. P.; Dwars, R.M. and Landman, W.J.M. (2011): "*Enterococcus hirae*-associated endocarditis outbreaks in broiler flocks: Clinical and pathological characteristics and molecular epidemiology", Veterinary Quarterly, 31: 1, 3 — 17.
- Waites, K.B.; Duffy, L.B. and Dowzicky, M.J. (2006): "Antimicrobial susceptibility among pathogens collected from hospitalized patients in the United States and in vitro activity of tigecycline, a new glycycline". Antimicrobial Agents Chemotherapy, American Society for Microbiology. 50, 3479–3484.

استبيان عن عدوى الانتيروكوكس في دجاج التسمين

هشام احمد همام ، مصطفى عبد المطلب شحاته ، هبة الله عبد الحليم ، عمر امين
E-mail: hhammam185@gmail.com Assiut University web-site: www.aun.edu.eg

تم جمع ١١٠ دجاجة (بعضها مريض والآخر نافق) من بعض مزارع التسمين بمحافظة اسيوط وكانت اعمارهم تتراوح من ١-٤ يوم وقد اظهر الفحص الظاهري للطيور المصابة عن اعراض خمول, انتفاش الريش, العرج, ارتعاش الراس واعراض عصبية واسفر الفحص التشريحي عن تضخم بالطحال و الكبد والكلية, احتقان الانسجة تحت الجلد ويقع نزفيه على المخ والتهاب كيس المح في الكتاكيت المصابة, التهاب المفاصل, التهاب عضلة القلب. ايضا تم جمع عدد ٦٥ عينة بيض كابس من مفرخات بلدي مختلفه من محافظة اسيوط , تم أخذ ٤ عينات من كل طائر من ١١٠ دجاج تسمين (الكبد, الطحال, القلب), الامعاء , المفاصل , المخ و ٦٥ عينة بيض كابس وزرعها على:

لمدة ٢٤ ساعة عند ٣٧° مئوية Brain heart infusion broth

ثم زرع كل عينة على: kf strept. agar, bile and esculine azide agar.

وقد امكن عزل ميكروب الانتيروكوكس من عينات الكبد و الطحال والقلب بنسبة (٦١,٨%) ومن عينات الامعاء بنسبة (٥٧,٣%) ومن عينات المفاصل بنسبة (١٠%) ومن عينات المخ (٨,٢%) ومن عينات البيض الكابس بنسبة (٥٢%) مما يدل على ان الميكروب ينتقل عن طريق تلوث البيض المخضب بالميكروب من الامهات او عن طريق التلوث بالزرع. وكانت النتيجة ايجابية للمعزولات في اختبارات

growth at 45°C and growth at 10°C, voges proskaur test, starch hydrolysis test, litmus milk, gelatin hydrolysis.

وسلبية في اختبارات

catalase test, Motility, pigment production

تم تصنيف ميكروب الانتيروكوكس المعزول باستخدام اختبارات

Sugar fermentation test (sucrose, mannitol, sorbitol, l-arabinose)

انتيروكوكس هيري من عينات (الكبد والطحال والقلب) بنسبة (٦٦,٢%) ومن عينات الامعاء بنسبة (٦٦,٧%) ومن عينات المفاصل كانت النسبة (٨١,٨%) ومن عينات المخ بنسبة (٦٦,٧%) ومن عينات البيض الكابس كانت النسبة (٤٤,١%).

انتيروكوكس ديورانس كانت النسب من عينات الكبد والطحال والقلب (٢٢%) ومن عينات الامعاء بنسبة (١٤,٣%) ومن عينات المفاصل (١٨,٢%) ومن عينات المخ (٣٣,٣%) ومن عينات البيض الكابس (٤١,٢%).

وايضا انتيروكوكس فيكالز كانت النسب (١١,٨%) و (١٩%) من عينات (الكبد والطحال والقلب) وعينات الامعاء على التوالي ولم تعزل من عينات المفاصل او المخ.

ومن عينات البيض الكابس كانت النسبة (١٤,٧%).

تم اجراء اختبار العدوى الصناعيه باستخدام عترة الانتيروكوكس هيري (نظرا لانها كانت اكبر نسبة عزل) لكتاكيت دجاج تسمين عمر ٤ ايام عن طريق الحقن في الوريد (وريد الجناح) والحقن في القصبه الهوائيه وكتاكيت مخالطه لكل منهما وادت الى نسبة نفوق ١٠٠% للحقن في الوريد و ٦٠% للكتاكيت المخالطه لها و ٩٠% للحقن في القصبه الهوائيه و ٦٠% للكتاكيت المخالطه لها وكانت اهم الاعراض الاكلينيكيه المسجله على الطيور هي الخمول, انخفاض الشهيه, الامتناع عن الاكل, انتفاش الريش, هزال مع عرج واعراض عصبية واطهرت الصفة التشريحيه احتقان في الانسجة تحت الجلد و في الاعضاء الداخليه كالكلية والقلب مع تضخم في الكبد والطحال والتهابات دمويه في الامعاء وتضخم في الكلية وترسب حمض اليوريك في الحالبين. وقد تم اعاده عزل ميكروب الانتيروكوكس هيري من الحالات المعده صناعيا والمخالطه.

وباجراء اختبار الحساسيه المعملية لميكروب الانتيروكوكس هيري المعزول ضد بعض المضادات الحيويه المختلفه وجد ان نيومايسين والامبيسيلين ثم استربتومايسين و اموكسيسيلين والبنسيلين هي الادويه الاكثر تاثيرا معمليا, كما وجد انه مقاوم تماما لكل من تتراسيكلين و اوكسي تتراسيكلين, تايلوزين, اريثرومايسين, اوكسيسيلين, انروفلوكساسين و كوتريموكسازول.