

Open Surgical Excision of Intracranial Arachnoid Cysts after Initial Procedure Failure in Children

Mohamed M. Elmaghrabi*, Tamer M. Elsanadidy, Ahmed A. Arab

Department of Neurosurgery, Faculty of Medicine, Benha University, Egypt

*Corresponding author: Mohamed M. Elmaghrabi, Mobile: (+20)1222751406, Email: dr_elmaghrabi@yahoo.com

ABSTRACT

Background: Intracranial arachnoid cysts (IAC) are pathological conditions that occur in 2.6% of children. Different surgical procedures had significant failure rate. The objective of the current study is to evaluate the effectiveness of open surgical excision in failed first-other surgery.

Patients and methods: A total of 23 patients with symptomatic arachnoid cysts, with radiological evidence who had had one previous failed surgical intervention, shunting or endoscopic fenestration, underwent open surgical excision of the arachnoid cyst at the Neurosurgery Department of Benha University and Benha Children Hospitals through the period from January 2018 to January 2022.

Results: Children with IAC underwent open surgical excision, totalling 9 (39.1%) cases and partial in 14 (60.9%) cases. In 13 cases, associated microscopic fenestration to basal arachnoid cisterns was done. The mean follow-up period is 28.36 (SD 3.97) months with 77.3% success and 22.7% failure with subsequent treatment by cystoperitoneal shunting. Total excision success is 100%, but partial excision is 64.3%, with 88.9% of them being associated with microscopic fenestration. Mild early transient complications were reported in only 3 cases and were conservatively treated, but late complications occurred in 2 cases.

Conclusion: Open surgical excision of IAC has a very good success rate in the treatment of intracranial arachnoid cysts after initial procedure failure; complete excision should be the main aim whenever possible for optimum results that force us to ask: "Could it be the first line of surgical treatment in symptomatic untreated cases?"

Keywords: Open surgical excision, Intracranial arachnoid cyst, Cystoperitoneal shunting, Children.

INTRODUCTION

Intracranial arachnoid cysts (IAC) are pathological conditions that occur in 2.6% of children (either symptomatic or asymptomatic), with 90% of these occur in the supratentorial area, with 60% in the middle cranial fossa⁽¹⁾. The aetiology of although it is unclear, a splitting or duplication of arachnoid membranes with an accumulation of cerebrospinal fluid via a slit valve mechanism is mostly accepted⁽²⁻⁴⁾.

Most authors suggested surgical intervention as the symptomatic arachnoid cyst had symptoms and signs related to cyst size and expansion with increased intracystic pressure^(5,6).

Different surgical procedures were approached, including aspiration, open surgical excision, endoscopic fenestration, marsupialization, and cystoperitoneal shunting^(3,4,7-8).

Cystoperitoneal shunting and endoscopic fenestration are good surgical options with good results. However, some cases with cystoperitoneal shunting complications and dependency and with ineffective endoscopic fenestration may need open microscopic surgery, aiming for effective fenestration to the basal cistern, marsupialization, or more extensively to partial or complete excision of the arachnoid cyst.

In our study, we evaluated the effectiveness of open surgical excision of an arachnoid cyst in cases with ineffective previous shunting or endoscopic fenestration.

PATIENTS AND METHODS

Study design: this is a prospective clinical cohort study of 23 patients with symptomatic arachnoid cysts with

radiological evidence who had a previous failed surgical intervention, either shunting or endoscopic fenestration were included in this study, and they underwent open surgical excision of the arachnoid cyst at the Neurosurgery Department of Benha University and Benha Children's Hospitals throughout the period from January 2018 to January 2022.

A total of 23 patients were recruited; 13 boys, and 10 girls, ranging in age from 1 year to 9 years (mean age 3.39; SD 2.25). It included one death case in the early postoperative period due to electrolyte imbalance without radiological complications from surgery. The IAC was classified as Sylvian (12/23), Middle Cranial Fossa (5/23), Posterior Cranial Fossa (4/23), and Frontal (2/23).

Preoperative Work-up:

All patients underwent routine physical examinations and received a thorough neurological evaluation. Neuroimaging studies consisted of computerized tomography (CT) and magnetic resonance imaging (MRI).

Clinically, these patients either presented with the same symptoms as before the previous intervention, or showed deterioration after an initial period of clinical improvement. Symptoms included signs of increased intracranial pressure (headache, drowsiness, vomiting, bulging of fontanelles, and an enlarged head), seizures, hemiparesis, and visual obscuration. All patients had a CT scan; those with no improvement or newly developed problems, such as a large compressing subdural hygroma were included in this study. For those who participated in the study, magnetic resonance

imaging was performed for a complete assessment and preparation for surgery. Radiologically, the Sylvian cysts had a mass effect with flattening of the gyri, compression of the brain tissue, causing midline shift and ventricular compression, especially those of Galassi's type II and type III.

Two posterior cranial fossa cysts were associated with hydrocephalus and failed cystoperitoneal shunting as an initial procedure. The clinical and radiological conditions of those included were discussed with their parents, and they agreed to the modality of open surgical excision.

Operative note:

Open craniotomy according to the location was done, and the dura was opened C-shaped except for the posterior fossa (**Figure 1**). It was Y-shaped after a careful dissection of the underlying arachnoid layer as a separate layer, attempting full removal of the part just beneath the dura. The sac might be opened during this stage, but a complete release from the dura was

attempted. The wall of the arachnoid cyst was followed laterally and was stripped carefully off the underlying pia matter. Some parts of the cyst wall were sticky to the pia and a possible pial injury might have happened. These parts were left and the arachnoid cyst wall was dissected around them.

The walls of the arachnoid cyst (a thick wall usually) were followed to the bottom towards the basal cisterns (as in Sylvian cysts) or surface of the brain (as in convexity cysts), then a wide connection with the basal cistern was made if we could microscopically. Careful watertight closure of the dura was done after meticulous hemostasis.

The craniotomy flab was replaced and secured with absorbable sutures. The skin was closed in layers after placement of a subcutaneous drain. Open surgical procedures were classified into total (or near total with a small area of adherent arachnoid membrane to pia or significant blood vessel) and partial excision (marsupialization) as in **Figure 2**.

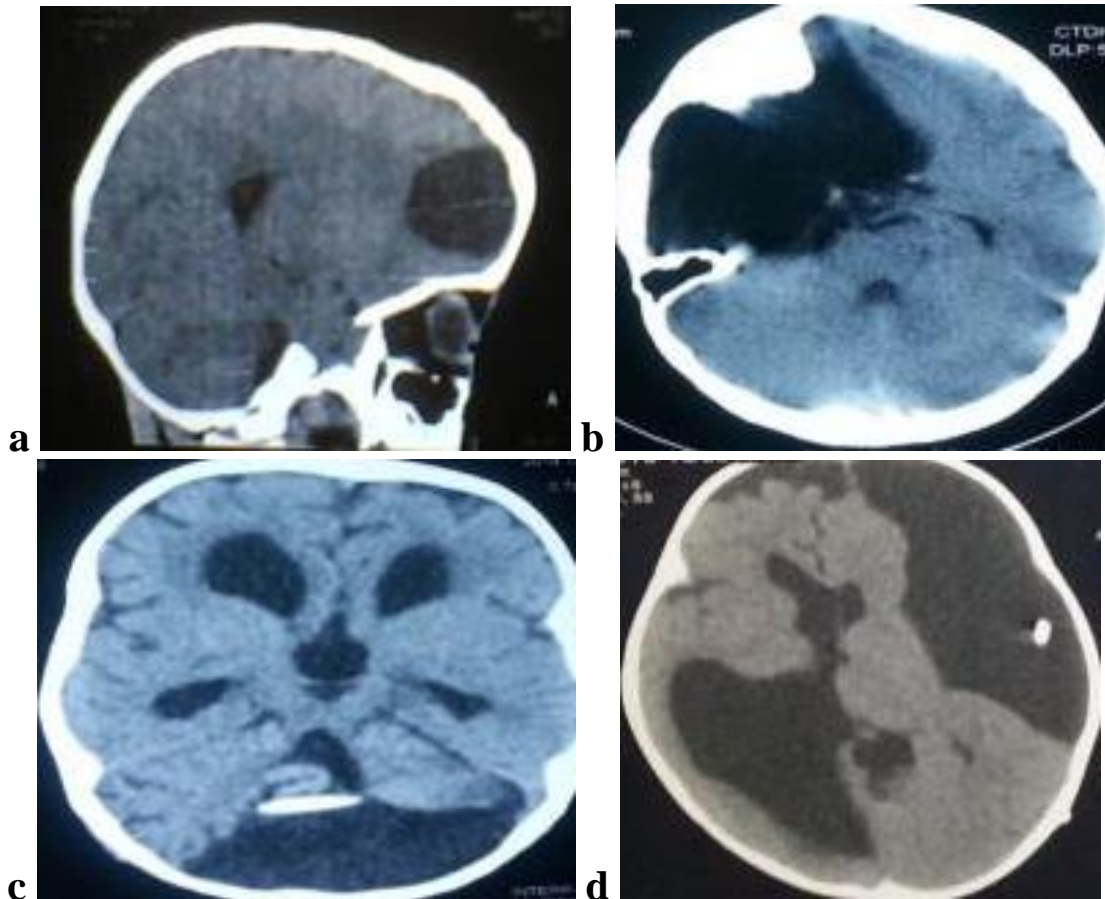


Figure (1 a-d): Types 0 f IAC in studied group (CT brain, a. sagittal b-d. axial cuts); a) frontal pole, b) middle cranial fossa, c) posterior fossa and d) fronto-temporo-parietal. a&b) failed endoscopic fenestration, c&d) failed cystoperitoneal shunting.

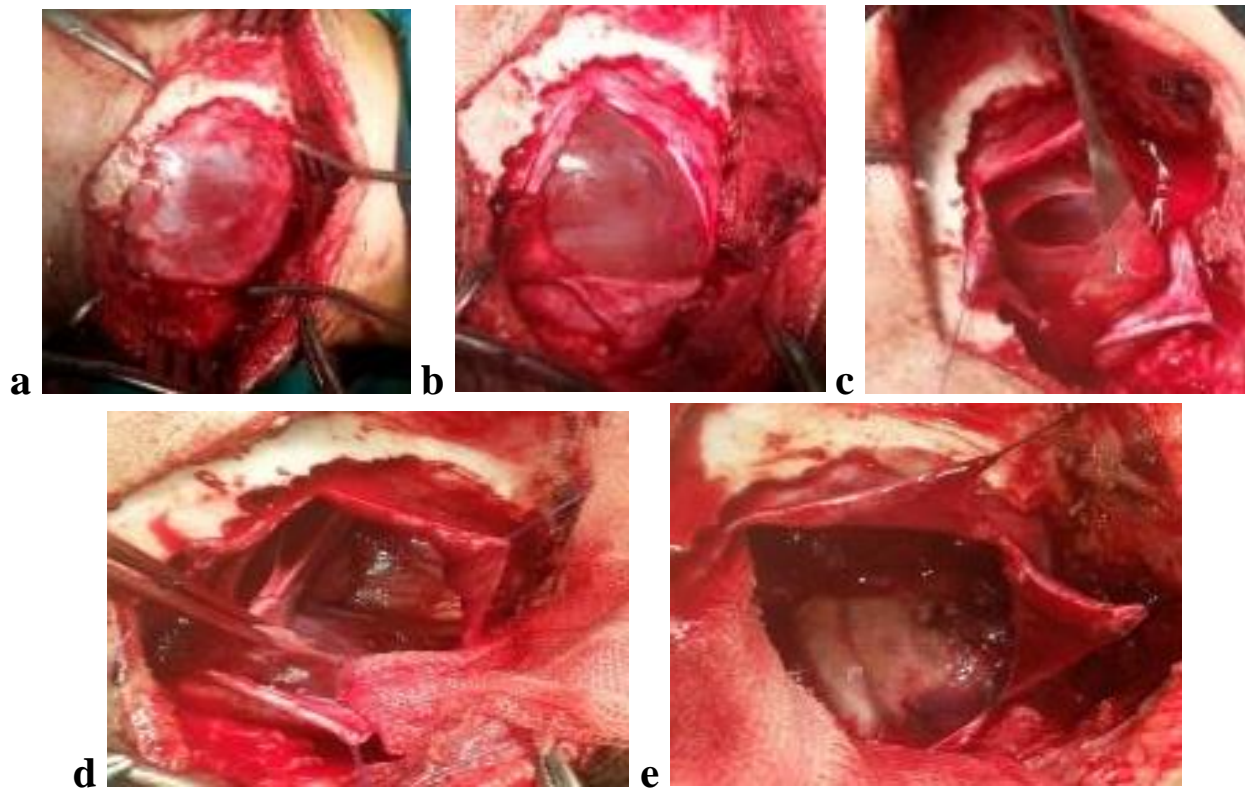


Figure (2 a-e): Operative steps of total excision of posterior fossa IAC; a) Open craniectomy of posterior fossa bone, b) Y-shaped dura was opened with a carefully dissection of the underlying arachnoid layer as a separate layer, c) opening of the outer layer of arachnoid with its fluid was evacuated, d) inner arachnoid layer was stripped carefully off underlying pia matter and e) successive complete cyst excision.

Postoperative follow up:

An early postoperative CT scan was performed to rule out early postoperative complications. Patients were then followed clinically and radiologically for 23 to 37 months (mean 28.36 3.97, range 23-37 months). Scan was done at 3 months and 6 months. Then, patients who were followed clinically, a CT scan was done for the first time postoperatively at 12–18 months. All intraoperative complications and clinical states postoperatively were collected and reviewed.

Ethical approval:

This research approved by Research Ethics Committee of Faculty of Medicine, Benha University.

The reference number of the ethics approval from the ethics committee: F 10, serial number 81, date of approval 14/8/2018. A written informed consent was obtained from each parent of participants after explaining all steps of this study. This work has been carried out in accordance with The Code of Ethics of the World Medical Association (Declaration of Helsinki) for studies involving humans.

Statistical analysis

The collected data were coded, processed and analyzed using the SPSS (Statistical Package for Social Sciences) version 22 for Windows® (IBM SPSS Inc, Chicago, IL, USA). Quantitative data were analyzed using mean and standard deviation, while frequency and percentage were used with qualitative data. Fischer exact test was used to analyze qualitative data and Z test was used to compare proportions. A P-value ≤ 0.05 was considered statistically significant (*) while > 0.05 statistically insignificant.

RESULTS

A total of 23 children with IAC underwent open surgical excision; 13 boys and 10 girls. The mean age was 3.39 (SD 2.25), which ranged from 1 to 9 years. A total of 17 (73.9%) cases were diagnosed as both clinical and radiological, but only 6 (26.1%) cases were accidentally (radiological only) discovered.

Table 1 and **Figure 3** show that the classification of IAC, according to site, into fronto-temporo-parietal (Sylvian) (52.2%), middle cranial fossa (21.7%), posterior cranial fossa (17.4%) and frontal pole (8.7%). About 69.6% of cases are failed shunts, but only 30.4% failed endoscopic fenestration.

Table (1): Sociodemographic data of the children with IAC who underwent open surgical excision.

Variable	Value (23 children)
Age /y	
Mean ± SD	3.39 ± 2.25
Range	1-9
Sex n (%)	
Male	13 (56.5)
Female	10 (43.5)
Diagnosis n (%)	
Clinical & radiological	17 (73.9)
Radiological only	6 (26.1)
Site n (%)	
Fronto-temporo-parietal (Sylvian)	12 (52.2)
Middle cranial fossa	5 (21.7)
Posterior cranial fossa	4 (17.4)
Frontal pole	2 (8.7)
Previous operation n (%)	
Shunt	16 (69.6)
Endoscopic fenestration	7 (30.4)
Excision n (%)	
Total	9 (39.1)
Partial	14 (60.9)
Associated microscopic fenestration n (%)	
Yes	13 (56.5)
No	10 (43.5)
Success n (%)*	
Yes	17 (77.3)
No	5 (22.7)
Follow up period*	
Mean ± SD	28.36 ± 3.97
Range	23-37

*n=22 due to death of one case in early postoperative period.

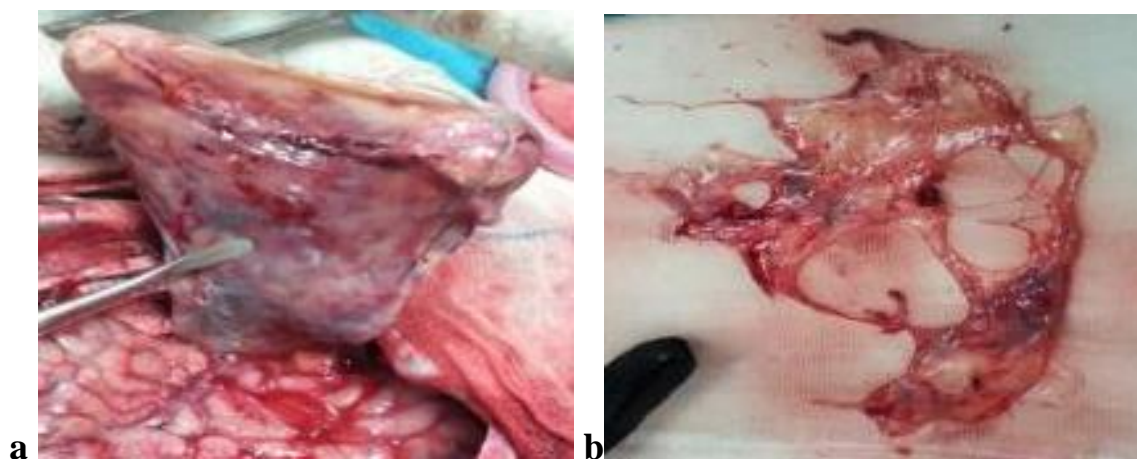


Figure (3 a, b): Types of IAC excision; a) total and b) partial excision.

Open surgical excision includes a total of 9 (39.1%) cases and partial in 14 (60.9%) cases. In 13 cases, associated microscopic fenestration to basal arachnoid cisterns was done. The dead case is excluded from the success results, so the total number of cases becomes twenty-two. The mean follow-up period is 28.36 (SD 3.97) months with 17 (77.3%) cases succeeding, improving both clinically (mild transient complications) and radiologically (complete disappearance, **Figure 4**, or 60% decrease in size with no mass effect nor midline shift, **Figure 5**), rather than failure, which occurs in only 5 (22.7%) cases with subsequent treatment by cystoperitoneal shunting. Transient early complications include surface brain contusion in two cases; one of them had transient monoparesis; and 1 case of superficial wound infection, which all were conservatively treated. One case suffered from cerebrospinal fluid leakage in the early postoperative period, resulting in failure, and a shunt operation was performed. Late complications occur in 2 patients with ipsilateral subdural hygroma, conservatively treated, and 1 patient with subacute subdural hematoma after mild head trauma, operated by one burr hole evacuation without recollection (**Figure 5.d**).

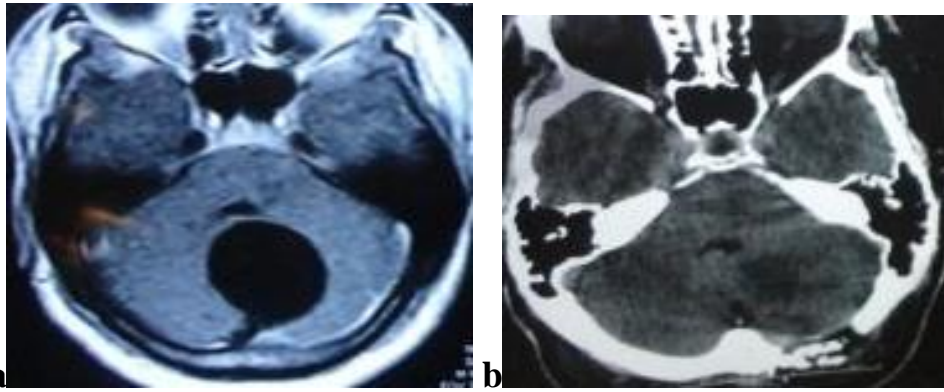


Figure (4 a,b): Radiological results of posterior fossa IAC total excision; a) preoperative MRI brain axial cut, and b) one week postoperative CT brain axial cut shows disappearance of the cyst.

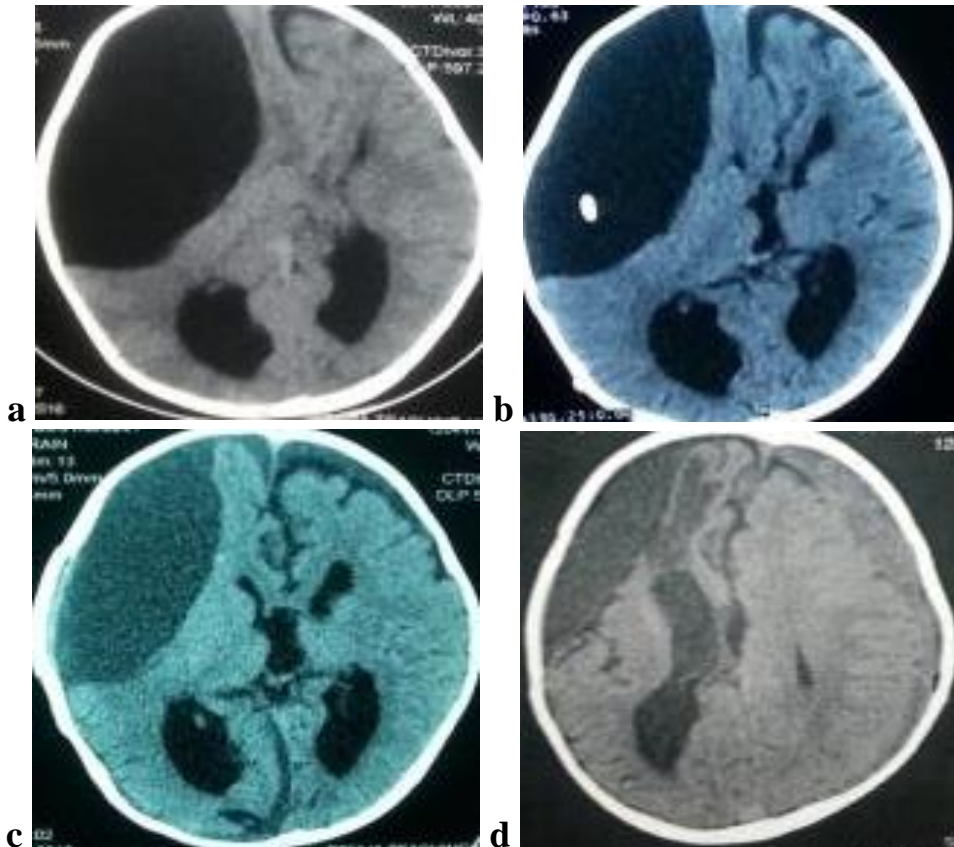


Figure (5 a-d): Radiological results of cystoperitoneal shunting and partial excision of large fronto-temporo-parietal IAC in 3 years old boy (CT brain axial images); a) pre shunting, b) 2 months post shunting with mild decrease in size and midline shift still present (complicated by shunt nephritis), c) 1 month post partial excision with fenestration shows opening of Rt ventricular horn and improved midline shift and d) 8 months post partial excision with more than 60% reduction of cyst size (measured intra-cystic pressure= 15 cm H₂O) and subdural hematoma was evacuated later.

Table 2 shows that success occurs in 8 (47.1%) cases of total excision and 9 (52.9%) cases of partial excision of all successful patients, but all 5 failed cases are done in partial excision, with no failure in total excision. The success rate is highly statistically significant (p 0.001). Total excision success is (8 of 8) 100%, but partial excision is (9 of 14) 64.3%.

Table (2): Success according to types of open surgical IAC excision

Success Excision	Succeed (16)	Failed (5)	Total	Z test	P-value
Total	8 (47.1)	0 (0.0)	8 (36.4)	-1.12	-0.13
Partial	9 (52.9)	5 (100)	14 (63.6)		
Total	17 (100)	5 (100)	22 (100)	3.05	0.001*

On comparison of the success of partial excision with and without microscopic fenestration, table 3 shows that 88.9% of success is associated with microscopic fenestration but only 11.1% without. Associated microscopic fenestration in partial excision is statistically highly significant in successful and total cases, p 0.001 and 0.004, respectively, but insignificant in failed cases (p 0.32).

Table (3): Success according to associated microscopic fenestration among group of partial IAC excision.

Success Fenestration	Succeed (9)	Failed (5)	Total
Yes	8 (88.9)	3 (60.0)	11 (78.6)
No	1 (11.1)	2 (40.0)	3 (21.4)
Total	9 (100)	5 (100)	14 (100)
Z test	3.71	0.46	2.61
P value	0.001*	0.32	0.004*

As shown in table 4, there is no statistically significant difference between different sites and different types of previous surgery regarding the success of open IAC surgery. The five failed cases, according to the site, are divided into three cases of fronto-temporo-parietal, one middle cranial fossa, and one posterior cranial fossa.

Table (4): Success according to the type of previous surgery and the site

Success	Succeed	Failed	Total	Fischer exact tes	P-value
Site n (%)					
-Fronto-temporo-parietal	9 (75)	3 (25)	12 (100)	0.36	0.95
-Middle fossa	4 (80)	1 (20)	5 (100)		
-Posterior fossa	3 (75)	1 (25)	4 (100)		
-Frontal pole	1 (100)	0 (0.0)	1 (100)		
Type of Previous Surgery n (%)					
-Shunt	12 (75)	4 (25)	16 (100)	0.17	0.68
-Endoscopic fenestration	5 (83.3)	1 (16.7)	6 (100)		

DISCUSSION

Symptomatic intracranial arachnoid cysts are to be treated, and asymptomatic arachnoid cysts with large size, brain tissue compression, or exerting mass effect should also be treated when there is a fear of clinical worsening or intracystic haemorrhage, whether spontaneous or traumatic (8). The asymptomatic IAC treatment protocol is to observe for clinical or radiological worsening. Children below 4 years should have serial imaging and those over 4 years should be followed clinically. Symptomatic IAC progression as hydrocephalus, localizable seizures, focal neurological deficit and disfigurement are indications for surgery (9).

There are many surgical intervention options for treating arachnoid cysts, including cyst tapping, cystoperitoneal shunting, ventriculocystostomy, cystocisternostomy, microsurgical cyst fenestration, and microsurgical cyst excision (7,10).

Because of the effectiveness, simplicity, and complications associated with each procedure, it is still debatable which of these procedures is superior to the others. A surgical procedure is chosen according to the type of arachnoid cyst. In an international survey of sylvian cyst surgeons, 66.6% agreed that direct surgery with excision and marsupialization is the most effective method, while only 28.8% chose pure or assisted endoscopic cyst marsupialization. Cystoperitoneal shunting was the least suggested option (8). Still, suprasellar arachnoid cysts had a general consensus with endoscopic fenestration (11-14). Many studies discussing the effectiveness of surgical procedures or comparing the results of different types of surgical procedures worked on primary cases of intracranial arachnoid cysts or did not separate the previously failed cases (6,15,16). In our study, we focused on the previously failed cases with shunting and endoscopic fenestration and offered open surgical excision for removal of the pathology as an effective surgical option.

Cystoperitoneal shunting is a surgical treatment option that could achieve a good rate of cyst elimination but had several complications. It offered a gradual decrease in the cystic cavity rather than a shifting in cyst pressure dynamics, and also this option is weakened by shunt failure, unexpected haemorrhage, infection, and shunt dependency (18-20). This option is not feasible for certain locations, such as suprasellar arachnoid cysts, and could injure important surrounding structures in suprasellar and posterior fossa arachnoid cysts. Furthermore, cystoperitoneal shunting had a high risk of shunt-related complications, such as slit cyst syndrome (15,21-22). And on attempting removal of the shunt system, some cases may show typical symptoms of pseudo-tumour cerebri, which might also occur with shunt malfunction (16). So, since cystoperitoneal shunting- was not our surgical plan for our secondary cases, we had to do it again. Five cases in this study who failed to improve after partial excision (22.7%) underwent cystoperitoneal shunting. They passed smoothly during the period of follow up. Perhaps a change in pressure dynamics and CSF pathway flow

after partial excision and attempting fenestration led to a good result, and still these cases will be followed.

Endoscopic fenestration is used in situations where direct microsurgery is difficult or may cause harm to important neurological structures, such as in cases of suprasellar arachnoid cysts, and it has been used in various locations with good results, but it has several limitations, and it is of limited use in small IAC at hemispheric, temporal, and posterior fossa areas with difficult fenestration towards a normal CSF cistern by endoscope⁽²⁴⁾. However, to be fair, endoscopic techniques are improving with the introduction of new approaches and techniques as well as with gaining more experience and skills. Many authors reported safe and effective management of arachnoid cysts in different regions. Some arachnoid cysts are still not approached by endoscope as interhemispheric arachnoid cysts⁽²⁵⁻²⁷⁾.

Most endoscopic systems permit the use of a single surgical instrument at any given time with difficulty in attempting to control intraoperative bleeding, which is a major cause of failed endoscopic fenestration. Manipulations are limited along the trajectory of the instrument to certain angles only. This is not the same in microsurgery, where easy manipulation of multiple instruments at different angles is free with no disturbance in the visual field. Visualization is limited in endoscopy and is directed towards the main trajectory, so the wall of the cyst cannot be visualized thoroughly and clearly. Fenestration is done in endoscopy using a blunt instrument to perforate the cyst wall, then augmentation is done with caution. This is totally different to microsurgery as the cyst wall is left dissected away from brain tissue before its opening protects important vessels and fenestration is usually wide and effective using special microsurgical instruments. This difference is technically significant. As described, it is clear why radiological resolution with microsurgery is superior with open microsurgery than with endoscopic fenestration⁽²⁸⁻³¹⁾. But as some surgeons offer the resolution of symptoms (clinical improvement) as a more reliable indicator than radiological resolution, endoscopic fenestration results are comparable to open microsurgery⁽³²⁾. Surgical options are directed towards IAC location, and as endoscopic fenestrations are better for suprasellar and quadrigeminal cysts, extra-cerebral, spheric, and intra-cerebrum IACs are better approached by open microsurgical craniotomy⁽³³⁾. Open surgical techniques had been considered too aggressive compared to minor symptoms of an arachnoid cyst⁽²⁴⁾.

Craniotomy and open surgery allowed for direct cyst inspection, sampling, and easy fenestration to the basal cistern in certain areas, aside from easy fenestration of multi-loculated IAC into one cyst before fenestration into the cistern⁽³⁴⁾. It also offers greater safety with the use of microsurgical instruments, adequate visualization of neural and vascular structure, and better bleeding control⁽³⁵⁾. Operative mortality and morbidity rates were not infrequently reported. Major

complications included meningitis, hemiparesis, oculomotor palsy, subdural hematoma, seizures, and even death⁽¹⁹⁾. This was disappointing, we think, and a more simple procedure was introduced, and although it had succeeded, it also showed comparable pitfalls. Other recent reports showed excision had fewer complications in the short and long run than reported before⁽¹⁶⁻²⁴⁾. Others believe that for effective decompression of the cyst, complete removal of the cyst wall is neither possible nor necessary, and that partial excision of the arachnoid cyst and opening to the basal cistern or ventricle has been proven to be an effective and safe procedure⁽⁷⁾.

In this study, open microsurgical procedures achieved total excision in 8 (36.4%) of 22 patients, and partial excision in 14 (63.6%). All cases of total excision did well in follow-up with no need for further intervention. While 5 out of 14 patients with partial excision failed to attempt good clinical or radiological improvement, they were subjected to redo surgery with shunting again, but their follow up later was not included in this study. The difference in results between total and partial excision in this study was statistically significant, favouring total excision, and thus attempting total or near total excision is better to achieve a good outcome. Fenestration done for partially excised IAC significantly yields a successful outcome in comparison to partially excised IAC without fenestration. The 5 failed cases showed no significant difference between fenestrated and non-fenestrated cases, implying failure due to inability of IAC self-resolution in non-fenestrated partially excised IAC, but this hypothesis is being debated due to the small number of cases. Older authors in the 1980s, such as Frazier, preferred total resection of the IAC wall. However, recent studies on open surgery advocated partial resection with communication to the ventricular system or basal cistern rather than complete wall resection. They attempted excision of the outer wall with respect to the inner wall adherent to the brain surface, and then they performed the communication. The main complications of open surgery are brain bruising with neurological deficit that has become lower with recent microsurgical techniques, occasional third and sixth nerve affection, which is usually transient, and late complications such as fenestra fibrosis leading to recurrence, and basal cistern fibrosis leading to hydrocephalus⁽³⁵⁾. Ali *et al.* discussed the comparative effectiveness of surgical procedure options in paediatric intracranial arachnoid cysts, and although they concluded comparable effectiveness, excision had the lowest rate of complications followed by endoscopic fenestration and primary shunting. More complications occurred with open fenestration. Excision also had the lowest rate of re-operation and further procedures needed. Shunting and excision were the best for cyst size reduction after surgery, but shunting had more postoperative complications and the possibility of re-operation than excision⁽²⁴⁾. Our results in this study in

which excision was done secondarily to a failed procedure were encouraging and the low rate of complications that were transient and easily managed proved the safety and effectiveness of this procedure.

In the light of comparable results between different treatment options, it is the surgeon's decision to choose simple surgery when he approaches IAC for the first time, like shunting and endoscopic fenestration, but he may need to go with excision when reoperation is needed after evident failure of the primary surgery, so why not consider this option as a first line for symptomatic IAC treatment for relatively better and more consistent results? Of course, this is not applicable for suprasellar and quadrigeminal IAC, where endoscopic fenestration is still leading.

In conclusion, open surgical excision of IAC has a very good success rate with mild transient few complications when used after failure of primary shunting or endoscopic fenestration. Total excision has superiority over partial excision. For optimum results, associated microscopic fenestration is mandatory with partial excision. We advise giving open surgical excision the chance to be the first line of surgical treatment for symptomatic IAC.

Financial support and sponsorship: Nil.

Conflict of interest: Nil.

REFERENCES

1. Al-Holou W, Yew A, Boomsaad Z *et al.* (2010): Prevalence and natural history of arachnoid cysts in children. *J Neurosurg Pediatr.*, 5:578-585.
2. Caemaert J, Abdullah J, Calliauw L *et al.* (1992): Endoscopic treatment of suprasellar arachnoid cysts. *Acta Neurochir (Wien)*, 119:68-73.
3. Choi J, Kim D, Huh R (1999): Endoscopic approach to arachnoid cyst. *Childs Nerv Syst.*, 15:285-291.
4. Schroeder H, Gaab M (1997): Endoscopic observation of a slit valve mechanism in a suprasellar prepontine arachnoid cyst: case report. *Neurosurgery*, 40:198-200.
5. Oberbauer R, Haase J, Pucher R (1992): Arachnoid cysts in children: a European co-operative study. *Childs Nerv Syst.*, 8:281-286.
6. Kang J, Lee K, Lee I *et al.* (2000): Shunt-independent surgical treatment of middle cranial fossa arachnoid cysts in children. *Childs Nerv Syst.*, 16:111-116.
7. Galassi E, Gaist G, Giuliani G *et al.* (1988): Arachnoid cysts of the middle cranial fossa: experience with 77 cases treated surgically. *Acta Neurochir.*, 1988, 42:201-204.
8. Tamburrini G, Dal Fabbro M, Di Rocco C (2008): Sylvian fissure arachnoid cysts: a survey on their diagnostic workout and practical management. *Childs Nerv Syst.*, 24:593-604.
9. Jafrani R, Raskin J, Kaufman A *et al.* (2019): Intracranial arachnoid cysts: Pediatric neurosurgery update. *Surg Neurol Int.*, 10:15-19.
10. Rappaport Z (1993): Suprasellar arachnoid cysts: options in operative management. *Acta Neurochir (Wien)*, 122:71-75.
11. Charalampaki P, Filippi R, Welschehold S *et al.* (2005): Endoscopic and endoscope-assisted neurosurgical treatment of suprasellar arachnoid cysts (Mickey Mouse cysts). *Minim Invasive Neurosurg.*, 48: 283-288.
12. Ersahin Y, Kesikci H, Ruksen M *et al.* (2008): Endoscopic treatment of suprasellar arachnoid cysts. *Childs Nerv Syst.*, 24:1013-1020.
13. Gangemi M, Colella G, Magro F *et al.* (2007): Suprasellar arachnoid cysts: endoscopy versus microsurgical cyst excision and shunting. *Br J Neurosurg.*, 21:276-280.
14. Pei A, Zhang Y, Zong X *et al.* (2007): Endoscopic treatment of suprasellar arachnoid cysts. *Zhonghua Yi Xue ZaZhi.*, 87:311-314.
15. Alexiou G, Varela M, Sfakianos G *et al.* (2010): Shunting for the treatment of arachnoid cysts in children. *Neurosurgery*, 67:1632-1636.
16. Shim K, Lee Y, Park E *et al.* (2009): Treatment option for arachnoid cysts. *Childs Nerv Syst.*, 25:1459-1466.
17. Zhang B, Zhang Y, Ma Z (2012): Long-term results of cystoperitoneal shunt placement for the treatment of arachnoid cysts in children. *J Neurosurg Pediatr.*, 10:302-305.
18. Arai H, Sato K, Wachi A *et al.* (1996): Arachnoid cysts of the middle cranial fossa: experience with 77 patients who were treated with cystoperitoneal shunting. *Neurosurgery*, 39:1108-1112.
19. Aoki N, Sakai T (1990): Intraoperative subdural hematoma in a patient with arachnoid cyst in the middle cranial fossa. *Childs Nerv Syst.*, 1990, 6:44-46.
20. Raffel C, McComb J (1988): To shunt or to fenestrate: which is the best surgical treatment for arachnoid cysts in pediatric patients? *Neurosurgery*, 23:338-342.
21. Harsh G, Edwards M, Wilson C (1986): Intracranial arachnoid cysts in children. *Journal Neurosurg.*, 64:835-842.
22. Kim S, Cho B, Chung Y *et al.* (2002): Shunt dependency in shunted arachnoid cyst: a reason to avoid shunting. *Pediatr Neurosurg.*, 37:178-185.
23. Turhan T, Ersahin Y, Akinturk N *et al.* (2012): Fenestration methods for Sylvian arachnoid cysts—endoscopy or microsurgery. *Childs Nerv Syst.*, 28:229-235.
24. Ali Z, Lang S, Bakar D *et al.* (2014): Pediatric intracranial arachnoid cysts: comparative effectiveness of surgical treatment option. *Childs Nerv Syst.*, 30:461-469.
25. Mustansir F, Bashir S, Darbar A (2018): Management of Arachnoid Cysts: A Comprehensive Review. *Cureus*, 10(4):e2458. doi: 10.7759/cureus.2458
26. Fayed A, Ibrahim T, Rayan T (2021): Endoscopic management of periventricular and intraventricular arachnoid cysts. *Egypt J Neurosurg.*, 36(24):1-9.
27. Raju S, Sharma R, Moningi S *et al.* (2016): Neuroendoscopy for Intracranial Arachnoid Cysts in Infants: Therapeutic Considerations. *J Neurol Surg A Cent Eur Neurosurg.*, 77(4):333-343.
28. Di Rocco F, James R, Roujeau T *et al.* (2010): Limits of endoscopic treatment of sylvian arachnoid cyst in children. *Childs Nerv Syst.*, 26:155-162.
29. Karabatsou K, Hayhurst C, Buxton N *et al.* (2007): Endoscopic management of arachnoid cysts: an advancing technique. *J Neurosurg.*, 106:455-462.
30. Spacca B, Kandasamy J, Mallucci C *et al.* (2010): Endoscopic treatment of middle fossa arachnoid cysts: a series of 40 patients treated endoscopically in two centres. *Childs Nerv Syst.*, 26:163-172.
31. Elhammady M, Bhatia S, Ragheb J (2007): Endoscopic fenestration of middle fossa arachnoid cysts: a technical description and case series. *Pediatr Neurosurg.*, 43:209-215.
32. Greenfield J, Souweidane M (2005): Endoscopic management of intracranial cysts. *Neurosurg Focus*, 19:7-11.
33. Wang C, Han G, You C *et al.* (2013): Individual surgical treatment of intracranial arachnoid cyst in pediatric patients. *Neurol India*, 61(4):400-405.
34. Pulido-Rivas P, Villarejo-Ortega F, Cordobés-Tapia F *et al.* (2005): Surgical treatment of symptomatic arachnoid cysts in children. *Rev Neurol.*, 41(7):385-390.
35. Saura Rojas J, Horcajadas Almansa Á, RosLópez B (2016): Microsurgical treatment of intracranial arachnoid cysts. *Neurocirugía (Astur)*, 27(1):24-27.