

Gastroprotective and Healing Effect of Naringin and Quercetin in Experimentally Induced Gastric Ulcer by Diclofenac Sodium in Adult Male Albino Rat: A Histological and Immunohistochemical Study

Hend Ragab Mousa*, Nehal Fahmy Shaheen

Anatomy and Embryology, Benha Faculty of Medicine, Benha University

*Corresponding author: Hend Ragab Mousa, Mobile: (+20) 1222898035, E-mail: drhendragab@yahoo.com

ABSTRACT

Introduction: Diclofenac (DFC) has been widely utilized as anti-inflammatory and analgesic medication. Naringin is a natural flavanone glycoside that is found in citrus fruits. Quercetin is a natural flavonoid found in vegetables and fruits.

Aim: evaluation of the roles of naringin and quercetin in protection and recovery of rats' stomach ulcers caused by DFC.

Material and methods: Forty male albino adult rats were divided into 4 identical groups: Control group, (DFC) group: rats were given 10 mg/kg b.w. /day DFC by oral gavage for 4 weeks, (DFC + Naringin) group: rats were given 100 mg/kg/body weight naringin daily along with previous dose of DFC dose for 4 weeks and (DFC + Quercetin) group: rats were given 50 mg/kg body weight quercetin daily along with previous dose of DFC. The stomach tissues were examined grossly and processed for microscopic examination.

Results: DFC group revealed ulceration of mucosa resulting in detachment of fundic mucosa, inflammatory infiltration, and wide lumen of fundic glands. There was a thin, sporadic PAS-AB mucous coating over the surface epithelium. It showed extensive iNOS immunoreaction in the cytoplasm of gastric epithelial cell and strong PCNA immun-expression in the cells lining the fundic glands. Both naringin and quercetin exhibited a protective effect by prevention of histopathological changes caused by DFC on gastric mucosa. There is a persistent, thick mucus coating covering the surface epithelium, weak iNOS immunoreaction and moderate PCNA.

Conclusion: The intake of naringin during taking diclofenac protects the stomach mucosa but quercetin has more protection than naringin.

Keywords: Diclofenac, naringin, Quercetin, ulcer.

INTRODUCTION

One of the most prevalent gastrointestinal disorders is gastric ulcer⁽¹⁾. It results from an imbalance between the digestive factors, including prostaglandins and blood flow, and the aggressive factors, including gastric acid and pepsin⁽²⁾. Due to their excellent effectiveness against pain and inflammation, nonsteroidal anti-inflammatory drugs (NSAIDs) are among the world's most frequently prescribed medicines⁽³⁾. Despite their ability to reduce inflammation, they have a variety of negative side effects⁽⁴⁾. Diclofenac, a member of this class of medications, it is a phenylacetic acid derivative that has long been used to treat a variety of illnesses as an analgesic and anti-inflammatory medication⁽⁵⁾. Diclofenac's adverse effects are brought on by oxidative stress and the suppression of the antioxidant defense system⁽⁶⁾. Natural therapies are a key component in the treatment and prevention of stomach ulcers⁽²⁾. Numerous plant species, particularly citrus fruits, contain the flavanone glycoside naringin (NA), which is generated from the flavanone naringenin⁽⁷⁾. NA has actions against allergies, ulcers, inflammation, cancer, osteoporosis, and free radicals⁽⁸⁾.

A flavonoid called quercetin (QU) is present in a variety of plants, vegetables, and seeds⁽⁹⁾.

The antioxidant, anti-inflammatory and free radical-scavenging capabilities of quercetin are partially responsible for its anti-ulcer actions⁽¹⁰⁾. The strong anti-inflammatory actions of quercetin are primarily achieved via cytokine suppression⁽¹¹⁾.

The purpose of this study is to assess the roles of naringin and quercetin on protection and curing of gastric ulcers in rats caused by DFC.

MATERIAL AND METHODS

Animals:

Forty adult albino male rats that were 2 months old and weighed between 180 and 200 grams were used in this study. The laboratory animals' department at the faculty of veterinary medicine at Benha University in Egypt is where we obtained the rats. To prevent any metallic contact, the rats were housed in plastic cages. The lab conditions were ambient, at a temperature of $20 \pm 2^{\circ}\text{C}$ with exposure to a planned illumination cycle (light/dark 14 hours/dark 10 hours). Water and regular food were permitted.

Ethical approval:

All aspects of this research approved from the Ethics Committee of the Faculty of medicine, Benha University, Benha, Egypt.

The study conformed to "Guide for the care and use of Laboratory Animals" for the use and welfare of experimental animals, published by the US National Institutes of Health (NIH publication No. 85-23).

Reagents:

-Diclofenac sodium was purchased from El Nasr Pharmaceutical Co. (ADWIC). It was obtained in the

form of tablets (50mg) that were crushed and dissolved in 1% sodium carboxymethyl cellulose (CMC).

-Naringin was purchased from Sigma Chemical Co. (CAS Number: 10236-47-2, purity \geq 95%, molecular weight (580.53), and 71162-25 G) (St. Louis, Mo, U.S.A.) in the form of powder and dissolved in distilled water immediately before its administration.

- Quercetin 500 mg capsule was purchased from Global Mart India and fulfilled by Amazon. It was suspended in 1% sodium (CMC) immediately before its administration.

The design of the experiment

After a week of housing, the rats were separated into four equal groups each ten rats.

Group I (control group): They were separated into three subgroups:

Subgroup Ia: consists of four rats, left without treatment during the time of the experiment.

Subgroup Ib: consists of three rats, they were given 1 ml of 1% sodium CMC administered by oral gavage.

Subgroup Ic: consists of three rats, they were given distilled water by oral gavage.

Group II (DFC group): consists of ten rats that received daily oral gavage treatment with diclofenac 10 mg/kg body weight daily for 4 weeks ⁽¹²⁾.

Group III (DFC + Naringin): consists of ten rats that received 100 mg/kg/ body weight of naringin along with a dosage of 10 mg/kg/body weight daily by gastric tube for four weeks ⁽¹³⁾.

Group IV (DFC + Quercetin): consisting of ten rats that received quercetin at a dose 50 mg/kg b.wt along with DFC at a dose 10 mg/kg/ body weight daily by gastric tube for four weeks ⁽¹⁴⁾.

Assessment of ulcer index:

The stomach was gently stretched over a white sheet of paper after being cut along its larger curvature and examined for macroscopical mucosal lesions by using dissecting microscope.

The ulcer index is the expression of gastric mucosal lesions. It is calculated using a 0–3 grading scale based on the severity of each lesion. Severity level; no lesion=0, lesion < 1 mm in length=1, lesion 2-4 mm in length=2 and lesion >4mm in length=3. A vernier caliper was used to measure the length of the ulcers. The number of lesions in each rat was multiplied by the severity factor for each lesion, and this resulted in the rat's overall lesions score. For each group the mean ulcer index was obtained by calculating the total scores divided by the number of rats in that group ⁽¹⁵⁾.

Histological Techniques:

The rats were sacrificed under anesthesia with sodium pentobarbital given intraperitoneally

(Nembutal, 30 mg/kg body weight) at the end of the experiment, and then sacrificed. For a light microscopic examination, the stomach tissues have been prepared. They were handled to obtain paraffin slices with a thickness of 5 μ m after being fixed in 10% formalin for a day.

The stains used on the sections were:

- **Hematoxylin and Eosin (H&E)** in each group to demonstrate the general histological structure ⁽¹⁶⁾.
- **Periodic Acid Schieff -Alcian Blue stain** :(PAS-AB stain) for revealing of neutral and acidic mucin ⁽¹⁶⁾.

Immunohistochemical examination:

- **iNOS :**

Primary antibodies were used to identify Inducible Nitric Oxide Synthase antigen by incubation for 1 hour at room temperature with rabbit anti-iNOS polyclonal antibody (Invitrogen, PA1-036, USA) with 1:20 dilution ⁽¹⁷⁾.

- **PCNA :**

Primary antibodies were used to identify (PCNA) proliferating cell nuclear antigen using the avidin-biotin peroxidase method (anti-PCNA monoclonal antibody, dilution 1: 400-800, obtained from Lab Vision Company) ⁽¹⁷⁾.

Morphometrical study

Serial sections stained with iNOS and PCNA immunohistochemical staining and PAS-AB stained sections were morphometrically evaluated. This was done in 5 separate sections in non-overlying fields from 5 different rats in each group using Leica Qwin 500 image analyzer computer system to detect:

(a) Area % of (PAS–AB reaction) was measured in sections stained with (PAS-AB) stain at a magnification of \times 100.

(b) Area% of iNOS immunopositive reaction in sections stained with iNOS immunostain at a magnification of \times 200.

(c) Area% of PCNA immunopositive reaction in sections stained with PCNA immunostain at a magnification of \times 200.

Statistical analysis

The data were presented in form of (mean \pm standard deviation). The information obtained from the image analyzer were subjected to (SPSS program; SPSS Inc., Chicago, IL, version 20.0 for windows.). The results were considered to be significant when the (P) value was \leq 0.05.

RESULTS

Gross morphology:

In the control group, the gastric mucosa was bright and normal looking, with rugae but no obvious lesions. Contrarily, examination of the gastric mucosa of DFC-

treated rats revealed congested mucosa and multiple ulcers. The groups that were given quercetin or naringin with DFC displayed mild ulceration and redness of the mucosal layer. Fig (1).

Gastric ulcer index (UI):

In table (1), UI was significantly higher in the DFC rats versus the control rats. (P< 0.05). In treated rats with QU or NA with DFC, UI was significantly decreased versus DFC only treated rats (P< 0.05).

Table (1): Protecting effect of quercetin and naringin against DFC-induced gastric ulcer in rats as indicated by ulcer index:

Groups	Control	DFC	DFC+ Naringin	DFC+ Quercetin	P-value
Gastric ulcer index Mean ±SD	0.00±0.00	12.30±1.96 ^a	5.60±1.89 ^{a,b}	3.80±0.99 ^{a,b}	p<0.05

Data represented by mean ± SD a= Significant difference (p<0.05) compared with control group, b= Significant difference (p<0.05) compared with DFC group.

Light microscopic results

Histological Examination:

• **Haematoxylin and Eosin staining**

Sections from the control group showed that the fundic mucosa was made up of lamina propria and surface epithelium. The surface epithelium was made up of surface mucous secreting cells; it had short, narrow pits that were parallel to the surface. There were many densely arranged, parallel-running tubular fundic glands in the lamina propria. The fundic glands had made up the three components exterior base, middle neck, and interior isthmus. Surface columnar mucous-secreting cells with basal oval nuclei and apical acidophilic cytoplasm lined the fundic pits and isthmus. Both polyhedral parietal cells with acidophilic cytoplasm and rounded central vesicular nuclei and mucous neck cells with foamy cytoplasm and oval basal nuclei lined the neck. Chief cells with their basal nuclei, basal basophilic cytoplasm, and a pale apical part, predominate the base of the gland while parietal cells were occasionally present (Figs. 2a,2b,2c) .

Examination of sections of group (II) revealed that, some areas showed deep ulceration of mucosa up to detachment of fundic mucosa from muscularis mucosa with discontinuity and the sloughing into the lumen of necrotic debris from the fundic epithelial cells. Disturbed fundic glands appeared. In the submucosa, there was an inflammatory infiltration and enlarged blood vessels. The fundic glands appeared with wide lumen and wide pits. There were thin flattened nuclei and little cytoplasm in the surface mucous cells. Most parietal cells possessed pyknotic nuclei and vacuolated cytoplasm, but some also had karyolytic nuclei.

Inflammatory cells aggregated between fundic glands. There was cystic dilatation of fundic glands with flattening of chief cells. Some chief cells appeared with pyknotic nuclei. (Fig.3a, 3b, 3c).

Examination of sections of group (III) revealed that, mucosa had nearly normal architecture of fundic glandular tissue. Congested blood vessels were noticed between the fundic glands and wide gastric glands with elongated fundic pits. The majority of surface mucous secreting cells appeared with thin flattened nuclei, only few cells had basal oval nuclei. Although few parietal cells exhibited pyknotic nuclei and vacuolated cytoplasm, the majority of them appeared normal (Figs.4a,4b,4c).

Examination of sections of groups (IV) exhibited a picture that was almost identical to the control group with the exception of wide fundic gland with short pits. Most of surface mucous secreting cells have basal oval nuclei. Nearly most of parietal cells appeared normal and few cells had vacuolated cytoplasm. Chief cells appeared normal (Fig.5a,5b,5c)

• **PAS-AB stain :**

Sections of the control group (I) stained with PAS-AB showed that the surface epithelium was covered in a continuous thick (PAS-AB) mucous film, which also filled the fundic pits, isthmus, and gland necks. Group (II) revealed a thin, pale and intermittent PAS- AB surface mucous film. There were weak AB-reaction and weak PAS-reaction in the fundic pits, isthmus and the necks of the glands.

Groups (III) and (IV) demonstrated PAS- AB reaction almost identical to the control with constant thick mucus film over the surface epithelium.

Immunohistochemical study

• **iNOS immunostaining :**

iNOS immunostaining was demonstrated as brown cytoplasmic reaction. Control group showed negative iNOS immunoreactivity in the cytoplasm of the gastric epithelial cells. Group (II) showed extensive iNOS immunoreactivity in the cytoplasm of gastric epithelial cell. Group (III) showed weak iNOS immunoreactivity. Group (IV) showed minimal iNOS immunoreactivity (Fig.7).

• **PCNA:**

Proliferating cell nuclear antigen (PCNA) staining was demonstrated as brown nuclear reaction. Control group showed positive (PCNA) immuno-expression in the cells of the isthmus of the fundic glands. Group (II) showed strong positive (PCNA) immuno-expression in the lining cells of whole fundic glands. Group (III) showed positive (PCNA) immuno-expression in the cells of the isthmus and neck of the fundic glands. Group (IV) showed positive (PCNA)immuno-expression in the cells of the isthmus of the fundic glands

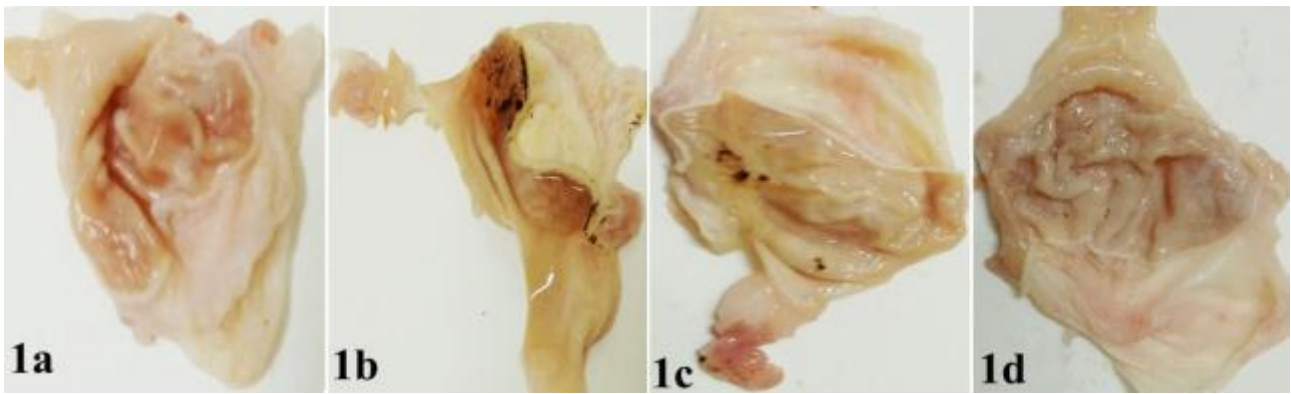


Fig (1): Stomach photographs of rats in different experimental groups. (1a) of control group showing: normal bright gastric mucosa. (1b): DFC group showing multiple areas of ulcerated mucosa (1c): (DFC + Naringin) group showing moderate ulcerated mucosa. (1d) : (DFC + Quercetin) group showing nearly normal gastric mucosa.

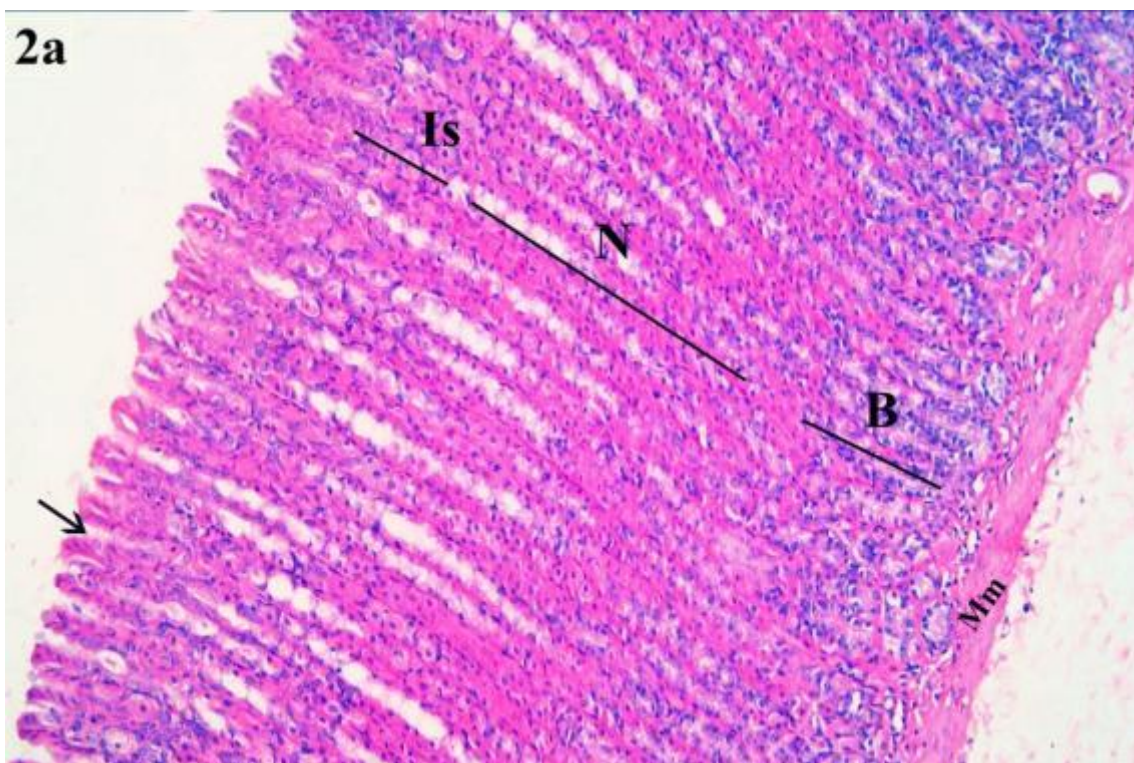
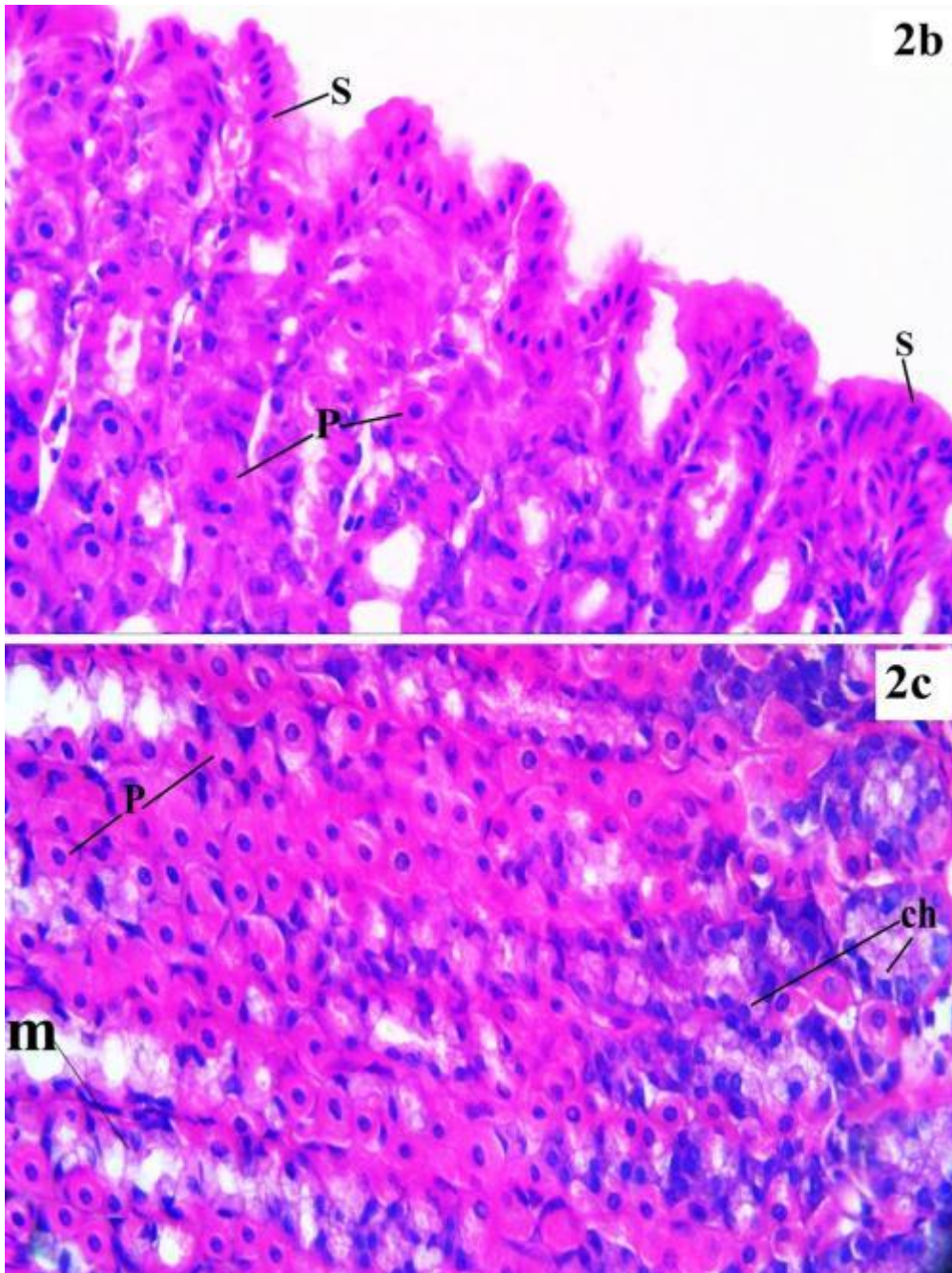


Fig.2a: photomicrograph of section in the fundic mucosa of the control group: showing numerous tightly packed parallel running tubular fundic glands lying perpendicular to the surface with short narrow pits (arrow). The glands are occupying the lamina propria and divided into isthmus (Is), neck (N), and base (B) regions. Muscularis mucosa (Mm). (H&E X 100).



Figs. (2b)(2c): photomicrographs of fundic glands of the control group: showing the fundic glands lined with surface mucous- secreting cells (S) with basal oval nuclei and apical acidophilic cytoplasm covering the surface and extending down into fundic pits and isthmus. The neck of the fundic glands lined with polyhedral parietal cells with acidophilic cytoplasm and rounded central vesicular nuclei (P) and mucous neck cells with foamy cytoplasm and oval basal nuclei(m). The base of the fundic glands lined mainly by many chief cells with their basal nuclei, basal basophilic cytoplasm, and a pale apical part (Ch). Parietal cells (P) can also be seen in the basal part. **(HE X 400)**

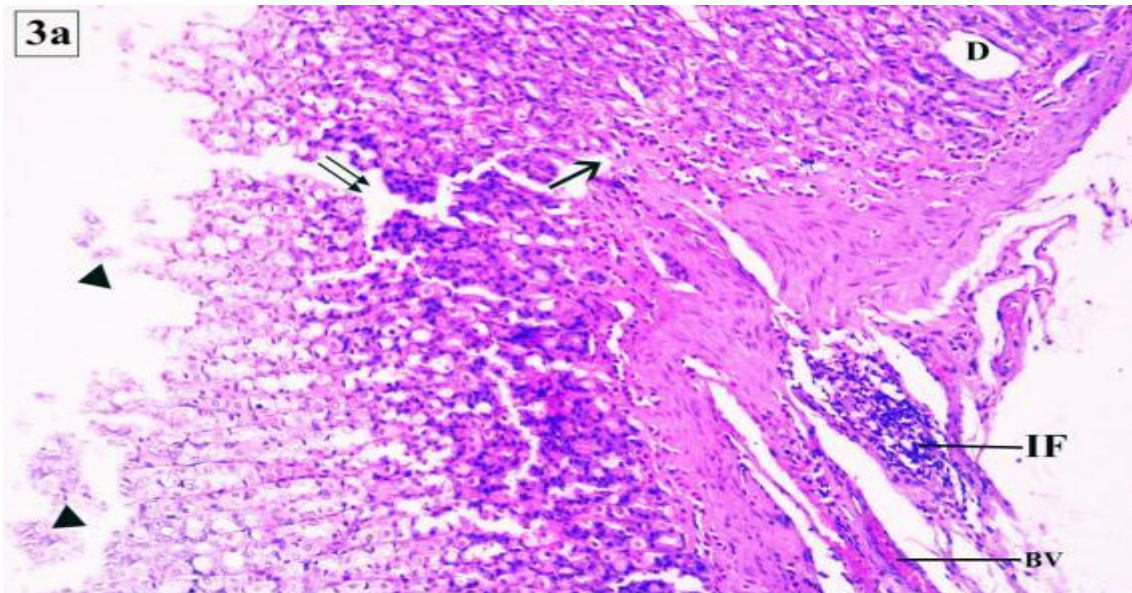
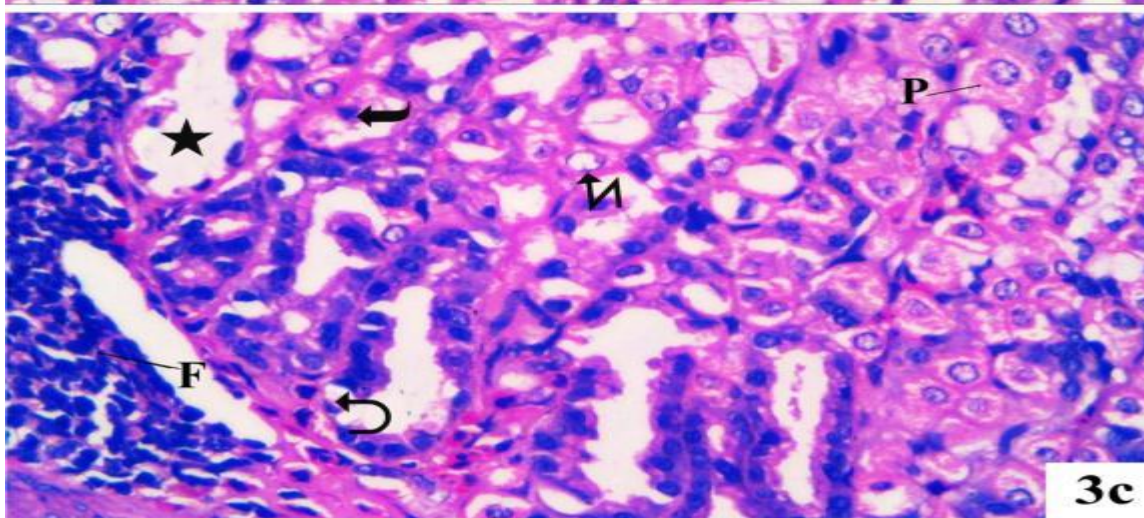
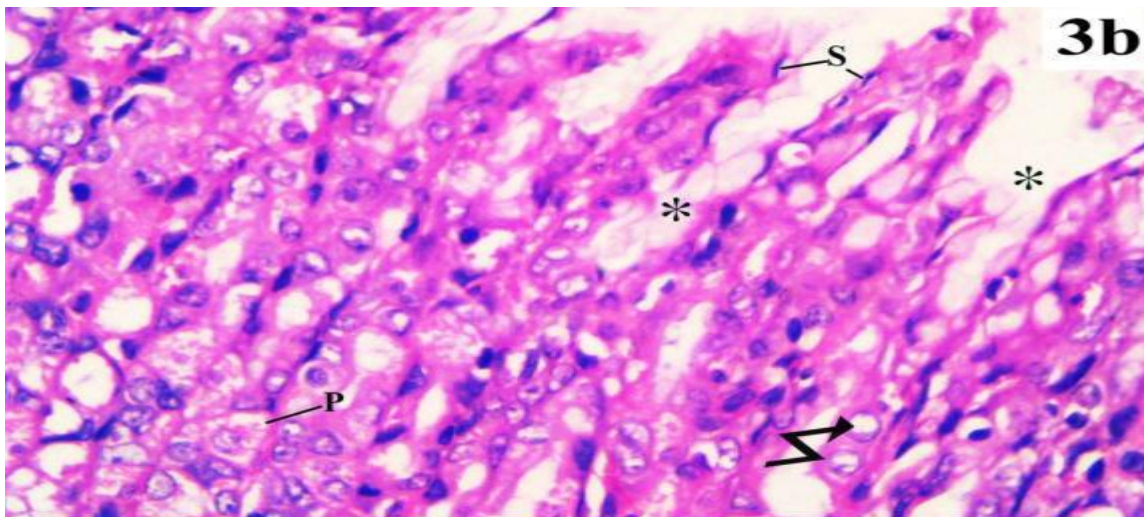


Fig. (3a): photomicrograph of section in the fundic mucosa of DFC group: showing deep ulceration (double arrows) reaching the muscularis mucosa with detachment (arrow) of fundic mucosa from the underlying muscularis mucosa with sloughing of necrotic debris from fundic epithelial cells into the lumen (head arrow). Part of fundic glands appear disrupted (D). There are inflammatory infiltration (IF) and congested blood vessel (BV) in the submucosa. (H&E X 100)



Figs: (3b),(3c) photomicrographs of fundic glands of DFC group: showing fundic glands with wide fundic pits (*). The surface mucous cells (S) appear with little cytoplasm and thin flattened nuclei. Parietal cells (P) appear with vacuolated cytoplasm. Most of parietal cells have vacuolated cytoplasm; some cells appear with karyolitic nuclei (zigzag arrow) and some with pyknotic nuclei (tailed arrow). Aggregated inflammatory cells (F) in the base between the fundic glands. Cystic dilatation of fundic glands with flattening of chief cells (star). Some of chief cells appear with pyknotic nuclei (curved arrow)(H&E X 400).

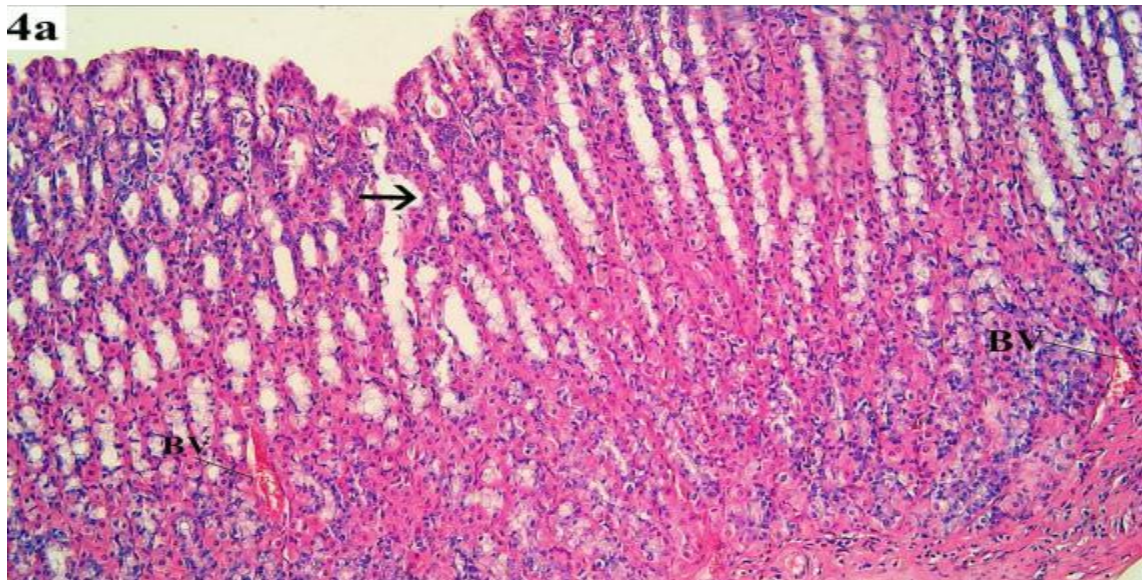
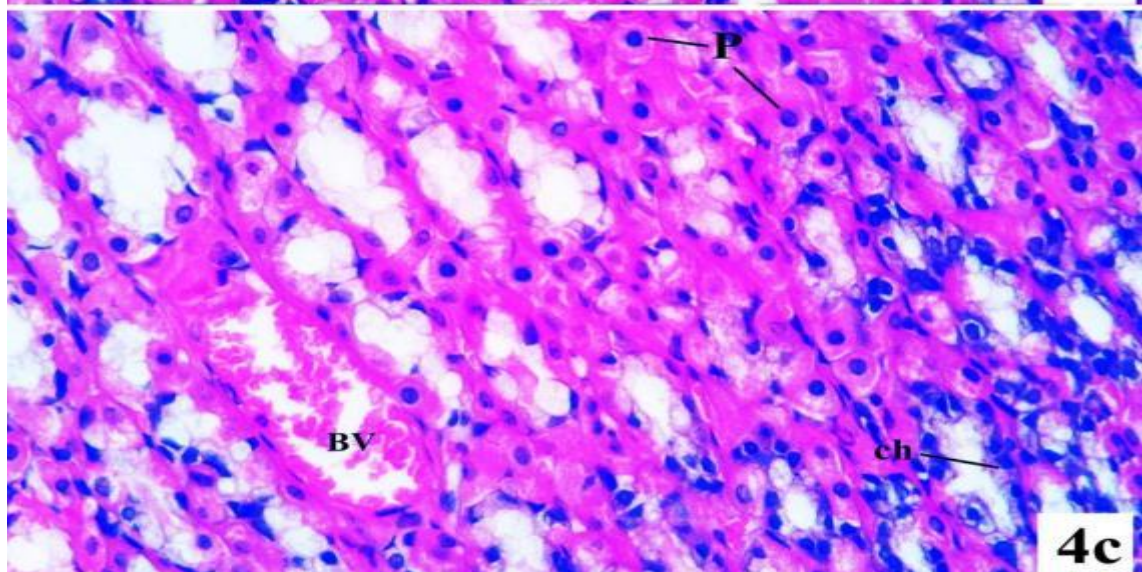
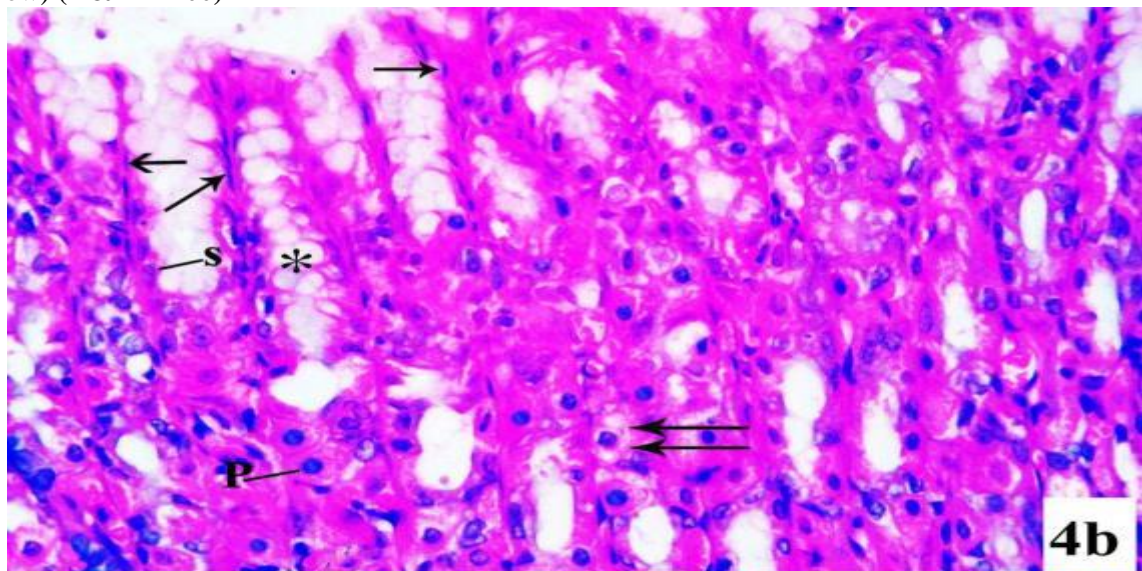


Fig.(4a): photomicrograph of section in the fundic mucosa of (DFC + naringin) group: showing nearly normal architecture of fundic mucosa except for congested blood vessels (B.V) which is detected in between the wide fundic glands (arrow) (H&E X 100)



Figs. (4b)(4c): photomicrographs of fundic glands of (DFC + naringin)group showing: long pits(*)of fundic glands. Most of surface mucous secreting cells have thin flattened nuclei (arrow). Only few cells have basal oval nuclei(S). Most of parietal cells appear nearly normal (P), few cells with vacuolated cytoplasm (double arrows).Chief cells appear nearly normal (Ch). N.B: congested blood vessels (B.V). (H&E X400)

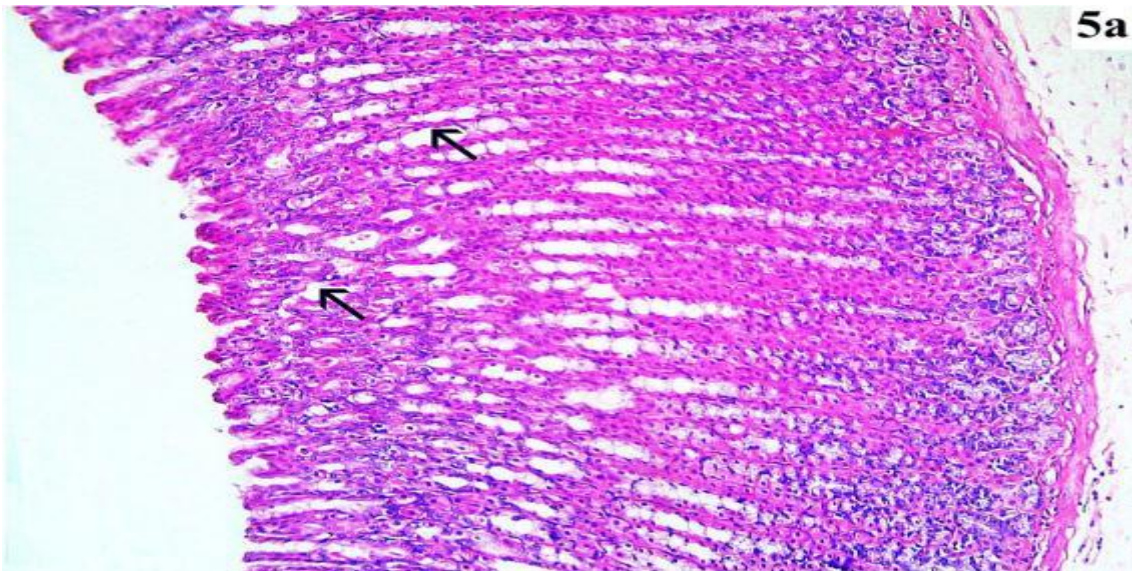
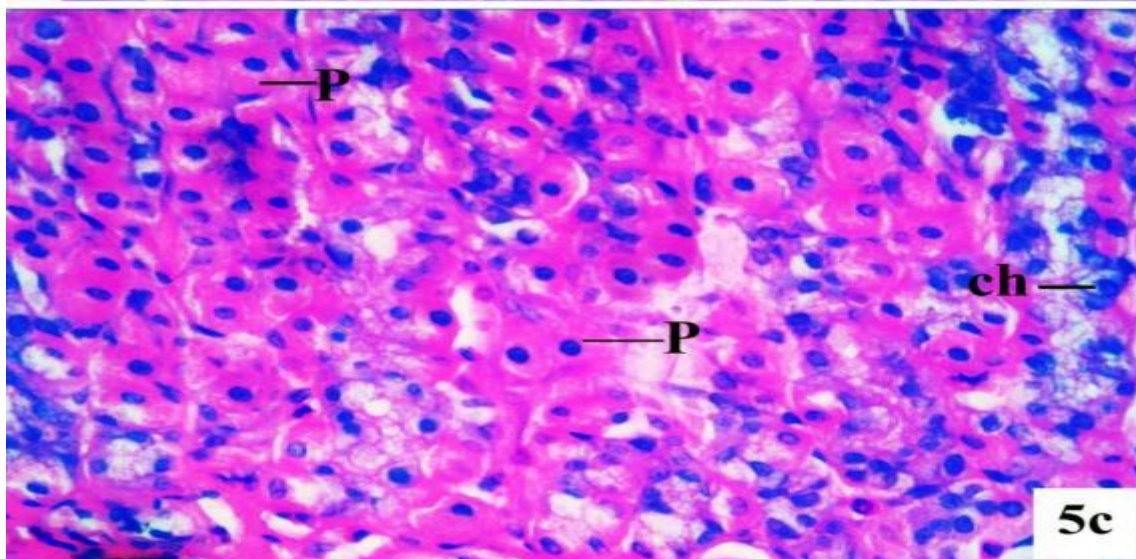
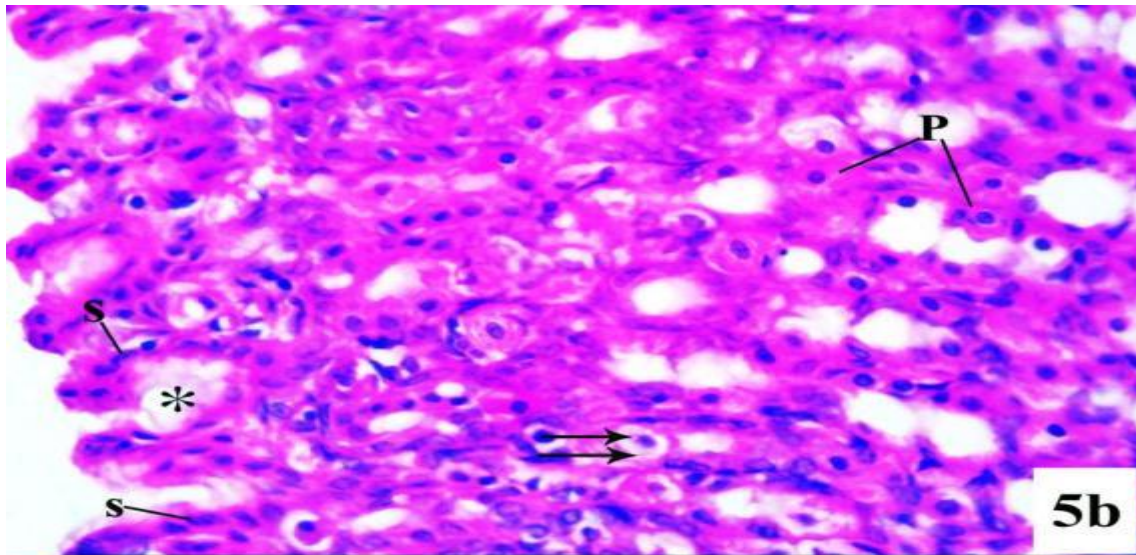


Fig. (5a): photomicrograph of a section in the fundic mucosa of (DFC+ Quercetin)group showing: nearly normal architecture of fundic mucosa with straight packed, parallel widely separated gastric glands (arrow)(H&E X100).



Figs(5b) (5c): photomicrographs of fundic glands of (DFC + Quercetin) group showing: short fundic pits (*). Most of the surface mucous secreting cells (S) have basal oval nuclei. Most of parietal cells (P) appear normal, but some cells with vacuolated cytoplasm (double arrows). N.B: normal chief cells (ch). (H&E X400)

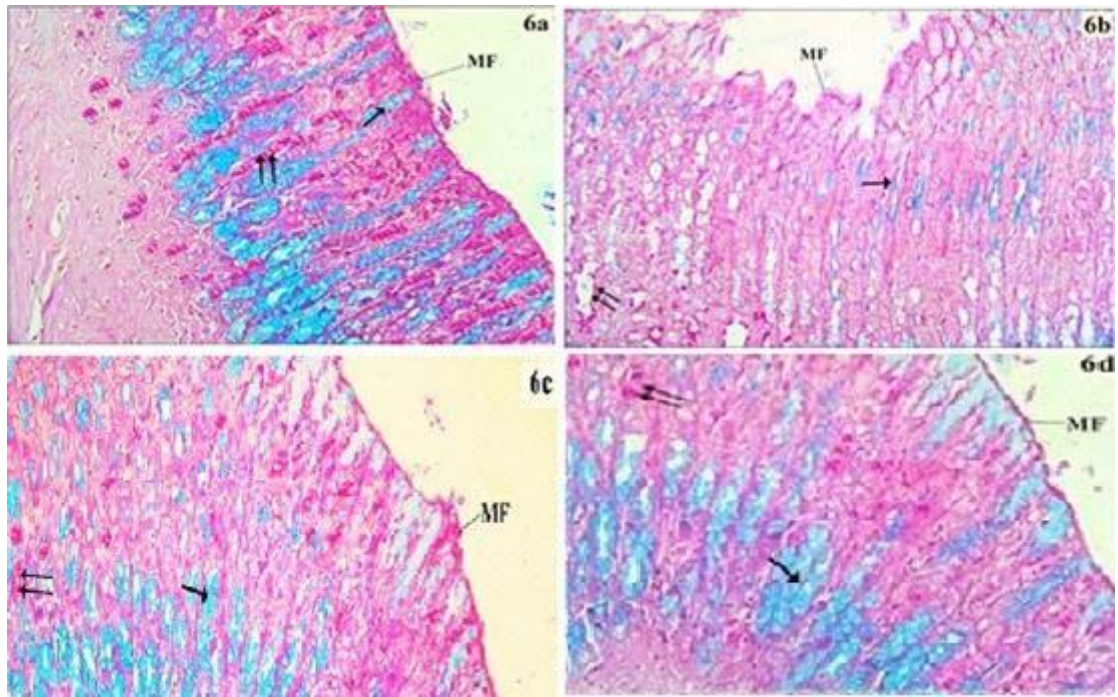
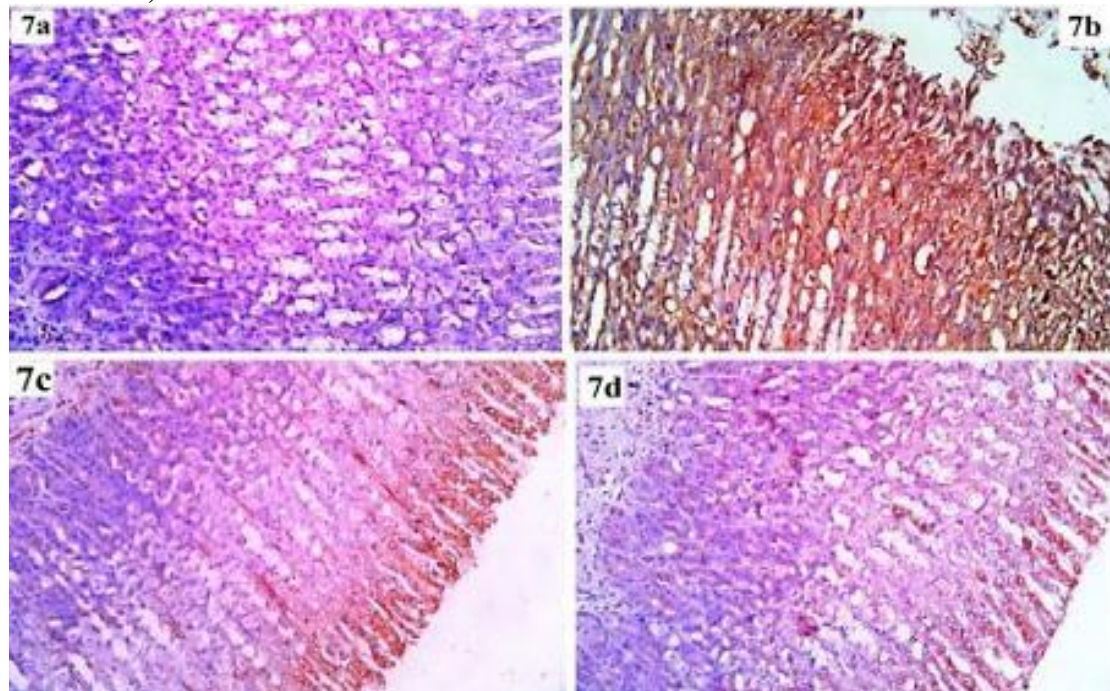
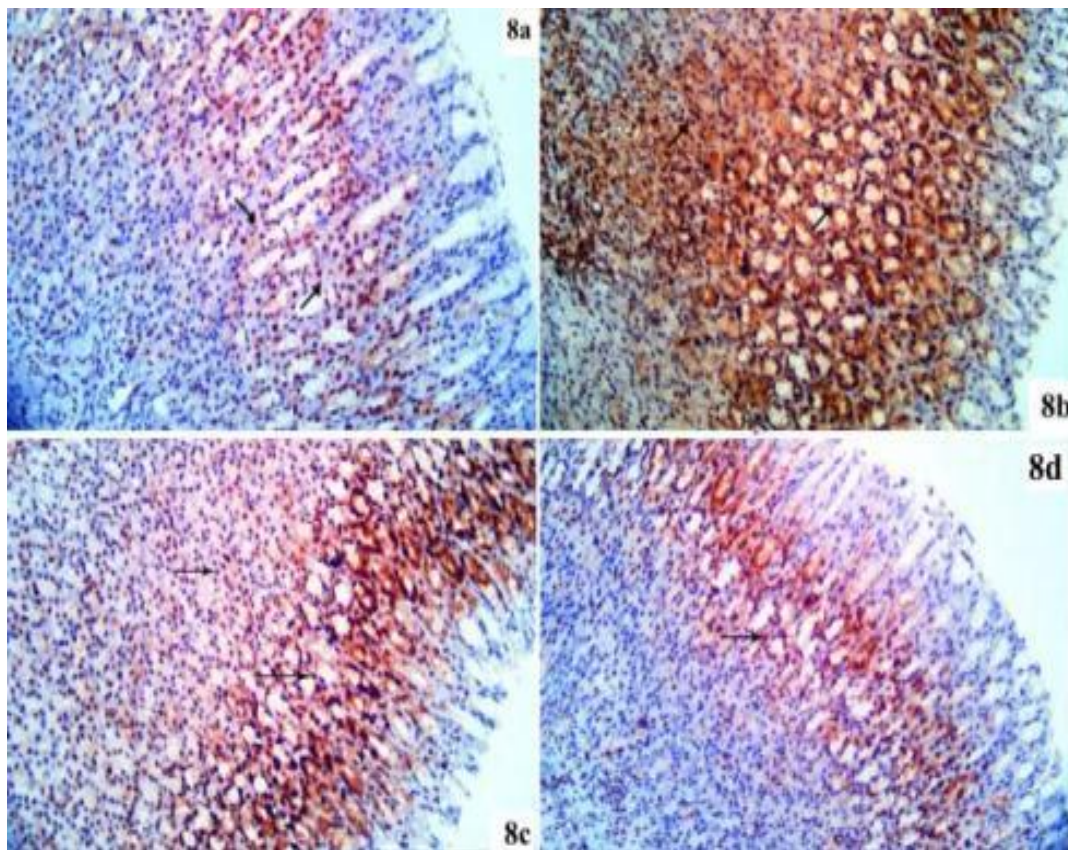


Fig (6): photomicrographs of sections in fundic mucosa of all experimental groups. **(6a):** control group displaying a persistent thick mucous layer that is positive for PAS-AB across the surface epithelium (MF) Strong AB-reaction (arrow) and PAS-reaction (double arrows) is extending to fill the fundic pits, isthmus and necks of the glands. **(6b):** DFC-treated group showing a thin, pale and intermittent mucous film on surface epithelium (MF). There are weak AB-reaction (arrow) and PAS-reaction (double arrows) in fundic pits, isthmus and necks of the glands. **(6c): Group III** displaying a persistent thick mucous layer (MF) that is positive for PAS-AB across the surface epithelium strong AB-reaction (arrow) and PAS-reaction (double arrows) extend to fill the fundic pits, isthmus and necks of the glands. **(6d): Group IV** displaying a persistent thick mucous layer that is positive for PAS-AB across the surface epithelium (MF). Strong AB-reaction (arrow) and PAS-reaction (double arrows) extending to fill fundic pits, isthmus and necks of the glands (PAS-AB X 100)



Fig(7): photomicrographs of sections in the fundic mucosa. **(7a):** Control group showing negative iNOS immunoreactivity in cytoplasm of the gastric epithelial cells. **(7b): group II** showing extensive expression in iNOS immunoreactivity in the cytoplasm of gastric epithelial cells. **(7c): group III** showing weak iNOS immunoreactivity. **(7d): group IV** showing minimal iNOS immunoreactivity. (iNOS immunostain X 200)



Fig(8): photomicrographs of sections in the fundic mucosa (8a):control group showing positive (PCNA) immun-expression in the cells of the isthmus of the fundic gland (arrow).(8b): **group II** showing strong positive (PCNA) immun-expression in the cells lining the whole fundic glands.(8c):**group III** showing positive (PCNA)immun-expression in the cells of the isthmus and neck of the fundic glands (arrow).(8d): **group IV** showing positive(PCNA) immun-expression in the cells of the isthmus of the fundic glands (arrow) (**PCNA immunostain × 200**).

Morphometric and statistical results

1-Area Percentage of PAS-AB reaction

The mean area% of PAS-AB reaction in group (II) exhibited a highly significant decline, compared to the control group (I) (P<0.05). The mean area% of PAS-AB reaction in group (III) and group (IV) exhibited significant rise, compared to the group (II) (P<0.05). (Table 2).

2- Area Percentage of iNOS immunoeexpression:

The mean area% iNOS expression revealed that iNOS immunoreactivity in group (II) exhibited significant rise, compared to the control group. Administration of Narginin or Quercetin with DFC in groups (III) and (VI) exhibited significant decline, compared to group (II) (P<0.05). (Table 2).

3- Area Percentage of PCNA immunoeexpression:

The mean area% PCNA expression revealed that PCNA immunoreactivity in Group (II) was significantly increased (P<0.05) when compared to control group. Administration of Narginin or Quercetin with DFC in groups (III) and (VI) exhibited significant decrease, compared to group (II) (P<0.05). (Table 2).

Table (2): Protective effect of quercetin and narginin against DFC-induced gastric ulcer in rats is indicated by area % of PAS-AB reaction, area % of iNOS immunoreaction and number of PCNA positive nuclei in fundic mucosa.

Groups	Area % of PAS-AB reaction (Mean±SD)	Area % of iNOS (Mean±SD)	number of PCNA positive nuclei of (Mean ± SD)	P-value
Control	54.86±4.45	8.32±2.10	14.46±4.15	p<0.05
DFC	18.35±2.37 ^a	70.52±3.03 ^a	60.22±5.92 ^a	
DFC+ Naringin	34.81±2.36 ^{a,b,c}	30.62±1.05 ^{a,b,c}	35.56±3.49 ^{a,b}	
DFC+ Quercetin	40.67±3.79 ^{a,b}	26.42±2.13 ^{a,b}	30.19±4.01 ^{a,b}	

Data represented by mean ± SD a: significant difference (p<0.05) compared with control group, b= significant difference (p<0.05) compared with DFC group, c= significant difference (p<0.05) compared with DFC+ Quercetin group.

DISCUSSION

Recent research has demonstrated that therapy can both prevent and reverse gastric injury (18).

The present study was planned to evaluate the roles of naringin and quercetin in protection and healing of gastric ulcers induced by DFC in rats

In the present study, the macroscopic examination revealed that oral administration of DFC induced significant increase of ulcer index in rats, this was in agree with **El-Deen *et al.*** (12) who described that increased levels of free radicals and reduction of prostaglandin synthesis have been linked to an increase in gastrointestinal ulcer severity in diclofenac-treated mice. The histological examination of this study revealed that DFC induced focal alterations on the gastric mucosa appearing as epithelial erosions, desquamation of epithelial cells up to deep ulceration reaching the muscularis mucosa, pyknotic nuclei of mucosal cells of stomach, vacuolated parietal cells with dilatation of fundic glands. These degenerative changes were observed by **Tandoh *et al.*** (19).

The balance between damaging agents like gastric acid and protecting agents that maintain the integrity of the gastric mucosa, like mucus, bicarbonate and nitric oxide (NO) are protective substances also prostaglandins can stimulate epithelial cells to release mucus and bicarbonate, decrease gastric output, enhance mucosal blood flow, and limit the release of some inflammatory mediators (13). Cyclooxygenase-1 (COX-1) controls level of prostaglandin. COX-2 is related with the inflammatory reaction. DFC causes stomach ulcers by inhibiting the activity of cyclooxygenases. This impairs protective mechanisms of the stomach by decreasing level of prostaglandins, increasing gastric acids, decreasing mucus and bicarbonate secretion, leucocyte infiltration and weakening microvascular structures (20). This was supported by studies that found that DFC significantly reduced prostaglandin E2 in both plasma and gastric tissue in rats treated with DFC (21).

Some authors have stated that DFC causes gastric ulcers that are accompanied by a substantial increase in MDA levels and a marked decrease in CAT activity and GSH content in stomach tissue when compared to the control group. This suggests that DFC has caused an oxidative reaction (22). DFC disrupts the stomach's protective phospholipid layer and prevents mitochondrial oxidative phosphorylation, which causes reactive oxygen species (ROS) to develop (23).

In this study, inflammatory cell infiltration was seen, indicating inflammatory effect of DFC. **Hassan *et al.*** (24) attributed neutrophil infiltration in the gastric ulcer to high level of TNF- α which occurs in oxidative damage induced by DFC. Prior study recorded significant increase in the level of gastric Myeloperoxidase (MPO) which is released from neutrophils in response to inflammation (21).

The inflammatory infiltration might follow affection of the integrity of intercellular junction

between surface columnar cells so; mucosa was more vulnerable to the effects of acid and proteolytic enzymes with subsequent bacterial invasion (25).

The current study's histochemical findings demonstrated that DFC inhibited the mucous production; this was shown by a marked drop in the area percentage of PAS-AB positive reaction with reduction of mucus on the surface of the disfigured gastric glands in DFC group when compared to control group. Decrease of gastric mucus indicated that stomach was unable to adjust to the DFC's cytotoxic effects (26). This could be explained by the oxidative stress and apoptosis of gastric mucous secreting cells, as has been previously reported by **Suzuki *et al.*** (27). Also, **Elghazouly and Yassien** (28) attributed the decrease in the mucous production to injury of the mucus cells such explanation was supported by ultrastructural picture of the mucous cells which revealed areas of cytoplasmic loss, irregular shrunken nucleus and few mucous granules as compared to control.

The gastric mucins act as a barrier between gastric juices and the surface epithelial cells; mucus can resist enzymatic hydrolysis by digestive enzymes in the lumen (29).

The current study showed that DFC treatment exhibited an elevated mean area percentage of iNOS that was significant compared to the control. It was reported that nitric oxide plays a role in protecting the gastric mucosa and is necessary for optimal mucosal function (27). High level of iNOS is activated by inflammatory cytokines, this leads to disturbance of microcirculation and gastric mucosal damage (30).

The excessive production of iNOS giving rise to inflammatory reactions that will form gastric injuries through the generation of reactive oxygen species (31).

Moreover, the DFC group showed a significant increase in the PCNA immuno-expression in the cells lining the whole fundic glands. This finding was consistent with those made by **El-ghazouly and Yassien** (28) who reported that increase PCNA may indicate the presence of stem cells that proliferate and differentiate to allow for the regeneration of damaged cells thus allowing healing of damaged mucosa. Some investigators explained increased PCNA immuno-expression as it is marker for DNA repair; it can replace abnormal nucleotides that release after DNA damage in non-proliferating cells undergoing DNA repair (32). This was in the contrary with **Youssef** (26) who recorded a significant decrease of PCNA positive immuno-expression in gastric mucosa after DFC treatment.

The recent study's findings showed that naringin restored the histological architecture of the fundic mucosa. This was in the same line with **Emin & Volkan** (13). A previous study stated that naringin potentiated gastroprotection against ethanol-induced ulcer in rats. Presented in minimizing mucosal erosion, reduction of oxidative stress markers, suppressing gastric secretion, free-radical-scavenging ability and its

anti-inflammatory effect by lowering gastric levels of TNF- α , NF- κ B and IL-6 expressions⁽³¹⁾. Another study revealed that naringin, could counteract DFC induced liver injury via improvement of antioxidant defense system and anti-inflammatory effect and inhibition of apoptosis⁽²⁴⁾.

In this study, the increase in mucous production in DFC+naringin group was evident by significant rise in PAS-AB reaction. This may be explained by Naringin's capacity to stimulate stomach gland mucus secretion.

Also, treatment with Naringin decreased iNOS elevation induced by DFC. This was in agreeing with **Emin and Volkan**⁽¹³⁾. The gastroprotective effect of Naringin is due to its ability to inhibit secretion of iNOS via the suppression of NF- κ B as well as improvement of microcirculation around the ulcer by stimulation of vascular endothelial growth factor (VEGF) synthesis that increases angiogenesis, so decrease gastric mucosal damage⁽³¹⁾. Quercetin alleviated DFC-induced gastric ulcer in this study. **Kotob et al.**⁽³³⁾ observed similar findings and said that pre-treatment with quercetin in gastric ulcer caused by aspirin attributing this due to their cytoprotective, anti-inflammatory and antioxidant potentials, as well as, iron chelating property.

As demonstrated by **Narayanamurthy et al.**⁽³⁴⁾ quercetin has been shown to have anti-ulcerogenic effects against histamine-induced gastric ulcers by an increase in SOD, GSH-Px, and CAT levels and a considerable decline in MDA levels in comparison to the ulcer group in both serum and stomach tissue.

Similarly, quercetin has been demonstrated to have a protective effect against indomethacin-induced ulcerogenesis, by downregulating pro-inflammatory cytokines like NF- κ B, lowering the activity of myeloperoxidase (MPO), and enhancing the gastric antioxidant system⁽¹⁴⁾.

The anti-ulcer activity of quercetin is credited to scavenging free-radical, increasing gastric mucus production and decrease gastric acid secretion by preventing the release of histamine⁽³⁵⁾.

Quercetin can reduce the number of gastric mast cells and reduces stomach acid output by inhibiting their histamine release and the gastric H⁺/K⁺ proton pump⁽³³⁾.

Abdel-Tawab et al.⁽¹⁴⁾ reported that treatment of ulcerated rats with quercetin was associated with increasing pH level and decreasing in gastric acid volume, which are necessary for rapid healing of ulcerated mucosa and protection against ulcer formation.

As regarding PAS-AB staining in IV group, there was significant increase in mucin and this was in line with the findings of **Kotob et al.**⁽³³⁾ who observed that quercetin-treated rats with stomach ulcers had increased mucin on their surface epithelium and mucous neck cells.

Quercetin can reduce inflammation by scavenging free radicals and decreasing inflammatory leukotriene production and increases glutathione (GSH) level⁽³⁵⁾.

CONCLUSION

Naringin intake during taking diclofenac sodium protects the stomach mucosa. On the other hand, quercetin is more protective than naringin when consumed.

DECLARATIONS

- Consent for Publication: I confirm that all authors accepted the manuscript for submission
- Availability of data and material: Available.
- Competing interests: None.
- Funding: No fund.
- Conflicts of Interest: The authors declared no conflicts of interest regarding the publication of this paper.

REFERENCES

1. **Li W, Hao D, Fan T et al. (2014):** Protective effect of chelerythrine against ethanol-induced gastric ulcer in mice. *Chem Biol Interact.*, 208:18-27.
2. **Sistani Karampour N, Arzi A, Rezaie A et al. (2019):** Gastroprotective Effect of Zingerone on Ethanol-Induced Gastric Ulcers in Rats. *Medicina (Kaunas)*, 55(3):64-73.
3. **Singh D, Borse S, Nivsarkar M (2016):** Clinical importance of nonsteroidal anti-inflammatory drug enteropathy: the relevance of tumor necrosis factor as a promising target. *Transl Res.*, 175: 76-91.
4. **Altman R, Bosch B, Brune K et al. (2015):** Advances in NSAID development: evolution of diclofenac products using pharmaceutical technology. *Drugs*, 75(8):859-877.
5. **Abbas J, Bashir S, Samie M et al. (2017):** Formulation and evaluation of a bilayer tablet comprising of diclofenac potassium as orodispersible layer and diclofenac sodium as sustained release core. *Marmara Pharmaceutical Journal*, 21(3): 707-716.
6. **Owumi S, Dim U (2019):** Biochemical alterations in diclofenac-treated rats: effect of selenium on oxidative stress, inflammation, and hematological changes. *Toxicology Research and Application*, 3: 1-10
7. **Zhang J, Gao W, Liu Z et al. (2014):** Systematic Analysis of Main Constituents in Rat Biological Samples after Oral Administration of the Methanol Extract of *Fructus Aurantii* by HPLC-ESI-MS/MS. *Iran J Pharm Res.*, 13(2):493-503
8. **Gelen V, Şengül E, Yıldırım S et al. (2018):** The protective effects of naringin against 5-fluorouracil-induced hepatotoxicity and nephrotoxicity in rats. *Iran J Basic Med Sci.*, 21(4):404-410.
9. **Nna V, Ujah G, Mohamed M et al. (2017):** Cadmium chloride-induced testicular toxicity in male wistar rats; prophylactic effect of quercetin, and assessment of testicular recovery following cadmium chloride withdrawal. *Biomed Pharmacother.*, 94: 109-123.
10. **Carrasco-Pozo C, Castillo R, Beltrán C et al. (2016):** Molecular mechanisms of gastrointestinal protection by quercetin against indomethacin-induced damage: role of NF- κ B and Nrf2. *J Nutr Biochem.*, 27:289-298.

11. **Dower J, Geleijnse J, Gijsbers L et al. (2015):** Supplementation of the Pure Flavonoids Epicatechin and Quercetin Affects Some Biomarkers of Endothelial Dysfunction and Inflammation in (Pre) Hypertensive Adults: A Randomized Double-Blind, Placebo-Controlled, Crossover Trial. *J Nutr.*, 145(7):1459-1463.
12. **El-Deen E, El-Mahdy N, Rashidy M et al. (2016):** Diclofenac-induced Gastric Ulceration in Rats: Protective Roles of Pantoprazole and Misoprostol. *British Journal of Pharmaceutical Research*, 11: 1-12.
13. **Emin S, Volkan G (2019):** Protective effects of naringin in indomethacin-induced gastric ulcer in rats. *GSC Biological and Pharmaceutical Sciences*, 8(2): 6–14.
14. **Abdel-Tawab M, Mostafa Tork O, Mostafa-Hedeab G et al. (2020):** Protective Effects of Quercetin and Melatonin on Indomethacin Induced Gastric Ulcers in Rats. *Rep Biochem Mol Biol.*, 9(3):278-290.
15. **Ahmed O, Shalaby S, Ibraheem E et al. (2020):** A comparative study between the therapeutic role of bone marrow mesenchymal stem cells and that of histamine2 receptor antagonists (nizatidine) in the management of ibuprofen induced gastric ulcer in adult albino rats. *Benha Medical Journal*, 37(3): 678-690.
16. **Suvarna K, Layton C, Bancroft J (2018):** Bancroft's Theory and Practice of Histological Techniques. Elsevier, 8th ed. Pp. 408-418. <https://www.us.elsevierhealth.com/bancrofts-theory-and-practice-of-histological-techniques-9780702068645.html>
17. **Buchwalow I, Böcker W (2010):** Immunohistochemistry: Basics and Methods. Springer, Heidelberg, Dordecht, London, New York. Pp. 31–39. <https://www.amazon.com/Immunohistochemistry-Methods-Igor-B-Buchwalow/dp/3642046088>
18. **Ahluwalia A, Hoa N, Jones M et al. (2019):** NSAID-induced injury of gastric epithelial cells is reversible: roles of mitochondria, AMP kinase, NGF, and PGE2. *American Journal of Physiology-Gastrointestinal and Liver Physiology*, 317(6): 862-871.
19. **Tandoh A, Danquah C, Ossei P et al. (2021):** Protective effects of andrographolide against diclofenac-induced gastric damage. *Scientific African*, 13: e00944
20. **Jafar M, Khalid M, Alghamdi H et al. (2018):** Improved analgesic effect and alleviated gastric problems of diclofenac sodium through a gastric floating in-situ gelling system. *Int J Pharm Phytopharm Res.*, 8(4): 42-52.
21. **Mostafa R, El-Marasy S, Jaleel G et al. (2020):** Protective effect of royal jelly against diclofenac-induced hepato-renal damage and gastrointestinal ulcerations in rats. *Heliyon*, 6(2): e03330. doi: 10.1016/j.heliyon.2020.e03330
22. **Saiah W, Halzoune H, Djaziri R et al. (2018):** Antioxidant and gastroprotective actions of butanol fraction of Zingiber officinale against diclofenac sodium-induced gastric damage in rats. *Journal of Food Biochemistry*, 42(1): e12456.
23. **Bjarnason I, Scarpignato C, Holmgren E et al. (2018):** Mechanisms of damage to the gastrointestinal tract from nonsteroidal anti-inflammatory drugs. *Gastroenterology*, 154(3): 500-514.
24. **Hassan R, Hozayen W, Abo Sree H et al. (2021):** Naringin and Hesperidin Counteract Diclofenac-Induced Hepatotoxicity in Male Wistar Rats via Their Antioxidant, Anti-Inflammatory, and Antiapoptotic Activities. *Oxid Med Cell Longevity*, 21 (7): 1-14.
25. **Elhusseiny M, Elabd S, Mihi K et al. (2017):** Histological study of the effect of leflunomide on fundic mucosa of Adult male albino rat and the possible alleviating effect of L-arginine. *Journal of Medical Histology*, 1: 170-189.
26. **Youssef S (2020):** Modulating Effect of Vitamin D on iNOS, PCNA and a-SMA Expression Against Diclofenac Sodium Induced Gastric Injury in Rats. *The Indonesian Biomedical Journal*, 12: 165-76.
27. **Suzuki H, Nishizawa T, Tsugawa H et al. (2012):** Roles of oxidative stress in stomach disorders. *J Clin Biochem Nutr.*, 50(1): 35-39.
28. **Elghazouly D, Yassien R (2022):** Effect of sofosbuvir (sovaldi) on the fundic mucosa of adult male albino rats and the possible protective role of fucoidan: Histological, histochemical, and immunohistochemical study. *Egyptian Journal of Histology*, 45(1): 1-19.
29. **Alkushi A, Elsayy N (2017):** Quercetin attenuates, indomethacin-induced acute gastric ulcer in rats. *Folia Morphologica*, 76(2): 252–261.
30. **De Araújo E, Guerra G, Araújo D et al. (2018):** Gastroprotective and antioxidant activity of Kalanchoe brasiliensis and Kalanchoe pinnata leaf juices against indomethacin and ethanol-induced gastric lesions in rats. *International Journal of Molecular Sciences*, 19(5): 1265. doi: 10.3390/ijms19051265
31. **Li W, Lin S, Chu C et al. (2021):** The gastroprotective effect of naringenin against ethanol-induced gastric ulcers in mice through inhibiting oxidative and inflammatory responses. *International Journal of Molecular Sciences*, 22(21): 11985. doi: 10.3390/ijms222111985.
32. **Bologna-Molina R, Mosqueda-Taylor A, Molina-Frechero N et al. (2013) :** Comparison of the value of PCNA and Ki-67 as markers of cell proliferation in ameloblastic tumors. *Med Oral Patol Oral Cir Bucal*, 18: 174–179
33. **Kotob S, Sayed A, Mohamed S et al. (2018):** Quercetin and ellagic acid in gastric ulcer prevention: an integrated scheme of the potential mechanisms of action from in vivo study. *Asian J Pharm Clin Res.*, 11(1): 381-389.
34. **Narayanamurthy U, Jayachandran R, Ramarajan S et al. (2019):** Effect of quercetin on histamine induced gastric ulcers in male Guinea pigs. *Int J Basic Clin Pharmacol.*, 8: 2018-23.
35. **Zhang W, Lian Y, Li Q et al. (2020):** Preventative and therapeutic potential of flavonoids in peptic ulcers. *Molecules (Basel, Switzerland)*, 25(20): 4626. doi:10.3390/molecules25204626.