

## Histopathological Artifacts in Skin Biopsies: Types, Frequencies and Its Impact on Final Diagnosis

Mohammed J E Ahmed<sup>1\*</sup>, Sajid Saad Mohammed<sup>2</sup>

<sup>1</sup>Department of Dermatology and Venereology,

<sup>2</sup>Department of Histopathology, Al-Yarmouk Teaching Hospital, Baghdad, Iraq.

**Corresponding author:** Mohammed J E Ahmed, **Mobile:** (+964)7848771871, **\*E mail:** [mohammedjasimessa@gmail.com](mailto:mohammedjasimessa@gmail.com)

### ABSTRACT

**Background:** Generally, in practical dermatology, the term artifacts is used to describe what is called pathomimia which means self-inflicted lesions or that lesions induced accidentally on oral mucosa and skin. Regarding dermatopathology, the word, 'artefact' comes from the Latin term, 'Ars' = art and 'factum' = made. This study evaluates types of artifacts, frequencies, and their impact on final diagnosis.

**Patients and method:** This observational, cross-sectional study. The study worked on 590 dermatological slides, that stained with hematoxylin and eosin stain. Slides evaluated from archive and that collected during time of study which occur from June 2022 to November 2022, in Al-Yarmouk Teaching Hospital, Baghdad, Iraq, analyzed for artifacts under light microscope.

**Results:** Totally 590 slides were evaluated, only 69 (11.695%) show no artifacts. Slides with artifact(s) counting 521(88.305%). Histopathological artifacts were accounted for 931 because more 45% of total examined slides show two or more artifacts. Folding artifacts were the most common type, while artefacts related to fixation were the least 307(32.975%), 6(0.644%) respectively.

**Conclusion:** Histopathological evaluation of skin biopsies had long, and multiple stages done by the dermatologist, assistant pathologists, and lab technicians. That led to increased incidence of errors and artifacts. Artifacts invariably occur in the majority of dermatopathological slides and may interfere with the interpretation of histopathological diagnosis. These artefacts should be recognized and do all effort to avoid or at least, minimized them, which yet defied even with soft tissue handle and wrong techniques avoidance.

**Keywords:** Histopathological artifacts, skin biopsies, impact on final diagnosis.

### INTRODUCTION

Generally, in practical dermatology, the term artifacts used to describe what call it pathomimia which mean self-inflicted lesions or that lesions induced accidentally on oral mucosa and skin <sup>(1)</sup>.

Regarding the dermatopathology, term biopsy derived from Greek word bios = 'life' and ops = 'sight' <sup>(2,3)</sup>. The word, 'artefact' comes from the Latin term, 'Ars' = art and 'factum' = made <sup>(4)</sup>. Skin biopsy remains the paradigm procedure for obtaining sufficient tissue for histological assessment and subsequently for obtained final diagnosis <sup>(5)</sup>.

Artefact refers to "an artificial structure or tissue alteration on a prepared microscopic slide caused by some extraneous factors" <sup>(6)</sup>. Artifacts may lead to changing of normal morphology or even cytology of tissue, and with multiple artifacts of same slide may give fully non useful tissue specimen, which may lead to major errors and mal-diagnosis histopathological picture <sup>(7)</sup>. Regarding the artifacts influence on final histopathological diagnosis, artifacts may be minimally affected or may lead to totally distrusted prepared stained tissue <sup>(4)</sup>.

Because of histopathological evaluations are multi-stages process, so many artifacts may happen through these stages which includes; surgical removal of specimen, fixation of obtained tissue, processing stage,

embedding stage, microtomy stage, staining stage and mounting process <sup>(8)</sup>.

### Artifacts can be categories as below according to known stages of dermatopathology processing:

- Surgical removal of specimen related artifact
- Fixation artifact
- Tissue processing artifact
- Embedding artifact
- Microtomy artifact
- Staining artifact
- Mounting and Cover-slipping artifact.

### Surgical biopsy procedure:

Many types of artifacts encountered in dermatopathology are occur in this stage, like epithelial vacuolation and connective tissue separation along with hemorrhage (Fig. 1) all may cause by injection of anesthesia <sup>(9)</sup>. That can be avoided by prelesional injection of anesthesia. Crush (Fig. 2) and hole artifact (Fig. 3) may cause by using of forceps with over-force before the stage of fixation and produced by syringe needle that use for separation of biopsy, respectively <sup>(10,11,3)</sup> which can be avoid by gently holding the biopsy and use Terson lens capsule forceps <sup>(12)</sup>. During obtaining of biopsy, electrocautery may be used to cutting or for hemostasis

which cause fulguration artifacts (Fig. 4) that show amorphous material <sup>(13)</sup>. Many contaminated artifacts originally occur in this stage like contaminated with cotton, hair, spores, suture.

#### **Fixation:**

Autolysis is a non-avoidable process in living tissue after being removed from human body, fixation with proper medium will prevent it if occurs immediately after removal of biopsy. Fixation also prevents putrefaction and leads to protein stabilization in cells, so fixation is mandatory. For optimum process, 10% formalin with 20 times the volume of biopsy should use <sup>(14,15)</sup>.

#### **Tissue Processing:**

The goal of tissue processing is dehydrated of tissue by removing all extractable water. And then replaced removed water with supporting medium in order to give considerable rigidity to tissue and that lead to tissue sectioning without or with little distractions. Inappropriate processing may cause cells distortion, uneven staining, tissue fragmentation, difficult sectioning <sup>(16)</sup>.

#### **Embedding artifacts:**

If the tissue orientation in the mould was set incorrectly, this may lead to alternation of biopsied tissues elements which may lead finally to diagnostic challenge; missing tissue or even damaged during microtomy process <sup>(4)</sup>. When the embedding media hardness was more than that of infiltrated tissue these lead to crack and wrinkle of examined tissue. Soft or hard wax usage as embedding media, wax rapidly cooled, clearing agent contaminated, wax denaturation or tissue dehydrated insufficiently all may lead to tear artifacts <sup>(16)</sup> and holes artefacts <sup>(17)</sup>.

#### **Microtomy:**

Mean tissues sectioning, folding (Fig. 5) and nicking (Fig. 6) are common artifacts in this stage. Alternate thick and thin sections (Fig. 7), Tangential cut artefact (Fig. 8) are frequently seen <sup>(18,19)</sup>.

#### **Staining:**

Incomplete or partial staining due to failure of wax remove <sup>(20)</sup>, as show in (Fig. 9), homogenous deep pink-stain mass occurs with excess amount of acetic acid used <sup>(4)</sup>, as show in (Fig. 10). Aluminium potassium sulphate is used as a mordant in many haematoxylin stain. Hematoxylin solution need to properly mix during process of staining, if mixing interrupted this will lead to crystallization of aluminium potassium sulphate which appear as deep black pigmentation (Fig. 11) throughout the section <sup>(21)</sup>.

#### **Mounting and cover slipping:**

Histological stained section should properly protect by the application of cover slip with appropriate usage of mounting media. Mounting with cover slipping stage may causes artifacts by is-self, which may interfere with appearance of slid and alternation of results of staining. Air bubbles may occur beneath the cover slip (Fig. 12) when we use too thin mounting media, this may lead to be dried and even cracked (Fig. 13), and more air may get under the edges <sup>(4,19)</sup>. Stain bleaching (colour diminished) may occur from exposure of slid to light to through prolong period (Fig. 14). Therefore, final slid must be storage in dark cabinet. Mounting bench should keep tidy and clean, this will lead to avoid contamination by fibres, debris <sup>(22)</sup>. Number of artifacts were proved as assisted clue for diagnosis, like stromal artifact which occur in basal cell carcinoma (Fig. 15).

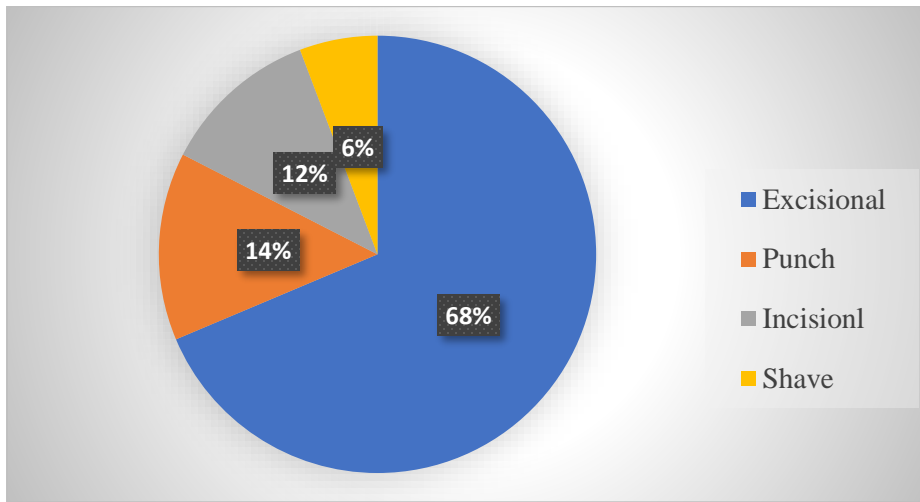
### **PATIENTS AND METHODS**

A cross sectional study evaluate of 590 consecutive histopathology slides. Slides were retrieved from archives of previous months, and that of patients which examined during this study which occur from June 2022 to November 2022, in Al-Yarmouk Teaching Hospital, Baghdad, Iraq. The slides prepared routinely using HISTO-PRO 300 VACUM TISSUE PROCESSOR, HISTO-LINE Laboratories. and stained with haematoxylin and eosin. These slides were observed grossly and then microscopically for the artefacts encountered due to problems in various stages of slide preparation.

**Ethical approval: The study protocol was assessed and approved by the Ethics Committee of our institution, the research protocol did not interfere with any medical recommendations or prescriptions. Informed consent was taken from the patient with keeping the patients` records confidential in all stages of the study. This work has been carried out in accordance with The Code of Ethics of the World Medical Association (Declaration of Helsinki) for studies involving humans.**

### **RESULTS**

Totally 590 slides were evaluated, only 69 (11.695%) show no artifacts. Slides with artifact(s) counting 521 (88.305%). Regarding the types of biopsies, excisional biopsy accounts 405 (68.644%) from total biopsies. Punch, incisional and shave accounts 82 (13.898%), 69 (11.695%), 34 (5.763%) respectively, as show in figure (16). Tow and more artifacts in same slide accounting 285 (48.305%) from total examined slides.



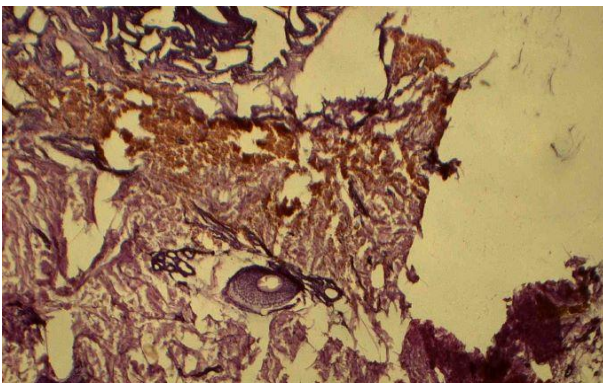
**Figure (16):** Types and percentage of biopsies.

Regarding to types of histopathological artifacts were account 931 because more 45% of total examined slides show tow and more artifacts. Folding artifacts were the most common type, while artefacts related to fixation were the least 307 (32.975%), 6 (0.644%) respectively, as show in table (1).

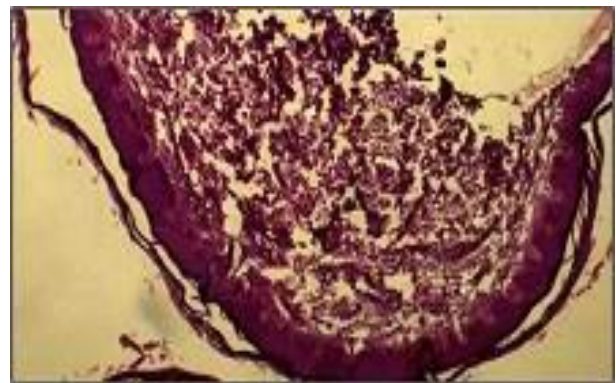
**Table (1):** Types of artifacts

| Histopathological artifacts (n.931) | No. and percentage |
|-------------------------------------|--------------------|
| Folding artifact                    | 307(32.975%)       |
| Dry mounting                        | 178(19.119%)       |
| Crush artifact                      | 109(11.708%)       |
| Air bubbles artifact                | 103(11.063%)       |
| Contaminated artifact               | 76(8.163%)         |
| Nicking artifact                    | 59(6.337%)         |
| Staining artifact                   | 44(4.726%)         |
| Split artifact                      | 31(3.33%)          |
| Poor processing                     | 21(2.256%)         |
| Electro-fulguration                 | 6(0.644%)          |
| Fixation artifact                   | 6(0.644%)          |

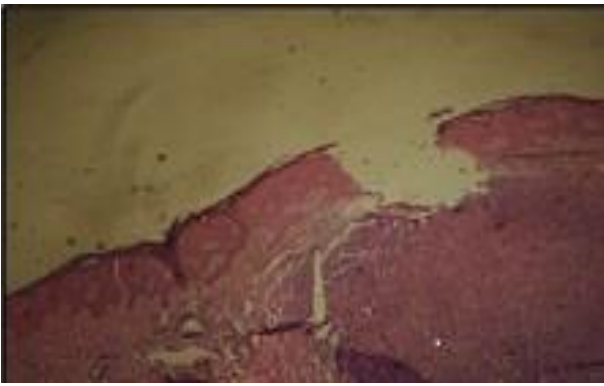
Artifacts during surgical biopsy may include, hemorrhage (Fig. 1), crush artifact (Fig. 2) and hole artifact (Fig. 3) also fulguration artifacts (Fig. 4) that show amorphous material.



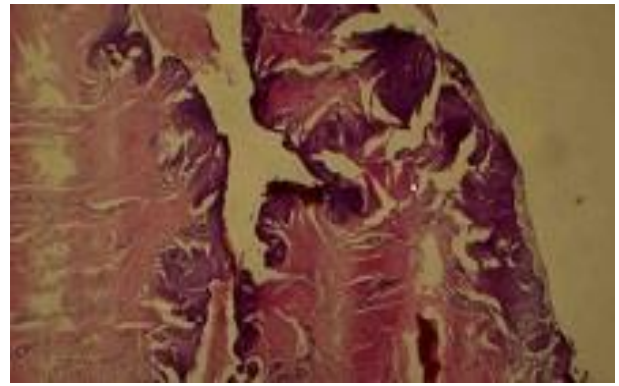
**Figure (1):** Hemorrhage artifact



**Figure (2):** Crush artifact

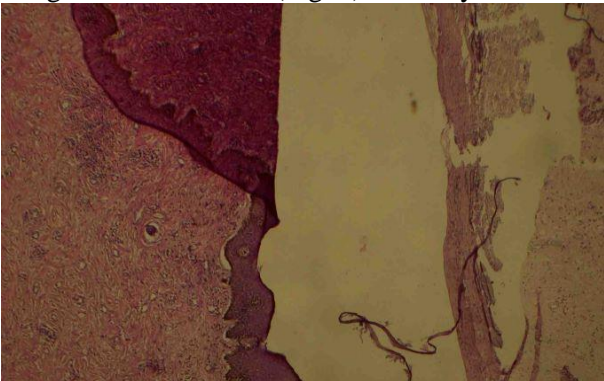


**Figure (3):** Artefactual hole produced by syringe needle

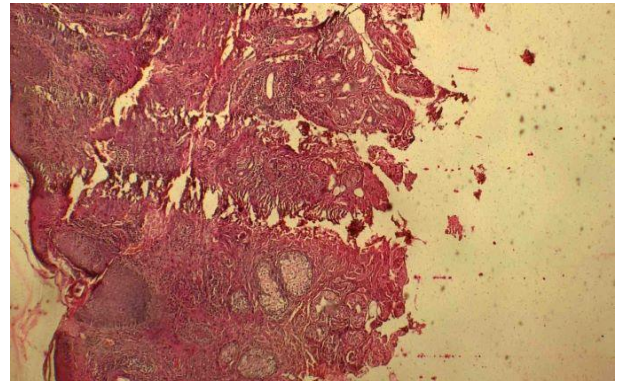


**Figure (4):** Fulguration artifact

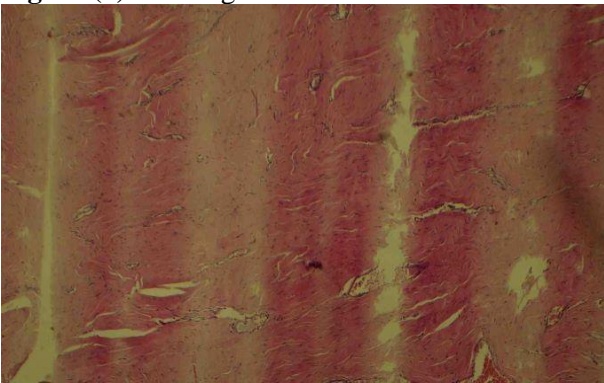
Folding (Fig. 5) and nicking (Fig. 6) are common artifacts in microtomy. Alternate thick and thin sections (Fig. 7), Tangential cut artifact (Fig. 8) also may occur.



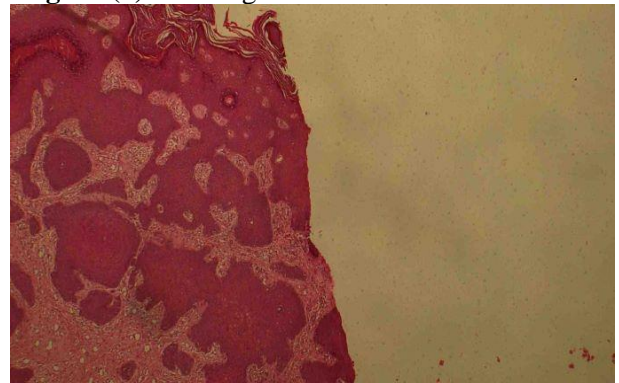
**Figure (5):** Folding artifact



**Figure (6):** Nicking artifact

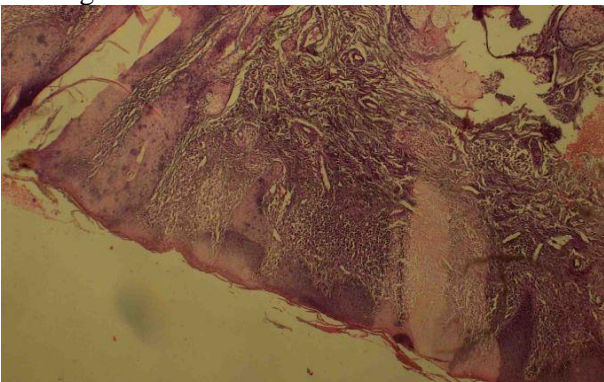


**Figure (7):** Alternating thin and thick artifact

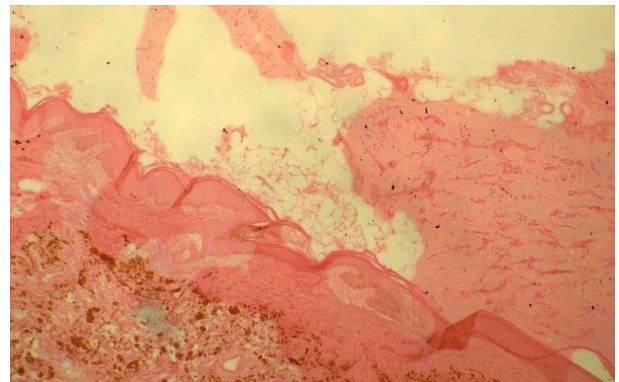


**Figure (8):** Tangential cutting artifact

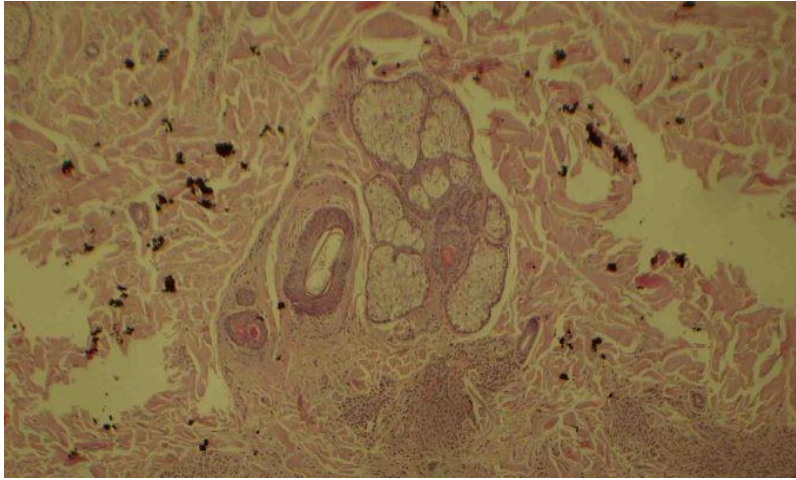
Failure of wax remove (Fig. 9), homogenous deep pink-stain (Fig. 10), deep black pigmentation (Fig. 11), all are related to staining artifacts.



**Figure (9):** Incomplete de-waxing artifact

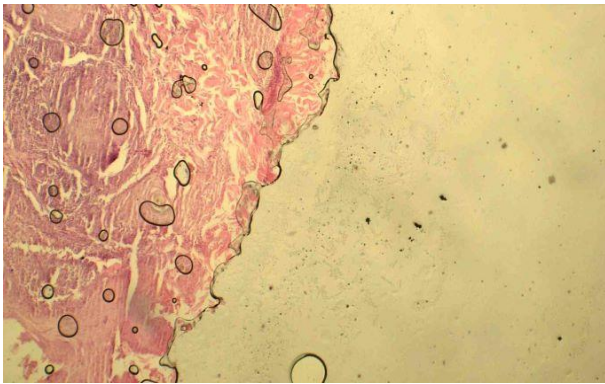


**Figure (10):** Eosin leaching artifact

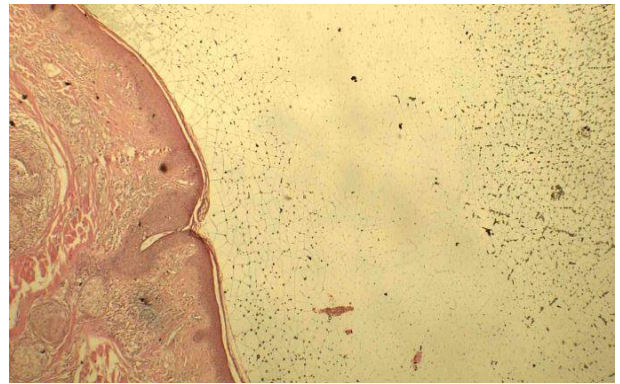


**Figure (11):** Stain deposition artifact

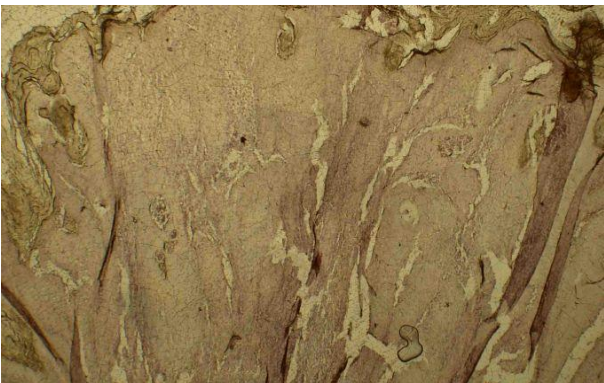
Air bubbles (Fig. 12), mounting media cracked (Fig. 13), Stain bleaching (colour diminished) (Fig. 14) all are related to mounting and cover slipping artifacts. While (Fig. 15) show stromal artifact which occur in basal cell carcinoma were proved as assisted clue for diagnosis.



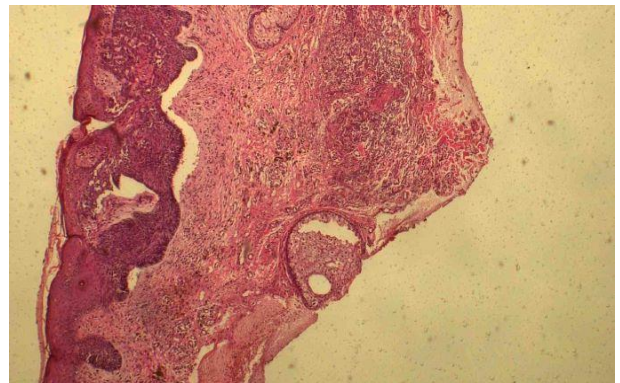
**Figure (12):** Air bubbles artifact



**Figure (13):** Cracked of DPX



**Figure (14):** Stain bleaching artifact



**Figure (15):** Stromal artifact in BCC

Generally, artifacts in histopathological slide were effect minimally in reading the slide and subsequently final diagnosis, although obscuring of diagnosis accounting 27 (4.576%).

## DISCUSSION

Even with careful preparing and handling skin specimen, through automated processing and serial steps in laboratory, artifact seems to be not avoidable. Many articles explain types and remedies of artifacts<sup>(23,24)</sup>. After evaluation of (590) slides with (931) artifacts, folding artifact accounted the majority. Similar data obtain from Igho and Aimakhume<sup>(25)</sup>.

Dry mounting accounted second common cause of artifact in this study, which may be related to shortage of material and improper storage of slides, which show nearly similar percentage with article of Mahesh *et al.*<sup>(26)</sup>. Crush artifacts and air bubbles artifacts accounting about (11%) for each, which can be avoided by gentle handling of skin biopsy and applying mild pressure by blunt needle. Common staining artifacts in this study were related to improper de-wax, Wyunchuk published an article deals with these artifacts<sup>(27)</sup>. Least types of artifacts in this study were that related to fixation and electro-fulguration which account (0.644%) for each type that can be avoided by proper fixation and using of surgical knife for separation of biopsied tissue, using of low milliamperage electrical current<sup>(24)</sup>.

## CONCLUSION

Histopathological evaluation of skin biopsies had long, and multiple stages done by the dermatologist, assistant pathologists, and lab technicians, that leads to increased incidence of errors and artifacts. Artifacts may occur in most of the histopathological section and may interfere with the interpretation of histopathological diagnosis. It says that the recognition of artifacts seems to be overcome but avoiding them are still challenge even with gentle specimen handling and get rid of wrong technique modes.

**Conflict of interest:** The authors declare no conflict of interest.

**Sources of funding:** This research did not receive any specific grant from funding agencies in the public, commercial, or not-for-profit sectors.

## REFERENCES

1. **Eva B (2006):** Dermatopathology with 138 figures in 445 separate illustrations and 5 tables. Springer-Verlag Berlin Heidelberg, pp 231. ISBN-10 3-540-30245-X Springer-Verlag Berlin Heidelberg New York.
2. **Hunter J, Savin J, Dahl M (2002):** Clinical dermatology. 3ed ed. Blackwell Science Ltd., pp37-38.
3. **Al-Rawi J, Ahmed M, Salloom A (2022):** Evaluation of skin biopsies in Al-Yarmouk teaching hospital. International Journal of Health Sciences, 6(S6): 289–299.
4. **Bancroft J, Stevens A (2008):** Theory and practice of histological technique 6th edition. Churchill Livingstone, Elsevier Health Sciences, PP 53-105.

5. **Moule I, Parsons P, Irvine G (1995):** Avoiding artifacts in oral biopsies: the punch biopsy versus the incisional biopsy. Br J. Oral Maxillofac Surg., 33: 244-247.
6. **Bernstein M (1976):** Biopsy techniques: the pathological considerations. J Am Dent Assoc., 96(3): 438-443.
7. **Margarone J, Natiella J, Vaughan C (1985):** Artifacts in oral biopsy specimens. J. Oral Maxillofac Surg., 43(3): 163-72.
8. **Scott T, Jaspreet S, Brian D et al. (2006):** Uncommon Cancers of the Prostate, In Textbook of uncommon cancer. 3<sup>rd</sup> ed. John Wiley & Sons, Ltd. doi.org/10.1002/0470030542.ch4.
9. **Thompson S, Luna L (1978):** An atlas of artifacts encountered in the preparation of microscopic tissue sections. 1st ed. Illinois: Springfield.
10. **Logan R, Goss A (2010):** Biopsy of the oral mucosa and use of histopathology services. Aust Dent J., 55:9-13.
11. **Jephcott A (2007):** Surgical management of the oral tissues. 2 surgical techniques. Dent Update, 34:654-657.
12. **Graham C (2008):** Outcomes of Skin Surgery. Informa Ltd. https://doi.org/10.3109/9780203091777.
13. **Taqi S, Sami S, Sami L et al. (2018):** A review of artifacts in histopathology. Journal of Oral and Maxillofacial Pathology, 22(2): 279.
14. **Yellowitz J, Horowitz A, Goodman H et al. (1998):** Knowledge, Opinions and practices of general dentists regarding oral cancer: A pilot study. J Am Dent Assoc., 129 (5): 579-583.
15. **Ficarra G, McClintock B, Hansen L (1987):** Artifacts created during oral biopsy procedure. J Craniomaxfac Surg., 15: 34-37.
16. **Ellis R, Woods A (1994):** Laboratory histopathology. A complete reference. Edinburg: Churchill Livingstone. https://lib.ugent.be/catalog/rug01:000337340.
17. **Krishnanand P, Kamath V, Nagaraja A et al. (2010):** Artefacts in oral mucosal biopsies: A review. J Orofac Sci., 2(1): 57-62.
18. **Culling C (1963):** Handbook of histopathological techniques. 2nd ed. London: Butterworth and Co (Publishers) Ltd p. 123.
19. **Carleton H, Drury R, Wallington E (1967):** Carleton's textbook of histological techniques (5th ed). The University of Michigan: Oxford University Press.
20. **Faoláin E, Hunter M, Byrne J et al. (2005):** Raman spectroscopic evaluation of efficacy of current paraffin wax section dewaxing agents. J Histochem Cytochem., 53:121-9.
21. **Chatterjee S (2014):** Artefacts in histopathology. J Oral Maxillofac Pathol., 18: S111-S116.
22. **McInnes E (2005):** Artefacts in histopathology. Comp Clin Path., 13:100-8.
23. **Varun R, Naveen B, Swati A et al. (2013):** Artefacts: A Diagnostic Dilemma. Journal of Clinical and Diagnostic Research, 7(10): 2408-2413.
24. **Ekundina V, Eze G (2015):** Common artifacts and remedies in histopathology (a review). Afr J Cell Pathol., 4:6-12.
25. **Igho O, Aimakhume A (2017):** Artifacts in histology: A 1-year retrospective study. Ann Bioanthropol., 5: 34-39.
26. **Mahesh S, Shashikala P and Kavitha G (2020):** A menace in histopathology. International Journal of Clinical and Diagnostic Pathology, 3(1): 290-292.
27. **Wynnychuk M (1990):** An Artifact of H&E Staining: The problem and its solution. The J Histotechnol., 13:193-198.