

Assessment of The Effect of Lyophilized Platelet-Rich Plasma on Superficial Wrinkles

May H. El-Samahy, Tabarak R. M. Alwaheely, Mona A. Ibrahim*

Department of Dermatology, Venereology, and Andrology, Faculty of Medicine, Ain Shams University, Egypt

*Corresponding author: Mona Abdel-Halim Ibrahim, Mobile: (+20) 01006228698,

E-mail: monaabdelhalim@med.asu.edu.eg

ABSTRACT

Background: Lyophilized platelet-rich plasma (L-RPR) is considered a simple and effective comparable method to fresh preparations of platelet-rich plasma (PRP). It is prepared using platelets concentration derived from different donors. It is ubiquitously available and enables medical professionals to inject a specific volume of growth factors. **Objective:** The aim of the current study is to assess the effect of L-PRP in treating superficial wrinkles.

Patients and methods: The present one-arm clinical trial was performed on 20 adult females (age range between 30 and 50 years old) with Type I and II superficial wrinkles (Glogau classification). The entire face was injected with a 2 cm reconstituted vial of sterilized L-PRP (L-GF[®]) for 3 treatment sessions at 2-week intervals. The evaluation was done before each treatment session and 2 weeks after the last session with 8 megapixels and Antera 3D[®] cameras. The wrinkles indentation index, the texture (roughness) score, the average melanin level, and the melanin variation were calculated.

Results: The mean duration of wrinkles was 5.8 (SD 2.9) with a range of 2-12 years. Most cases (95%) had skin type III and Glogau classification type II (75%). A statistically significant difference was found before and after treatment in the average melanin level using Antera 3D[®] camera assessment. However, no significant difference was found before and after treatment regarding the roughness score, melanin variation level, and wrinkle indentation index. Treatment was well tolerated with minimal local side effects.

Conclusion: L-PRP is a safe, simple, and cost-effective treatment modality for aging-related hyperpigmentation.

Keywords: L-PRP, wrinkles, PRP, Pigmentation, Aging, One-arm.

INTRODUCTION

Skin aging is a physiological process that poses significant distress to many people, especially females. Skin aging occurs by combined mechanisms; intrinsic as hereditary or hormonal factors and extrinsic as ultraviolet rays (UVR) and smoking. The combination of these factors leads to the appearance of signs of aged skin clinically in the form of atrophy, laxity, sagging, dryness, dyspigmentation, telangiectasia, and wrinkles⁽¹⁾. The increased desire to look younger led to the development of novel dermatological techniques for treating skin aging. Recently, a greater emphasis has been placed on minimally invasive treatments and approaches for treating skin elasticity, wrinkles, dyspigmentation, roughness, and skin photodamage⁽²⁾.

Platelet-rich plasma (PRP) has gained interest as a minimally invasive technique in treating the signs of skin aging. PRP stimulates the body's natural healing process and tissue regeneration by releasing platelet-derived compounds at the treatment site in a hyperphysiologic manner. It may result in the reduction of a number of age-related skin aging symptoms⁽³⁾.

Lyophilized PRP (L-PRP) is a novel and refined form of PRP. It shares the same first preparation steps, benefits, and uses of PRP. However, L-PRP uses allogenic, pathogen-free platelets as a source of growth factors as opposed to autologous platelets. It offers many advantages over fresh preparations of

PRP as it has a much longer shelf life (12 months in L-PRP vs 8 hours in fresh preparations). In order to achieve standardization, apheresis and platelet processing were obtained from different volunteers, thereby eliminating variations in the concentrations of platelets and growth factors between individual donors⁽⁴⁾.

On the other hand, leukocyte depletion, gamma irradiation, or lyophilization have no deleterious effects on growth factor concentrations^(5,6).

L-PRP powder contained a variety of growth factors, such as transforming growth factor β 1 (TGF- β 1), platelet-derived growth factor-AB (PDGF-AB), vascular endothelial growth factor (VEGF), basic fibroblast growth factor (bFGF), insulin-like growth factor 1 (IGF-1), epidermal growth factor (EGF), interleukin (IL)-1a, IL-1b, and IL-1 receptor agonist (IL-1RA)⁽⁷⁾. These various growth factors can have a beneficial effect in reducing skin aging. Scarce data is available on the role of L-PRP in skin rejuvenation. The aim of the current study is to assess the effect of L-PRP in treating superficial wrinkles.

PATIENTS AND METHODS

The study groups:

The present one-arm clinical trial included 20 adult females (30-50 years old) with superficial wrinkles (Type I and II by Glogau classification)⁽⁸⁾.

Exclusion criteria include patients who had received facial dermabrasion procedures, topical or systemic retinoid use, facial botulinum toxin

injection in the last 6 months, facial dermal filler material in the last year, or systemic drug (especially those affecting facial skin as hormone replacement therapy). Patients with deep wrinkles (type III and IV by Glogau classification), pregnancy, skin disorders, autoimmune diseases, malignancy, and severe systemic illness were also excluded.

All patients were subjected to full history taking with particular emphasis on previous treatment of wrinkles, history of the systemic drug, or systemic illness. A careful general examination was performed to exclude patients with clinical manifestations suggestive of systemic disease. A dermatological examination was also done to know the patient's skin type and Glogau classification.

Before each session, local anesthesia with EMLA cream was applied to the whole face and covered with cellophane tape for approximately 45-60 minutes. The face was disinfected and degreased with alcohol. Intra-dermal injection of the whole face was done with one vial of L-GF[®] in 1 cm equidistant points using a 23-gauge needle. The vial is first reconstituted with 2 cm distilled water and gently swirled for 3 minutes to ensure complete protein rehydration. L-GF[®] is L-PRP prepared at the Cairo Medical Center (CMC) blood bank and was standardized to a dose of 1×10^6 platelets/vial. All patients received 3 treatment sessions at 2-week intervals. After each session, sunscreen cream was advised to be used daily before sun exposure and re-applied every 2 hours.

Method of L-GF[®] powder preparation:

L-GF[®] powder was obtained by apheresis collected from different donors using 12 platelet concentrates (PCs). Each PC underwent a series of washing procedures that eliminated all cellular components and brought the plasma protein concentration down to about 30 mg/mL.

All suspensions were then divided into 1 mL portions, freeze-dried, and the resulting lyophilized PRP powder was obtained⁽⁹⁾. Thereafter, a pooled batch was produced⁽¹⁰⁾. The requisite growth factor concentration was determined from each batch using an ELISA kit-based approach⁽¹¹⁾.

To make it less likely to cause allergies and kill all pathogens, every PC utilized in L-GF[®] powder preparation was leuko-depleted. Additionally, prior to processing, all pooled PCs were gamma-irradiated to prevent graft-versus-host disease. Moreover, processing the pooled PC into L-GF[®] powder eliminated pathogens, and washing decreased the protein level, which could induce allergic reactions⁽¹²⁾.

Finally, using approved testing techniques, L-GF[®] powder has been examined and confirmed to be non-reactive for HBsAg, HIV antibodies, HIVp24 antigen, HCV antibodies, and antibodies to

Treponema pallidum. Nuclear acid testing is used to further investigate the seronegative plasma of such pathogens (NAT)⁽¹³⁾. As a result of changes in the bioactivity of platelets throughout time, it is recommended to use the vial within 3 hours after vial reconstitution when stored between (15-22°C). However, the shelf life of undiluted L-GF[®] powder is approximately one year.

The assessment of results:

The photographic evaluation was done before each session and 2 weeks after the last session. Facial photographs were taken at more than one profile (front, right, and left) for each patient using 8 megapixels camera. Photos were standardized to the area, distance, illumination, angle of exposure, and background so that there were no major differences between the series of photographs. For more precise photographic evaluation, a multi-LED hand-held Antera 3D[®] camera (Miravex Ltd., Dublin, Ireland) was also employed. In order to ensure direct comparison of the same area, the camera is combined with area-matching software. The four areas of the face (forehead, right and left cheek, and chin) were examined.

Using Antera 3D[®], a high-resolution color image was first obtained; then, the following parameters were recorded for all patients each time:

1. The indentation index of the wrinkles: this was done using a medium (2mm) filter; it measures the negative vertical deviations of the surface from its ideal form in arbitrary units (au.). The depth, width, and average cross-section of an individual wrinkle can be calculated in millimeters (mm).
2. The average roughness (Ra) score texture: this was done using a medium (2mm) filter; it analyzes the skin's topography and texture. The vertical disparities between an actual surface and its ideal shape are used to quantify roughness. The surface is characterized as rough if these variations are considerable and smooth if they are minimal. The values are shown as (au.)
3. The average melanin level: This is the average concentration of melanin per unit area relative to the selected area. It also maps the distribution of melanin. The values are expressed in (au.)
4. Melanin Variation. This parameter assesses the homogeneity of the pigment and examines the variance of melanin in the chosen region. The pigment's homogeneity has an inverse relationship with the variation. The variation offers crucial parameters for assessing the skin's complexion. The values are expressed in (au.)

All parameters are displayed in the data display bar of the software and represented by a false color

map. Each parameter was calculated for the four areas of the face. The mean value for the whole face was calculated as follows: forehead value + right cheek value + left cheek value + chin value divided by 4.

Ethical consent:

The Research Ethical Committee, Faculty of Medicine, Ain Shams University, accepted the study and found that it complied with all the ethical standards needed for human research. All patients were supplied with comprehensive information regarding the nature of the treatment method, potential side effects, and photographic records. Written informed consent was obtained from all participants. This study was executed according to the code of ethics of the World Medical Association (Declaration of Helsinki) for studies on humans.

Statistical analysis

The Statistical Package for Social Science was used to code, tabulate, and transmit the data to a computer (IBM Corp. Released 2011). Qualitative data were defined as numbers and percentages. Chi-Square test and Fisher’s exact test were used for comparison between categorical variables as appropriate. Quantitative data were tested for normality by Kolmogorov-Smirnov test.

Quantitative was described as mean, standard deviation (SD) and range were computed for numerical data that were parametric; median and interquartile range (IQR) were computed for numerical data that were non-parametric.

The Student T-Test was used to assess the statistical significance of the variance between the means of the two research groups. The statistical significance of the difference between two means assessed twice for the same research group was evaluated using a paired t-test. Correlation analysis (using Pearson’s technique) was used to assess the strength of the link between two quantitative variables. P value ≤0.05 was considered to be statistically significant.

RESULTS

Among 20 female patients, the mean age was 40.31 (SD 5.05) with a range of 32-48 years. The mean duration of wrinkles was 5.8 (SD 2.9) with a range of 2-12 years. Most cases (95%) had Skin type III, and Glogau classification type II (75%).

There was no significant difference between before and after treatment regarding the indentation index of facial wrinkles (P=0.496), the roughness score (P=0.527), or melanin variation (P=0.377). However, there was a significant difference between average melanin levels before and after treatment (P=0.022) (Table 1 and Figure 1).

Table (1): Description and comparison of wrinkles indentation index, texture (roughness), average melanin level, and melanin variation before and after treatment among study cases

Variable	Before treatment		After treatment		P-value
	Mean ± SD	Range	Mean ± SD	Range	
Face wrinkles indentation index	17.62 ± 2.57	13.68-21.94	17.39 ± 2.54	13.15-23.02	0.496
Face texture roughness	18.28 ± 2.82	14.32-24.73	18.48 ± 3.07	14.09-25.95	0.527
Average melanin level	0.68 ± 0.07	0.57-0.84	0.67 ± 0.06	0.56-0.79	0.022*
Melanin variation	0.05 ± 0.01	0.03-0.06	0.05 ± 0.03	0.04-0.16	0.377

SD, standard deviation; *P<0.05 is significant; Paired t-test.

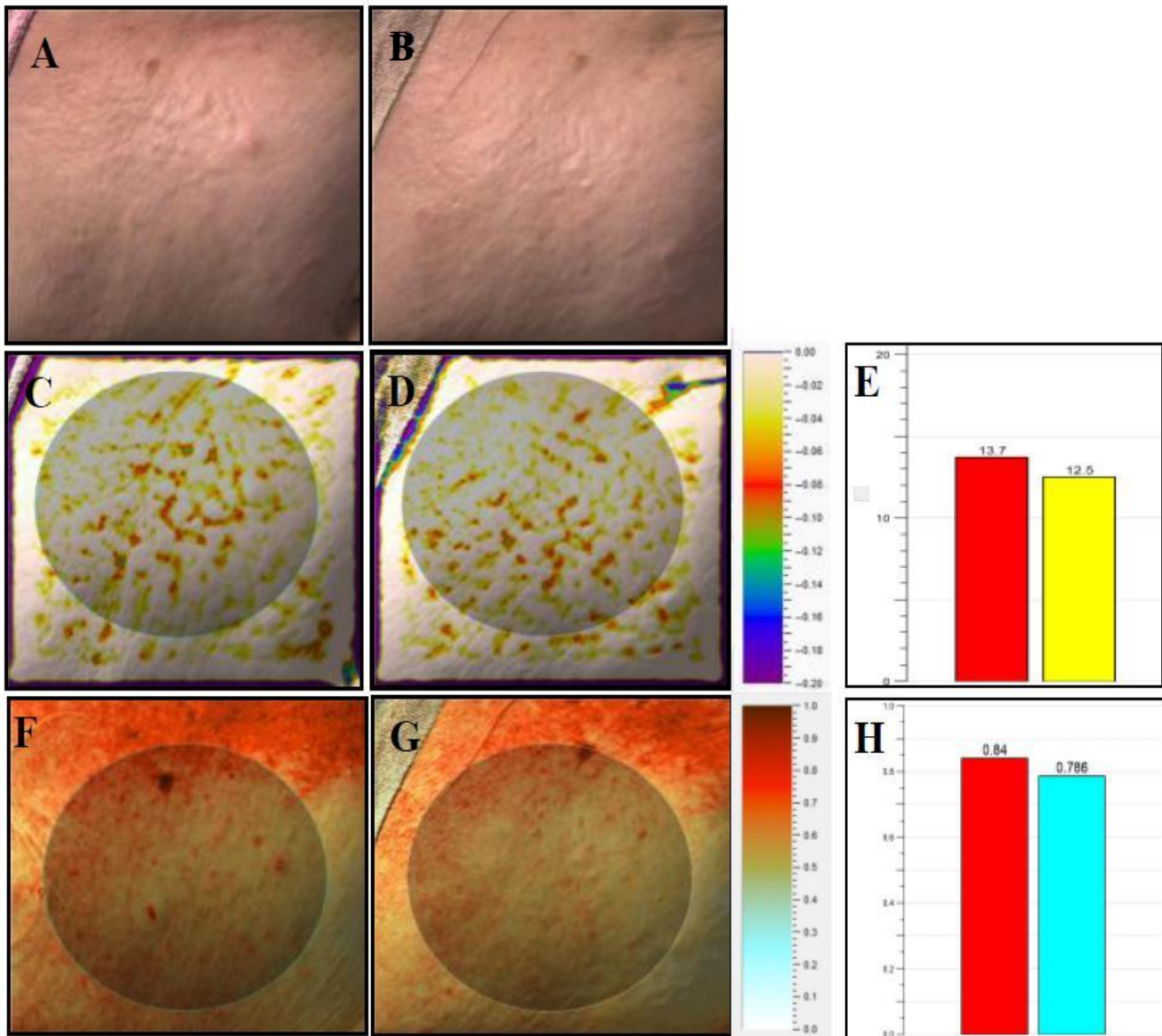


Figure (1): A case of right cheek wrinkles examined by Antera 3D[®] camera. (A): Color image mode before treatment. (B): Color image mode after treatment. (C): Wrinkle mode before treatment. (D): wrinkle mode after treatment showing mild improvement of facial wrinkles; the color chart on the right shows the different depths of the depressions of wrinkles, measured in mm under a medium filter. (E): a graph showing the indentation index before (13.7) and after treatment (12.5), measured in arbitrary units. (F): Melanin mode before treatment. (G): Melanin mode after treatment shows improvement of the average melanin level; the color chart on the right shows the different concentrations of melanin represented by different shades of brown colors and measured in arbitrary units. (H) a graph showing the average melanin level before (0.84) and after treatment (0.796), measured in arbitrary units. The evaluated area is shaded in (C), (D), (F), and (G).

There was no significant difference ($P>0.05$) between Glogau I and II cases as regards the indentation index of facial wrinkles, roughness score of texture, average melanin level, and melanin variation before treatment. There was a significant positive correlation between age and between the indentation index of facial wrinkles, the roughness score of texture, and the average melanin level; however, no significant difference was found between age and the melanin variation before treatment (**Figure 2**).

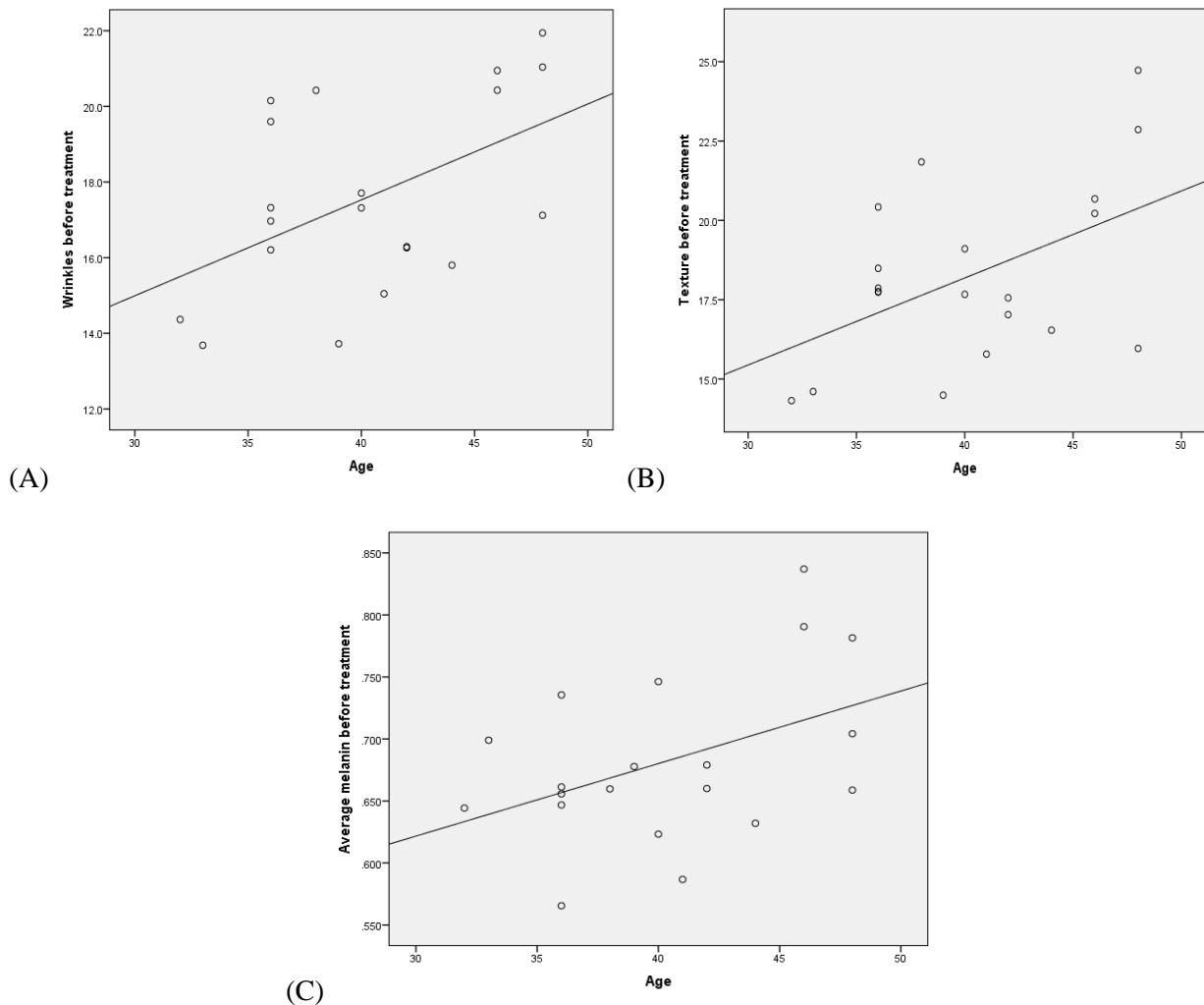


Figure (2): There is a positive correlation between age and (A) the indentation index of facial wrinkles, (B) the roughness score of texture, (C) and the average melanin level in cases before treatment.

DISCUSSION

PRP has recently become a popular aesthetic treatment. It contains various growth factors that can induce collagen synthesis and down-regulate collagen degradation⁽¹⁴⁾. However, there is a general lack of standardization of protocols, concentrations, and doses of PRP that is used in clinical trials and medical practice. In addition, PRP preparation involves several steps of blood withdrawal and centrifugation which is time-consuming. It also requires more staff resources and is considered less convenient to the patients.

L-PRP is another simple method of preparation for growth factors. It is prepared using platelets concentration derived from different donors⁽¹⁵⁾. It has many advantages over PRP. It allows physicians to apply a defined amount of growth factors. Moreover, L-PRP is ubiquitously available as it shows no need for centrifugation, therefore saving effort and time in clinical practice⁽⁴⁾.

A comparative study between fresh and L-PRP showed that both techniques have the same concentrations of growth factors (PDGF, EGF, TGF- β , VEGF), and both can induce fibroblastic proliferation after 24h. This study proves that L-PRP

can be used as an alternative to fresh PRP. The actions of various growth factors promote the proliferative activity of L-PRP⁽¹⁶⁾.

In the current study, we included 20 females recruited from the dermatology outpatient clinic of Ain-Shams University Hospitals. The study group was middle-aged, with most cases (95%) having Skin type III. 75% had type II wrinkles, whereas 25% had type I wrinkles by Glogau classification. One reconstituted vial of L-PRP (L-GF[®]) was introduced per session at 2 weeks intervals for 3 sessions in four areas of the face (forehead, chin, right and left cheeks). The assessment was done before each session and 2 weeks after the last session through the clinical photographs. In addition, we assessed the indentation index of the wrinkles, the roughness score of texture, the melanin average level, and the melanin variation using Antera 3D[®] camera.

The present study showed a significant difference between the average melanin level before and 2 weeks after the last treatment. However, no significant difference was found regarding the roughness score, the melanin variation level, and the wrinkles indentation index. These results agree with da Silva *et al.*⁽¹⁷⁾ who found no effect of L-PRP on

skin aging. They performed a Phase II pilot split-face study on females with Glogau II and III types. One side of the face was injected with L-PRP and the other with saline. No change in the collagen was found before and after treatment on both sides.

In contrast, **Cheng et al.**⁽¹⁸⁾ found that L-PRP is efficient and convenient in skin rejuvenation, comparable to the original PRP. They injected 4-7 vials of L-PRP per treatment session, totaling 20 vials for all sessions. The treatment interval ranged 2-4 weeks. They used various assessment tools (photography, Visia camera, DermaLab USB ultrasound examination, and histologic assessment of collagen and elastic fibers). There was an improvement in the wrinkles and skin texture before and after treatment. The discrepancies in results found between studies may be attributed to many factors, including the difference in the ethnic group, the different assessment tools, the dose of L-PRP, and the frequency of treatment.

Several studies have investigated the role of PRP in skin rejuvenation. Although most of these studies showed positive results, they didn't all perform randomized controlled trials with consistent quality. In addition, there is no standardization of the PRP protocols between different clinical trials. The few higher-quality clinical trials - that were published over the last years - showed less favorable outcomes. Therefore, there is a general lack of evidence-based recommendations and international consensus regarding using PRP in skin rejuvenation. Larger randomized controlled studies are still warranted for further evaluation of the use of PRP in the treatment of skin aging^(19,20).

To the best of our knowledge, no studies have evaluated the role of L-PRP in age-related hyperpigmentation. However, several studies have evaluated fresh PRP in treating hyperpigmentation, with controversial results. **Nofal et al.**⁽²¹⁾ found improvement in hyperpigmentation by PRP injections. They injected 1 ml of PRP for 7 sessions (every 2 weeks) in the left periorbital area of 30 patients. The results were assessed using visual analogue scale (VAS) for periorbital hyperpigmentation by both investigators and patients after each session and after 3 months of the last session. They found that 55% of patients achieved a fair response, 15% achieved a good response, and 30% achieved an excellent response in reducing periorbital hyperpigmentation. Moreover, **Al-Shami**⁽²²⁾ injected PRP every month for 3 sessions into the whole face and the periorbital area of 50 patients. The therapeutic outcomes were assessed 3 months after the last session by standardized digital photography. He found that 46% of patients had moderate improvement, 38% had mild improvement, 4% reported excellent improvement, and 12% had significant improvement in the appearance of the dark circles around the eyes. Therefore, both original

PRP and L-PRP can lead to a decrease in skin pigmentation.

On the other hand, **Mehryan et al.**⁽²³⁾ reported controversial results. They performed one single injection of PRP (1.5 ml) into the creases around the crow's feet and the tear trough for 10 patients. Three months after the injection, they assessed melanin content using Mexameter probe, stratum corneum hydration using Corneometer, and wrinkles volume using Skin Surface Analyzer device and software. In terms of wrinkle volume, stratum corneum moisture, and melanin concentration, they revealed no statistically significant alterations. As mentioned, these discrepancies in the results between different studies are mostly attributed to the difference in the treatment protocol and assessment methods. This warrants larger-scale randomized controlled studies that compare different PRP treatment protocols in the management of different skin problems.

In the current study, a significant correlation was found between the age of the patients and the indentation index of the wrinkles, the roughness score of the texture, and the average melanin level before treatment. This was in concordance with **Linming et al.**⁽²⁴⁾ who did their study on 28 patients using Antera 3D[®] camera. They found that the wrinkles' indentation index, the texture's roughness score, and the average melanin level were positively correlated with age ($P < 0.05$).

In this study, L-PRP turned out to be a potentially safe option with minimal post-treatment complications. Only mild pain at the injection site was reported and lasted for a few hours after the session. This was in concordance with other studies^(17,18). No immunogenicity or infection occurred among cases. However, the use of heterologous L-PRP should be investigated more as it still carries a potential risk of immunogenicity and infection^(16,25).

Though no significant results were found regarding the improvement of facial wrinkles, the presence of significant results regarding the improvement of facial pigmentation may throw light on the role of L-PRP as an effective, simple, and cost-effective method in improving age-related pigmentary changes.

The study's limitations include its limited sample size and brief follow-up time. So, we recommend further studies on a large series of patients with long-term follow-up to detect the delayed and prolonged effect of L-PRP on collagen deposition. In addition, histopathological and immunohistochemical studies are needed to assess its effect on collagen remodeling and melanin density. Moreover, the protocol of L-PRP, including the dose, concentrations, and the number and interval of sessions, should be optimized to ensure the best results for skin rejuvenation.

CONCLUSION

L-PRP is a safe, simple, and cost-effective treatment modality for aging-related hyperpigmentation.

Acknowledgment: We would like to thank Professor Hossam Mostafa Fahmy, professor of clinical pathology, Ain Shams University for his efforts in the preparation of L-GF[®].

Source(s) of support: None.

Conflicting Interest: None.

REFERENCES

1. **Zhang S, Duan E (2018):** Fighting against Skin Aging: The Way from Bench to Bedside. *Cell Transplantation*, 27(5):729-38.
2. **Sparavigna A, Tenconi B, De Ponti I (2015):** Antiaging, photoprotective, and brightening activity in biorevitalization: a new solution for aging skin. *Clinical, Cosmetic and Investigational Dermatology*, 8:57-65.
3. **Maisel-Campbell A, Ismail A, Reynolds K et al. (2020):** A systematic review of the safety and effectiveness of platelet-rich plasma (PRP) for skin aging. *Archives of Dermatological Research*, 312(5):301-15.
4. **Kieb M, Sander F, Prinz C et al. (2017):** Platelet-Rich Plasma Powder: A New Preparation Method for the Standardization of Growth Factor Concentrations. *The American Journal of Sports Medicine*, 45(4):954-60.
5. **Pan L, Yong Z, Yuk K et al. (2016):** Growth Factor Release from Lyophilized Porcine Platelet-Rich Plasma: Quantitative Analysis and Implications for Clinical Applications. *Aesthetic Plastic Surgery*, 40(1):157-63.
6. **Filardo G, Di Matteo B, Di Martino A et al. (2015):** Platelet-Rich Plasma Intra-articular Knee Injections Show No Superiority Versus Viscosupplementation: A Randomized Controlled Trial. *The American Journal of Sports Medicine*, 43(7):1575-82.
7. **Kushida S, Kakudo N, Morimoto N et al. (2014):** Platelet and growth factor concentrations in activated platelet-rich plasma: a comparison of seven commercial separation systems. *Journal of Artificial Organs*, 17(2):186-92.
8. **Glogau R (1996):** Aesthetic and anatomic analysis of the aging skin. *Seminars in Cutaneous Medicine and Surgery*, 15(3):134-8.
9. **DeLong J, Russell R, Mazzocca A (2012):** Platelet-rich plasma: the PAW classification system. *Arthroscopy*, 28(7):998-1009.
10. **Roffi A, Filardo G, Assirelli E et al. (2014):** Does platelet-rich plasma freeze-thawing influence growth factor release and their effects on chondrocytes and synoviocytes? *BioMed Research International*, 2014:692913. doi: 10.1155/2014/692913
11. **Dohan Ehrenfest D, Andia I, Zumstein M et al. (2014):** Classification of platelet concentrates (Platelet-Rich Plasma-PRP, Platelet-Rich Fibrin-PRF) for topical and infiltrative use in orthopedic and sports medicine: current consensus, clinical implications and perspectives. *Muscles, Ligaments and Tendons Journal*, 4(1):3-9.
12. **Creaney L, Hamilton B (2008):** Growth factor delivery methods in the management of sports injuries: the state of play. *British Journal of Sports Medicine*, 42(5):314-20.
13. **Bausset O, Giraudo L, Veran J et al. (2012):** Formulation and storage of platelet-rich plasma homemade product. *Bio Research Open Access*, 1(3):115-23.
14. **Raeissadat S, Rayegani S, Hassanabadi H et al. (2015):** Knee Osteoarthritis Injection Choices: Platelet-Rich Plasma (PRP) Versus Hyaluronic Acid (A one-year randomized clinical trial): Clinical medicine insights. *Arthritis and Musculoskeletal Disorders*, 8:1-8.
15. **Burnouf P, Juan P, Su C et al. (2010):** A novel virally inactivated human platelet lysate preparation rich in TGF-beta, EGF and IGF, and depleted of PDGF and VEGF. *Biotechnology and Applied Biochemistry*, 56(4):151-60.
16. **da Silva L, Montalvão S, Justo-Junior A et al. (2018):** Platelet-rich plasma lyophilization enables growth factor preservation and functionality when compared with fresh platelet-rich plasma. *Regenerative Medicine*, 13(7):775-84.
17. **da Silva L, Cancela R, de Lima Montalvão S et al. (2021):** The effect of lyophilized platelet rich-plasma on skin aging: a non-randomized, controlled, pilot trial. *Archives of Dermatological Research*, 313(10):863-71.
18. **Cheng T (2020):** Utilization of lyophilized platelet-rich plasma in esthetic facial treatment. *Journal of Cosmetic Medicine*, 4(2):101-107.
19. **Schoenberg E, Hattier G, Wang J et al. (2020):** Platelet-rich plasma for facial rejuvenation: An early examination. *Clinics in Dermatology*, 38(2):251-3.
20. **Atiyeh B, Oneisi A, Ghieh F (2021):** Platelet-Rich Plasma Facial Rejuvenation: Myth or Reality? *Aesthetic Plastic Surgery*, 45(6):2928-38.
21. **Nofal E, Elkot R, Nofal A et al. (2018):** Evaluation of carboxytherapy and platelet-rich plasma in treatment of periorbital hyperpigmentation: A comparative clinical trial. *Journal of Cosmetic Dermatology*, 17(6):1000-7.
22. **Al-Shami S (2014):** Treatment of Periorbital Hyperpigmentation Using Platelet-Rich Plasma Injections. *Journal of Dermatology and Venereology*, 3:87-94.
23. **Mehryan P, Zartab H, Rajabi A et al. (2014):** Assessment of efficacy of platelet-rich plasma (PRP) on infraorbital dark circles and crow's feet wrinkles. *Journal of Cosmetic Dermatology*, 13(1):72-8.
24. **Linming F, Wei H, Anqi L et al. (2018):** Comparison of two skin imaging analysis instruments: The VISIA[®] from Canfield vs the ANTERA 3D[®] CS from Miravex. *Skin Research and Technology*, 24(1):3-8.
25. **Keller-Stanislawski B, Lohmann A, Günay S et al. (2009):** The German Haemovigilance System--reports of serious adverse transfusion reactions between 1997 and 2007. *Transfusion Medicine (Oxford, England)*, 19(6):340-9.