

## Evaluation of The Outcomes of Intra-Operative Colonic Lavage in Non-Elective Colonic Resection and Primary Anastomosis for Sigmoid Volvulus

Sherif Albalkiny, Mohamed Elsayed Seifalyazal, Gamal Fawzy\*

Department of General Surgery, Faculty of Medicine, Ain Shams University, Egypt

\*Corresponding author: Gamal Fawzy, Mobile: (+20) 01220495554, E-Mail: dr.gamalfawzy@yahoo.com

### ABSTRACT

**Background:** Management of acute sigmoid volvulus was documented using a variety of surgical techniques. It has been established that mechanical bowel preparation is not required for elective colorectal surgery. To lower the risk of post-operative infectious complications and anastomotic dehiscence, one-stage primary resection and anastomosis of left sided colon blockage with on-table antegrade colonic lavage are becoming more and more popular.

**Objective:** The aim of the current study was to assess the safety of single stage resection and anastomosis in the treatment of acute left sided colonic blockage brought on by acute sigmoid volvulus without intraoperative colonic lavage. **Patients and methods:** This study was conducted in the Department of Surgery, Ain shams University Hospitals (Cairo, Egypt) between June 2018 till June 2021. It included 37 patients who presented with acute sigmoid volvulus and managed by colonic resection and primary anastomosis then furtherly classified into two groups based on the usage of antegrade colonic lavage to evaluate their outcome. **Results:** Preoperative characteristics of the 2 studied groups were comparable. In terms of mortality, general morbidity, or significant morbidity, there was no difference between the 2 studied groups. Operative time was significantly higher in Group I where Intra-operative Antegrade Colonic lavage (IOACL) took place, which could be attributed to the extra step of setting the lavage system and colonic irrigation time. Of the studied 37 patients, superficial wound infection occurred in 12 patients and 3 of them progressed to develop complete wound dehiscence, however; neither required further surgery as no disruption and managed conservatively with antibiotics and wound dressing. **Conclusion:** Colonic resection and primary anastomosis can be used to safely treat left-sided colonic blockage brought on by acute sigmoid volvulus without the need for mechanical bowel preparation.

**Keywords:** Left sided colonic obstruction, Sigmoid volvulus, Resection, Primary anastomosis, Intraoperative colonic lavage.

### INTRODUCTION

The sigmoid colon twisting around its mesentery is known as a sigmoid volvulus and could be attributed to abnormal narrow attachment of its root to the posterior abdominal wall which in turns results in close approximation of its two limbs and predispose to its twist around its mesenteric axis. In these vulnerable patients, lack of dietary fibers and chronic constipation could be precipitating factors for volvulus. Twisting usually occurs counterclockwise with variable degree of torsion ranging from 180° to 540°<sup>(1-3)</sup>. The most frequent type of volvulus often occurs around the mesenteric axis and is located 15–25 cm away from the anus, making sigmoidoscopic inspection possible<sup>(1-3)</sup>.

Elderly people older than 70 who have a history of persistent constipation or who have underlying neuropsychiatric illnesses are the most often afflicted group<sup>(4-15)</sup>, if prompt intervention is not done, serious complications such as intestinal gangrene and peritonitis might progress and result in death.

Around 10-50% of bowel blockages worldwide, including in Latin America, Africa, Eastern Europe, Russia, the Middle East, and India, are caused by sigmoid volvulus, compared to only 2-3% in the United States<sup>(11-14)</sup>.

It was shown that sigmoid volvulus patients tend to be younger and have less morbidities than what was previously suggested in previous reports, in a sizable population-based analysis of individuals who underwent surgery correction for the condition<sup>(16)</sup>.

The majority of patients are very young and healthy, which increases the likelihood that they will be able to recover from the condition and its surgical side effects. This is reflected in the low mortality rates following emergency surgery for acute volvulus<sup>(4-6)</sup>.

As long as patient does not have features suggestive for peritonitis, endoscopic detorsion is the preferred initial approach for sigmoid volvulus. Endoscopic reduction is being effective in reducing the volvulus in about 77–98% of patients. Additionally, it is less invasive procedure than emergent colectomy with lower mortality rate. Even so, endoscopic detorsion has recurrence rates ranging between 7 and 67%<sup>(3,15,17-19)</sup>.

Moreover, emergency endoscopic decompression could not be an available facility out of hours in most of the developing countries. Therefore, it is advised to think about a colectomy following a successful endoscopic reduction<sup>(3,12,17,19)</sup>, which may be followed by a primary anastomosis with or without proximal diversion or resection with end colostomy (Hartman's Procedure)<sup>(11)</sup>. There is insufficient high-quality evidences to favor one operational strategy over another.

Most surgeons would like to conduct initial anastomosis on mechanically cleansed bowel as a general, established criterion for safe colonic resection and anastomosis. On-table antegrade colonic lavage is intended to clear and decompress the proximal blocked colon in order to reduce abdominal distension, promote abdominal closure, and enhance colonic blood

flow. As several reviews have reported, it is not required to completely clean the colon of feces in order to maintain anastomotic integrity<sup>(6-10)</sup>. Additionally, several trials showed that colonic resection and primary anastomosis without antegrade colonic lavage was not an inferior approach to that after colonic lavage<sup>(9-10)</sup>.

In this series, we analyze individuals who presented with sigmoid volvulus and managed with colonic resection and primary anastomosis with or without on-table antegrade colonic lavage.

The aim of the current study is to assess the safety of single stage resection and anastomosis in the management of acute left sided colonic blockage brought on by acute sigmoid volvulus with or without intraoperative colonic lavage.

## PATIENTS AND METHODS

Our retrospective cohort study was carried on 88 patients who presented with acute sigmoid volvulus at Ain shams University Hospitals, between June 2018 and June 2021.

Patients who were managed with colectomy and end colostomy (Hartman's procedure, n=51) were not included in our study. Further classification for the remaining 37 patients who were managed with colectomy and primary anastomosis into two **Groups I** and **II** based on the usage of antegrade colonic lavage to evaluate their outcome.

On table antegrade colonic lavage was done in 15 patients (**Group I**) while primary anastomosis was carried out directly without colonic lavage in 22 patients (**Group II**).

Diagnosis of sigmoid volvulus was established from history of bowel obstruction, abdominal distension, and abdominal pain. Confirmation with Computerized tomography (CT) abdomen and pelvis was done in all patients. Initial resuscitation and stabilization of patient general condition was achieved in the Emergency Department via intravenous fluids and antibiotics.

Antibiotic regimen used include preoperative intravenous one gram third generation cephalosporin twice per day combined with metronidazole 500 mg TDS and continued for one week after operation.

## Study Variables

There were several preoperative and postoperative factors gathered. Gender, age, BMI, the ASA score (American Society of Anesthesiology physical state categorization), and patient comorbidities were preoperative factors.

Operative time is one of the operational factors. The 30-day postoperative outcomes included mortality, significant morbidity, including reoperation within 30 days, organ space surgical site infection (SSI), wound dehiscence, postoperative sepsis, postoperative myocardial infarction, pulmonary embolism, or anastomotic leak, and length of hospital stay.

## Surgical technique

To facilitate access to the anal canal, the patient will be placed in the lithotomy position. All laparotomies involved a lower midline incision, formal abdominal exploration, and evaluation of the viability of the intestine.

Decompressing the sigmoid colon after manual detorsion of the colon to remove the blockage, followed by large bore-controlled suction of the colon's contents through a colotomy; a purse string suture was used to anchor the Foley catheter. Closing the colotomy and isolating the sigmoid colon from the surgical field required the division of the colon between 2 non-crushing occluding clamps.

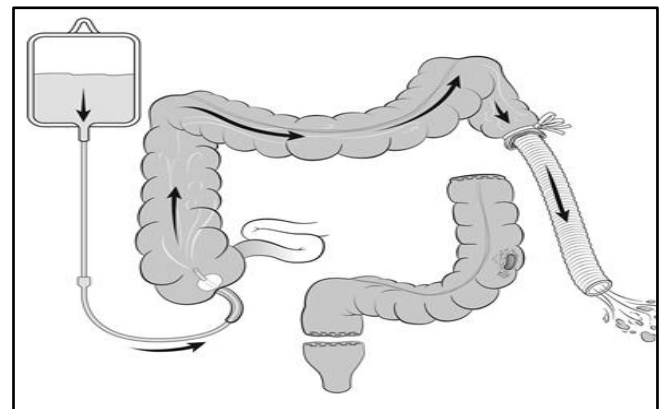
Proximal and distal colon decompression was done manually with great care. When there was good free marginal bleeding, the superfluous sigmoid colon was removed proximally and distally.

When antegrade colonic lavage was performed intra-operatively (**Figure 1**), an intravenous line tube is placed by an appendicular orifice or via a tiny enterotomy in the ileum into the caecum.

To prevent irrigation from refluxing into the small intestine, a soft bowel clamp is placed on the terminal ileum proximal to the ileotomy. The other end of the line is attached to a 2L bag of warm Hartmann's solution. A size 10 cuffed endotracheal tube has been placed per anum or in the mobilized sigmoid allows for adequate effluent control when using the lavage procedure.

An adequate mobilization of the rectum and descending colon to provide a tension-free, well-vascularized anastomosis was assured. Cleansing the bowel ends with swabs dipped in povidone iodine was followed by a single-layered tensionless, interrupted, extra mucosal anastomosis using 2-0 Vicryl or PDS suture. No patient had any covering stoma. During peritoneal lavage, normal saline was used to completely irrigate the pelvis and peritoneal cavity. Pelvic drains are often utilized in all situations.

Nylon sutures were utilized in mass closure to approximate the abdominal wall.



**Figure (1):** Intra-operative Antegrade Colonic lavage (IOACL)<sup>(13)</sup>.

On the tenth postoperative day, skin sutures or clips were removed, and the patients were advised to come back for follow-up. Patients were checked on after one month and then every 6 months for a year. The presence of pus that either discharges spontaneously or has to be drained was used to identify wound infection. Wound discharge samples were collected for sensitivity testing and culture.

Presence of fecal fistula or anastomotic dehiscence picked up during sigmoidoscopy or a laparotomy performed after peritonitis, the condition is referred to as an astomotic leak.

**Ethical Approval:**

**IRB approval from the Ethical Committee, Department of General Surgery, Ain Shams University were obtained. Written informed consent was obtained from all patients prior to operation. This study was executed according to the**

**code of ethics of the World Medical Association (Declaration of Helsinki).**

**Statistical analysis**

The collected data were introduced and statistically analyzed by utilizing the Statistical Package for Social Sciences (SPSS) version 20 for windows. Qualitative data were defined as numbers and percentages. Chi-Square test and Fisher’s exact test were used for comparison between categorical variables as appropriate. Quantitative data were tested for normality by Kolmogorov-Smirnov test. Normal distribution of variables was described as means and SD, and independent sample t-test was used for comparison between groups. P value ≤0.05 was considered to be statistically significant.

**RESULTS**

Preoperative characteristics of the 2 studied groups were comparable (**Table 1**).

**Table (1): Preoperative characteristics of patients with sigmoid volvulus undergoing Colectomy with primary anastomosis with & without IOACL.**

Variable	Group I (N= 15)	Group II (N= 22)	P-value	Significance (P ≤0.05)
Age mean (SD)	63 (7.6)	65 (7.5)	0.2	NS
Gender				
Male (N. %)	8 (53%)	12 (54.5%)	0.46	NS
Female (N. %)	7 (47%)	10 (45.5%)	0.47	NS
BMI mean (SD)	25 (2.25)	25 (2)	0.5	NS
ASA grade III and IV (N. %)	8 (53%)	12 (54.5%)	0.46	NS
DM (N. %)	2 (13.3%)	3 (13.6%)	0.489	NS
Hypertension (N. %)	6 (40%)	9 (40.9%)	0.478	NS
Congestive heart failure (N. %)	1 (6.6%)	2 (9%)	0.39	NS
COPD (N. %)	1 (6.6%)	3 (13.6%)	0.25	NS

Group I: On table antegrade colonic lavage. Group II: Primary anastomosis without colonic lavage.

In terms of mortality, general morbidity, or significant morbidity, there was no difference between the 2 studied groups (**Table 2**). Operative time was significantly higher in **Group I** where Intra-operative Antegrade Colonic lavage (IOACL) took place, which could be attributed to the extra step of setting the lavage system and colonic irrigation time.

Anastomotic leaks occurred in 3 (8%) individuals. They had gangrenous sigmoid at laparotomy and were middle-aged (54, 59, and 49 years old). The proximal colon was exteriorized as an end colostomy, the anastomosis was broken up, and the rectal stump was closed during re-laparotomy (Hartmann's procedure). After spending a total of 15 days in the hospital, patients were discharged after making a full recovery. They were later readmitted for an elective Hartmann's reversal.

Superficial wound infection occurred in 12 patients, 3 of them progressed to develop complete wound dehiscence, however; neither required further surgery as no disruption took place and managed conservatively with antibiotics and wound dressing.

**Table (2): Operative and Postoperative outcomes of patients undergoing colectomy with primary anastomosis with and without Intra-operative Antegrade Colonic Lavage.**

Variable	Group I (N= 15)	Group II (N= 22)	Total (N= 37)	P-value	Significance (P≤0.05)
<b>Operative Time in min. , Mean (SD)</b>	110 (11.6)	96 (7.8)	-----	0.000022	<b>S</b>
<b>Mortality (N. %)</b>	1 (6.6%)	0	1 (2.7%)	-----	-----
<b>Serious Morbidity (N. %)</b>	8 (53%)	16 (72%)	24 (64.8%)	0.116	NS
<b>Leakage (N %)</b>	1 (6.6%)	2 (9%)	3 (8%)	0.39	NS
<b>Wound Infection (N. %)</b>	4 (26%)	8 (36%)	12 (32%)	0.27	NS
<b>Wound dehiscence (N. %)</b>	1 (6.6%)	2 (9%)	3 (8%)	0.39	NS
<b>Organ space SSI (N. %)</b>	1 (6.6%)	2 (9%)	3 (8%)	0.39	NS
<b>Reoperation (N. %)</b>	2 (13.3%)	3 (13.6%)	5 (13.5%)	0.489	NS
<b>Pneumonia (N. %)</b>	2 (13.3%)	4 (18%)	6 (16%)	0.348	NS

Group I: On table antegrade colonic lavage. Group II: Primary anastomosis without colonic lavage.

The sole reported death was a postoperative death in **Group I**. She was an older woman (80 years old) who presented after a lengthy delay (>5 days), had a perforated colon, and was hypotensive. She had a challenging recovery, and despite receiving the best postoperative care possible in the hospital, she passed away on the seventh postoperative day from severe renal failure, pneumonia, and septicemia. The mean duration of hospital stay was 11.4 (SD 4.2) days and ranged from 8 to 20 days.

## DISCUSSION

A common cause of bowel obstruction in various regions of Africa and the Middle East is sigmoid volvulus. Many aspects of its care are still up for debate, especially the surgical approach to take in cases when endoscopic decompression is unavailable or has failed to deflate the Bowel <sup>(2,3,6)</sup>.

Multiple surgical techniques were employed, including multi-staged procedures (three stages could involve decompression colostomy, resection and anastomosis, and colostomy closure), two-stage procedures (primary resection with covering colostomy then colostomy closure), and single-stage procedures that involved intraoperative antegrade colonic irrigation followed by resection and anastomosis <sup>(16)</sup>.

Among the merits of the one staged procedure that might encourage some surgeons, are reducing the cumulative risk of anesthesia, better quality of life without having a stoma as well as will shortens hospitalization. On the other hand, risk of anastomotic failure and leakage with its consequences of sepsis and risk of multiple organ failure, should elude usage of this technique in high-risk patients.

Furthermore, colonic irrigation will also lengthen the surgical procedure, use excessive quantities of saline that may result in electrolyte imbalances, and raise the danger of spillage and contamination <sup>(10,17)</sup>.

With excellent outcomes, colonic resection with primary anastomosis after decompression and without intra-operative colonic lavage, is currently emerging as

an alternative to primary anastomosis with Intra-operative colonic lavage <sup>(6,7,8,10,19)</sup>.

Anastomotic dehiscence and incomplete colon cleaning are not clearly linked, according to recent research <sup>(7,8)</sup>.

To establish a secure anastomosis, decompression and intraoperative colonic lavage are mostly advised for patients with firm stools <sup>(10,21)</sup>. In cases of acute left-sided blockage secondary to volvulus where the colonic contents are rather liquid, decompression alone is adequate to provide a secure anastomosis. Additionally, decompression of the colon will promote abdominal closure and enhance the decompressed bowel muscle's tone and colonic blood supply <sup>(10)</sup>.

The Monk-Moynihan and closed decompression via flatus tube method, which is effective if done early before resection, as it increases anastomosis security as the divided gut wall is no longer weak and friable and will retain sutures as the normal colon, might be used to eliminate the spillage risks.

A total of 197 patients with acute intestinal blockage brought on by acute sigmoid volvulus were included in a large prospective research <sup>(10)</sup>, and they had single-stage resection and anastomosis without intraoperative lavage. The mortality rate was 1%, and two patients passed away after the procedure. This was quite similar to our results as thankfully we have not recorded any mortality in the group of patients who had their primary colonic anastomosis without performing intraoperative colonic irrigation. Our recorded mortality was from the group who had intraoperative colonic lavage, she was elderly frail patient who died because of sepsis. In fact, her selection for such approach should not be considered, ideally, should be managed with Hartman's procedure.

Our recorded mean hospital length of stay was 11.4 (SD 4.2) which was not too far from that reported in **Utpal and Shibajyoti study** <sup>(10)</sup> which was 9.8 days.

In the same study <sup>(10)</sup>, one percentage of anastomotic leak was recorded where two patients developed anastomotic leakage which empathize that

primary anastomosis without performing intraoperative colonic lavage as a one-stage method can be successfully used to treat acute sigmoid volvulus.

Although our recorded anastomotic leak rate was relatively higher (9%), but this could be attributed to our smaller sample size or to the operative selection criteria which might needed to be revised, however; this should not revoke the view that acute sigmoid volvulus managed with single-stage resection and primary anastomosis without on-table lavage, is safe to be executed since the colonic material is rather liquid and it is likely unneeded to empty the proximal colon.

So, it is obvious from our study and other reviews as well that bowel preparation should not be the cornerstone or the key factor to avoid primary anastomosis in the left colonic resections<sup>(22-24)</sup>. However, clinical judgement, tissue handling, tensionless anastomosis, well vascularized bowel ends with well-placed sutures should be the critical factors and cornerstone for patient selection for such procedure.

In the emergency management of acute sigmoid volvulus, one-stage restorative resection without on-table lavage appears to be a promising alternative approach.

## CONCLUSION

Colonic resection and primary anastomosis without mechanical bowel preparation can be used to safely treat left-sided colonic blockage brought on by acute sigmoid volvulus. It benefits from being a quicker and easier process to carry out without raising morbidity or fatality rates.

## RECOMMENDATIONS

Acute sigmoid volvulus could be managed safely with colonic resection and primary anastomosis without intra-operative colonic lavage in selected low risk patients. As per safety concept, primary anastomosis should be precluded in elderly frail patients with multiple co-morbidities.

**Financial support and sponsorship:** Nil.

**Conflict of interest:** Nil.

## REFERENCES

1. **Bhuiyan M, Machowski Z, Linyama B et al. (2005):** Management of sigmoid volvulus in Polokwane-Mankweng Hospital. *S Afr J Surg.*, 43(1):17-9.
2. **Liang J, Lai H, Lee P (2006):** Elective laparoscopically assisted sigmoidectomy for the sigmoid volvulus. *Surg Endosc.*, 20(11):1772-3.
3. **Safioleas M, Chatziconstantinou C, Felekouras E et al. (2007):** Clinical considerations and therapeutic strategy for sigmoid volvulus in the elderly: a study of 33 cases. *World J Gastroenterol.*, 13(6):921-4.
4. **Mumtaz K, Safir U, Mian A et al. (2007):** Primary anastomosis in the management of acute sigmoid volvulus without colonic lavage. *Journal of Postgraduate Medical Institute.*, 21(04):305-8.
5. **Baker D, Wardrop P, Burrell H et al. (1994):** The management of acute sigmoid volvulus in Nottingham. *J R Coll Surg Edinb.*, 39(5):304-6.
6. **Naaeder S, Archampong E (1995):** One-stage resection of acute sigmoid volvulus. *Br J Surg.*, 82(12):1635-6.
7. **Santos J, Batista J, Sirimarco M et al. (1994):** Prospective randomized trial of mechanical bowel preparation in patients undergoing elective colorectal surgery. *Br J Surg.*, 81(11):1673-6.
8. **Irving A, Scrimgeour D (1987):** Mechanical bowel preparation for colonic resection and anastomosis. *Br J Surg.*, 74(7):580-1.
9. **van Geldere D, Fa-Si-Oen P, Noach L et al. (2002):** Complications after colorectal surgery without mechanical bowel preparation. *J Am Coll Surg.*, 194(1):40-7.
10. **Utpal D, Shibajyoti G (2003):** Single stage primary anastomosis without colonic lavage for left-sided colonic obstruction due to acute sigmoid volvulus: a prospective study of one hundred and ninety-seven cases. *ANZ J Surg.*, 73(6):390-2.
11. **Halabi W, Jafari M, Kang C et al. (2014):** Colonic volvulus in the United States: trends, outcomes, and predictors of mortality. *Ann Surg.*, 259(2):293-301.
12. **Swenson B, Kwaan M, Burkart N et al. (2012):** Colonic volvulus: presentation and management in metropolitan Minnesota, United States. *Dis Colon Rectum.*, 55(4):444-9.
13. **Raveenthiran V, Madiba T, Atamanalp S et al. (2010):** Volvulus of the sigmoid colon. *Colorectal Dis.*, 12(7): 1-17.
14. **Heis H, Bani-Hani K, Rabadi D et al. (2008):** Sigmoid volvulus in the Middle East. *World J Surg.*, 32(3):459-64.
15. **Mangiante E, Croce M, Fabian T et al. (1989):** Sigmoid volvulus. A four-decade experience. *Am Surg.*, 55(1):41-4.
16. **Dolejs S, Guzman M, Fajardo A et al. (2018):** Contemporary Management of Sigmoid Volvulus. *J Gastrointestinal Surg.*, 22(8):1404-11.
17. **Oren D, Atamanalp S, Aydinli B et al. (2007):** An algorithm for the management of sigmoid colon volvulus and the safety of primary resection: experience with 827 cases. *Dis Colon Rectum.*, 50(4):489-97.
18. **Anderson J, Lee D (1981):** The management of acute sigmoid volvulus. *The British Journal of Surgery.*, 68(2):117-20.
19. **Atamanalp S (2013):** Treatment of sigmoid volvulus: a single-center experience of 952 patients over 46.5 years. *Tech Coloproctol.*, 17(5):561-9.
20. **Dudley H, Racliffe A, McGeehan D (1980):** Intraoperative irrigation of the colon to permit primary anastomosis. *Br J Surg.*, 67(2):80-1.
21. **Nyam D, Seow-Choen F, Leong A et al. (1996):** Colonic decompression without on-table irrigation for obstructing left-sided colorectal tumors. *Br J Surg.*, 83(6):786-7.
22. **Raveenthiran V (2004):** Restorative resection of unprepared left-colon in gangrenous vs. viable sigmoid volvulus. *Int J Colorectal Dis.*, 19(3):258-63.
23. **Hsu T (1998):** One-stage resection and anastomosis for acute obstruction of the left colon. *Dis Colon Rectum.*, 41:28-32.
24. **Sule A, Iya D, Obekpa P et al. (1999):** One-stage procedure in the management of acute sigmoid volvulus. *J R Coll Surg Edinb.*, 44(3):164-6.