

## Comparative Study between Laparoscopic versus Open Orchiopexy in Peeping and High Inguinal Undescended Testis: Review article

Mostafa Abdel Razek Ahmed<sup>1</sup>, Ahmad Abolyosr Mohammed<sup>1</sup>, Abdelrahman Mahmoud Mohamed Mahmoud<sup>1\*</sup>, Omar Mohammed Elsoghier<sup>1</sup>,

<sup>1</sup>Urology Department, Faculty of Medicine, South Valley University, Egypt

\*Corresponding author: Abdelrahman Mahmoud Mohamed Mahmoud

E mail: [abdo.mahmoud11111@gmail.com](mailto:abdo.mahmoud11111@gmail.com)

### ABSTRACT

**Background:** Traditional open orchiopexy remains the gold standard for palpable undescended testicles. Several authors recently noted successful outcomes in therapy of palpable cryptorchidism using laparoscopic approach.

**Objectives:** This review article aimed to compare outcomes of laparoscopic versus open orchiopexy in peeping and high inguinal undescended testis.

**Conclusion:** Both laparoscopic and open orchiopexy were safe & effective in cure of peeping and high inguinal undescended testis. However, laparoscopic orchiopexy was superior to open orchiopexy as it was associated with better outcomes as regards final testicular position at the bottom of the scrotum or low level below the mid-scrotal point and shorter hospital stay. It was also associated with non-significantly higher success rate. Further comparative research with greater sample size & longer follow-up are required to approve results & to identify risk factors of adverse events.

**Keywords:** Undescended exams, Palpable cryptorchidism, Laparoscopy, Testicular atrophy, Laparoscopic orchiopexy, Orchiopexy.

### INTRODUCTION

Cryptorchidism, & an undescended testis, is congenital malformation in children. Throughout foetal development, testicle usually fails to change from abdomen through the inguinal canal to scrotum. In clinical practice, cryptorchidism is classified as inguinal cryptorchidism or intra-abdominal cryptorchidism based on position of testis. However, more than eighty percent of cryptorchidism can contact testis in groyne area <sup>(1)</sup>.

A form of cryptorchidism testis known as a peeping testis emerges from an internal ring and is movable between the inguinal area and abdominal cavity; as a consequence, it is not always felt or visible in the inguinal area. Peeping testis is both diagnostics and therapy challenges. Most common approach between paediatric urologists & surgeons is open surgical cure of such testes. Because of difficulty of surgical mobilisation of some peeping testes, in addition to significant problems like testicular retraction/atrophy, current research hypothesized that laparoscopic orchiopexy is a promising alternative procedure for such high inguinal testes <sup>(2)</sup>.

Aim of research was to compare outcome of laparoscopic versus open orchiopexy in peeping and high inguinal undescended testis.

### Testis Anatomy

Adult testis is made up of two parts: gamete portion that provides sperm & endocrine portion that secretes testosterone. Spermatogenesis takes place in gamete portion, within seminiferous tubules, in which Sertoli cells generate and preserve spermatozoa. Leydig cells in the interstitium among seminiferous tubules produce androgen (testosterone) <sup>(3)</sup>.

They migrate to gonadal ridge after primitive gonad's somatic cells have created. It is critical that

these committed germ cells exist outside of fetus's somatic differences. In the fifth week of human embryo development, the gonadal blastema forms and, based on the sex-determining gene SRY, either develops into a testis or an ovary. Prior to this point, both men & women gonads are composed of 3 different cell types: entry germ cells, supportive epithelial cells that arises into either ovarian granulosa cells or testicular Sertoli cells, stromal cells produced by gonadal ridge mesenchyme. Sertoli cells of men equate to granulosa cells of women <sup>(4)</sup>.

### Cryptorchidism

Mal-descendus testis is the medical term for when one or both testes do not descend into the scrotum. Instead, testis is discovered along normal path of testicular descent, & it can be intra-abdominal, inguinal, suprascrotal, or high scrotal. Prevalence of preterm birth & low birth weight in boys ranges from 1.1 to 45.3% at birth <sup>(5)</sup>.

Cryptorchidism is connected to higher frequency of testicular germ cell tumours (TGCT) in the future. When compared to general population, risk of TGCT is enhanced two-five-fold. The testicular dysgenesis disorder theory, which contends that cryptorchidism and TGCT have a same fetal origin and is supported by these findings. <sup>(6)</sup>

Hypogonadism is traditionally defined as testicular dysfunction caused by androgen deficiency. But, **Rey et al.** <sup>(7)</sup> suggested comprehensive definition that would contain age-related testicular dysfunction, such as weakened Sertoli and Leydig cell functioning, as well as spermatogenesis disorder <sup>(8)</sup>.

Normal testes include retractile testes & testes in scrotal position. When a testis is placed outside of the typical line of testicular descent, it is known as an ectopic testis. In this case, testis can be found in perineal, femoral, or

pubopenile areas, as well as in crossed scrotal position<sup>(9)</sup>.

### **Testicular descent physiology**

The mechanism of testicular descent in men fetuses is complicated. Testicular descent must be normal for the HPT axis. Androgen synthesis and action must also be normal.<sup>(10)</sup>

There is proof that the paracrine actions of AMH have an impact on this mechanism. Sertoli cells proliferate rapidly during 2nd trimester of pregnancy, as do germ cells & Leydig cells, increasing volume of testis<sup>(11)</sup>.

It is common for boys born with cryptorchidism to experience spontaneous testicular descent before the age of six months, or even before the age of three months, i.e., throughout mini-puberty. Finnish-Danish birth cohort research found that incidence of cryptorchidism at birth was 2.4% in Finland & nine% in Denmark, with prevalence at three months and six months being one & 1.9% respectively. After of years old, spontaneous descent is uncommon<sup>(12)</sup>.

### **Etiologies of Cryptorchidism**

Genetic, hormonal, anatomical, & environmental factors all play role in testicular descent. Cryptorchidism can be caused by diseases or conditions that affect any of associated factors. Numerous genetic disorders & syndromes are linked to cryptorchidism, which is known as syndromic cryptorchidism<sup>(13)</sup>.

### **Reduced abdomen pressure or anatomical abnormality of the abdomen wall**

Unrelated to androgen insufficiency, cryptorchidism is seen in disorders & abnormalities such prune belly disorder, posterior urethral valve issues, & abdominal wall anomalies. This indicates that cryptorchidism is caused by mechanical flaw<sup>(14)</sup>. These factors are thought to interfere with foetal testicular development & result in testicular dysgenesis disorder. As regards the TDS theory, several male reproductive illnesses and symptoms, including cryptorchidism, hypospadias, poor sperm quality, TGCT, low serum testosterone concentrations, and short anogenital distances, may have the same fetus as their source<sup>(15)</sup>. Through the initial year of life, the number of germ cells per tubule is normal. Nevertheless, it begins to decline, especially

between one and three years. Sertoli cell & germ cell numbers are minor in boys who had orchiopexy at years old of three compared to those who had it at years old of nine months<sup>(16)</sup>.

Histological abnormalities are also seen in descending testes of boys with unilateral cryptorchidism. These include fewer Ad spermatogonia & delay in development of primary spermatocytes<sup>(5)</sup>.

### **Orchiopexy**

Undescended testis is surgical condition & all paediatric surgeons & urologists must know procedure for surgery. This simple procedure can occasionally present as hard surgical challenge<sup>(17)</sup>.

### **Inguinal orchiopexy**

Low transverse inguinal crease incisions following Langer lines, as well as layering, are required. Once the external ring has been located, the external oblique fascia is cut to reveal the canal, being careful not to damage the ilioinguinal nerve. Spermatic cord is separated, & testis is dissected distally from its connection to gubernacular remnant. If long-looped vas deferens is present, care should be taken to prevent injury. Hernial sac is located & opened overlying testis, with incision extending proximally along length of cord. Sac is ligated at deep ring level, & cord structures are gently isolated from sac after it has been ligated<sup>(9)</sup>.

### **Cord lengthening procedures**

Goal of orchidopexy is to bring testis to mid scrotum with minimal or no damage to vas & vessels & with little or no tension on pedicle. Even so, this is frequently linked to increased tension in cord & vessels, which increases risk of atrophy & retraction<sup>(17)</sup>.

### **Division of the lateral fibrous bands and mobilization of the retroperitoneum**

When extension is necessary for mobilized cord structures that are just long enough to reach mid-scrotal level, the internal ring of the deep ring may be opened by dissecting the fibrous bands that connect the cord to the abdominal wall. This procedure is similar to that used in inguinal orchiopexy (Figures 1 & 2)<sup>(18)</sup>.

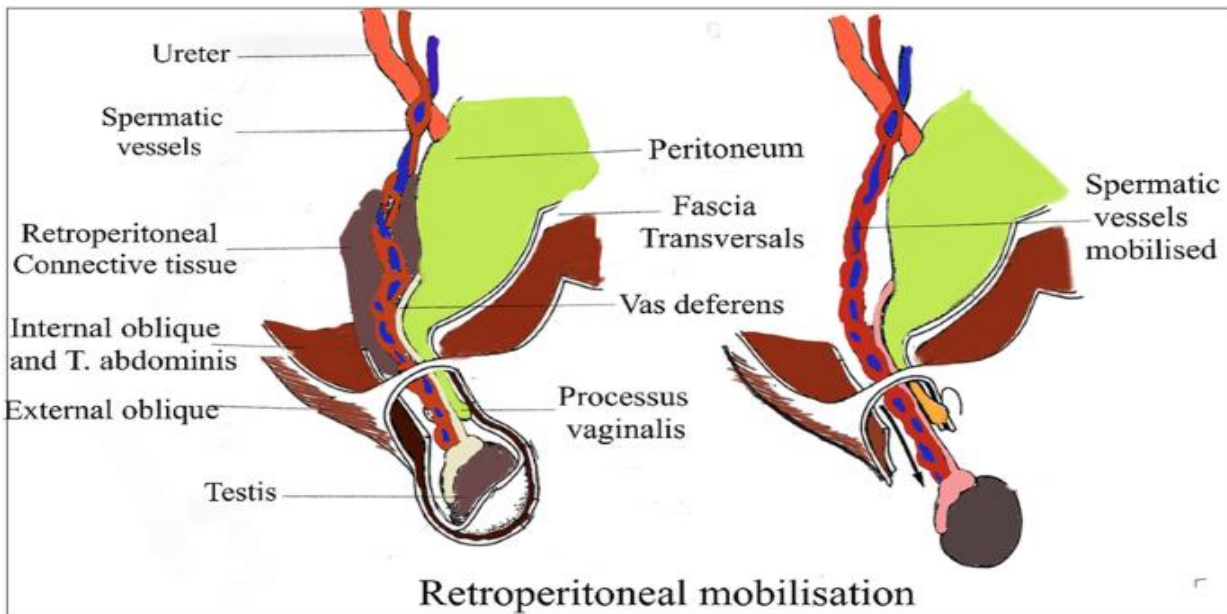


Fig. 1: Retroperitoneal mobilization <sup>(18)</sup>

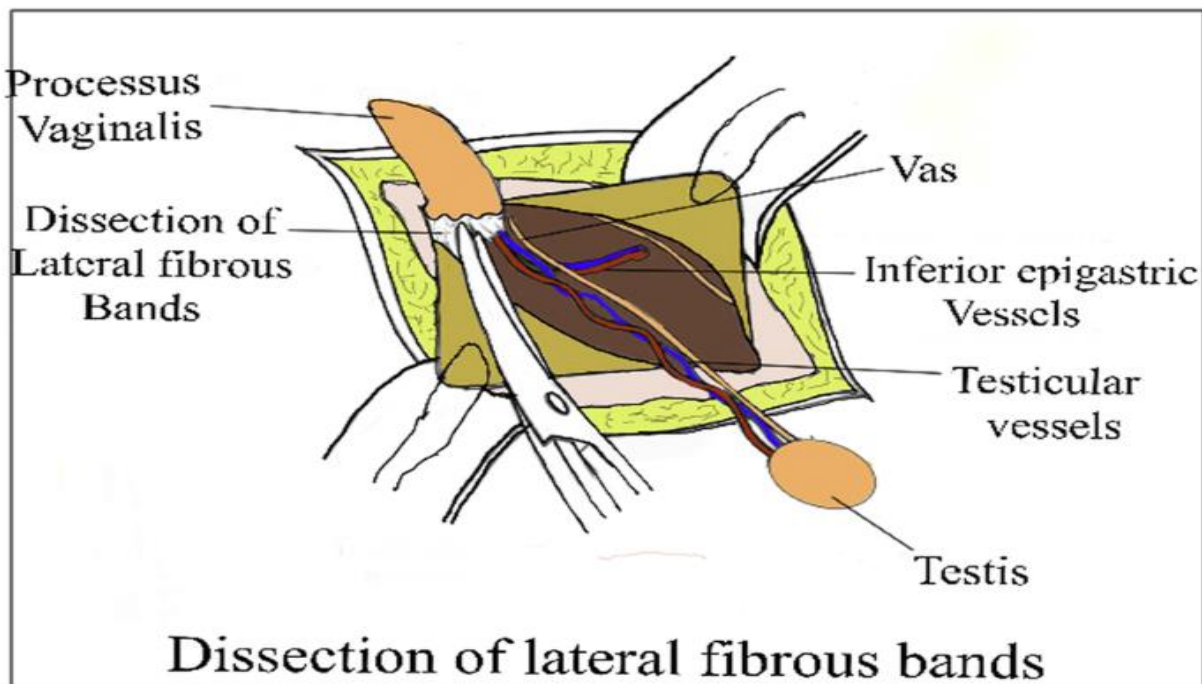


Fig. 2: Segmentation of lateral bands <sup>(18)</sup>

**Laparoscopic orchiopexy**

Laparoscopic cord lengthening is occasionally used to treat large inguinal testes. Standard laparoscopic way will be used, with five-mm umbilical port serving like camera port & 2 five-mm ports in mid-clavicular line below the first port's position when it is put in the lumbar area. Testis can be seen peeking out from internal ring <sup>(19)</sup>.

Testis is then mobilized downwards with forceps medial to inferior epigastric vessels to sub-dartos pouch then fixed, as previously explained. Several writers describe inserting an eight- or ten-mm trocar through outer ring from scrotum. Laparoscopic clamp

gone through this can grasp gubernaculum & deliver testis with gentle twisting motion <sup>(20)</sup>.

**Ante-grade laparoscopic testicular vessels dissection**

The standard laparoscopic method with the recommended port placement must be used. Ante-grade dissection of the inguinal canal, including dissection of the testicular arteries and, if necessary, proximal mobilization of the gubernaculum, will occur after this. This procedure provides an additional safeguard to guarantee the maintenance of the vasculature and veins, avoiding testis vascular deterioration <sup>(21)</sup>.

### Staged orchidopexy

When either vas & gonadal vessels are too short to enter scrotum after full movement with lengthening processes such as Prentiss maneuver, 2 orchidopexy may be regarded. Testis can be anchored in most distal position possible during first surgery, & 2nd process can be performed at or after six months. In this case, staged orchidopexy may be preferable to Stephen-Fowlers orchidopexy because initial lengthening maneuvers, such as retroperitoneal mobilization, may cause separation of several of collateral vessels on which procedure's success is dependent. Even, existence of adhesions around testis & internal ring, as with any 2nd-stage procedure, presents challenge to surgeons & poses risk of damage to gonadal vessels & vasculature <sup>(22)</sup>.

### Open vs laparoscopic Orchiopexy (LO) in peeping and high Inguinal undescended testis

Open inguinal orchiopexy is the generally acknowledged method for treating palpable undescended testes, which make up more than 80% of all undescended testes. For nonpalpable testes, diagnostic laparoscopy is usually followed by 1 or 2 stages of laparoscopic orchiopexy or inguinal exploration <sup>(23)</sup>.

Over the last ten years, a number of writers have provided results from laparoscopy in instances with palpable undescended testes. Many writers have lately argued that laparoscopic orchiopexy is superior to open orchiopexy and ought to be advised for these testes. Main benefits of LO that it has the possibility of large retroperitoneal dissection and the ability to reroute the testis through smaller medial to epigastric vessel pathway (Prentiss maneuver), resulting in more favourable scrotal position <sup>(24)</sup>.

The study of **Mentessidou et al.** <sup>(25)</sup> Overall success & complication rates with LO in treating of palpable undescended testes were 99.7% & 0.7%, respectively. Regular large dissection, Prentiss maneuver, & trans-scrotal fixation had no effect on rates of success in LO of palpable undescended testes. The primary benefit of laparoscopy is that it allows for extensive spermatic vessel dissection in the retroperitoneum all the way to the inferior renal pole. This is particularly useful for intrabdominal testes, where significant mobilization is required for orchiopexy. Laparoscopy is thus preferred for the care of nonpalpable testes, despite the fact that certain investigations, such as meta-analyses, do not clearly demonstrate a benefit-cost ratio favoring laparoscopic orchiopexy over open techniques for nonpalpable testes <sup>(26)</sup>.

Inguinal testes, unlike intrabdominal testes, often do not need significant retroperitoneal dissection unless they are very large, as in peeping. Only 1/3 of cases in research on LO of palpable intracanalicular testes

reportedly required retroperitoneal dissection. It was not specified whether this 3rd of cases had large canalicular & peeping testes, laparoscopy was needless in other 2/3 of cases. In concert with above, **Mentessidou et al.** <sup>(25)</sup> reported that independent of height, there was no variation in the rates of success with the usual utilization of great retroperitoneal dissection, demonstrating that there was no proof of a clear benefit of LO in palpable testes. In comparative research by **Yang et al.** <sup>(24)</sup>, they reported that LO was associated with significantly higher rate of more favourable scrotal position leading authors to conclude that LO must be desired over open orchiopexy (OO). Even yet, the practical importance of the discovery is in doubt since there is no proof that a location near the bottom of the scrotum leads to longer-lasting benefits than a more tolerable upper scrotal position. **Elderwy et al.** <sup>(27)</sup> discovered that less incidences of redoing the procedure meant that laparoscopic orchiopexy had a rate of success that was equivalent to open orchiopexy. **He et al.** <sup>(28)</sup> used laparoscopy to treat 103 inguinal canalicular palpable undescended testes. There was only one problem, & all of testes were of adequate size & intrascrotal position.

### CONCLUSION

Both Laparoscopic and Open Orchiopexy were safe & effective in therapy of peeping and high inguinal undescended testis. However, Laparoscopic Orchiopexy was superior to Open Orchiopexy as it was associated with better outcomes as regards final testicular position at the bottom of the scrotum or low level below the mid-scrotal point and shorter hospital stay. It was also associated with non-significantly higher success rate. Further comparative researches with greater sample size & longer follow-up are required to approve results & to identify risk factors of adverse events.

### DECLARATIONS

- **Consent for Publication:** I verify that all authors have agreed to submit manuscript.
- **Availability of data & material:** Available
- **Competing interests:** None
- **Funding:** No fund
- **Conflicts of Interest:** no conflicts of interest.

### REFERENCES

1. **Kim J, Chua M (2018):** A critical review of recent clinical practice guidelines on management of cryptorchidism. *J Pediatr Surg.*, 53 (10): 2041–7.
2. **Penson D, Krishnaswami S, Jules A et al. (2013):** Effectiveness of hormonal and surgical therapies for cryptorchidism: a systematic review. *Pediatrics*, 131: e1897e907.
3. **Silber S (2018):** Testis Development, Embryology, and Anatomy. In: *Fundamentals of Male Infertility*. Springer, Cham. [https://doi.org/10.1007/978-3-319-76523-5\\_1](https://doi.org/10.1007/978-3-319-76523-5_1)

4. **Silber S (2015):** Unifying theory of adult resting follicle recruitment and fetal oocyte arrest. *Reprod BioMed Online*, 31: 472–475
5. **Rodprasert W, Virtanen H, Mäkelä J et al. (2020):** Hypogonadism and Cryptorchidism. *Front Endocrinol (Lausanne)*, 10: 906.
6. **Skakkebaek N, Rajpert-De E (2016):** Male reproductive disorders and fertility trends: influences of environment and genetic susceptibility. *Physiol Rev.*, 96: 55–97.
7. **Rey R, Grinspon R, Gottlieb S et al. (2013):** Male hypogonadism: an extended classification based on a developmental, endocrine physiology-based approach. *Andrology*, 1: 3–16. 10.1111/j.2047-2927.2012.00008.x
8. **Papadimitriou D, Chrysis D, Nyktari G et al. (2019):** Replacement of male mini-puberty. *J Endocr Soc.*, 3: 1275–82.
9. **Radmayr C, Dogan H, Hoebeke P et al. (2016):** Management of undescended testes: European Association of Urology/European Society for Paediatric Urology Guidelines. *J Pediatr Urol.*, 12 (6): 335–43.
10. **Mäkelä J, Koskenniemi J, Virtanen H et al. (2019):** Testis development. *Endocr Rev.*, 40: 857–905. 10.1210/er.2018-00140
11. **Arboleda V, Quigley C, Vilain E (2016):** Genetic basis of gonadal and genital development. In: Jameson JL, De Groot LJ, de Kretser DM, Giudice LC, Grossman AB, Melmed S, et al., editors. *Endocrinology: Adult & Pediatrics*. 7th ed Philadelphia, PA: Elsevier Saunders, Pp: 2051–85.
12. **Kelsey T, Miles A, Mitchell R et al. (2016):** A normative model of serum inhibin B in young males. *PLoS ONE*, 11: e0153843. 10.1371/journal.pone.0153843
13. **Cunha S, Andrade J, de Angelis C et al. (2018):** Early development of a gonadal tumor in a patient with mixed gonadal dysgenesis. *Arch Endocrinol Metab.*, 62: 644–7.
14. **Urh K, Kolenc Ž, Hrovat M et al. (2018):** Molecular mechanisms of syndromic cryptorchidism: data synthesis of 50 studies and visualization of gene-disease network. *Front Endocrinol.*, 9: 1–11. 10.3389/fendo.2018.00425
15. **Gurney J, McGlynn K, Stanley J et al. (2017):** Risk factors for cryptorchidism. *Nat Rev Urol.*, 14: 534–48. 10.1038/nrurol.2017.90
16. **Yue S, Hutson J, Li R (2015):** Gene expression during gonocyte transformation into spermatogonial stem cells is not androgen dependent. *J Pediatr Surg.*, 50: 2090–3.
17. **Shreyas K, Rathod K, Sinha A (2021):** Management of high inguinal undescended testis: a review of literature. *Ann Pediatr Surg.*, 17: 42.
18. **Jones P, Bagley F (1979):** An abdominal extraperitoneal approach for the difficult orchidopexy. *Br J Surg.*, 66 (1): 14–8.
19. **Manoj S (2017):** Modified dartos pouch technique by transfixing the testis to a nylon button for undescended testes with short spermatic cord. *GJRA.*, 6 (5): 15-16
20. **Elderwy A, Kurkar A, Abdel-Kader M et al. (2014):** Laparoscopic versus open orchidopexy in the management of peeping testis: A multi-institutional prospective randomized study. *J. Pediatr. Urol.*, 10: 605–609.
21. **Shehata S, Effat A, Shalaby M (2018):** Ante-grade laparoscopic testicular vessels dissection in proximal inguinal undescended testis: a novel approach. *JSM Pediatr Surg.*, 2 (2): 1017.
22. **Vikraman J, Hutson J, Li R et al. (2016):** The undescended testis: clinical management and scientific advances. *Semin Pediatr Surg.*, 25 (4): 241–8.
23. **European Society for Pediatric Urology (ESPU) (2020):** EAU guidelines on pediatric urology. European society association of urology, 2018, <https://uroweb.org/wp-content/uploads/EAU-Guidelines-on-Paediatric-Urology-2018-large-text>.
24. **You J, Li G, Chen H et al. (2020):** Laparoscopic orchidopexy of palpable undescended testes\_experience of a single tertiary institution with over 773 cases. *BMC Pediatr.*, 20: 124.
25. **Mentessidou A, Gargano T, Lima M et al. (2021):** Laparoscopic versus open orchidopexy for palpable undescended testes: Systematic review and meta-analysis. *Journal of Pediatric Surgery*, 57(4): 770-775
26. **Yang, Z (2020):** "Laparoscopic orchidopexy versus open orchidopexy for palpable undescended testis in children: a prospective comparison study." *Journal of Laparoendoscopic & Advanced Surgical Techniques*, 30 (4): 453-457
27. **Elderwy A, Kurkar A, Abdel-Kader M et al. (2014):** Laparoscopic versus open orchidopexy in the management of peeping testis: a multi-institutional prospective randomized study. *J Pediatr Urol.*, 10 (4): 605-9.
28. **He D, Lin T, Wei G et al. (2008):** Laparoscopic orchidopexy for treating inguinal canalicular palpable undescended testis. *J Endourol.*, 22: 1745–1749.