



Hydroxytyrosol: A Prospective Preventive Option for Diabetic Nephropathy in Rats

Shereen M. Samir¹, Heba A. Sheta², Nadia Bakry³

Department of Physiology¹, Pathology², Faculty of Medicine, Faculty of Science³, Mansoura University

Received: 6 July. 2018
Accepted: 8 Nov 2018
Available online: 1 Mar 2019

Abstract

Diabetic nephropathy (DN) is one of most prevalent diabetic complication. It remains unclear whether the anti-inflammatory Hydroxytyrosol (HT) has beneficial effects on biogenesis of diabetic renal changes. Therefore, we aimed to find out the relationship between inflammation, apoptosis, oxidative stress and the progression of DN. Also, try to assess the possible effects of HT on diabetic renal tissue. Materials and Methods: Rats were divided into: non-diabetic rats (group I) and rats with induced type II diabetes that were subdivided into: group II non-treated DM, group III treated with HT, group IV treated with glyclazide and group V treated with combined treatment. Treatments were supplied for eight weeks. Results: Administration of HT alone or with GLY significantly lowered blood glucose levels and ameliorated kidney hypertrophy index together with improving renal dysfunction parameters including creatinine in serum and urine, blood urea nitrogen, serum and urinary albumin, together with the tissue oxidative markers and inflammatory cytokines activities compared to diabetic group. These effects of HT were also reflected on histologic evaluation and Nrf2- Keap1 system expression. Conclusion: This study discovers the renoprotective effect of HT in diabetic rats. Hence, this study recommended an addition of antioxidants like HT to the management of diabetes.

Keywords

- Diabetic
- nephropathy
- Hydroxytyrosol
- oxidative stress
- Nrf2, Keap1

INTRODUCTION

Diabetes mellitus (DM), most commonly, Type-2 is considered one of the most prevalent chronic disorders in the developed countries that derived from insulin resistance in peripheral tissues. If left untreated, diabetes can result in serious long-term complications including cardiovascular diseases, nephropathy, retinopathy, neuropathy, and chronic wounds including diabetic foot ulcers [1]. Diabetic nephropathy (DN) is the second prevalent diabetic complication after cardiovascular disorders and is considered a possible reason for end-stage renal disease [2]. Clinically, it is presented by some sort of albuminuria while, histologically featured by the Kimmelstiel-Wilson lesions. These lesions are characterized by many features that are indicators for renal function loss, they include basement membrane thickening, mesangial matrix expansion and nodular aggregation together with sclerosis in glomeruli [3]. The pathogenesis of DN could be multifactorial and several mediators have been implicated in its underlying mechanism. Several factors play a role in the pathogenesis of diabetic glomerular diseases, as insulin-like growth factor-I, angiotensin II, platelet-derived growth factor, transforming growth factor- β 1 (TGF- β 1) and advanced glycation end products [4]. Reactive oxygen species are one of these factors that thought to have a significant role in diabetic nephropathy development [5]. Exposure to hyperglycemic environment (1-13 days) could inhibit cell proliferation and induce cellular apoptosis in the epithelial cells of proximal renal tubules [6]. Also, Habib [7] explained proximal tubular apoptosis induced by hyperglycemia

through activation of caspase-3 mediated by oxidative stress.

Oxidative stress has been identified to be involved in diabetic vascular complications pathogenesis, including nephropathy [8]. In diabetes, the mitochondria are considered the major site producing highly reactive oxygen species (ROS) [9], and they can also be damaged by ROS. A redox-sensitive transcription factor which is called nuclear factor (erythroid-derived 2)-like 2 (Nrf2), is a factor belonging to the cap "n" collar (CNC) family which tightly interacts with Kelch-like ECH-associated protein 1 (Keap1) [10]. Exposure to ROS, or reactive nitrogen species, the cysteine residues in Keap1 are modified, that in turn, prevent the proteasome-mediated degradation of Nrf2 [11]. Accordingly, stabilization of Nrf2, leads to its nuclear accumulation then induction of genes encoding multiple antioxidant proteins, all of which can counteract inflammatory and oxidative damage by enhancing the removal of cytotoxic electrophiles or ROS in cells [12].

Several trials to prevent the development of diabetic complications including exercise, diet, insulin and oral antidiabetic drugs have been investigated. Oral antidiabetic supplementations such as gliclazide (second generation sulphonylurea), is commonly used as a treatment of type 2 diabetes and Onozato et al., [13] has been described that the azabicyclo-octyl ring of glyclazide may be the reason of its antioxidant properties independent of glycemic control either in vitro or in vivo. Therefore, in the recent years new therapeutic strategies such as plants have been utilized to reduce the hyperglycemia in diabetic

rats [14]. Extravirgin olive oil consists of a series of phenolic components that possess important antioxidant activities [15]. Hydroxytyrosol (HT) is a simple phenol, formed during olive oil storage from hydrolyzing the secoiridoid aglycones of ligstroside and oleuropein [16]. Recent researches suggested that HT may exert an antioxidant role in scavenging ROS [17]. The Mediterranean diet, rich in virgin olive oil, had an improving effect on inflammation, endothelial function and oxidative stress [15]. A study in recent years have shown that HT improved the oxidative stress in hepatoma cells and spleen [17].

Therefore, the study hypotheses were to assess the relationship of inflammation, apoptosis and oxidative stress on progression of diabetic nephropathy and to investigate the possible protective effect of Hydroxytyrosol (HT) on renal tissue in streptozotocin-nicotinamide induced type II diabetic rats.

Materials and Methods:

Male Sprague-Dawley rats (6-8 weeks old, 200-250 g) were obtained from and housed in the Mansoura experimental research center (MERC) in faculty of medicine, Mansoura University for these experiments. Rats were kept in a room with controlled environment (temperature around $25 \pm 1^\circ\text{C}$ and 12 h period of light- dark) and free supplementation with water and normal chow. All experiments and animal care were conformed to the guidelines of Care and Use of Laboratory Animals (Institute for Laboratory Animal Research, National Research Council, Washington, DC, National Academy Press, no. 85-23, revised 1996). This protocol was approved by our Local

Committee of Laboratory Animal Care and Use (code No. R.18.03.73. R1).

Chemicals

Nicotinamide, Streptozotocin (STZ), Hydroxytyrosol and glyclazide were purchased from Sigma-Aldrich Chemical Co., St Louis, MO, USA.

Induction of type II diabetes in rats

STZ was freshly prepared in citrate buffer (0.1 M with pH 4.5) while nicotinamide was dissolved in normal physiological saline. Overnight fasted rats were injected with a single dose of STZ (65 mg/kg) intraperitoneally, after I.P. injection of nicotinamide (110 mg/kg) by 15 min [18]. Nicotinamide produces type II diabetes through preservation up to 40% of the pancreatic β -cells from STZ cytotoxicity. On the third day of injection, hyperglycemia was confirmed by measuring the level of fasting blood glucose from rat-tails using the One Touch Blood Glucose Monitoring System (Life Scan, Milpitas, CA). Rats with blood glucose level ≥ 300 mg/dl were incorporated in the experiments as diabetic rats [14]. Moreover, those with homeostatic model assessment of insulin resistance (HOMA-IR) ≥ 2.29 , considered having severe insulin resistance (HOMA-IR = fasting glucose concentration \times the fasting insulin concentration /405) [19] and were selected for this study. Control rats were received citrate buffer as vehicle treatment.

Experimental design

In the present experimental study, 50 male rats were used and randomly divided into two main divisions, group I (control, C) with normal non-diabetic rats, the other division includes rats with

induced diabetes. (10 normal rats, 40 diabetic rats).

The diabetic rats were further subdivided into four groups: group II (DM) vehicle treated rats, group III (DM-HT) treated with hydroxytyrosol (10 mg/kg/day) [20], group IV (DM-GLY) treated with glyclazide (5 mg/kg B.W.) [21] and group V (DM-HT-GLY) treated with combined Hydroxytyrosol and glyclazide in the same previous doses. Both HT and GLY were given to rats by oral gavage for eight weeks. Measurement of each animal body weight was done at the start and end of the experiment. On the completion of 8 weeks, blood was withdrawn from fasted rats via retro orbital plexus. Blood samples were centrifuged at 1300g for separation of serum and stored at -20 °C until assay. Anesthesia of rats were performed using ketamine (50 mg/kg), decapitation was done and both kidneys in each were dissected out, washed with isotonic saline and weighed. After that, left kidney of each rat was cut into two halves. One half was embedded in paraffin for examining it histologically and immunohistochemically for caspase 3. Other half was minced and prepared with Tris-HCl buffer (0.025 M, pH 7.5), then after centrifugation for 10 min at 2000 rpm, the clear supernatant was kept and used for biochemical assays. Right kidneys were quickly kept at -80°C in liquid nitrogen.

Biological analysis

The biological parameters include assessment of blood glycosylated hemoglobin (HbA1c) according to Nayak & Pattabira-man methodology [22], evaluation of plasma glucose levels using the glucose oxidase-catalyzed reaction (chemistry analyzer; Auto Analyzer Quik-Lab, Ames, Spain).

Measurement of serum insulin was done using the method of sandwich enzyme-linked immunosorbent assay (ELISA) (Merckodia, Uppsala, Sweden). Also, determination of serum creatinine, albumin and blood urea nitrogen (BUN) levels were done. Pooled 24 h urine was evaluated for creatinine and albumin values. The estimation of serum and urine parameters was carried out using biochemical kits (ACCUREX, Biomedical Pvt. Ltd).

Antioxidant Potential Measurement

To investigate the total antioxidant capacity, Ferric reducing antioxidant potential (FRAP) assay was used. This procedure depends on the affinity of biological antioxidants to reduce the ferric tripyridyltriazine (Fe III-TPTZ) to a blue colored Fe II-TPTZ. This change the absorbance of the sample in reference to the known standard (FeSO₄ 7H₂O) at 600 nm [23].

Lipid Peroxidation

As following Yagi's methods [24], the measurement of the renal tissue content of malondialdehyde (MDA) was detected spectrofluorometrically.

Assay of Oxidized Protein by Measuring Carbonyl Protein Content

As described by Arellano-Buendía, et al. [25], the carbonyl content in the proteins was measured using the molar absorption coefficient of 22,000 M⁻¹.cm⁻¹ for 2,4-dinitrophenylhydrazine (DNPH) derivatives. Blank used was guanidine solution. Expression of results were in the form of nmol carbonyl groups/mg protein.

Histological examination

The renal tissues were immediately fixed in 10% phosphate-buffered formalin at room temperature for 24 hours, dehydration was occurred through graded alcohol series, then embedded in paraffin, cut into 4 μm sections and stained with hematoxylin and eosin (H&E). The slides were examined by light microscopy under 400x magnification for microscopic alterations of pathological significance.

Glomerular damage was assessed by evaluating the presence of glomerular basement membrane thickening, mesangial expansion, nodular lesions and glomerulosclerosis. Scoring of mesangial expansion was graded semi quantitatively into mild, moderate and severe [26]. In addition, evaluation of the tubules, interstitium and blood vessels was done.

Immuno-histochemical staining for caspase 3

Immunohistochemical staining of the formalin-fixed, paraffin-embedded tissue sections against rabbit polyclonal antibody against caspase 3 overnight (4- μm thick) was performed following the technique of Hsu et al. [27]. Antibody was received in a concentrated form (Diagnostic BioSystems) and then diluted in PBS. Caspase 3 antigen detection was by a two-step detection system.

Computer Assisted digital image analysis (Digital morphometric study)

Slides were photographed using an Olympus microscope with digital camera of 1/2 X photo

adaptor, with 20 X objective. The result images were analyzed by Intel[®] Core I3[®] based computer using Video Test[®] Morphology[®] software (Russia) with a specific built-in routine for area measurement, stain density and descriptive geometrical parameters analysis. 5 slides from each case were prepared, 5 random fields from each slide were analyzed. Percentage area of caspase staining was calculated

Real-time qPCR analysis for Nrf2, Keap1

Extraction of total RNA from the kidney tissues of all rats was done by TRIzol[®] reagent (Invitrogen, Carlsbad, CA), following the manufacturer's protocol and purified by Qiagen RNeasy Mini Kit (Qiagen, Venlo, The Netherlands). Single strand cDNAs was formed by reverse transcription of purified RNA, then was successively analyzed using the SYBR GREEN PCR master mix (Applied Biosystems, Foster City, CA) for real-time qPCR. The protocol of amplification comprised of 1 cycle for 3 min at 95 °C followed by 40 cycles at 95 °C, 58 °C, and then 72 °C for 30 s for each cycle. Primer Express 2.0 software designed the primer sequences using Applied Biosystems instructions for optimal primer design as in table (1). Standard curve was prepared by diluting the reference sample and was included in each real-time run to correct the product amplification variations. Standard curve values were used to obtain relative copy numbers that were normalized to those obtained from *Gapdh*, the internal control. The change in expression was then assessed by $2^{-\Delta\Delta\text{CT}}$ method.

Statistical analysis

Expression of the results were shown as mean \pm SEM of the rats in each group. The results were statistically analyzed using One-way

ANOVA followed by post-hoc test to evaluate the significance between the different investigated groups using SPSS version 16 (Chicago, IL, USA). Values with $P < 0.05$ were statistically considered significant.

Table 1. List of primer sequences for real-time qPCR.

Accession no.	Gene description	Gene symbol	Forward	Reverse	Product size
NM_031789.1	Nuclear factor (erythroid-derived 2)-like 2	<i>Nrf2</i>	gagacggccatgactgat	gtgaggggatcgatgagtaa	196
NM_057152.1	Kelch-like ECH-associated protein 1	<i>Keap1</i>	ctgcatccaccacagcagcgt	gtgcagcacacagaccccggc	250
NM_017008.3	Glyceraldehyde-3-phosphate dehydrogenase	<i>Gapdh</i>	aggtgtctcctgtgacttc	ctgttgctgtagccatattc	130

Results:

As regard measuring the rats' body and kidneys weight, table (2) showed significant reduction in body weight of diabetic rats as comparing them to the normal group after 8-week experiment. Although there was non-significant change in food intake, the body weight of treated groups showed significant increase when referred to the diabetic group. Also, it showed that the kidney weight and kidney hypertrophy index (kidney weight/Body weight) in diabetic rats were significantly increased as compared to those in the control rats. While, in treated groups the kidney hypertrophy index was ameliorated as comparing to the diabetic rats. By comparing the isolated treated groups with the combined one, DM-HT-GLY group shows significant improvement in all parameters that presented in table (2) than DM-HT and DM-GLY groups.

This study revealed magnificent effects of hydroxytyrosol as antioxidant and anti-inflammatory which could improve the biochemical picture of diabetic rats as shown in tables (3 and 4). Table (3) showed significant increase in blood glucose level, HbA1c, BUN, serum level of creatinine and increase in the albumin content in urine together with significant reduction in serum insulin, serum albumin and level of creatinine in urine of diabetic animals when comparing them to the control ones. Groups supplemented with HT, glyclazide or both, rats showed significant improvement in all these parameters in comparison with diabetic group especially in the combined treated group (as compared to the other treated groups). While, by comparing parameters of both DM-HT and DM-GLY rats, they did not show any significance, except for BUN, serum and urinary creatinine

levels DM-HT group expressed significant improvement as compared to DM-GLY group.

By measuring the oxidants and total antioxidant capacity (TAC) in renal tissue, diabetic rats showed significant increase in MDA and carbonyl protein content with reduction in TAC in comparison to the control rats. Also, the inflammatory cytokines (TNF α , IL6 and IL1B) in the diabetic rats' kidneys were significantly increased as compared to the control ones. Results

in table (4) showed that treated groups expressed statistically significant improvement in the tested parameters especially in those supplemented with combined HT and GLY when comparing with the non-treated diabetic or other treated groups. Also, Table (4) showed significant improvement in HT treated rats as compared with GLY treated group regarding these antioxidant and anti-inflammatory parameters.

Table2. Effect of Hydroxytyrosol on body weight and kidney weight of type 2 diabetic rats

	C	DM	DM- HT	DM- GLY	DM-HT-GLY
Body weight (gm) 8th week	420.37 \pm 7.82	205.93 \pm 10.83*	281.33 \pm 15.63#	294.12 \pm 11.22#	351.34 \pm 11.78#
Kidney weight (gm)	1.1 \pm 0.08	1.53 \pm 0.12*	1.21 \pm 0.08#	1.19 \pm 0.06#	1.11 \pm 0.05#
Kidney hypertrophy (kidney weight/Body weight) %	0.26 \pm 0.02	0.74 \pm 0.03*	0.43 \pm 0.01#	0.40 \pm 0.01#	0.32 \pm 0.01#

Values were expressed as means \pm standard error (n = 8~10 per group). C: non-diabetic control, DM: diabetic group, DM- HT: DM treated with HT (10 mg/kg/day) for eight weeks, DM- GLY: DM treated with glyclazide (5 mg/kg/day) for eight weeks. DM-HT-GLY: DM treated with HT and glyclazide in the same doses for eight weeks. *: P < 0.05 diabetic group as compared to control group, #: P < 0.05 treated groups as compared to diabetic group, \$: P < 0.05 treated groups as compared to DM-HT-GLY group

Table3. Effect of Hydroxytyrosol on the biochemical parameters in type 2 diabetic rats

	C	DM	DM- HT	DM- GLY	DM-HT-GLY
Glucose (mg/dl)	88.77 \pm 7.34	303.95 \pm 22.49*	144.26 \pm 18.53#	136.3 \pm 15.01#	108.97 \pm 8.16#
Insulin (mIU/l)	3.15 \pm 0.84	11.97 \pm 0.78*	7.10 \pm 0.91 #	7.51 \pm 0.62#	5.02 \pm 0.10#
Glycosylated Hb%	5.15 \pm 0.06	14.3 \pm 1.41*	7.3 \pm 0.41#	6.59 \pm 0.55#	5.84 \pm 0.77#
Serum creatinine (mg/dl)	0.48 \pm 0.048	2.0 \pm 0.128 *	0.84 \pm 0.077#	1.05 \pm 0.116#	0.57 \pm 0.078#
Blood urea nitrogen (mg/dl)	11.61 \pm 0.45	47.37 \pm 2.36*	17.15 \pm 0.37#	18.96 \pm 0.52#	14.71 \pm 0.70#
Serum albumin (gm%)	6.43 \pm 0.03	2.17 \pm 0.21*	4.28 \pm 0.56#	4.61 \pm 0.63#	5.02 \pm 0.37#
Urine creatinine mg/24 h	24.90 \pm 0.53	11.33 \pm 0.23*	18.41 \pm 0.63#	16.39 \pm 0.15#	22.63 \pm 0.62#
Urine albumin gm/24 h	0.06 \pm 0.02	0.54 \pm 0.04*	0.26 \pm 0.02#	0.32 \pm 0.01#	0.11 \pm 0.02#

Values were expressed as means \pm standard error (n = 8~10 per group). C: non-diabetic control, DM: diabetic group, DM- HT: DM treated with HT (10 mg/kg/day) for eight weeks, DM- GLY: DM treated with glyclazide (5 mg/kg/day) for eight weeks. DM-HT-GLY: DM treated with HT and glyclazide in the same doses for eight weeks. *: P < 0.05 diabetic group as compared to control group, #: P < 0.05 treated groups as compared to diabetic group, \$: P < 0.05 treated groups as compared to DM-HT-GLY group, ϕ : P < 0.05 DM-GLY group as compared to DM-HT group

Table 4. Effect of Hydroxytyrosol on the oxidative, antioxidant and anti-inflammatory activity in the renal tissue of type 2 diabetic rats

	C	DM	DM- HT	DM- GLY	DM-HT-GLY
MDA (nmol/mg protein)	6.71 ± 0.49	9.82 ± 0.34*	7.31 ± 0.18 [#]	7.97 ± 0.12 ^{#\$φ}	6.92 ± 0.1 [#]
TAC (μmol/mg protein)	122.44 ± 3.23	66.84 ± 6.87*	113.14 ± 13.0 ^{#\$}	104.6 ± 5.98 ^{#\$φ}	120.32 ± 6.72 [#]
Carponyl protein (nmol/mg protein)	3.63 ± 0.54	304.77 ± 8.29*	155.1 ± 9.52 ^{#\$}	184.55 ± 8.82 ^{#\$φ}	97.12 ± 11.63 [#]
TNFα (pg/mg protein)	84.65 ± 7.97	186.30 ± 3.91*	95.72 ± 4.05 [#]	106.34 ± 5.97 ^{#\$φ}	90.39 ± 6.81 [#]
IL6 (pg/mg protein)	51.24 ± 9.03	154.5 ± 3.85*	87.4 ± 3.07 ^{#\$}	93.35 ± 4.6 ^{#\$φ}	76.73 ± 5.88 [#]
IL-1β (pg/mg protein)	22.15 ± 2.83	78.99 ± 4.26*	36.57 ± 2.74 ^{#\$}	42.88 ± 2.97 ^{#\$φ}	31.35 ± 2.12 [#]

Values were expressed as means ± standard error (n = 8~10 per group). C: non-diabetic control, DM: diabetic group, DM- HT: DM treated with HT (10 mg/kg/day) for eight weeks, DM- GLY: DM treated with glyclazide (5 mg/kg/day) for eight weeks. DM-HT-GLY: DM treated with HT and glyclazide in the same doses for eight weeks. *: P < 0.05 diabetic group as compared to control group, #: P < 0.05 treated groups as compared to diabetic group, \$: P < 0.05 treated groups as compared to DM-HT-GLY group, φ: P < 0.05 DM-GLY group as compared to DM-HT group

The histopathological study of different groups reveals:

In control group (fig.1 A) slides didn't show any abnormal morphological changes in H&E stained kidney sections as regard glomeruli, tubules, interstitium and blood vessels.

Diabetic group (fig.1 B, C, D, E) revealed severe mesangial expansion (both cellular and matrix) along with tubular injury as evidenced by desquamation of the tubular epithelial cells, hydropic degeneration of the tubules, moderate interstitial chronic inflammatory cellular infiltrate and arteriolar hyalinosis.

In the group treated with hydroxytyrosol (fig.2A), slides showed moderate mesangial expansion, focal hydropic degeneration along with mild interstitial chronic inflammatory cellular infiltrate and normal blood vessels.

For those treated with gliclazide (fig.2B), slides showed moderate mesangial expansion, mild interstitial chronic inflammatory cellular infiltrate along with normal tubules and blood vessels.

The group treated with combined hydroxytyrosol and gliclazide (fig.2 C) revealed focal mild mesangial expansion along with normal tubules, interstitium and blood vessels.

Figure (3) showed the immunohistochemical stain of the kidneys of experimental groups for

caspase3. The image analysis in Figure (4) revealed that the diabetic kidneys show significant increase in percentage area stained with antibody for caspase 3. In the treated groups, the kidneys showed significant reduction in this percentage area of caspase3 in comparison to diabetic group especially the HT treated and combined treated groups.

In figure (5), results showed the significant reduction in quantitative renal expression of Nrf2 in type 2 diabetic rats as compared to the control rats. Although, Keap1 quantitative expression was elevated significantly in diabetic kidneys. These results were corrected in treated groups especially in the combined treated group as well as the HT treated group.

The histopathological study of different groups reveals:

In the group treated with hydroxytyrosol (fig.2A), slides showed moderate mesangial expansion, focal hydropic degeneration along with mild interstitial chronic inflammatory cellular infiltrate and normal blood vessels.

For those treated with gliclazide (fig.2B), slides showed moderate mesangial expansion, mild interstitial chronic inflammatory cellular infiltrate along with normal tubules and blood vessels.

The group treated with combined hydroxytyrosol and gliclazide (fig.2 C) revealed focal mild mesangial expansion along with normal tubules, interstitium and blood vessels.

Figure (3) showed the immunohistochemical stain of the kidneys of experimental groups for caspase3.

The image analysis in Figure (4) revealed that the diabetic kidneys show significant increase in percentage area stained with antibody for caspase 3. In the treated groups, the kidneys showed significant reduction in this percentage area of caspase3 in comparison to diabetic group especially the HT treated and combined treated groups.

In figure (5), results showed the significant reduction in quantitative renal expression of Nrf2 in type 2 diabetic rats as compared to the control

In control group (fig.1 A) slides didn't show any abnormal morphological changes in H&E stained kidney sections as regard glomeruli, tubules, interstitium and blood vessels.

Diabetic group (fig.1 B, C, D, E) revealed severe mesangial expansion (both cellular and matrix) along with tubular injury as evidenced by desquamation of the tubular epithelial cells, hydropic degeneration of the tubules, moderate interstitial chronic inflammatory cellular infiltrate and arteriolar hyalinosis.

rats. Although, Keap1 quantitative expression was elevated significantly in diabetic kidneys. These results were corrected in treated groups especially in the combined treated group as well as the HT treated group.

Discussion:

About 30-40% of type 2 diabetic patients suffer from diabetic nephropathy [28]. In spite of multiple therapeutic agents' availability which retard the progression of this diabetic renal complication, there is an interest in the use of natural medicines in order to prevent its genesis. In order to investigate the effect of one extravirgin olive oil simple phenol, hydroxytyrosol, in preventing diabetic-induced renal changes, we employed a STZ-nicotinamide model of type 2 diabetes in rats. Although numerous researches have been investigated the relationship of inflammation, apoptosis and oxidative stress on progression of diabetic nephropathy, the results were not always consistent. So, our study aimed to detect these relations with the development of diabetic nephropathy and tried to find out the effect of HT on the progression of the nephropathy.

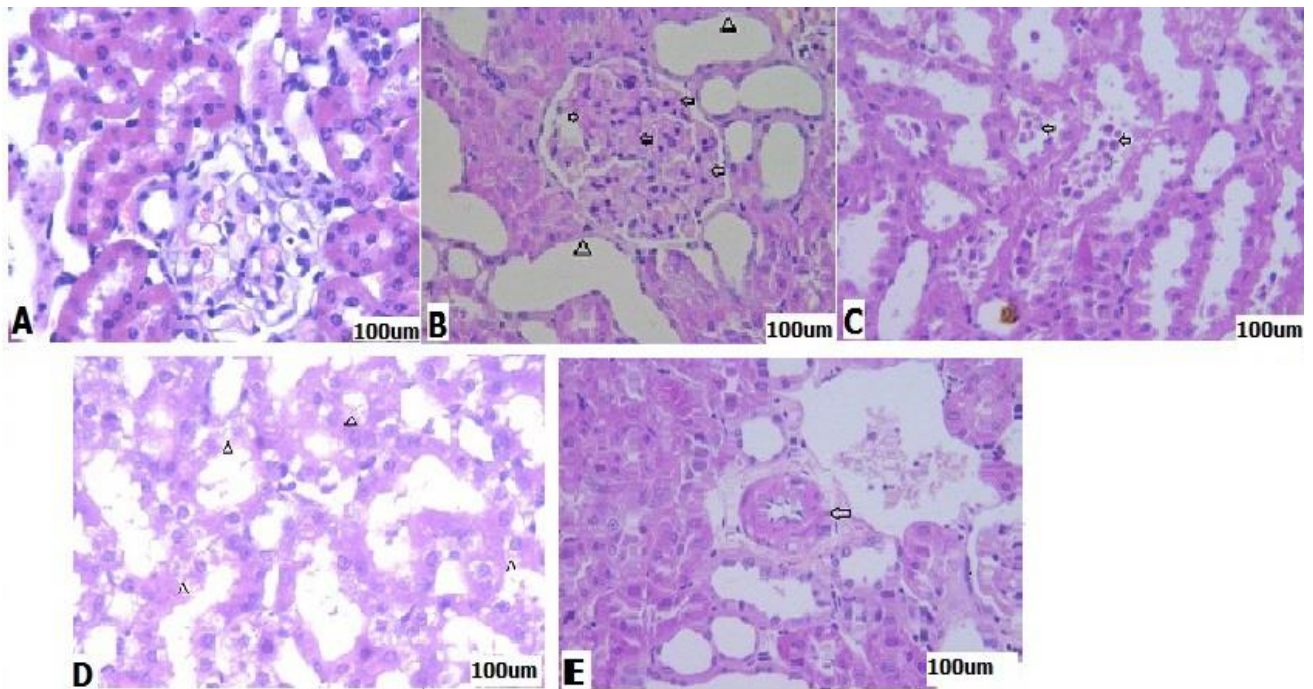


Figure (1): Histopathological examination of control and diabetic renal tissues. Photomicrograph (A): control group (C) that shows normal glomeruli and tubules (H&E x400). Photomicrograph (B): diabetic group (DM) shows glomerulus with severe mesangial expansion mainly matrix (arrows) and atrophy and dilatation of the surrounding tubules (asterisks) (H&E x400). Photomicrograph (C): diabetic group (DM) Shows tubular injury with desquamation of the lining epithelial cells (arrows) (H&E x400). Photomicrograph (D): diabetic group (DM) Shows hydropic degeneration of the tubular epithelium (asterisks) (H&E x400). Photomicrograph (E): diabetic group (DM) Shows arteriolar hyalinosis (arrow) (H&E x400).

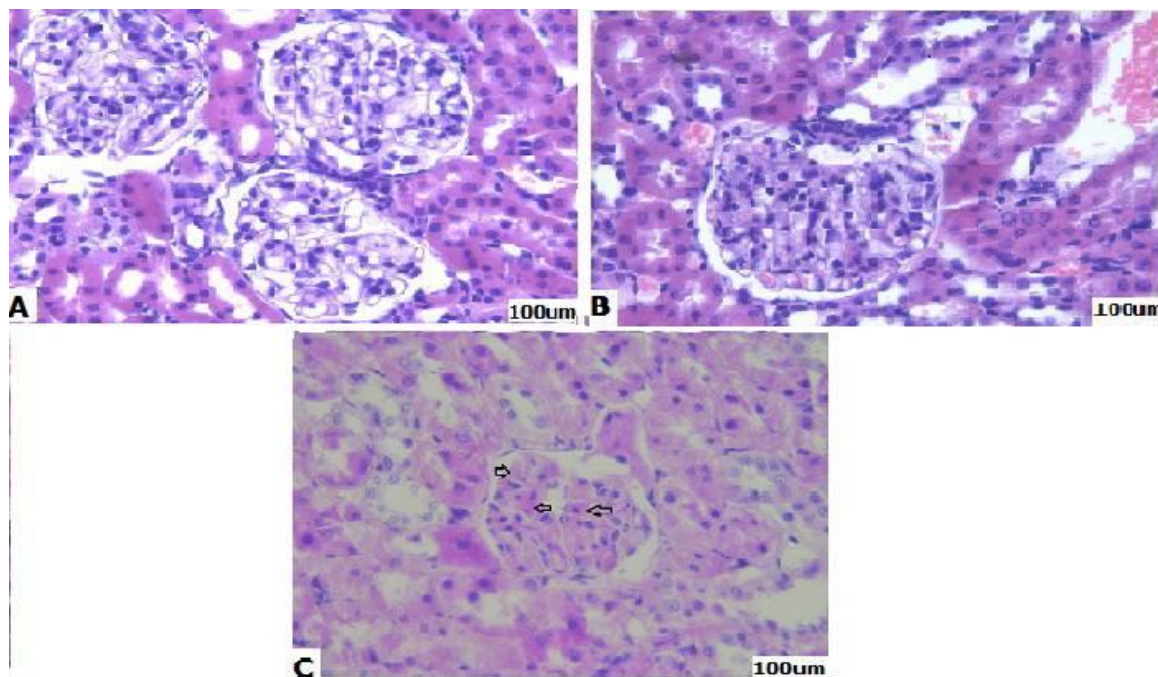


Figure (2): Histopathological examination of renal tissues for diabetic treated rats . Photomicrograph (A): diabetic group treated with hydroxytyrosol (DM-HT) shows glomeruli with moderate mesangial expansion (H&E x400). Photomicrograph (B): diabetic group treated with glyclazide (DM-GLY) shows glomerulus with moderate mesangial expansion and mesangial cell proliferation (H&E x400). Photomicrograph (C): diabetic group treated with combined HT-GLY (DM-HT-GLY) shows glomeruli with mild mesangial expansion (H&E x400).

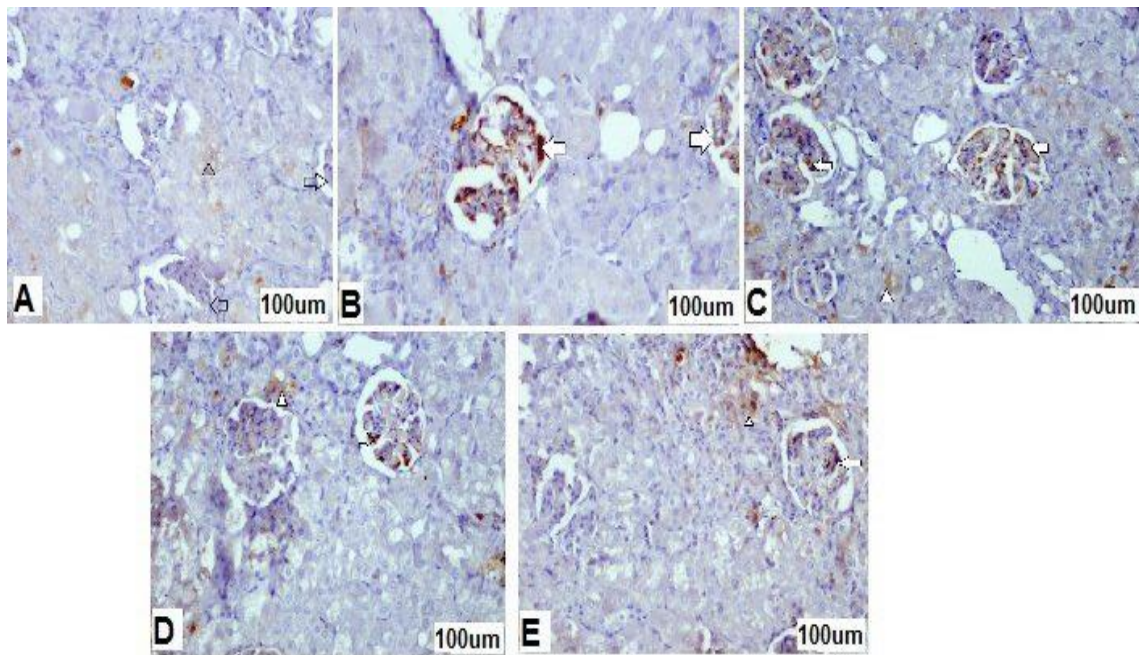


Figure (3) Immunostaining for caspase 3: Photomicrograph (A): control group (C) shows focal cytoplasmic reaction in tubular epithelial cells (Asterix) with total negative reaction in the glomeruli (arrows). Photomicrograph (B): Diabetic group (DM) shows cytoplasmic reaction is evident in all glomeruli (arrows) with focal cytoplasmic positivity in the tubular epithelial cells (Asterix). Photomicrograph (C): diabetic group treated with GLY (DM-GLY) shows focal moderate cytoplasmic reaction is seen in most of the glomeruli (arrow) with focal cytoplasmic reaction in tubular epithelial cells (Asterix). Photomicrograph (D): diabetic group treated with HT (DM-HT) shows focal cytoplasmic reaction in some glomeruli (arrow) with focal scattered cytoplasmic reaction in tubular epithelial cells (Asterix). Photomicrograph (E): diabetic group treated with combined HT-GLY (DM-HT-GLY) shows focal cytoplasmic reaction in few glomeruli (arrow) with focal scattered cytoplasmic reaction in tubular epithelial cells (Asterix).

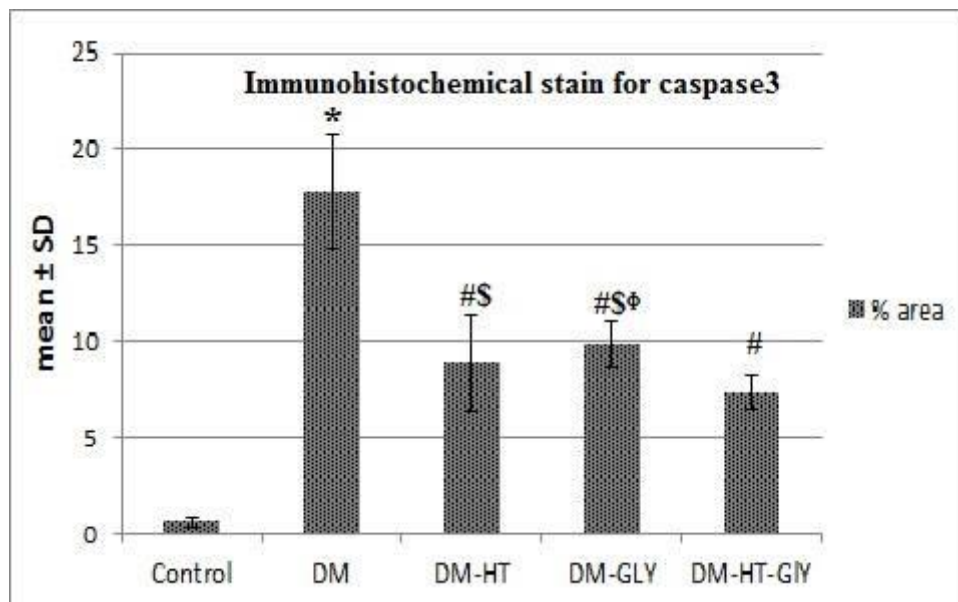


Figure (4): Immunohistochemical stain of the kidneys of experimental groups for caspase3. Values were expressed as means ± standard error (n = 8~10 per group). C: non-diabetic control, DM: diabetic group, DM- PTS: DM treated with Pterostilbene (40 mg/kg/day) for six weeks, DM- GLY: DM treated with glyclazide (5 mg/kg/day) for six weeks. DM- PTS-GLY: DM treated with Pterostilbene and glyclazide in the same doses for six weeks. *: P < 0.05 diabetic vs. control, #: P < 0.05 treated groups vs. DM, \$: P < 0.05 treated groups vs. DM-HT-GLY group, φ: P < 0.05 DM-GLY vs. DM-HT.

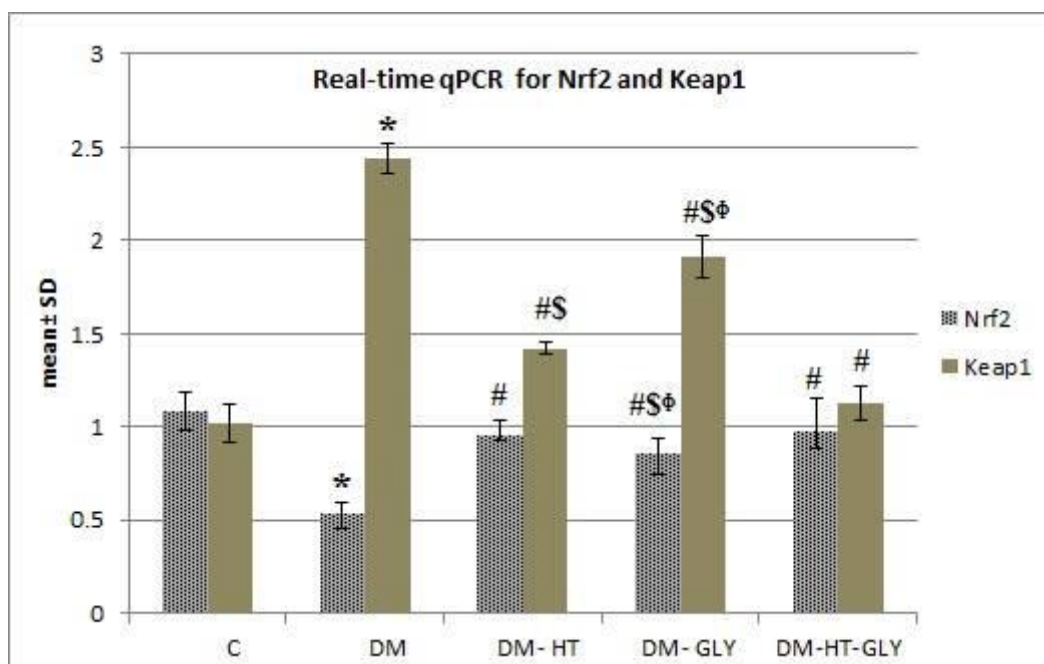


Figure (5): Effect of Hydroxytyrosol on the quantitative expression of Nrf2-Keap1 System in Kidney of type 2 diabetic rats. Values were expressed as means \pm standard error (n = 8~10 per group). C: non-diabetic control, DM: diabetic group, DM- HT: DM treated with HT (10 mg/kg/day) for eight weeks, DM- GLY: DM treated with glyclazide (5 mg/kg/day) for eight weeks. DM-HT-GLY: DM treated with HT and glyclazide in the same doses for eight weeks*: P < 0.05 diabetic vs. control, #: P < 0.05 treated groups vs. DM, \$: P < 0.05 treated groups vs. DM-HT-GLY group, φ: P < 0.05 DM-GLY vs. DM-HT.

Treated groups with HT alone or combined with glyclazide showed reduction in plasma glucose and insulin secretion resulted in significant decrease in glycosylated Hb% in comparison to diabetic rats. These results prove Pirozzi et al., [29] work who found that administration of HT to rats for 5 weeks stimulates the tolerance for glucose and increases insulin sensitivity leading to a reduction of HOMA-IR. Moreover, Violi et al. [30] detected that with increasing the concentration of polyphenols and olive oil, the glucose tolerance will be enhanced. Also, treated groups showed significant improvement in rats' body weights and kidney hypertrophy index when compared to diabetic group, indicating prevention of hyperglycemia induced muscle tissue damage and kidney hypertrophy. In diabetic rats, serum albumin concentration was decreased significantly with an increase in the albumin levels in urine,

thus demonstrating that albuminuria was related to deteriorating kidney function. Also, diabetic sera showed increased creatinine level and BUN along with decreased excretion of creatinine in the urine that are indicators of the development of diabetic nephropathy [28]. All of these renal deteriorating markers were reversed in all treated groups.

ROS toxicity that results from peroxidation of lipid in diabetes and production of protein carbonyls could have a crucial role in development of diabetic glomerulosclerosis [31]. These developed species deplete the antioxidant defenses of the cell thus getting it highly risky to be damaged by oxidative stress. The results of this research indicated that declining the levels of renal protein carbonyls and lipid peroxides were associated with HT administration to diabetic rats. These results may be due to free-radical quenching nature and antioxidant effect of HT.

A significant role of proinflammatory cytokines and subsequent inflammation have been suggested to be involved in diabetic nephropathy development and progression. TNF- α is competent to generate reactive free radicals that have cytotoxic effect on the renal epithelial, glomerular and mesangial cells leading to direct damage of kidneys [32]. Also, IL-1 β is considered to be involved in intraglomerular hemodynamics abnormalities development may be through synthesis of prostaglandin by mesangial cells [33]. The expression of iNOS in glomerular mesangial cells may be provoked by TNF- α and IL-1 β , that in turn results in excessive production of NO and cellular cGMP concentrations which lead to alteration of the cellular contractile responses and contributes to the early characteristic signs of diabetic nephropathy including hyperfiltration and microalbuminuria [34]. IL-6 enhances the proliferation of mesangial cell, accelerates fibronectin expression, also alters the extracellular matrix dynamics at the levels of podocyte and mesangial matrix that leads to increasing the endothelial permeability. Evans [35] and his coworkers had established a significant correlation between the degree of basement membrane thickening of glomeruli, a strong predictor of diabetic nephropathy progression, and increasing levels of IL-6. The present research detected that HT administration to diabetic group attenuates in a significant manner the raised renal levels of inflammatory cytokines as TNF- α , IL-1 β and IL-6, also it scavenges the free radicals efficiently thereby reducing the inflammatory consequence and renal tissue damage.

In this study, the increase in proinflammatory cytokines in renal tissue of the diabetic group was associated with impaired renal function as well as increase in mesangial matrix, and focal tubular injury. Elmarakby et al. [36] also detected that the inflammation and release of proinflammatory and profibrotic cytokines as well as ROS such as hydrogen peroxide may be involved in the structural damage of the kidney. Furthermore, lipids and protein oxidation were increased in association with a failure of Nrf2 transcription factor to translocate to nuclei and increase in its repressor Keap1 protein expression.

Nrf2 is considered as an important cellular defense mechanism that is capable to cope with chemical and oxidative stress [37]. It neutralizes free radicals by regulating the expression of intracellular antioxidants and phase II detoxifying enzymes, leading to cellular redox homeostasis. Our results showed a reduction in Nrf2 expression in the kidney slices and increase in Keap1, its repressor, which could explain the state of high oxidative stress in the diabetic rats. Nrf2–Keap1 sensor system identified the potency of HT to initiate dissociation of this complex, indicating Nrf2 activation which was detected in the treated kidneys.

The defensive nature of HT in the renal tissue of experimental groups was confirmed by histological as well as immunohistochemical studies. The major observation in the diabetic kidney morphology was mesangial expansion (both cellular and matrix) along with desquamation of the tubular epithelial cells, hydropic degeneration of the tubules, moderate interstitial chronic inflammatory cellular infiltrate,

together with arteriolar hyalinosis as referenced to control rats. With treatment either by HT alone or combined with GLY, the examined slides showed improvement in the previous diabetic renal changes.

Thus, this study divulges HT reno-protective effect in streptozotocin–nicotinamide rat model of diabetes and provides evidence about the antioxidant and anti-inflammatory effects of HT on the renal tissues. Moreover, HT exhibited a significant attenuation of glucose intolerance-induced oxidative stress, resulting in alleviating the renal ultrastructural changes.

In conclusion, we have demonstrated that HT may attenuate the oxidative stress induced by hyperglycemia through Nrf2 pathway activation and also, has anti-inflammatory effects via suppression of TNF α , IL6 and IL1B. As a result of these effects, HT attenuates the development and progression of diabetic nephropathy by reducing the mesangial cell proliferation and alleviating the tubular injury. Hence, this study recommends that the addition of antioxidants like HT to the management of diabetes may usefully signify its pharmacologic overture.

Limitations of the study: All histopathological sections and tissue enzyme activities were obtained from the left kidneys to keep the right one for RT-qPCR. The duration of the study was eight weeks only according to our reference [20], further work still needed to try the antioxidants for longer period.

Acknowledgements: We are acknowledged the members of department of Physiology together with MERC, Medical Experimental Research Center, in Mansoura University who contribute significantly in the experimental part of this research.

Author contribution: Shereen M. Samir designed the plane and performed the research; also, wrote the paper and discussed the results. Heba Sheta done the histopathological part of the study. Nadia Bakry performed the statistics of the data.

Conflict of interest: Authors disclose that there is no conflict of interest nor financial resources.

References:

1. **Karagiannis, T., Bekiari, E., Manolopoulos, K., Paletas, K. & Tsapas, A. (2010).** Gestational diabetes mellitus: why screen and how to diagnose. *Hippokratia*. 14(3),151-4.
2. **Kang, E.S., Lee, G.T., Kim, B.S., Kim, C.H., Seo, G.H., Han, S.J., Hur, K.Y., Ahn, C.W., Ha, H., Jung, M., Ahn, Y.S. Cha, B.S. & Lee, H.C. (2008).** Lithospermic acid B ameliorates the development of diabetic nephropathy in OLETF rats. *Eur. J. Pharmacol.*, 579, 418-25.
3. **Lee, E.Y., Lee, M.Y., Hong, W.Y., Chung, C.H. & Hong, S.Y. (2007).** Blockade of oxidative stress by vitamin c ameliorates albuminuria and renal sclerosis in experimental diabetic rats. *Yonsei Med. J.*, 48, 847-55.

4. **Ziyadeh, F.N. (2004).** Mediators of diabetic renal disease: the case for TGF- β as the major mediator. *J. Am. Soc. Nephrol.*, 15, S55-7.
5. **Ha, H., Hwang, I., Park, J. & Lee, H. (2008).** Role of reactive oxygen species in the pathogenesis of diabetic nephropathy. *Diabetes Res. Clin. Pract.*, 82, S42-5.
6. **Verzola, D., Bertolotto, M.B., Villaggio, B., Ottonello, L., Dallegrì, F., Salvatore, F., Berruti, V., Gandolfo, M.T., Garibotto, G. & Deferrari, G. (2004).** Oxidative stress mediates apoptotic changes induced by hyperglycemia in human tubular kidney cells. *J. Am. Soc. Nephrol.*, 15, S85–S87.
7. **Habib, S.L. (2013).** Diabetes and renal tubular cell apoptosis. *World J. Diabetes*, 15, 27–30.
8. **Fujii, H., Kono, K., Nakai, K., Goto, S., Komaba, H., Hamada, Y., Shinohara, M., Kitazawa, R., Kitazawa, S. & Fukagawa, M. (2010).** Oxidative and nitrosative stress and progression of diabetic nephropathy in type 2 diabetes. *Am. J. Nephrol.*, 31(4), 342-52.
9. **Vlassara, H., Torreggiani, M., Post, J.B., Zheng, F., Uribarri, J. & Striker, G.E. (2009).** Role of oxidants/inflammation in declining renal function in chronic kidney disease and normal aging. *Kidney Int. Suppl.*, 114, S3-11.
10. **Choi, B. H., Kang, K. S. & Kwak, M. K. (2014).** Effect of redox modulating NRF2 activators on chronic kidney disease. *Molecules*, 19(8), 12727–12759. doi: 10.3390/molecules190812727.
11. **Lee, J. M. & Johnson, J. A. (2004).** An important role of Nrf2-ARE pathway in the cellular defense mechanism. *Journal of Biochemistry and Molecular Biology*, 37(2), 139–143. doi: 10.5483/BMB.Rep.2004.37.2.139.
12. **Kobayashi, A., Kang, M. I. & Okawa, H. (2004).** Oxidative stress sensor Keap1 functions as an adaptor for Cul3-based E3 ligase to regulate proteasomal degradation of Nrf2. *Molecular and Cellular Biology*, 24(16), 7130–7139. doi: 10.1128/mcb.24.16.7130-7139.2004.
13. **Onozato, M.L., Tojo, A., Goto, A. & Fujita, T. (2004).** Radical scavenging effect of gliclazide in diabetic rats fed with a high cholesterol diet. *Kidney International*, 65, 951-960.
14. **Vallianou, N.G., Evangelopoulos, A. & Kazazis, C. (2013).** Resveratrol and diabetes. *Rev. Diabet. Stud.*, 10(4), 236–42. doi: 10.1900/RDS.2013.10.236.
15. **Covas, M.I., de la Torre, R. & Fitó, M. (2015).** Virgin olive oil: a key food for cardiovascular risk protection. *Br. J. Nutr.*, 113, S19-28.
16. **Mnafgui, K., Hajji, R., Derbali, F., Khlif, I., Kraiem, F. & Ellefi, H. (2016).** Protective effect of hydroxytyrosol against cardiac remodeling after isoproterenol-induced myocardial infarction in rat. *Cardiovasc. Toxicol.* 16, 147-55.

17. **Bulotta, S., Celano, M., Lepore, S.M., Montalcini, T., Pujia, A. & Russo, D. (2014).** Beneficial effects of the olive oil phenolic components oleuropein and hydroxytyrosol: focus on protection against cardiovascular and metabolic diseases. *J. Transl. Med.*, 12,1-9. doi:10.1186/s12967-014-0219-9
18. **Szkudelski, T . (2012).** Streptozotocin-nicotinamide-induced diabetes in the rat. Characteristics of the experimental model. *Exp. Biol. Med.*, 237(5),481-90. doi: 10.1258/ebm.2012.011372. Epub 2012 May 22.
19. **Radikova, Z., Koska, J., Huckova, M., Ksinantova, L., Imrich, R.& Vidas, M. (2006).** Insulin sensitivity indices: a proposal of cut-off points for simple identification of insulin-resistant subjects. *Exp. Clin. Endocrinol Diabetes*, 114, 249–56.
20. **Storniolo, C.E., Roselló-Catafau, J., Pintó, X., Mitjavila, M.T.& Moreno, J.J. (2014).** Polyphenol fraction of extra virgin olive oil protects against endothelial dysfunction induced by high glucose and free fatty acids through modulation of nitric oxide and endothelin-1. *Redox Biol.*, 2, 971–977.
21. **Palsamy,P. & Subramanian, S. (2011).** Resveratrol protects diabetic kidney by attenuating hyperglycemia-mediated oxidative stress and renal inflammatory cytokines via Nrf2–Keap1 signaling. *Biochimica et Biophysica Acta*, 1812, 719–731.
22. **Nayak, S.S. & Pattabiraman, T.N. (1981).** A new colorimetric method for the estimation of glycosylated hemoglobin. *Clin. Chim. Acta.*, 109, 267-274.
23. **Benzie, I.F.& Strain, J.J. (1996).** The ferric reducing ability of plasma (FRAP) as a measure of "antioxidant power": the FRAP assay. *Anal Biochem.*, 239(1),70–6.
24. **Yagi, K. (1984).** Assay for blood plasma or serum. *Meth Enzymol.*, 105, 328–31.
25. **Arellano-Buendía, A. S., García-Arroyo, F. E.& Cristóbal-García, M.I. (2014).** Urinary excretion of neutrophil gelatinase-associated lipocalin in diabetic rats. *Oxidative Medicine and Cellular Longevity*, 2014,11.
26. **Mega, C., De Lemos, E.T., Vala, H., Fernandes, R., Oliveira, J., Mascarenhas-Melo, F., Teixeira, F., & Reis, F. (2011).** Diabetic Nephropathy Amelioration by a Low-Dose Sitagliptin in an Animal Model of Type 2 Diabetes (Zucker Diabetic Fatty Rat). *Experiment. Diabetes Res.* 2011,162092, 12.
27. **Hsu, S.M., Raine, L. & Frauger, H. (1981).** Use of avidin-biotin peroxidase complex (ABC) in immunoperoxidase techniques: a comparison between ABC and unlabelled antibody (PAP) procedures. *J. Histochem. Cytochem.*, 29, 577–80.

28. **Mestry, S.N., Dhodi, J.B., Kumbhar, S.B. & Juvekar, A.R. (2017).** Attenuation of diabetic nephropathy in streptozotocin-induced diabetic rats by *Punica granatum* Linn. leaves extract. *J. Trad. Complem. Med.*, 7, 273-280.
29. **Pirozzi, C., Lama, A., Simeoli, R., Paciello, O., Pagano, T.B., Mollica, M.P., Di Guida, F., Russo, R., Magliocca, S. & Canani, R.B. (2016).** Hydroxytyrosol prevents metabolic impairment reducing hepatic inflammation and restoring duodenal integrity in a rat model of NAFLD. *J. Nutr. Biochem.*, 30,108–115.
30. **Violi, F., Loffredo, L., Pignatelli, P., Angelico, F., Bartimoccia, S., Nocella, C., Cangemi, R., Petruccioli, A., Monticolo, R. & Pastori, D. (2015).** Extra virgin olive oil use is associated with improved post-prandial blood glucose and LDL cholesterol in healthy subjects. *Nutr. Diabetes*, 5, e172.
31. **Hamden, K., Allouche, N., Damak, M. & Elfeki, A. (2009).** Hypoglycemic and antioxidant effects of phenolic extracts and purified hydroxytyrosol from olive mill waste in vitro and in rats. *Chem. Biol. Interact.*, 180, 421–432.
32. **Kuhad, A., Sachdeva, A.K. & Chopra, K. (2009).** Attenuation of renoinflammatory cascade in experimental model of diabetic nephropathy by sesamol. *J. Agric. Food Chem.*, 57, 6123–6128.
33. **Eberhardt, W. & Pfeilschifter, J. (2007).** Nitric oxide and vascular remodeling: spotlight on the kidney. *Kidney Int. Suppl.* S9–S16.
34. **Navarro-Gonzalez, J.F. & Mora-Fernandez, C. (2008).** The role of inflammatory cytokines in diabetic nephropathy. *J. Am. Soc. Nephrol.*, 19, 433–442.
35. **Evans, J.L., Goldfine, I.D., Maddux, B.A. & Grodsky, G.M. (2002).** Oxidative stress and stress activated signaling pathways: a unifying hypothesis of type 2 diabetes. *Endocr. Rev.*, 23,599–622 .
36. **Elmarakby, A. A. & Sullivan, J. C. (2012).** Relationship between oxidative stress and inflammatory cytokines in diabetic nephropathy. *Cardiovascular Therapeutics*, 30(1),49–59. doi: 10.1111/j.1755-5922.2010.00218.
37. **Elango, B., Dornadula, S., Paulmurugan, R. & Ramkumar, K.M. (2016).** Pterostilbene Ameliorates Streptozotocin-Induced Diabetes through Enhancing Antioxidant Signaling Pathways Mediated by Nrf2. *Chem. Res. Toxicol.*, 29, 47–57.