



## LATERAL SPHINCTEROTOMY UP TO THE FISSURE APEX VERSUS TO LESS-THAN 1CM FROM ANAL VERGE IN CHRONIC ANAL-FISSURE IN FEMALES

Beshoy Tharwat Eskander, Abd El-Rahman Hassan Sadik, Abd El-Wahab Saleh, Hassan Awad Saad

general surgery Departments, Faculty of medicine, Zagazig University

### Corresponding author:

Beshoy Tharwat Eskander  
Zakaria .,  
[tharwat\\_beshoy@yahoo.com](mailto:tharwat_beshoy@yahoo.com)

### Abstract

**Background:** Lateral internal sphincterotomy is the ideal and gold standard surgical management of chronic anal fissure. The extent of lateral internal sphincterotomy is still a subject of discussion. Excess division of the internal sphincter leading to incontinence either to stool or flatus, so we must determine the extent of sphincterotomy.

**Subjects and methods:** Between the period from February 2018 and October 2018 in the General Surgery Department of Zagazig University and El – Ahrar teaching Hospitals, 62 female patients with chronic anal fissure with mean ages of (34.1 + 8.2) and (41.8 + 9.05) of group A and B respectively complaining of chronic anal fissure. Group A of (31) patients (50%) of study cases were subjected to lateral internal sphincterotomy up to the fissure apex. Group B of (31) patients (50%) of study cases were subjected to lateral internal sphincterotomy to less than 1 cm from anal verge.

**Results:** Group A showed complete fissure healing in 4 weeks (25) patients (80.6%) with (6) patients cases comprising (19.35%) with delayed wound healing in 6 weeks. (9) patients (29%) had transient incontinence to flatus.

Group B showed complete fissure healing in 5 weeks (20) patients (64.5%) with (11) patients cases comprising (35.5%) with delayed wound healing in 6 weeks. (2) patients (6%) had transient incontinence to flatus.

**Conclusions:** In females with chronic anal fissure, division of internal sphincter must not exceed 1 cm from anal verge and not reach apex of the fissure to preserve the internal sphincter function and prevent incontinence either to stool or to flatus.

**Keywords:** chronic anal fissure, lateral internal sphincterotomy, stool incontinence, fissure healing.

### INTRODUCTION

Anal fissure is a painful ulcer/crack in the skin lining the lower third of the anal canal distal to the dentate line. Anal fissure has acute and chronic forms, affecting both males and females at any age. [1].

Acute anal fissure can be managed by diet modification and medical treatment, but chronic anal fissure usually needs surgical intervention. [2].

Lateral internal sphincterotomy remains the surgical intervention of choice for management of anal fissures not responding to non-surgical therapy. Lateral internal sphincterotomy when indicated, remains the gold standard for surgical management of anal fissure [3].

Lateral internal sphincterotomy cures chronic anal fissure by preventing internal sphincter stenosis. However, division of the internal sphincter predisposes to sphincter dysfunction, manifests as incontinence, subdivided into different degrees of severity which, as might be expected, showed that flatus incontinence and seepage were much more frequent than frank incontinence of stool of any consistency [4].

Lateral internal sphincterotomy can be done by local or spinal anesthesia, carried out in the lithotomy position. There are two methods for LIS, closed method and open method [5].

**Aim of work:** To compare the results of lateral internal sphincterotomy : up to the fissure apex versus to less than 1 cm from anal verge in chronic anal fissure in females

to ensure rapid fissure healing , rapid pain relief and avoid incontinence either to stool or to flatus .

**Patients and methods:** The study was approved by the Ethical Committee of the Faculty of Medicine, Zagazig University, informed patient consent was obtained. This prospective randomized study included a total of 62 female patients \_in the period between February 2018 and October 2018 \_ presented by chronic anal pain and slight bleeding during defecation and lasts about 1-2 hours , with mean ages of (34.1 + 8.2) and (41.8 + 9.05 ) of group A and B respectively in the period from October 2016 and June 2018. Patients had been grouped A and B; group A of (31) patients with lateral internal sphincterotomy up to the fissure apex. Group B of (31) patients with lateral internal sphincterotomy to less than 1 cm from anal verge.

**Inclusion criteria:** Female Patients, at any age with chronic anal fissure, classified according to digital rectal examination scoring system (DRESS).

**Exclusion criteria:** Male patients, patients with acute anal fissure, Coexisting crohn`s disease or ulcerative colitis, Patients with impaired continence, Previous history of ano-rectal surgery, Previous history of anorectal malignancy/radiotherapy and Patients unfit for surgery

#### **Surgical technique :**

##### **Group (A): lateral internal sphincterotomy up to the fissure apex :**

- (31) cases were managed through lateral internal sphincterotomy up to the fissure apex.
- Patients in lithotomy position with spinal anesthesia (without muscle relaxant), the buttocks were retracted, laterally, using plasters. , under complete aseptic precautions, anal region sterilization done by povidone Iodine. A small 1-cm incision is made in the intersphincteric groove, and artery forceps is used to separate the internal sphincter from the mucosa and from the external sphincter, the internal sphincter is carried out **–at the level of fissure apex** - by a curved clamp to the surface of

wound and divided with the help of electro cautery, followed by pressure for 3 min. to control bleeding..

##### **Group (B): lateral internal sphincterotomy to less than 1 cm from anal verge:**

- (31) cases were managed by lateral internal sphincterotomy to less than 1 cm from anal verge
- Patients in lithotomy position with spinal an aesthesia (without muscle relaxant); the buttocks were retracted, laterally, using plasters. , under complete aseptic precautions, anal region sterilization done by povidone Iodine. A small 1-cm incision is made in the intersphincteric groove, and artery forceps is used to separate the internal sphincter from the mucosa and from the external sphincter, the internal sphincter is carried out **–at a point less than 1 cm from the anal verge** - by a curved clamp to the surface of wound and divided with the help of electro cautery, followed by pressure for 3 min to control bleeding..

Postoperatively, patients were given antibiotics and were examined for pain or bleeding. In the 1st postoperative day, local examination of the wound for any haematoma, bleeding, seroma, bruises, if there is no findings the patient was discharged and covered with antibiotics for 7 days and follow up for 2 weeks, and 1-6 months to check any discharge, infection, incontinence (fecal, flatus) and recurrence

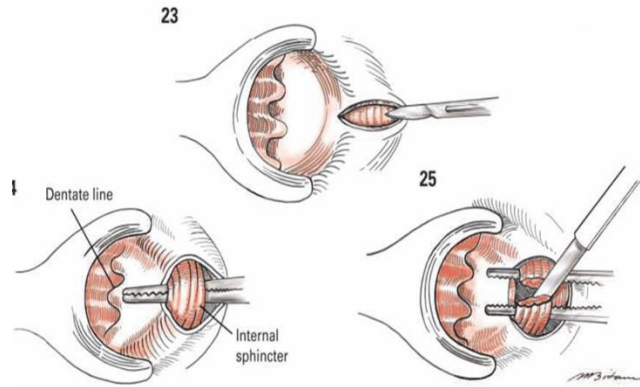
#### **RESULTS**

Group A of (31) female patients with chronic anal fissure , with a mean age 34.1 + 8.2 years (25 – 55), were subjected to lateral internal sphincterotomy **up to the fissure apex** , showed pain relief in about 2 days ( 2.1 + 0.86 days ) with fissure healing within ( 3 – 5 weeks ) ,only 6 patients with delayed fissure healing in 6 weeks ,9 patients had transient flatus incontinence .

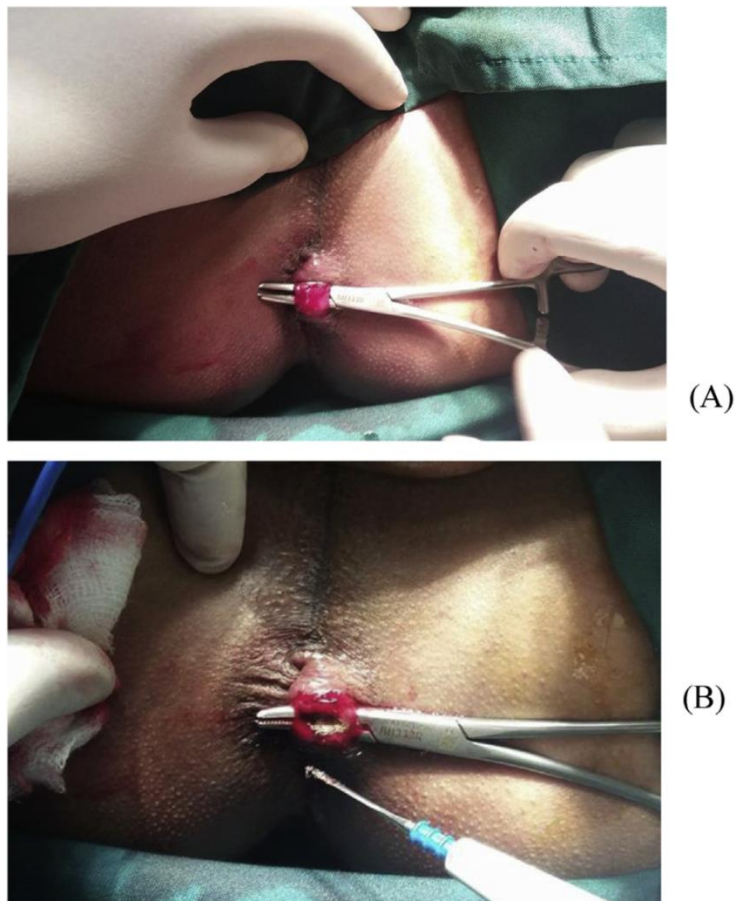
Group B of (31) patients with mean age 41.8 + 9.05 years ( 23 – 65 ) , who were treated by lateral internal sphincterotomy to less than 1 cm from anal verge. showed pain relief in about 3 days (3.8 + 0.79) days with fissure

healing within ( 4– 5 weeks ) ,only 11 patients with delayed fissure healing in 6 weeks ,2

patients had transient flatus incontinence .



**Fig 1** open lateral internal sphincterotomy .



**Fig 2** identification of internal sphincter and division by electro cautery.

**Table 1.** age in both groups .

<u>Variable</u>	<u>Group ( A )</u> <u>N = 31</u>	<u>Group ( B )</u> <u>N = 31</u>	<u>P value</u>
<u>Mean age</u> <u>( in years )</u>	<u>34.1 + 8.2</u> <u>years(25 – 55 )</u>	<u>41.8 + 9.05 years ( 23</u> <u>– 65 )</u>	<u>0.499869.(NS)</u>

**Table 2 :** time required for pain relief postoperatively in both groups

Pain relieved In ( days )	Group ( A ) N = 31	Group ( B ) N = 31	P value
Mean $\pm$ SD	2.1 $\pm$ 0.86 (1-3 )	3.8 $\pm$ 0.79 (3-5)	0.02468552

**Table 3.** clinical symptoms and signs in both groups .

	Group ( A ) N = 31	Group ( B ) N = 31	Total N= 62	P value
<b>Presenting symptoms</b>				
Pain with defecation	<b>30 ( 96.7 % )</b>	<b>29 ( 93.5 % )</b>	<b>59 ( 95.1 % )</b>	<b>0.499869. (NS)</b>
Bleeding	<b>11 ( 35.5 % )</b>	<b>10 ( 32.2 % )</b>	<b>21 ( 33.9 % )</b>	
Itching	<b>9 ( 29 % )</b>	<b>10 ( 32.2 % )</b>	<b>19 ( 30.6 % )</b>	
Perianal Discharge	<b>5 ( 16.1 % )</b>	<b>3 ( 9.7 % )</b>	<b>8 ( 12.9 % )</b>	
<b>Clinical signs</b>				
Sentinel piles	<b>23 ( 74.1% )</b>	<b>25 ( 80.6% )</b>	<b>48 ( 77.4 % )</b>	<b>0.5667 . ( N S )</b>
Hypertrophied anal papillae	<b>14 ( 45.1% )</b>	<b>12 ( 38.7% )</b>	<b>26 ( 41.2 % )</b>	
Exposed IAS fibers	<b>9 ( 29.03% )</b>	<b>7 ( 22.5 % )</b>	<b>16 ( 25.8 % )</b>	
Duration of symptoms (month )	<b>7.3 + 1.9(4-11)</b>	<b>7.5 + 2.5(4-12)</b>		<b>0.635917 ( NS )</b>

Tab 4 : healing in both group

Healing	Group ( A ) : N : 31	Group ( B ) : N :31	P value
Early healing	25 ( 80.65 % )	20 ( 64.5 % )	0.15865387 .
Late healing	6 ( 19.35 % )	11 (35.5 % )	

### DISCUSSION

Chronic anal fissure is a common anorectal disorder affecting any age. It commonly affects the younger and middle age groups, and has no sex predilection with acute form (< 6 weeks) and chronic forms (not responding to medical treatment > 6 weeks [6] (

The cardinal symptom of chronic anal fissure is sharp, agonizing, cutting pain with defecation that may persist for minutes to hours post defecation. The pain may be associated with scanty amount of bright red blood and pruritis ani [7]

In this study we are concerned with chronic anal fissure in females as they are liable to obstetric anal sphincter injuries. Obstetric anal sphincter injuries (OASIS) is believed to be the most important cause of fecal incontinence, and as many as 44% of women with OASIS will develop fecal incontinence later in life.[8] .

In contrast to lateral internal anal sphincterotomy in males, division of the internal anal sphincter in most females tends to be more extensive than intended. This is probably related to their shorter anal canal. In some females, lateral internal anal sphincterotomy may compromise sphincter function and precipitate anal incontinence, particularly in the presence of other sphincter defects. Care should be exercised especially in the presence of previous obstetric trauma, as internal anal sphincter division may further compromise sphincter function.[9].

Women giving birth are at increased risk of developing anal fissures due to pressure on the perineum. Spasm of the anal sphincter or local ischemia can predispose them to, or worsen, anal fissures. [10]

Anal fissure is more common in females as they are more liable to constipation by hormonal changes during pregnancy decreasing intestinal motility or mechanically by compression on the rectum by the gravid uterus and direct trauma to (rectum, anal canal) during childbirth.[11]

Women are nearly twice as likely as men to report fecal incontinence that is moderate to severe and it is well known that vaginal birth can cause significant trauma to the anal sphincter. However, it is well known that many women with sphincter injuries are continent and some women with intact sphincters have fecal incontinence.[12]

Primary Anal Fissures usually caused by trauma. Trauma may be caused by passage of hard stool as in constipation, childbirth trauma in women. Less commonly, may be caused by local irritation to the inner lining of the anus by prolonged or repeated passage of diarrhea [13]

The ideal treatment of chronic anal fissure - after failure of medical treatment is surgical treatment in the form of lateral internal sphincterotomy [14]

Although lateral internal sphincterotomy is the operation of choice , some people don't prefer performing it for the post-operative incontinence , so , The following question is the extent of internal sphincterotomy , should it extend to the fissure apex or just to less than 1 cm from anal verge .[15]

Lateral internal sphincterotomy must be done cautiously in female patients as they are more liable to incontinence. Anal incontinence can result from damage to the pelvic floor muscles or nerves (or both) during delivery, or from a tear or another injury to the anal sphincter. For example, if you have an

assisted vaginal delivery (especially with forceps) or an episiotomy.[16]

In this study, we have 62 female patients with chronic anal fissure randomly divided in two groups. Group (A); in which lateral internal sphincterotomy done **up to the fissure apex**; and group (B) In which lateral internal sphincterotomy done **up to less than 1 cm from anal verge**.

In group (A), the patients ages ranged from 25 to 55 years old with mean 34.1years. While in group (B) ages ranged from 23 – 65 years old with mean age 41.8 + 9.05 years. With p value (0.4998.) indicating that there is no statistical significant difference.

Our study revealed that healing is faster in group (A) Where Internal Sphincter divided up to the fissure apex in which fissure healed in about (3-5weeks) with 6 patients only with delayed healing in 6 weeks, compared to group (B) where internal sphincter divided up to less than 1 cm from anal verge with fissure healed in (4-5) weeks, 11 patients with delayed healing in 6 weeks.

Post-operative pain was assessed by using the patients' Verbal Descriptive Scale (VDS) for pain with standard five categories; 0: No pain, 1: Mild pain, 2: Moderate pain, 3: Severe pain, 4: Very severe pain. Our study showed that time required for pain relief in group ( A ) was 2.1 + 0.86 days which was shorter than in group ( B ) which was : 3.8 + 0.79 days.

Time needed for pain relief postoperatively is shorter in group (A) with mean time needed for pain relief is 2.1 days compared to 3.8 days needed in group (B). [17]

Time needed for pain relief postoperatively is shorter in group (A) with mean time needed for pain relief is 2.1 days compared to 3.8 days needed in group (B).

In our study, no patient had incontinence to stool, with 9 patients had incontinence to flatus in group (A) compared to 2 patients only in group (B). Only one patient had recurrent anal fissure after one month in group (A) compared to two patients complained from recurrent anal fissure after three month in group (B).

Our study showed that , both techniques allows fissure healing but , division of the

internal sphincter up to the fissure apex may cause loss of internal sphincter function with incontinence either to stool or flatus ,while division of the internal sphincter to less than 1 cm from anal fissure allows fissure healing and preserve sphincteric function .

#### Follow up:

\* Patients are allowed to get out of bed and encouraged to move their bowels as soon as possible after operation. Sits baths can be an effective method of pain control

\* Postoperative stool softener, laxatives, local analgesics and sits baths were advised for all patients to reduce pain, bleeding and avoid constipation

\* Postoperatively, patients were given antibiotics and were examined for pain or bleeding. In the 1st postoperative day, local examination of the wound for any haematoma, bleeding, seroma, bruises, if there is no findings the patient was discharged and covered with antibiotics for 7 days and follow up for 2 weeks, and 1-6 months to check any discharge, infection, incontinence (fecal, flatus) and recurrence..

#### CONCLUSIONS

In females with chronic anal fissure, division of internal sphincter must not exceed 1 cm from anal verge and not reach apex of the fissure to preserve the internal sphincter function and prevent incontinence either to stool or to flatus.

**Conflict of Interest:** Non declared.

**Funding:** No funding sources.

#### REFERENCES

1. Latif, A., et al. (2013). "Morbidity associated with treatment of chronic anal fissure." *Pak J Med Sci* 29(5): 1230-1235.
2. Nelson, R. L. (2014). "Anal fissure (chronic)." *BMJ Clin Evid* 2014..
3. Bapat, P. S. and A. Y. Desai (2016). "A study of outcome after lateral internal anal sphincterotomy for anal fissure." *IJAR* 2(2): 423-425.
4. Liang, J. and J. M. Church (2015). "Lateral internal sphincterotomy for surgically recurrent chronic anal fissure." *The American Journal of Surgery* 210(4): 715-719.
5. Anandaravi, B. and B. Ramaswami (2017). "Closed versus open lateral internal anal sphincterotomy in a chronic anal fissure."

- International Surgery Journal 4(3): 1055-1058.
6. COURA, M. d. M. A., et al. (2016). "Is digital rectal exam reliable in grading anal sphincter defects?" *Arquivos de gastroenterologia* 53(4): 240-245.
  7. Elsebae, M. M. (2007). "A study of fecal incontinence in patients with chronic anal fissure: prospective, randomized, controlled trial of the extent of internal anal sphincter division during lateral sphincterotomy." *World journal of surgery* 31(10): 2052-2057.
  8. Fox, A., et al. (2014). "Anorectal conditions: anal fissure and anorectal fistula." *FP essentials* 419: 20-27..
  9. Salih, A. M. (2017). "Chronic anal fissures: Open lateral internal sphincterotomy result; a case series study." *Annals of Medicine and Surgery* 15: 56-58.
  10. Mapel, D. W., et al. (2014). "The epidemiology and treatment of anal fissures in a population-based cohort." *BMC gastroenterology* 14(1): 129.
  11. Bradley, C. S., et al. (2017). "Constipation in pregnancy: prevalence, symptoms, and risk factors." *Obstetrics & Gynecology* 110(6): 1351-1357.
  12. Brincat, C., et al. (2009). "Fecal incontinence in pregnancy and post-partum." *International Journal of Gynecology & Obstetrics* 106(3): 236-238.
  13. Khan, R., et al. (2015). "Prevalence of Fissure-in-Ano among the Patients of Anorectal Complaints Visiting Nium Hospital." *J Community Med Health Educ* 5(2): 344.
  14. Higuero, T. (2015). "Update on the management of anal fissure." *Journal of visceral surgery* 152(2): S37-S43.
  15. Garg, P., et al. (2013). "Long-term continence disturbance after lateral internal sphincterotomy for chronic anal fissure: a systematic review and meta-analysis." *Colorectal Disease* 15(3): e104-e117.
  16. Faridi, A., et al. (2012). "Anal sphincter injury during vaginal delivery—an argument for cesarean section on request?" *Journal of perinatal medicine* 30(5): 379-387.
  17. Pathak, A., et al. (2018). "The utility and validity of pain intensity rating scales for use in developing countries." *Pain reports* volume 3 issue 5).

**How to cite this article:** Beshoy TE, Abd El-Rahman HS, Abd El-Wahab S, Hassan AS. lateral sphincterotomy up to the fissure apex versus to less-than 1cm from anal verge in chronic anal-fissure in females.ZUMJ 2019; 25 (2); 227-233. DOI: [10.21608/ZUMJ.2019.26923](https://doi.org/10.21608/ZUMJ.2019.26923)