



## Hepatoprotective Effect of Gum Arabic Versus Cisplatin Hepatotoxicity in Adult Male Rats: Biochemical, Histological and Ultrastructural Studies

Mohamed I. Rady<sup>1</sup>, Yosry A. Okdah<sup>2</sup>, Hamada Z. Hassaan<sup>2</sup>, Amany E. Nofal<sup>2\*</sup>

<sup>1</sup>Department of Zoology, Faculty of Science (Boys), Al-Azhar University, Egypt

<sup>2</sup> Department of Zoology, Faculty of Science, Menoufia University, Egypt



### Abstract

Hepatotoxicity is an imperative drawback of treatment with antineoplastic Cisplatin (Cis). Gum Arabic (GA) is a drained Gummy dislodged from the Acacia Senegal branches and stems, composed of calcium, potassium, and magnesium salts of polysaccharide GA acid. The objective of the current study is to evaluate the capability of GA to keep liver safe from damage caused by a single intraperitoneal weekly dose of 7.5 mg Cis/kg rats. Twenty-four albino rats were located randomly in 4 groups; G1 act as control, G2 received GA, G3 received Cis, and G4 received simultaneously both Cis and GA. The results showed that Cisplatin-induced elevation in liver enzymes and caused different histological lesions in the hepatic structures. Immunohistochemically moderate positive reactions for PCNA and Caspase-3 were detected in hepatocytes of Cis in comparison with control. While, GA as a protective antioxidant exhibited a significant improvement in biochemical, histological, and immunohistochemical parameters, suggesting the use of GA in combination with Cis to attenuate liver damage in cancer patients.

*Keywords:* Cisplatin, Electron microscope, Immunohistochemistry, liver, PCNA.

### 1. Introduction

Natural products have a powerful history as an active component of traditional medicine; around 2.1 million biomolecules with drug-like resources have been mentioned. Natural products like Gum Arabic (GA) are fruitful and help to diminish side effects unlike common chemotherapy in non-target organs [1]. GA is a loose liquid gained from the discharge of Acacia Senegal branches and stems. The GA consists of macromolecules, minerals, and amino acids. Gum Arabic has carbohydrates like galactose, rhamnase, glucuronic acid, and arabinose. Also, it is rich in amino acids (hydroxyproline, serine, proline, leucine, and histidine). Gum Arabic is a rich source of antioxidant minerals; copper, iron, zinc, and manganese [2].

Cisplatin is one of the antineoplastic therapies and one of alkylating agents that is known to treat many neoplastic disorders like gut, ovarian, cervical, and germ cell tumors [3]. Besides, Cisplatin could

suspend the growth of tumor cross-linking guanine bases in DNA strands directly striking DNA, so Cisplatin can limit the base pairing process and cause apoptosis [4]. Some studies approved that Cisplatin caused oxidative stress, responsible for various deleterious effects like nephrotoxicity, ototoxicity, hepatotoxicity, cardiotoxicity, and neurotoxicity [5]. This study aimed to clarify the possible enhancing effects of Gum Arabic as a natural product against non-target hepatotoxicity of Cisplatin in male rats.

### 2. Material and Methods

#### 2.1. Natural Materials and Chemicals

Gum Arabic was bought as crystals from a medical plants market (Shana health shop), Menoufia-Egypt.

Cisplatin was purchased from Hikma pharmacy, Badr City-Egypt as 1 mg per 1 ml concentration. Cis is the square planar coordination

\*Corresponding author e-mail: [shaimaa.nabil@sci.suezuni.edu.eg](mailto:shaimaa.nabil@sci.suezuni.edu.eg); (Amany E. Nofal).

EJCHEM use only: Received date 18 November 2022; revised date 08 January 2023; accepted date 27 January 2023

DOI: 10.21608/EJCHEM.2023.175461.7203

©2023 National Information and Documentation Center (NIDOC)

complex Cis-Diamminedichloroplatinum (Cis-[Pt (NH<sub>3</sub>)<sub>2</sub>Cl<sub>2</sub>], and its Molar mass is 300.01 g.mol<sup>-1</sup> [6].

## 2.2. High-Performance Liquid Chromatography Analysis (HPLC)

The aqueous Gum Arabic was prepared by dissolving 5 g of GA in 5 ml of distilled water as stock [7]. The HPLC of the aqueous Gum Arabic was performed by the Agilent 1100 series using for separation a C18 column chromatography (125×4.60 mm i.d., 5µm particle size). The Phenolic compounds and Flavonoids were separated by the recommended procedures [8 & 9], respectively.

## 2.3. Animals

Twenty-four male albino rats (*Rattus norvegicus*) were delivered from the National Research Centre (NRC), Giza-Egypt, and randomly housed in cages for a week before the experiment to be adapted to room climate and standard diet.

## 2.4. Experimental Design

The animals were separated into 4 groups each of 6 rats and given the following treatments for 4 weeks (Author's pilot study); The control group (G1) did not receive any treatment, Gum Arabic group (G2) orally received freshly prepared Gum Arabic at dose 7.5 mg GA/ kg rat BW/ daily (via stomach tube) [7], Cisplatin group (G3) injected a single intraperitoneal weekly dose of 7.5 mg Cis/ kg BW rat [10], and Co-treated group (G4) injected intraperitoneally with 7.5 mg Cis/ kg rat BW/ once a week and orally received 7.5 mg GA/ kg rat BW/daily. After 4 weeks of the experiments, animals have fasted overnight, and euthanization for complete dissection.

## 2.5. Biochemical Investigations

Inferior vena cava blood samples were collected immediately after the animal's dissection; centrifuged at 3000 rpm for 15-20 min and then the separated sera were stored at -18 °C for the biochemical estimation.

Both alanine aminotransferase and aspartate aminotransferase by using the recommended methods (ALT & AST) activity were assayed by using a commercial kit from Randox-Egypt [11].

Total concentrations of protein and albumin (ALB) were measured by using a commercial kit from Diamond-Egypt [12].

Estimation of antioxidant activity and oxidative stress in serum to assess the antioxidant enzymes activities; Catalase (CAT), Superoxide dismutase (SOD), Glutathione (GSH), and Malondialdehyde oxidative biomarker (MDA) by the recommended previous methods [13-16], respectively.

## 2.6. Histological Examinations

Liver was quickly removed after the animal's dissection. Liver pieces from each rat were harvested, fixed in 10% neutral formal saline, and embedded in molten paraffin at 58-60°C. Liver sections (5-µm) were cut by rotary microtome and located on glass slides for hematoxylin and eosin staining [17].

## 2.7. Immunohistochemical (IHC) Studies

The paraffin sections (4 µm thick) were performed by the avidin-biotin-peroxidase protocol. Sections were incubated with primary antibodies for one hour against proliferating cell nuclear antigen (PCNA) as a marker of cell proliferation [18] and Caspase-3 protein [19]. After that, were incubated with a secondary biotinylated antibody, then horseradish peroxidase conjugated with streptavidin for further 15 minutes, and finally added 3-amino-9-ethyl-carbasole (Dako Cytomation, USA).

## 2.8. Histomorphometric alteration and Image Analysis

All glass slides were examined under Olympus BX 41 light microscope; and photographed by Olympus digital camera, images were analyzed using the Image J software program [20] to determine the histomorphometric changes and the positive mean immune reactions percentage (%) in 10 selected fields of 6 paraffin sections in each group. The degree of Caspase3 reaction was recorded as the percentage of positively stained area of 10 fields/ slide, while, PCNA for 10 fields/ slide was evaluated as a percentage of immuno-labeled cells to all basal cells. After that their average means were calculated by using the color threshold to reflect what is seen in the images, and then measured the area, min&max, mean and area fraction.

## 2.9. Ultrastructure (TEM) Study

Small liver pieces were fixed in a mixture of formaldehyde and glutaraldehyde (4:1 percentage)

and embedded in molten Epon 812 for transmission electron microscopy (TEM) examination. Ultrathin sections (60–70 nm) were cut by ultramicrotome, stained by uranyl acetate and lead citrate [21], examined with CX100-JSM then the new model 1400 plus-JSM transmission electron microscope (JEOL Ltd., Tokyo, Japan) at Electron Microscope Unite, Alexandria University, Egypt.

### 2.10. Statistical analysis

Statistical data were estimated using Graph Pad Prism 8 software and expressed as the mean  $\pm$  standard deviation (mean $\pm$ SD), then compared between the different groups by one-way ANOVA (one-way analysis of variance) followed by Tukey HSD multiple range tests to determine the significance between them [22]. P values were deemed to be significant at  $P < 0.01$ . The normality test was performed utilizing the online normality test calculator "Shapiro-Wilk Test" and the data was

normally distributed [23&24].

## 3. Results

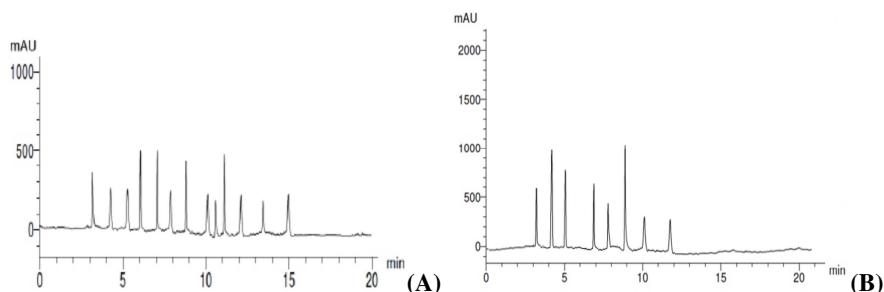
### 3.1. HPLC Analysis

The chromatography analysis of aqueous GA exhibited 21 compounds. The identified components were presented in Table (1) with the concentration ( $\mu\text{g/g}$ ) of each compound. Twenty-one compounds were characterized; including 13 phenolic acids and 8 flavonoids in the aqueous GA with significant concentrations (Figure 1; Table 1). The phenolic compounds as descending concentrations were ferulic acids, p-coumaric, Cinnamic, Pyrogallol, Chlorogenic, Benzoic acid, Caffeic, Syringenic, Catechol, Ellagic, Gallic, Protocatechulic, and Salicylic. The flavonoids as descending concentrations were luteolin, Naringin, Rutin, Querestetin, 7-OH flavones, Kampferol, Apegenin, Catechin.

**Table (1)**  
Phenolic and Flavonoid compounds of GA derived via HPLC

No	Retention time (RT)	Compounds name	Concentration ( $\mu\text{g/g}$ )*
<b>Phenolic acids</b>			
1.	3.0	Chlorogenic	7.88 $\pm$ 2.1
2.	4.0	Catechol	3.45 $\pm$ 1.01
3.	5.0	Syringenic	3.56 $\pm$ 1.1
4.	6.0	p-coumaric	10.14 $\pm$ 3.6
5.	7.0	Cinnamic	9.79 $\pm$ 2.88
6.	8.0	Caffeic	3.69 $\pm$ 1.08
7.	9.0	Pyrogallol	9.77 $\pm$ 3.02
8.	10.0	Gallic	2.56 $\pm$ 1.06
9.	10.5	Protocatechulic	2.31 $\pm$ 1.2
10.	11.0	Ferulic	11.09 $\pm$ 4.02
11.	12.0	Salicylic	2.17 $\pm$ 1.01
12.	13.5	Ellagic	3.09 $\pm$ 2.0
13.	15.0	Benzoic acid	4.19 $\pm$ 2.7
<b>Flavonoids</b>			
14.	3.0	7-OH flavone	6.11 $\pm$ 1.7
15.	4.0	Naringin	9.14 $\pm$ 2.01
16.	5.0	Rutin	7.02 $\pm$ 1.6
17.	7.0	Querestetin	6.88 $\pm$ 1.5
18.	8.0	Kampferol	3.88 $\pm$ 1.01
19.	9.0	Luteolin	10.22 $\pm$ 2.1
20.	10.0	Apegenin	2.33 $\pm$ 1.2
21.	12.0	Catechin	1.9 $\pm$ 0.83

\*average concentration of two replications  $\pm$  standard deviation



**Figure (1):** HPLC chromatograms of Phenolic (A) and Flavonoid (B) contents of Gum Arabic

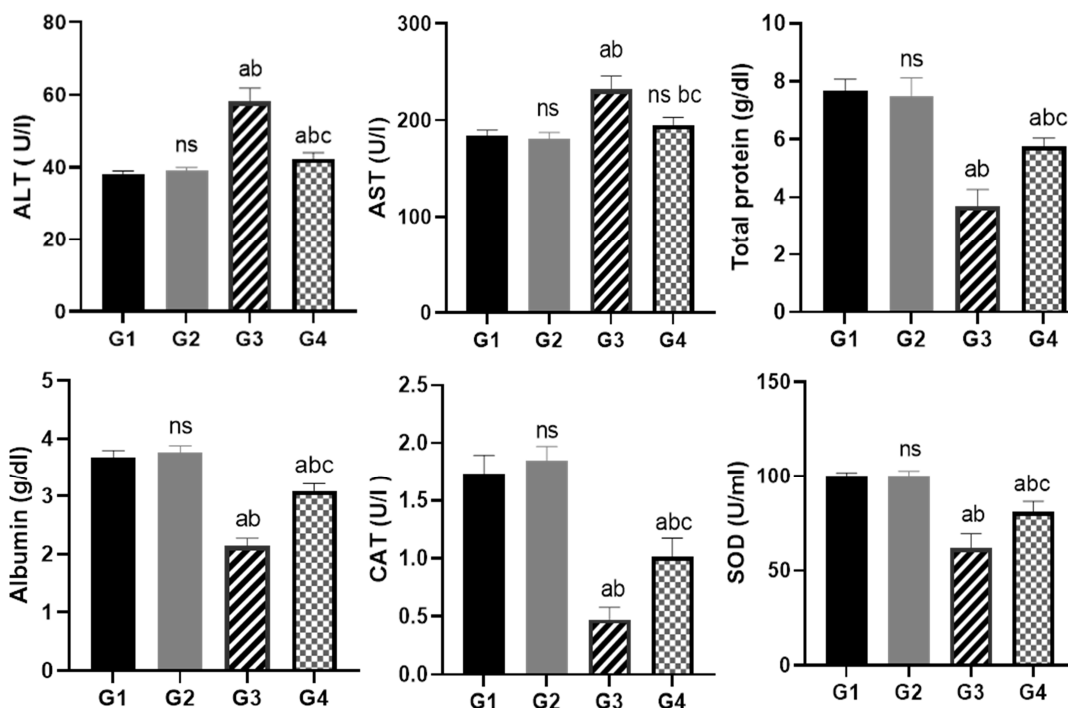
## 3.2. Biochemical results

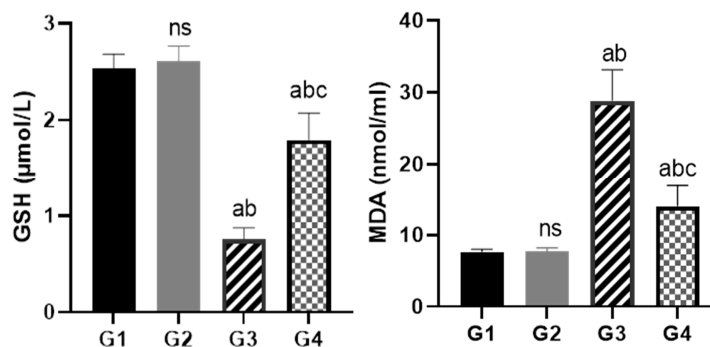
### 3.2.1. Liver Function Tests

Serum ALT and AST levels showed; no significant difference between the control and GA animals (**Figure. 2**), a significant elevation in Cis group compared to the control and GA groups, and an improvement with high significance at  $p < 0.01$  in co-treated group by decreasing ALT levels when compared with Cis group. **Figure (2)** showed that total protein and albumin concentrations in Cis group were significantly decreased when compared with control and GA groups, while in co-treated group (GA+Cis) showed a significant improvement in them in comparison with Cis group.

### 3.2.2. Antioxidant Biomarker

**Figure (2)** showed that, antioxidant enzymes activities, CAT, SOD and GSH in Cis group were significantly reduced in comparison with both control and GA groups ( $P < 0.01$ ), while in co-treated group (GA+Cis); they were significantly elevated when compared with Cis group. MDA in Cis group as an oxidative biomarker was significantly elevated compared with both control and GA groups ( $P < 0.01$ ), while in co-treated group (GA+Cis); it was significantly reduced when compared with Cis group.





**Figure (2):** Diagrammatic charts of serum alanine aminotransferase (ALT, U/I), aspartate transferase (AST, U/I), total protein (g/dl), albumin (g/dl), catalase (CAT, U/I), superoxide dismutase (SOD, U/ml), glutathione (GSH, μmol/L), and Malondialdehyde (MDA, nmol/mL) in the different studied groups; (G1) control, (G2) Gum Arabic, (G3) Cisplatin and (G4) Co-treated group. Different letters <sup>a,b,c,ns</sup> in the same column display the difference between groups; (ns) Indicates insignificant difference in comparison to G1, (a) Indicates a significant difference in comparison to G1, (b) Indicates a significant difference in comparison to G2, and (c) Indicates a significant difference in comparison to G3 (*P* value <0.01).

### 3.3. Histological and histomorphometric results

Rat liver sections of control and GA groups showed normal polygonal liver cells with round nuclei and eosinophilic cytoplasm, narrow spaced hepatic blood sinusoids with fine arrangement of Kupffer cells were arranged in between the hepatic cords (**Figure. 3, A&B; Table.2**). Liver sections of Cis-treated rats showed severe loss of hepatic architecture as sever congestion in the central hepatic veins, lymphocytic infiltration, perivascular edema,

hepatic cords disturbance, sever vacuolated cells, cellular necrotic area with condensed pyknotic nuclei (**Figure. 3, C,D&E; Table.2**). Liver sections in co-treated rats showed an obvious degree of improvement in hepatic structure, while a few vacuolated hepatocytes, mild congestion in central veins and dilated sinusoids were seen. Meanwhile, the necrotic and apoptotic cells that appeared in Cis group were seldom seen in co-treated rats (**Figure. 3, F; Table.2**).

**Table (2)**  
Histomorphometric and immunohistochemical alterations

Groups	Control	Gum Arabic	Cisplatin	Co-treatment
<b>Lesions</b>				
Inflammatory cell infiltration	Nil	Nil	++++	+
Vacuolated hepatocytes	+	+	++++	++
Condensed nuclei	+	+	++++	++
Apoptosis	Nil	Nil	++++	+
Necrotic area	Nil	Nil	+++	Nil
Perivascular edema	Nil	Nil	++++	++
PCNA %	+	+	+++	++
Caspase-3 %	+	+	+++	++

Absent (Nil), slight (+), mild (++) , moderate (+++), severe (++++).

### 3.4. Immunohistochemical Results

#### 3.4.1. Proliferating cell nuclear antigen immunoreactivity (PCNA-ir)

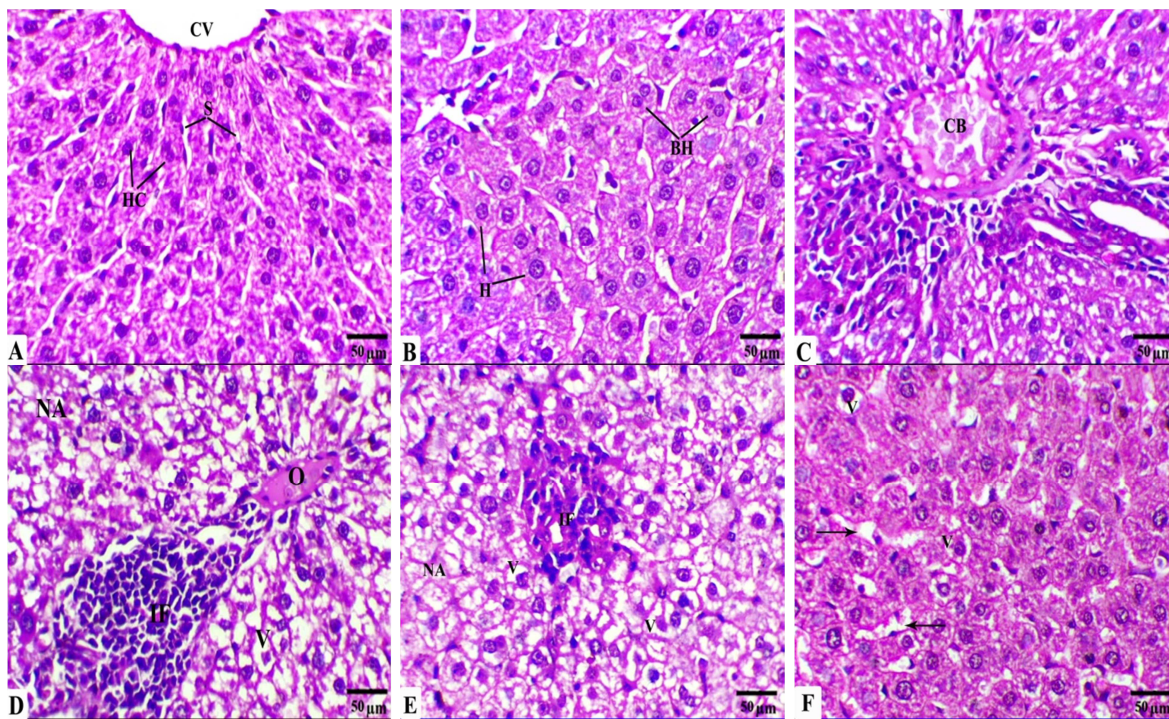
Liver sections in control and GA animals revealed a few positive reaction for PCNA-ir in hepatocyte nuclei (**Figure. 4, A&B**), while moderate positive reactions were detected for PCNA-ir in the liver sections of the Cis-treated rats (**Figure. 4, C**). Mild positive reactions for PCNA-ir were observed in

liver sections of rats treated with GA plus Cis (**Figure. 4, D**).

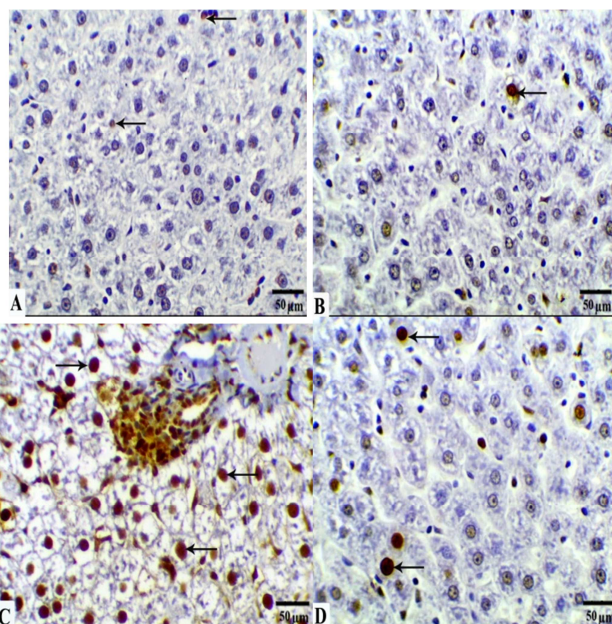
#### 3.4.2. Caspase-3 immunostaining expression

The Cisplatin group showed a significant increase in the Caspase-3 immunopositive reactions as compared to the control and GA rats. While Co-treatment with both GA and Cis caused a significant decrease in the Caspases-3 immunopositive reactions as compared to the Cis group (**Figure. 5, A-D**).



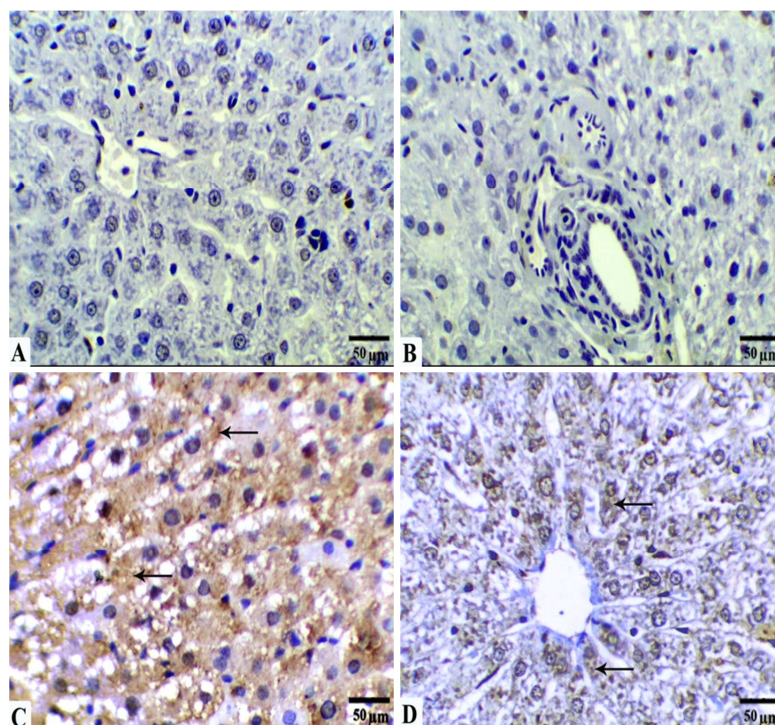


**Figure (3):** Photomicrographs of rat liver tissues from  
**A&B:** Control group (G1) and Gum Arabic group (G2), respectively, showing normal structures: central vein (CV), hepatic cords (HC), sinusoid (S), hepatocytes (H), and binucleated hepatocyte (BH). (H&E X400, 50µm Scale Bar)  
**C, D&E:** Cisplatin group (G3) showing moderate to a severe loss of liver architecture, congested blood vessel (CB), necrotic area (NA), oedematous blood vessel (O), aggregation of inflammatory cells (IF) and vacuolated hepatocytes (V). (H&E X400, 50µm Scale Bar)  
**F:** Co-treated group (G4) showing a mild to moderate degree of improvement in hepatocytes; central vein (CV) and hepatic cords (HC) with a few vacuolated cytoplasm (V) and mildly dilated sinusoids (arrows). (H&E X400, 50µm Scale Bar)



**Figure (4):** Photomicrographs of rat liver immunohistochemically PCNA-ir sections of the studied groups. A&B: Slight positive reactions in G1 and G2 respectively, C: Moderate positive reactions in Cis group (G3), and D: Mild positive reactions in the co-treated group (G4), positive reactions (arrows) (IHC., X400, 50µm Scale Bar)



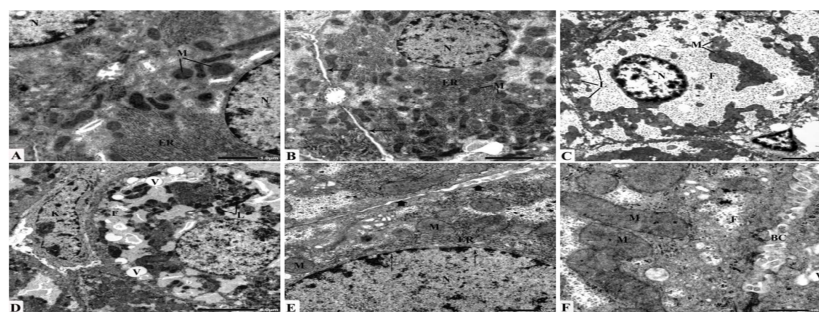


**Figure (5):** Photomicrographs of rat liver immunohistochemically Caspase-3 sections of different groups. A&B: G1 and G2 respectively showing a slight immune expression, C: Cisplatin group (G3) showing a significant immune expression, and D: the co-treated group (G4) showing a significant decrease in Caspase-3 positively stained cells as compared to the Cis group, positive reactions (arrows) (IHC., X400, 50 $\mu$ m Scale Bar)

### 3.5. Ultrastructure Study

Normal ultrastructure of the hepatocytes in G1 and G2 are depicted in **figures (6, A & B)**, respectively. Electron microscopy of the liver after Cisplatin treatment (G3) exhibited different lesions (**Figure. 6, C&D**). The heterochromatin condensation along the nuclear margin and small but prominent nucleoli along the nuclear envelope a noticeable features of the hepatic cells that indicated degenerated nuclei. Cellular margins were showing rough, ruptured, and irregular contours. Also, dilated mitochondria with dense matrix were mostly adhesive to each other. Lipid infiltration in the cytoplasm and fragmentation of the endoplasmic reticulum was commonly detected where those encountered suffered vesiculation and ruptured lamellae. In addition, increases in the lysosomes within the hepatocytes and hypertrophied

Kupffer cells were noticed (**Figure. 6, D**). Electron microscopy of liver sections of G4 revealed a histological picture of most of the hepatocytes comparable to that of the control group. Hepatocytes with intact cell membranes have euchromatic nuclei with regular nuclear membranes prominent. Also, regeneration in the rough endoplasmic reticulum, normal mitochondria, a smaller number of lysosomes, and an obvious decrease in the lipid inclusions were the most prominent features of the hepatocytes (**Figure. 6, E&F**).



**Figure (6): Electron micrographs of**

**A & B:** hepatocytes of G1 and G2, respectively, showing normal structures; cell membrane (Thin arrows), nucleus (N), mitochondria (M), and endoplasmic reticulum (ER)

**C & D:** hepatocytes of G3 showing irregular chromatin within the nucleus (N), adhesion mitochondria (M), increase of lysosomes (L), endoplasmic reticulum fragments within the cytoplasm (F), vacuolization in the cytoplasm (V) and hypertrophied Kupffer cell (K)

**E & F:** hepatocytes of G4 showing nearly normal nucleus (N), mitochondria (M), endoplasmic reticulum (ER), cell membrane (Arrowheads), nuclear membrane (Thin arrows), bile canaliculi (BC), with slight vacuolization (V) and fragmented endoplasmic reticulum (F)

**4. Discussion**

Since 1969 FAO/WHO Expert Committee on food additives give accepted the daily consumption of Gum Arabic due to its health benefits [25]. GA is a drained Gummy dislodged from the stems and branches of *Acacia senegal* composed of calcium, potassium, and magnesium salts of polysaccharide GA acid [26].

Cisplatin as chemotherapy and antineoplastic therapy can easily pass through the cell membrane and reaches the cell nucleus then changing the structure of DNA. Cis is related to hepatotoxicity caused by oxidative stress and apoptosis [27].

The findings of this study elicited Cis was found to cause hepatotoxicity which caused a significant elevation in serum concentrations of enzymatic biomarkers including ALT and AST and decreasing in total protein and albumin levels were recorded in the Cis group which is associated with liver damage degrees. This study suggests that the elevated liver markers were released from the damaged liver upon exposure to Cis, in agreement with Diab *et al.* [28] and Saleh *et al.* [29]. Cis-related hepatotoxicity at standard doses rarely occurred; however, at higher doses, hepatotoxicity was frequently observed and altered the clinical situation of cancer patients [30, 31]. Lu and Cederbaum [32] have mentioned that Cis-induced hepatotoxicity is enhanced by the increased generation of ROS (reactive oxygen species) and oxidative stress. Moreover, these oxygen radicals (ROS) bind covalently to the macromolecules and cause peroxidative degradation of cell membrane lipids, mitochondria, lysosomes, and endoplasmic reticulum rich with polyunsaturated fatty acids [33]. The current results agreed with Al-Malki and Sayed [34] and Basuony *et al.* [35] who concluded that serum AST and ALT were significantly elevated in Cis-caused liver damage. The elevated levels of AST and ALT enzymes in serum are indicative of cellular leakage, as well as, loss of functional integrity of cell membranes in the liver [36]. The capability of Cis to induce changes in the liver enzyme activity could be a secondary event next to Cis-caused liver damage with the consequent hepatocyte leakage [37].

In the current work, several hepatic histopathological and ultrastructural abnormalities were observed in Cis-treated animals. The liver cells undergo hydropic degeneration with swollen,

degenerated, and vacuolated organelles. The previous studies mentioned that Cis caused hepatocellular damage that is associated with increased oxidant stress, mitochondrial damage, and inflammatory cytokines [27, 32, 35]. Tveden-Nyborg *et al.* [38] reported similar ultrastructural features in fatty liver and attributed these abnormalities to the oxidative stress resulting in damaged polyunsaturated lipids in the mitochondrial membrane leading to cell death. Similarly, Ellatif *et al.* [39] reported that the hepatocytes of steatosis rats appeared with abnormal nuclei with an irregular nuclear envelope, dilated rough endoplasmic reticulum, degenerated swollen mitochondria, and an increased number of lysosomes that were possibly attributed via oxidative stress.

Elshama *et al.* [40] stated that cancer chemotherapy and antipsychotics are common examples of drug-caused oxidative stress associated with toxicity. The results of this study showed a drop in glutathione activity and severe loss of liver architecture in light and electron microscope examination, negative PCNA-ir reactivity, and positive Caspase-3 reactivity in the Cis group. That goes in the same line with biochemical results. While using GA, which is rich in antioxidative elements, showed ameliorating effects on all biochemical, histopathological, immunohistochemical, and ultrastructural signs. Gamal El-din *et al.* [41] showed that GA has an effective hepatoprotective role against acetaminophen-intoxication through oxidative stress depletion, nitric oxide scavenging and blocking hepatic macrophage function wherein acetaminophen overdose caused a significant decrease in the glutathione levels associated with the nitric oxide release and activation of the hepatic macrophages that are mediators of acetaminophen-caused hepatotoxicity. In coincidence with the present findings, Najla *et al.* [42] concluded that GA supplementation has a hepatic protective role whether biochemically or histologically. Also, Elshama [43] stated that GA is considered one of the natural antioxidants that have a protective and therapeutic role in several toxicities cases. Also, Hamid *et al.* [44] proved that GA improved the total protein concentration, glutathione peroxidase activities, total antioxidant capacity, and SOD. These agree with the combinational effect of the natural product as an active component of traditional medicine with anticancer drugs [45]. The author attributed these



antihepatotoxic effects to the ability of GA to lower the amount of the free radical that reduces lipid peroxidation and blocks oxidative stress; also, it showed an effective action on the histopathological extent of hepatocellular necrosis, inflammation, and apoptosis.

All biochemical, histological, immunohistochemical, and ultrastructural results of the current work concluded that GA kept liver safe from degeneration, in addition to its antioxidant, anti-inflammatory, and hepatoprotective properties may be attributed to its phenolic compounds and flavonoids. Antioxidant, bioactive, anti-inflammatory, antibacterial, anti-cancer, cardioprotective, and hepatoprotective properties of phenolic natural products and flavonoids have been demonstrated [46, 47]. Oxidative stress is the major contributor to liver injuries, thus antioxidant supplementation has often been recommended to be beneficial plant food flavonoids and Vitamins present in fruits, vegetables, and aromatic plants to be valuable in the protection from different diseases [48]. Phenolic acids such as syringic, gallic, ferulic, and gallic acids, showed activity in chronic liver injuries, diabetes, memory loss, and wound healing [49]. Lower risk of developing cancer, cardiovascular disease, and other chronic diseases might be related to a dietary intake of high vegetables, fruits, and whole grains [50].

### 5. Conclusion

So, this study recommends highly using GA as a protective antioxidant during Cis therapy duration to save from hepatotoxicity. GA might be suggested as a beneficial agent to safeguard against hazards occurring at the liver structure induced by chemotherapy exposure.

### 6. Ethical approval

Rats received ethical human care on the authority of the Ethics Committee at the Zoology department in the Faculty of Science of Menoufia University in Egypt (Approval number MUFS/ F/ HI/ 4/ 21).

**7. Conflicts of interest:** Not found.

### 8. Abbreviations

ALB: albumin; ALT: alanine aminotransferase; AST: aspartate aminotransferase; CAT: Catalase; Cis: Cisplatin; E: Eosin; GA: Gum Arabic; GA+Cis: Gum Arabic plus Cisplatin group; G1: Control group; G2: Gum Arabic group; G3: Cisplatin group; G4: Co-treated group; GSH: Reduced glutathione; H: Haematoxylin; HPLC: High Performance Liquid Chromatography Analysis; IHC: Immunohistochemistry; MDA: Malondialdehyde;

NRC: National Research Centre; PCNA: Proliferating cell nuclear antigen; ROS: reactive oxygen species; SOD: Superoxide dismutase; TEM: Transmission electron microscope.

### 9. References

- [1] Hastings, J., de-Matos, P., Dekker, A., Ennis, M., Harsha, B., Kale, N., Muthukrishnan, V., Owen, G., Turner, S., Williams, M. and Steinbeck, C. The ChEBI reference database and ontology for biologically relevant chemistry: enhancements for 2013. *Nucleic Acids Research*, (2013); 41(Database issue), D456–D463.
- [2] Babiker, M., Abbas, T. and Mohammed, M. Effect of Gum Arabic on liver function and antioxidant enzymes of Sprague Dawley rats. *IOSR Journal of Pharmacy and Biological Sciences*, (2017); 12: 29-33.
- [3] Siddik, Z.H. Cisplatin: mode of cytotoxic action and molecular basis of resistance. *Oncogene*, (2003); 22(47):7265–79.
- [4] Melnikov, S., Steitz T. and Polikanov Y. (2016). Insights into RNA binding by the anticancer drug Cisplatin from the crystal structure of Cisplatin-modified ribosome. *Nucleic Acids Res.*, 44(10):4978–87.
- [5] Santos, N.A., Rodrigues, M.A., Martins, N.M. and Santos, A.C. Cisplatin-induced Nephrotoxicity and Targets of Nephroprotection: An Update. *Arch. Toxicol.* (2012); 86 (8): 1233–1250.
- [6] Housecroft, C.E. and Sharpe, A.G. *Inorganic chemistry*, 2nd ed. Pearson Education Limited, Harlow ISBN., (2001); 978-0-130-39913-7.
- [7] El-Garawani, I., Hassab El-Nabi, S., El Kattan, A., Sallam, A., Elballat, S., Abou-Ghanima, S., El Azab, I.H., El-Seedi, H.A., Khalifa, S. and El-Shamy, S. The ameliorative role of Acacia senegal Gum against the oxidative stress and genotoxicity induced by the radiographic contrast medium (ioxitalamate) in albino rats. *Antioxidants*, (2021); 10(2): 221.
- [8] Lin, Y.L., Chen, Y.L., Liang, Y.C., Lin, J.K. Composition of Polyphenols in fresh Tea Leaves and Associations of their Oxygen Radical Absorbing Capacity with Antiproliferative Actions in Fibroblast Cells. *J. Agri. Food Chem.* (1996); 44:1387-1394.
- [9] Kuntic, V., Pejić, N., Ivković, B., Vujić, Z., Ilić, K., Mičić, S., & Vukojević, V. Isocratic RP-HPLC method for rutin determination in solid oral dosage forms. *Journal of Pharmaceutical and Biomedical Analysis*, (2007); 43(2): 718-721.
- [10] Al-Majed, A.A., Abd-Allah, A.R., Al-Rikabi, A.C., Al-Shabanah, O.A. and Mostafa, A.M.

- Effect of oral administration of Gum Arabic on Cisplatin-induced nephrotoxicity in rats. *Journal of biochemical and molecular toxicology*, (2003); 17(3): 146-153.
- [11] Reitman, S. and Frankel, S. A colorimetric method for the determination of serum glutamic oxalacetic and glutamic pyruvic transaminases. *Amer. J. Clin. Pathol.*, (1957); 28(1): 56-63.
- [12] Bowers, L.D. and Wong, E.T. Kinetic serum creatinine assays. II. A critical evaluation and review. *Clinical Chemistry*, (1980); 26(5): 555-561.
- [13] Aebi, H., Wyss, S.R., Scherz B. and Skvaril, F. Heterogeneity of erythrocyte catalase II. Isolation and characterization of normal and variant erythrocyte Catalase and their subunits. *Eur. J. Biochem.*, (1974); 48(1): 137-145.
- [14] Rest, R.F. and Spitznagel, J.K. Subcellular distribution of superoxide dismutases in human neutrophils. Influence of myeloperoxidase measurement of superoxide dismutase activity. *Biochem.J.*, (1977); 166(2):145-153.
- [15] Rahman, I., Kode, A., and Biswas, S.K. Assay for quantitative determination of glutathione and glutathione disulfide levels using enzymatic recycling method. *Nature Protocols*, (2007); 1(6): 3159-3165. doi:10.1038/nprot.2006.378
- [16] Ohkawa, H., Ohishi, N. and Yagi, K. Assay for lipid peroxidase in animal tissue by thiobaubituric acid reaction. *Anal Biochem.*, (1979); 95 : 351-358.
- [17] Suvarna, K.S., Layton C. and Bancroft, J.D. Bancroft's theory and practice of histological techniques E-Book, Elsevier health sciences. (2018).
- [18] Miller, K. Immunocytochemical techniques. In: Bancroft JD, Gamble M. Theory and practice of histological techniques, Ch: 20. 5th ed. Toronto, London, New York: Churchill Livingstone, (2002); 421.
- [19] Unger, C.A., Buchmann, C.L., Bunemann, S.K. and Schwarz, M. "Wild-Type Function of the p53 Tumor Suppressor Protein is not Required for Apoptosis of Mouse Hepatoma Cells." *Cell Death and Differ.*, (1998); 5: 87-95.
- [20] Rasband, W.S. ImageJ, National Institutes of Health, Bethesda, Maryland, USA, Imagej.Nih.Gov/Ij/, 1997-2012. (2014); JMP versión7,1989-2007.
- [21] Woods, A.E. and Stirling J.W. Transmission electron microscopy applications. In: Layton C, Bancroft JD, editors. Theory and practical histological techniques. Ch 22, 7th ed. Philadelphia, Churchill Livingstone, (2013); pp: 493 – 538.
- [22] Abdi, H. and Williams, L.J. Tukey's honestly significant difference (HSD) test, *Encyclopedia of research design*, (2010); 3(1) 1-5.
- [23] Shapiro, S.S., Wilk, M.B. "An analysis of variance test for normality (complete samples)". *Biometrika.* (1965); 52 (3-4): 591-611. JSTOR 2333709. MR 0205384. p. 593. doi:10.1093/biomet/52.3-4.591.
- [24] RMD "The Shapiro-Wilk and related tests for normality. (2022); Retrieved 2022-06-16, [http://eric.univ-lyon2.fr/~ricco/cours/cours/Test\\_Normalite](http://eric.univ-lyon2.fr/~ricco/cours/cours/Test_Normalite).
- [25] Owusu-Apenten, R. and Vieira, E. Food Additives. In *Elementary Food Sciencel*. Springer, (2022); Cham: pp. 355-376).
- [26] Khedr, A.A. Antiulcer protective activity of Gum Arabic (*Acacia senegal*) in adult rats. *Bulletin of the National Nutrition Institute of the Arab Republic of Egypt*, (2017); 49: 1-28.
- [27] Taghizadeh, F., Hosseinimehr, S.J., Zargari, M., Karimpour M.A., Mirzaei, M. and Talebpour Amiri, F. Alleviation of Cisplatin-induced hepatotoxicity by gliclazide: Involvement of oxidative stress and Caspase-3 activity. *Pharmacology Research and Perspectives*, (2021); 9(3), e00788.
- [28] Diab, A.A., Zahra, M. H., Hendawy, A.A., Hamza, R.Z. and Mekky, G.A. Hepatoprotective effect of curcumin and vitamin C against Cisplatin induced oxidative stress and toxicity in albino rats. *Journal of American Science*, (2014);10 (11): 37-48.
- [29] Saleh, R.M., Awadin, W.F., Elseady, Y.Y. and Waheish, F.E. Renal and cardiovascular damage induced by Cisplatin in rats. *Life Sci J.*, (2014); 11(2): 191-203.
- [30] Yilmaz, H.R., Sogut, S., Ozyurt, B., Ozugurlu, F., Sahin, S., Isik, B. and Ozyurt, H. The activities of liver adenosine deaminase, xanthine oxidase, catalase, superoxide dismutase enzymes and the levels of malondialdehyde and nitric oxide after Cisplatin toxicity in rats: protective effect of caffeic acid phenethyl ester. *Toxicology and Industrial Health*, (2005); 21(1-2): 67-73.
- [31] Voruz, F., Vuilleumier, A., Migliorini, D., Nacher-Soler, G., Rousset, F., De Maesschalck, T. and Senn, P. Cisplatin-induced ototoxicity in 401 consecutive Geneva cancer patients. (2022).
- [32] Lu, Y. and Cederbaum, A.I. Cisplatin-induced hepatotoxicity is enhanced by elevated expression of cytochrome P450 2E1. *Toxicological Sciences*, (2006); 89(2): 515-523.

- [33] Elhassaneen, Y.A. The effect of charcoal broiled meat consumption on antioxidant defence system of erythrocytes and antioxidant vitamins in plasma. *Nutrition Research*, (2004); 24 (6): 435-446.
- [34] Al-Malki, A.L., and Sayed, A.R. Thymoquinone attenuates Cisplatin-induced hepatotoxicity via nuclear factor kappa- $\beta$ . *BMC Complementary and Alternative Medicine*, (2014); 14(1): 1-8.
- [35] Basuony, M., Tousson, E., Massoud, A. and Saad, S. Preventive/ameliorative effects of ginseng aqueous extract on Cisplatin-induced hepatic and renal injuries. *Asian Oncology Research Journal*, (2020); 13: 31-39.
- [36] Basuony, M., Hafez, E., Tousson, E., Massoud, A., Elsomkhraty, S. and Eldakamawy, S. Beneficial role of Panax ginseng root aqueous extract against Cisplatin induced blood toxicity in rats. *Am. J. Biol. Chem.*, (2015); 3(1): 1-7.
- [37] Yousef, M.I., Saad, A.A. and El-Shennawy, L.K. Protective effect of grape seed proanthocyanidin extract against oxidative stress induced by Cisplatin in rats. *Food and Chemical Toxicology*, (2009); 47(6): 1176-1183.
- [38] Tveden-Nyborg, P., Birck, M.M., Ipsen, D.H., Thiessen, T., Feldmann, L.B., Lindblad, M.M., Jensen, H.E., Lykkesfeldt, J. Diet-induced dyslipidemia leads to nonalcoholic fatty liver disease and oxidative stress in guinea pigs. *Transl Res.* (2016); 168:146-160.
- [39] Ellatif, M. A., El Karib, A. O., Dallak, M., Eid, R. A., Al-Ani, R. and Haidara, M. A. Vitamin E protects against hepatocyte ultrastructural damage induced by high fat diet in a rat model of pre-diabetes. *Int. J. Morphol.*, (2018); 36(4):1350-1355.
- [40] Elshama, S.S., Abdlla, M. and Mohamed A. Role of natural antioxidants in treatment of toxicity. *J. Toxicol. Analysis*, (2018); 1: 1-7.
- [41] Gamal El-din, A.M., Mostafa, A.M., Al-Shabanah, O.A., Al-Bekairi, A.M. and Nagi, M.N. Protective effect of Gum Arabic against acetaminophen induced hepatotoxicity in mice. *Pharmacological Research*, (2003); 48(6): 631-635.
- [42] Najla, O.N, Kholoud, S.R., Hoda, E.A.F. and Hanan, S.A. "Protective role and antioxidant activity of Arabic Gum against trichloroacetate-induced toxicity in liver of male rats," *Indian Journal of Animal Research*, (2017); 51(2): 303-309.
- [43] Elshama, S.S. The protective role of Arabic Gum in the treatment of toxicity. *Toxicol. & Res.*, (2018); 1(1): 27-29.
- [44] Hamid, M., Yassin, A., Abdelnasir, A., Khalid, M., Mohammedsalih, I., Nagmeldin, A., Omer, A., Juma, A., Hassan, M., Hejair, I., Tam our, E. and Tagwa, N. Protective Effect of Gum Arabic on Liver Oxidative Stress, Inflammation and Apoptosis Induced by CCl<sub>4</sub> in vivo. *EAS J. Nurs. Midwifer*, (2021); 3(1): 27-34.
- [45] Nofal, A.E. and Fayad, R. Enhanced Effect of Resveratrol on Hepatocellular Carcinoma of Rats Treated with 5-Fluorouracil. *Advances in animal and veterinary sciences*, (2021); 9(11):1978-1988.
- [46] Nofal, A., Okdah, Y., Rady, M. and Hassaan, H. Gum Acacia attenuates cisplatin toxic effect spermatogenesis dysfunction and infertility in rats. *International Journal of Biological Macromolecules*, (2023); 240. 124292. 10.1016/j.ijbiomac.2023.124292.
- [47] Phuyal, N., Jha, P. K., Raturi, P. P. and Rajbhandary, S. Total Phenolic, Flavonoid Contents, and Antioxidant Activities of Fruit, Seed, and Bark Extracts of *Zanthoxylum armatum* DC, *The Scientific World Journal*, (2020).
- [48] Kumar, S. and Pandey, A. K. Chemistry and biological activities of flavonoids: an overview," *The Scientific World Journal*, (2013); 16: 1-7.
- [49] Valanciene, E., Jonuskiene, I., Syrpas, M., Augustiniene, E., Matulis, P., Simonavicius, A., Malys, N. *Advances and Prospects of Phenolic Acids Production, Biorefinery and Analysis. Biomolecules.* (2020); 10(6):874.
- [50] Sá, C., Oliveira, A.R., Machado, C., Azevedo, M., Pereira-Wilson, C. Effects on Liver Lipid Metabolism of the Naturally Occurring Dietary Flavone Luteolin-7-glucoside. *Evidence-Based Complementary and Alternative Medicine*, (2015); 9.