

## SINGLE IMPLANT-RETAINED MANDIBULAR OVERDENTURES REINFORCED WITH POLYETHER ETHER KETONE AND METALLIC FRAMEWORKS: A COMPARATIVE STUDY OF CRESTAL BONE LOSS AND PROSTHETIC MAINTENANCE

Hana'a G. Youssef<sup>\*</sup>  and Yasser M. Shawky<sup>\*</sup> 

### ABSTRACT

**Statement of problem:** Studies have shown the efficacy of mandibular overdentures retained by a single implant for oral rehabilitation of edentulous patients. The primary complication of these overdentures has been reported to be their high incidence of midline fracture. The addition of a reinforcing framework to the acrylic denture base can prevent fractures and ensure the durability of overdenture treatment. **Purpose:** The aim was to compare crestal bone loss and prosthetic maintenance events of single implant-retained mandibular overdentures (SIMO) reinforced by Polyetherether ketone (PEEK) and metallic frameworks after a two-year follow-up period.

**Materials and methods:** Twenty-two edentulous patients received SIMOs containing reinforcing frameworks. The resin patterns of the frameworks were printed using CAD/CAM. The printed castable resin frameworks were processed using either PEEK by injection molding technique (PEEK group) or cobalt-chromium metal by conventional casting techniques (Metal group). Crestal bone loss was evaluated using digital radiography and prosthetic maintenance events were analyzed. The follow-up period was two years after overdenture loading.

**Results:** There was a slight increase in crestal bone loss in the Metal group compared to the PEEK group, but the difference was statistically insignificant. There was no overdenture fracture, crack, or abutment fracture in either group. No significant differences in prosthodontic maintenance events between the two groups were noted.

**Conclusions:** Based on the limitations of this study, it is concluded that the crestal bone loss and prosthetic maintenance results of SIMO reinforced with a PEEK framework were comparable to those of metal reinforcement.

**KEYWORDS:** Single implant overdenture, reinforcement framework, polyether ether ketone, metal.

\* Associate Professor, Removable Prosthodontic Department, Faculty of Oral and Dental Medicine, Misr International University, Cairo, Egypt

## INTRODUCTION

The single-implant-retained mandibular overdenture (SIMO) has been suggested as a less traumatic prosthetic solution for older people who have lost all of their teeth or those who have functional difficulties with conventional dentures. This treatment option would improve their chewing function and quality of life.<sup>1-3</sup> Studies that compared the SIMO to the two-implant-retained overdenture showed a comparable positive effect of both treatments on crestal bone loss. Furthermore, the SIMO had a slightly better treatment cost and implant survival than the two-implant-retained overdenture.<sup>4-7</sup> If the efficiency of the treatment is validated by long-term research, the SIMO might become the standard of treatment for older edentulous patients.<sup>8-10</sup>

However, one of the most common SIMO limitations is denture base fracture. Clinical studies have reported denture fracture as a common complication that occurs in SIMO.<sup>11-13</sup> The fracture occurs primarily in the anterior region of the overdenture, where the presence of an attachment system reduces the thickness of the overdenture base.<sup>14-16</sup> The high concentration of compressive stresses in the vicinity of the attachment housing may lead to SIMO fractures.<sup>17-22</sup> Furthermore, the single mandibular implant becomes a fulcrum for the overdenture during its functional movement, resulting in denture base deformation and subsequent fracture.<sup>23-25</sup> The incidence of SIMO fractures has been reported in a number of clinical studies, as denture base fracture has been found within the first year of SIMO use. Other studies have found that 50% of SIMO fractures occurred during three years of denture insertion.<sup>17-19</sup>

Overdenture base reinforcement is a technique for distributing stresses more evenly and minimizing fracture incidence. A cast metal framework incorporated into the acrylic resin was shown to be efficient in minimizing denture base strains.<sup>14,16,22</sup>

Moreover, the metal reinforcement distributes stresses more widely across the edentulous ridge, reducing functional deformation and supporting tissue problems.<sup>15,24,25</sup> On the other hand, metal frameworks require complicated construction steps and may cause hypersensitivity. Additional problems that may occur with cobalt-chromium (Co-Cr) frameworks are the esthetic display of metal through the denture base and the metallic taste.<sup>23,26</sup>

Polyether ether ketone (PEEK) is a semi-crystalline thermoplastic biomaterial that is the most widely used high-impact polymer in medical applications. It has excellent mechanical characteristics, as well as high biocompatibility, wear resistance, and chemical stability. It is also characterized by a low plaque affinity, a white color, good chemical and thermal resistance, a low specific weight, polishability, and high bond strength.<sup>27-29</sup> PEEK's low modulus of elasticity (4 GPa) and bone-like elasticity provide a cushioning effect and lower stress transmission to the abutment teeth as compared to rigid metal frameworks. Therefore, PEEK is an alternative to metal and ceramic materials.<sup>30-33</sup>

Studies have suggested using PEEK as a framework material for metal-free removable prostheses,<sup>34-36</sup> all on four restorations,<sup>37</sup> implant overdentures,<sup>38</sup> and occlusal splints.<sup>39</sup> Dental implant fixtures,<sup>40</sup> implant abutments and healing abutments, have also been made using this material.<sup>41,42</sup> Some studies have shown that PEEK can be employed as an overdenture attachment retainer.<sup>43-46</sup> PEEK can be fabricated using either CAD/CAM or injection molding.

PEEK has been used as a metal substitute for removable dental prostheses.<sup>47-49</sup> PEEK frameworks combined with acrylic resin denture bases and teeth were previously recommended as an alternative to metallic frameworks in a clinical report.<sup>50</sup> Also, it was used for the construction of metal-free removable partial dentures which eliminated the unacceptable esthetic display of metal clasps

as well as the metal taste and hypersensitivity to metallic frameworks.<sup>36, 50</sup> Metal clasps, which have an unacceptable appearance, the risk of metallic taste and allergy reactions in certain people, are no longer an issue with these lighter, metal-free PEEK removable partial dentures. After three years of fatigue testing, PEEK clasps had greater retention forces at steeper undercuts and bulkier clasp designs than metal clasps.<sup>50</sup> Another study described the fabrication of a maxillary obturator using PEEK frameworks. Patients were more satisfied with retention, aesthetics, and comfort with PEEK than with conventional prostheses.<sup>51,52</sup>

PEEK can also be used as a reinforcement framework for removable dental prostheses. It has been utilized as a framework material for full dentures to reduce denture deformation, which is the cause of midline fractures.<sup>53</sup> Kortam et al 2020<sup>54</sup> used PEEK as a reinforcing framework for palatless four-implants supported maxillary overdenture and recommended its usage with favorable clinical and radiological outcomes. Muhsin et al.2019<sup>28</sup> investigated milled or thermo-pressed PEEK and polymethyl methacrylate (PMMA) denture bases. According to the findings of this in-vitro study, PEEK denture bases outperformed resins in terms of tensile and impact strength. As a consequence of its resistance to crack concentration and denture breaking, PEEK may be offered as an appropriate material for denture bases.

Reviewing the scientific literature showed that there aren't many studies that evaluate whether using reinforcing frameworks for SIMO can reduce the incidence of denture fractures. Grageda, Rieck 2014<sup>14</sup> described in a clinical report an edentulous patient who used a maxillary complete denture opposed by SIMO reinforced with a metal framework for two years without any problems. Amaral et al 2018<sup>55</sup> compared stress distribution in reinforced SIO with or without Co-Cr framework at the denture base between canines. They concluded

that the framework reduced the stress across the front of the prosthesis by 62% compared to the overdenture without a framework. This might lessen the fracture incidence of the prosthesis.

Amaral et al 2019<sup>16</sup> described a technical approach that included the use of Co-Cr frameworks in the front area of the mandibular overdentures prior to the patient receiving a single mandibular implant. Pinheiro et al 2021<sup>22</sup> investigated patient satisfaction, masticatory performance, maximum bite force, masseter thickness, and the prosthetic maintenance events of SIMOs strengthened by metallic frames throughout a two-year follow-up study. ELshaboury et al 2020<sup>56</sup> compared the clinical deformation of SIMO denture bases reinforced with PEEK to metal frameworks.

Moreover, there is a scarcity of research comparing the outcomes of SIMO reinforced with PEEK versus metal frameworks. Hence, the objective of the current study was to compare crestal bone loss, and prosthetic maintenance events of SIMO reinforced with PEEK and metallic framework after a two-year follow-up period. The null hypothesis stated that following a two-year follow-up period, there would be no difference in crestal bone loss and prosthetic maintenance of SIMO strengthened with PEEK versus metallic framework.

## **MATERIALS AND METHODS**

### **Participants selection and study design**

This study was conducted on a group of twenty-two completely edentulous patients (14 males and 8 females) with an average age of 61 (ranging from 55 to 67 years). The patients were chosen from the Removable Prosthodontic Department's outpatient clinic. The following inclusion criteria guided the selection of the patients: complete denture wearer complaining of a loose mandibular denture, had bone height in the anterior mandibular

area that permitted implant installation without the requirement for bone augmentation (determined by panoramic radiography), accepted to be treated with SIMO, and agreed to a follow-up period. Exclusion criteria include: a physical condition that will constitute a hindrance for implant surgery; a history of pre-prosthetic surgery; radiation or chemotherapy in the head or neck area; smoking habits; and uncooperative patients.

Based on a previous study<sup>57</sup>, it was determined that 18 subjects would yield a statistically significant difference with 80% power and 5% error probability. The final sample consisted of 22 edentulous patients, given the expected loss rate of 25%. Calculation of the sample size was done using G Power program (University of Düsseldorf, Düsseldorf, Germany). Simple random numbers generated by Excel (a Microsoft software) were used to divide the participants into two groups. After a balanced randomization procedure, a non-significant difference was found in baseline characteristics between the two groups.

PEEK group: patients were rehabilitated with SIMOs that were reinforced by PEEK frameworks.

Metal group: patients were restored with SIMOs that were reinforced by metal frameworks.

The selected patients were informed about the surgical and prosthodontic procedures. The study was conducted according to Helsinki guidelines for ethics and was authorized by a local ethical review board to ensure the protection of the participants. After an explanation of the study procedures, all recruited participants signed an informed consent form. CONSORT (Consolidated Standards of Reporting Trials) guidelines were followed.

### **Surgical and prosthetic procedures:**

The patients' existing mandibular dentures were assessed and their fit was adjusted. Duplication of the mandibular dentures was performed to construct

transparent acrylic resin radiographic stents with a hole at the proposed implant site. The radiographic stents were placed on the dental surveyor in a zero-tilt position. Then the hole was filled with acrylic resin and shaped with the pilot drill, which was mounted into the surveyor to create an acrylic channel at the proposed implant location. After polymerization, the acrylic channel was packed with a gutta-percha marker.<sup>58,59</sup> The stent was inserted in the patient's mouth, and cone-beam CT (CBCT, I-CAT Vision, Imaging Sciences International, Hatfield, PA, USA) of the implant site was obtained. To convert the radiographic stent into a surgical stent, the gutta-percha was taken out of the acrylic channel.

Using a flapless approach, an implant 12 mm long and 3.6 mm in diameter (Superline, Dentium Co. Ltd., Korea) was implanted in the anterior midline region with the help of a surgical stent. The cover screw was then tightened onto the implant. The mandibular denture was relieved at the corresponding implant site. This was followed by relining using a tissue conditioning material (Viscogel, Dentsply). Following implant placement, a periapical radiograph was done to evaluate the implant's position. Two weeks later, the mandibular denture was relined with a soft liner. After three months healing period, implant osseointegration was assessed clinically and radiographically. The healing abutment was screwed into the implant to allow for mucosal healing. Two weeks later, the ball abutment was tightened to the implant fixture with a torque of 35 Ncm. (*Fig. 1*)

Irreversible hydrocolloid (CA 37, Cavex Holland BV, Haarlem, Netherlands) was used to make primary impressions. Over the cast, custom impression trays were created. The custom trays were border molded with modelling plastic impression compound (Impression compound type I; Kerr Corp) at the final impression appointment. Then polyether impression material (Impregum Penta, 3M ESPE St. Paul, USA) was used to make

the final impression. The definitive impression was immediately boxed and poured with a type III dental stone (Micro Stone; Whip Mix Corp) after placing the abutment analogue in it. The female housing was attached to the abutment analog on the cast. The definitive mandibular cast was scanned using a benchtop scanner (Swing, DOF, Seoul, Korea), then the scan was exported to the designing software (Blender 2.78, Amsterdam, the Netherlands) to create the virtual model. The reinforcing framework in this model was designed to cover the crest of the ridge and the attachment and extends between the canines. It had a thickness of 1 mm, a relief space of 1 mm from the cast, and tissue stops for the framework on both sides. A second relief space was made above the attachment assembly to give the ball-housing attachment assembly enough vertical space in the framework. (*Fig. 2*)

The framework design was saved as a standard triangulation (STL) file format. After importing the STL file into the Creation Workshop programme, a new STL file of the framework with its supporting arms was created. This was followed by importing the new STL file to the 3D printer (MOGASSAM Dent2 3D Printer, Mogassam, Cairo, Egypt) and the resin frameworks were produced using a castable resin (Next Dent® Cast, XH244N03, Vertex-Dental BV, Netherlands). (*Fig. 3*)

In the PEEK group, the printed castable resin frameworks were processed using PEEK (Bredent GmbH & Co. KG, Senden, Germany) by the injection molding technique. As PEEK was preheated at 400 °C for 20 minutes by using the injection molding unit (Thermoflex 400). Then the heated softened PEEK was injected into the mold by pressure 950 mega pascal and velocity 6 bars in 240 seconds. While in the Metal group, the printed castable resin frameworks were processed into metal frameworks by conventional casting techniques. As the frameworks were sprued, then invested (Sheravest, SHERA GmbH & Co.KG, Lemförde, Germany)

before being casted by the conventional technique. Cobalt-chromium alloy (WIRINIUM®, BEGO GmbH & Co.KG, Bremen, Germany) is used. (*Fig. 4*)

For both groups, the frameworks were then tried in the patient mouth to ensure passive fit over the attachment. After placing the framework on the definitive cast, the acrylic resin base with a wax occlusal rim was constructed. Jaw relationship was registered, definitive casts were fixed on the articulator, and the teeth were set using a lingualized occlusal scheme. The trial dentures were checked in the patient's mouth for occlusion and esthetics.

Overdentures have been processed using heat-cured acrylic resin (Vertex SR, Vertex Dental, Zeist, Netherland) with conventional compression molding using a long heat-curing cycle at 74 °C for 9 hours. The dentures were finished and adjusted intraorally. Using a direct pick-up procedure, the attachment housings were picked up intraorally on the fitting surfaces of overdentures. The excess acrylic resin was removed; the occlusion was adjusted and the denture was finished then delivered to the patient. (*Fig. 5*)

Follow-up appointments were scheduled at 6-, 12-, and 24-months post overdenture loading. Patients got oral hygiene care and written oral hygiene instructions at each follow-up appointment. Outcomes assessment was done at the end of prosthetic treatment (baseline), as well as after 6 months, 12 months, and 24 months of prosthetic loading.

## **Outcomes assessment**

### ***Crestal bone loss***

The linear measurement method supplied by the digital radiography software (Digora Optima, Orion Corp/Soredex) was used to assess peri-implant crestal bone loss. Periapical radiographs were obtained using the long cone paralleling technique.

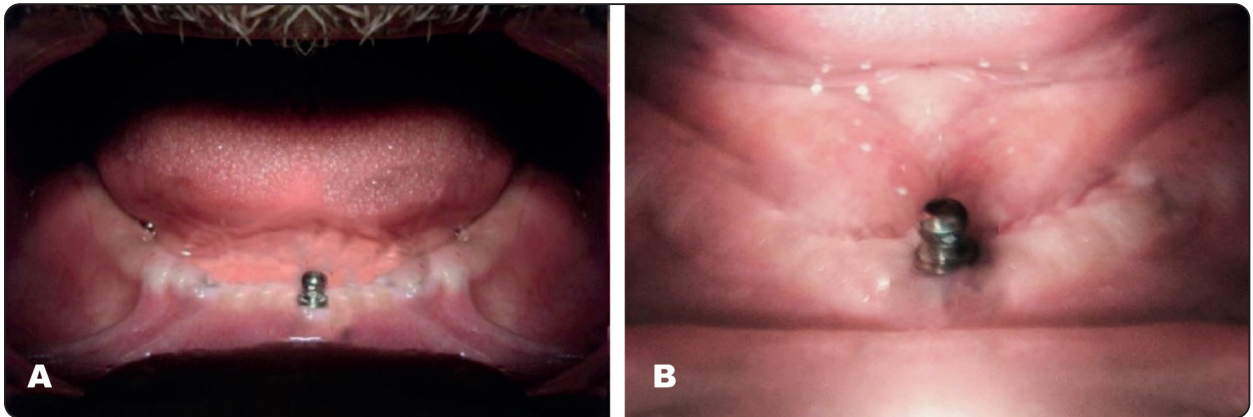


Fig. (1): Ball abutment tightened into the single symphyseal implant in (A) PEEK group (B) Metal group.

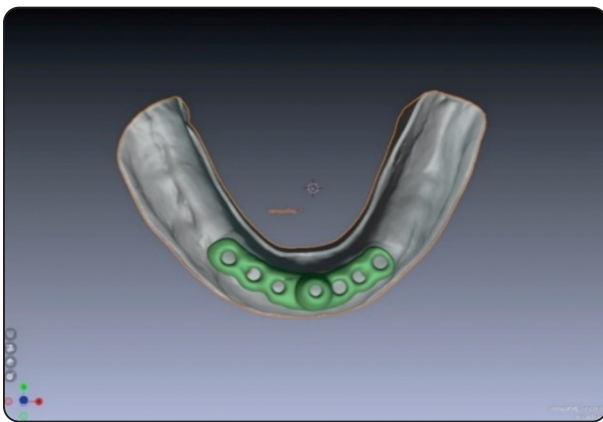


Fig. (2): The virtual model with the reinforcement framework.

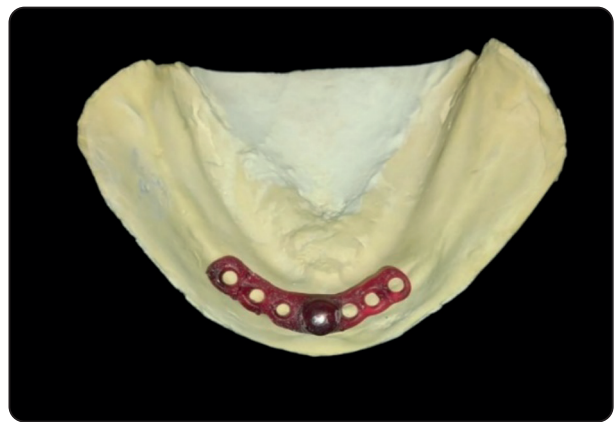

Fig. (3): Printed resin pattern of the reinforcement framework.

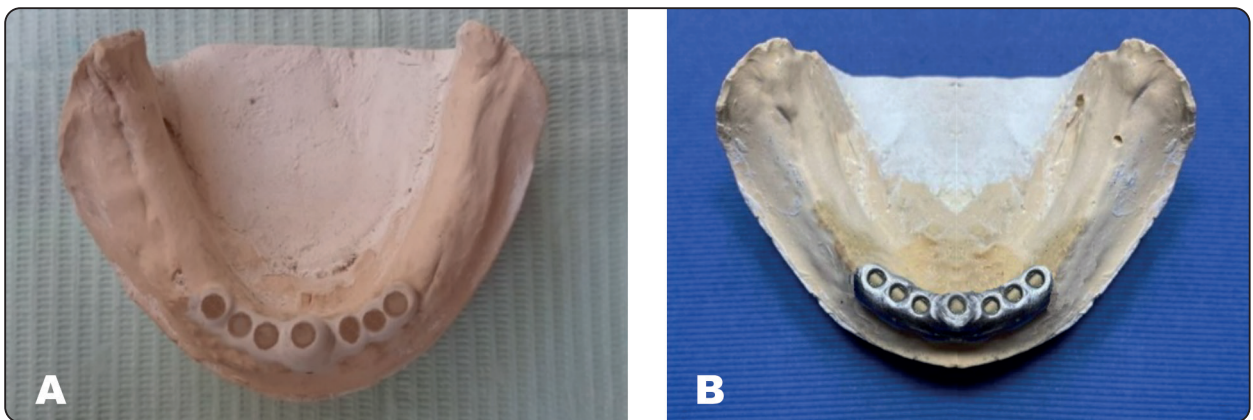


Fig. (4): The reinforcement framework on the master cast (A) PEEK (B) Metal.

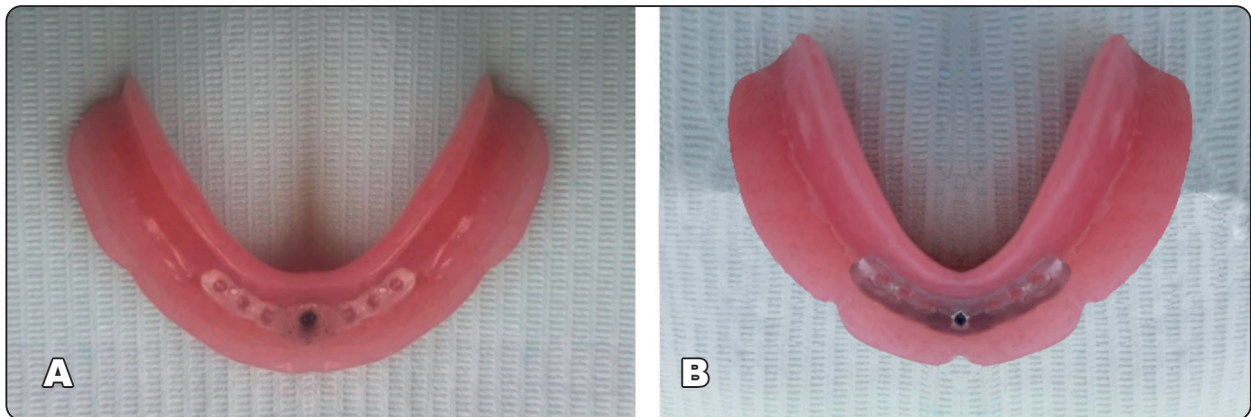


Fig. (5): The fitting surface of SIMO with the attachment housing and reinforcement framework (A) PEEK (B) Metal.

This was done using a radiographic template with a periapical film holder and an Ultra-speed film (Kodak Co., Rochester, NY, USA). Radiographs were taken using the same X-ray machine (ORIX-70s Ardet Srl, Buccinasco, Italy) with 70 kVp, 8 mA, 0.144 Kw exposure factor, and a 0.25s exposure time. The films were developed with automatic equipment (Velopexs Extra-X, Medivance, Harlesden, London, UK). Radiographs were digitized and stored on a personal computer after being scanned (HP Scanjet 3c/t, Hewlett Packard, Cernusco sul Naviglio, Milan, Italy). Measurements of crestal bone levels were made on both sides of the implant and rounded to the nearest 0.01 mm. (**Fig. 6**) To account for magnification errors, images were calibrated based on the known implant dimensions using Patil and Nimbalkar-Patil<sup>60</sup> formula. Crestal bone loss was calculated at the baseline, then after 6, 12, and 24 months by comparing the bone level at each follow-up visit to the baseline. Measurements were made by two examiners after instruction and calibration. The mean of the four trials was then calculated and recorded.

### Prosthetic maintenance events

The frequency of prosthetic maintenance events has been reported at the 12-month and 24-month follow-ups. This included all clinical procedures

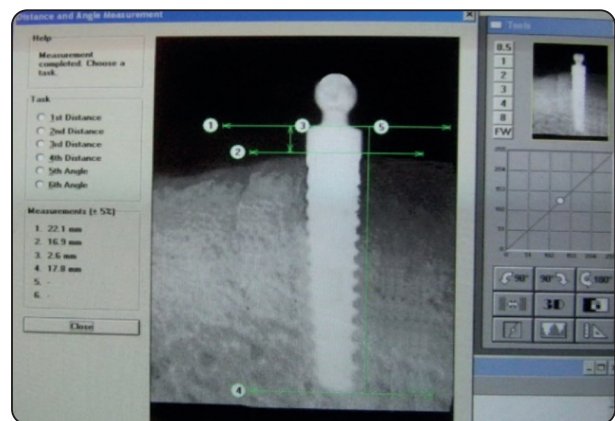

Fig. (6) Crestal bone height measurement by digital radiography.

and complications associated with the use of SIMO. The following prosthetic events were recorded: abutment fracture, abutment loosening, female housing replacement, overdenture fracture, crack of the denture base, wear of overdenture teeth and replacement, overdenture margin modification, overdenture relining, and new overdenture.

### Statistical analysis

The mean ( $\bar{X}$ ) and standard deviation (S) of crestal bone loss (mm) were expressed using descriptive statistics (mm). The number of patients (NP), the number of prosthodontic events (NE),

the incidence rate (%), and the incidence density (%) were used to describe the prosthodontic maintenance events. To compare SIMOs with PEEK and metal reinforcement, independent student t-test was utilized for crestal bone loss and Mann-Whitney test for prosthetic maintenance events. To compare observation times within groups, repeated measures ANOVA test followed by Tukey's Multiple Comparison Test was used for crestal bone loss, Friedman test followed by Dunn's Multiple Comparison test for prosthetic maintenance events. Statistical analyses were carried out using Statistical Package for Social Sciences (SPSS) for Windows (Version 20, SPSS Inc., Chicago, IL, USA). P is considered significant if  $\leq 0.05$  with a 95% confidence interval.

**RESULTS**

All study participants completed the follow-up period, and no implant loss was identified in either group.

**Results of crestal bone loss:**

The differences in crestal bone loss between the mesial and distal sides of both groups were statistically insignificant, so they are represented as an average. When comparing both groups, the mean crestal bone loss for PEEK and Metal groups was (0.52±0.07 vs 0.54 ± 0.08) at 6 months, (0.85±0.07 vs 0.87±0.04) at 12 months, and (0.98±0.06 vs 1.05 ±0.15) after 24 months. At 6, 12, and 24 months, there was a slight difference in bone loss across the groups, with the Metal group losing more bone, but the difference was statistically insignificant. A comparison of different observation periods in the

two groups demonstrated a significant (P <0.0001) increase in crestal bone loss after 12 months compared to 6 and 24 months from the baseline in both groups. (**Tab. 1**).

**Results of prosthetic complications:**

The prosthetic problems reported were very few. The results of the study revealed that there was no overdenture fracture or crack, abutment fracture, or new overdenture in both groups. Matrix replacement was the most common maintenance event, as it was (54.55%), (45.5%) in the PEEK group, and (72.73%), (27.3%) in the Metal group after 12 and 24 months, respectively. There were no significant differences in prosthodontic maintenance events between the two groups. (**Tab. 2**) (**Tab. 3**)

TABLE (1) Comparison of mean crestal bone loss between groups (PEEK and Metal) and between observation periods.

Duration	PEEK group (X ± S)	Metal group (X ± S)	T
Baseline	0.00 <sup>a</sup> ±0.00	0.00 <sup>a</sup> ±0.00	-
6 months	0.52 <sup>a</sup> ±0.07	0.54 <sup>a</sup> ±0.08	0.55
12 months	0.85 <sup>b</sup> ±0.07	0.87 <sup>b</sup> ±0.04	0.34
24 months	0.98 <sup>b</sup> ±0.06	1.05 <sup>b</sup> ±0.15	0.12
<b>A</b>	<0.0001*	<0.0001*	

*X: Mean, S: Standard deviation, A: ANOVA test, T: Student t-test, \* Significant at p ≤ 0.05. A significant difference between each two-time interval is indicated by different letters in the same column. (P≤ 0.05)*



TABLE (2) Comparison of prosthetic complications for PEEK and Metal groups after 12 months.

Prosthetic complication	PEEK group (n=11)		Metal group (n=11)		P
	NP	NE	NP	NE	
Abutment fracture	0	0	0	0	-
Abutment loosening	2	2	3	3	0.651
Female housing replacement	6	6	8	8	0.408
Overdenture fracture	0	0	0	0	-
Crack of the denture base	0	0	0	0	-
Wear of overdenture teeth and replacement	1	1	2	2	0.581
Overdenture margin modification	2	2	3	3	0.651
Overdenture relining	0	0	0	0	-
New overdenture	0	0	0	0	-
Total complications	11	11	16	16	0.3027

*NP : number of patients, NE: number of events, P: Friedman, \* Significant at  $p \leq 0.05$ .*

TABLE (3) Comparison of prosthetic complications for PEEK and Metal groups from 13 months to 24 months.

Prosthetic complication	PEEK group (n=11)		Metal group (n=11)		P
	NP	NE	NP	NE	
Abutment fracture	0	0	0	0	-
Abutment loosening	1	1	1	1	0.948
Female housing replacement	5	5	3	3	0.408
Overdenture fracture	0	0	0	0	-
Crack of the denture base	0	0	0	0	-
Wear of overdenture teeth and replacement	3	3	2	2	0.651
Overdenture margin modification	4	4	4	4	0.969
Overdenture relining	1	1	2	2	0.581
New overdenture	0	0	0	0	-
Total complications	14	14	12	12	0.676

*NP : number of patients, NE: number of events, P: Friedman, \* Significant at  $p \leq 0.05$ .*

## DISCUSSION

The aim of this study was to test the null hypothesis that, after two years of follow-up, there would be no difference in crestal bone loss and prosthetic maintenance between SIMO reinforced with PEEK and metal frameworks. According to the study findings, the null hypothesis was accepted. Since the crestal bone loss and prosthetic maintenance of PEEK-reinforced SIMO had not been studied before, the results of this study could not be compared to other authors' findings.

A reinforcing metal framework is commonly used in attachment retained overdentures to reinforce the overlay prosthesis. The reduced acrylic thickness surrounding the attachment makes the prosthesis susceptible to fracture.<sup>45</sup> The addition of a grid strengthener has been shown to enhance the flexural strength of the denture base, leading to lower fracture rates.

To reinforce the mandibular prosthesis for a patient allergic to base metals, a PEEK framework within the overdenture base was advocated.<sup>61,62</sup> In the present study, CAD/ CAM designing and printing of the castable resin pattern were done to standardize the dimensions of both PEEK and metal frameworks. The selected design of the reinforcement framework was the short design, which extended between both canines, as it was reported in the literature that the reinforcement of SIMO with Co-Cr or zirconia short frameworks reduced von Mises stress and denture base deformation more than long frameworks.<sup>63</sup> A relief space of 1 mm was left between the framework and the residual ridge to allow room for the acrylic resin base. Another relief space was designed above the attachment assembly to provide sufficient vertical space in the metal framework for the ball-housing attachment assembly, and to allow for easy replacement of the retentive elements. Another relief space was designed above the attachment assembly to give enough vertical room in the metal framework for the ball-matrix attachment assembly and to facilitate the replacement of the retentive

components. Although CAD/CAM fabrication techniques for both PEEK and metal frameworks were available, injection molding for PEEK and conventional casting for metal were chosen for their lower cost and simpler laboratory steps. This is in accordance with Zoidis 2018<sup>45</sup>

When compared to the baseline, both groups showed significant progressive crestal bone loss at 12 months. This might be related to the bone remodeling process that happens following implant placement, as well as bone response to healing paired with functional stresses. After 12 months, the crestal bone loss in the PEEK group was 0.85 mm compared to 0.87 mm in the metal group. This was consistent with the findings of other studies, which found that PEEK reinforced maxillary overdenture<sup>54</sup> and PEEK all on four prostheses<sup>64</sup> were associated with (0.98) and (0.37) mm of crestal bone loss after 12 months, respectively.

The bone loss results for both groups were within the accepted range stated in the literature.<sup>65</sup> This might be attributed to the use of a reinforcing framework. This could be attributed to the use of a reinforcing framework, which more evenly distributes the stresses. This explanation could be inconsistent with Amaral et al. 2018<sup>55</sup> who evaluated the stress distribution in SIMO with and without the Co-Cr reinforcing framework and concluded that Co-Cr framework provided a better distribution of stress across the denture base.

The PEEK group's insignificant reduced crestal bone loss compared to the metal group might be due to PEEK's lower modulus of elasticity, shock absorption capabilities, and attenuation of occlusal stresses compared to Co-Cr framework reinforcements.<sup>34-37</sup> On the other hand, ELshaboury et al 2020<sup>56</sup> concluded that, respecting SIMO, metal reinforcement is preferred over PEEK reinforcement due to lower strains.

SIMO reinforcement did not appear to influence the frequency of prosthetic maintenance events reported in the literature after a 24-month

follow-up<sup>11,13,18</sup>, but it did contribute to the avoidance of catastrophic fractures. The lack of reinforced SIMO fractures during the follow-up interval was the most important finding of this study, confirming the framework's preventive function. These results are in accordance with Pinheiro et al 2021<sup>22</sup> who found that no fracture occurred after two years of using SIMO with a reinforcing framework. The reinforcing framework stopped cracks from initiating, spreading, and breaking the whole prosthesis, which led to clinical success. The most common prosthetic maintenance event was matrix exchange. Regardless of the number of implants or the type of attachments employed, studies indicate high levels of matrix exchange.<sup>1,66</sup> Because matrix systems use various materials, such as nylon and rubber nitril, the replacement time varies.<sup>1</sup> As a result of the repeated insertion and removal cycles in the mouth, the ball attachment housing may distort and wear.<sup>67</sup> Also, the frequency of matrix replacement may have increased due to denture rotation caused by the differences in height between the front and posterior areas of the mouth.<sup>18</sup>

In terms of crestal bone loss and prosthetic maintenance events, the PEEK reinforcement material achieved results comparable to metal reinforcement. However, this study had drawbacks, including a small sample size and a short assessment time. So, long-term randomized clinical trials with a large enough sample size are still needed to verify the findings, as well as evaluation of other attachment types that might exhibit varied mechanical characteristics.

## CONCLUSIONS

Based on the limitations of this study, it is concluded that:

- The crestal bone loss and prosthetic maintenance results of SIMO reinforced with a PEEK framework were comparable to those of metal reinforcement

- Reinforced SIMO did not fracture during the two-year follow-up.
- Even though the difference was not statistically significant, SIMO with a PEEK framework lost less crestal bone than SIMO with metal reinforcement.

## REFERENCES

1. Coutinho PC, Nogueira TE, Leles CR. Single-implant mandibular overdentures: Clinical, radiographic, and patient-reported outcomes after a 5-year follow-up. *J Prosthet Dent.* 2021;24:S0022-3913(21)00044-5.
2. Padmanabhan H, Kumar SM, Kumar VA. Single Implant Retained Overdenture Treatment Protocol: A Systematic Review and Meta-Analysis. *J Prosthodont.* 2020;29(4):287-297.
3. Nogueira TE, Dias DR, Leles CR. Mandibular complete denture versus single-implant overdenture: a systematic review of patient-reported outcomes. *J Oral Rehabil.* 2017; 44(12):1004-1016.
4. Walton JN, Glick N, MacEntee MI. A randomized clinical trial comparing patient satisfaction and prosthetic outcomes with mandibular overdentures retained by one or two implants. *Int J Prosthodont* 2009;22:331-9.
5. Kronstrom M, Davis B, Loney R, Gerrow J, Hollender L. A prospective randomized study on the immediate loading of mandibular overdentures supported by one or two implants; a 3 year follow-up report. *Clin Implant Dent Relat Res* 2014;16:323-9.
6. Tavakolizadeh S, Vafae F, Khoshhal M. Comparison of marginal bone loss and patient satisfaction in single and double-implant assisted mandibular overdenture by immediate loading. *J Adv Prosthodont* 2015;7:191-8.
7. Bryant SR, Walton JN, MacEntee MI. A 5-year randomized trial to compare 1 or 2 implants for implant overdentures. *J Dent Res* 2015;94:36-43.
8. Alsabeeha N, Payne AGT, De Silva RK, Swain MV. Mandibular single implant overdentures: A review with surgical and prosthodontic perspectives of a novel approach. *Clin Oral Implants Res* 2009;20:356-65.
9. Passia N, Kern M. The single midline implant in the edentulous mandible: A systematic review. *Clin Oral Investig* 2014;18:1719-24.

10. Srinivasan M, Makarov N, Herrmann FR, Müller F. Implant survival in 1- versus 2-implant mandibular overdentures: A systematic review and meta analysis. *Clin Oral Implants Res* 2016;27:63-72.
11. Gonda T, Maeda Y, Walton JN, MacEntee MI. Fracture incidence in mandibular overdentures retained by one or two implants. *J Prosthet Dent* 2010;103:178-81.
12. Mahoorkar S, Bhat S, Kant R. Single implant supported mandibular overdenture: A literature review. *J Indian Prosthodont Soc* 2016;16:75-82.
13. de Paula MS, Cardoso JB, de Menezes EEG, Nogueira TE, McKenna G, Leles CR. A prospective cohort on the incidence of fractures in single-implant mandibular overdentures. *J Dent*. 2020 ; 103:103521.
14. Grageda E, Rieck B. Metal-reinforced single implant mandibular overdenture retained by an attachment: A clinical report. *J Prosthet Dent* 2014;111:16-9.
15. Rodrigues AH, Özçelik TB, Yilmaz B, Akçimen Y. Metal reinforcement for implant-supported mandibular overdentures. *J Prosthet Dent* 2000;83:511-3.
16. Amaral CFD, Pinheiro MA, Rodrigues Garcia RCM. Reinforcement of Single Implant-Retained Mandibular Overdenture with a Cobalt-Chromium Framework before Implant Surgery. *J Prosthodont*. 2019;28(7):844-848.
17. Passia N, Wolfart S, Kern M. Ten-year clinical outcome of single implant-retained mandibular overdentures—a prospective pilot study. *J Dent*. 2019;82:63–65.
18. Nogueira TE, Oliveira Aguiar FM, de Barcelos BA, Leles CR. A 2-year prospective study of single-implant mandibular overdentures: patient-reported outcomes and prosthodontic events. *Clin Oral Implants Res*. 2018;29:541–550.
19. Harder S, Wolfart S, Egert C, et al. Three-year clinical outcome of single implant-retained mandibular overdentures - results of preliminary prospective study. *J Dent*. 2011;39:656–661.
20. Pisani MX, Presotto AGC, Mesquita MF, et al. Biomechanical behavior of 2-implant- and single-implant-retained mandibular overdentures with conventional or mini implants. *J Prosthet Dent*. 2018;120:421–430.
21. Liddel G, Henry P. The immediately loaded single implant retained mandibular overdenture: a 36-month prospective study. *Int J Prosthodont*. 2010; 23:13–21.
22. Pinheiro MA, do Amaral CF, Meira IA, Carletti TM, Câmara-Souza MB, Souza CSV, de Moraes M, Rodrigues Garcia RCM. Single implant overdenture reinforced with a metallic framework: A 2-year clinical follow-up. *Spec Care Dentist*. 2021;41(5):607-618.
23. Rached RN, de Souza EM, Dyer SR, et al: Dynamic and static strength of an implant-supported overdenture model reinforced with metal and nonmetal strengtheners. *J Prosthet Dent* 2011;106:297-304
24. Özçelik TB, Yilmaz B, Akçimen Y: Metal reinforcement for implant-supported mandibular overdentures. *J Prosthet Dent* 2013;109:338-340
25. Godoy A, Siegel SC: Simplified technique for incorporating a metal mesh into record bases for mandibular implant overdentures. *J Prosthodont* 2015;24:661- 664
26. Im SM, Huh YH, Cho LR, Park CJ. Comparison of the fracture resistances of glass fiber mesh- and metal mesh-reinforced maxillary complete denture under dynamic fatigue loading. *J Adv Prosthodont*. 2017;9(1):22-30.
27. Najeeb S, Zafar MS, Khurshid Z, Siddiqui F. Applications of polyetheretherketone (PEEK) in oral implantology and prosthodontics. *J Prosthodont Res*. 2016;60(1):12-9.
28. Muhsin SA, Hatton PV, Johnson A, Sereno N, Wood DJ. Determination of Polyetheretherketone (PEEK) mechanical properties as a denture material. *Saudi Dent J*. 2019;31(3):382-391.
29. Peng TY, Ogawa Y, Akebono H, Iwaguro S, Sugeta A, Shimoe S. Finite-element analysis and optimization of the mechanical properties of polyetheretherketone (PEEK) clasps for removable partial dentures. *J Prosthodont Res*. 2020; 64(3):250-256.
30. Najeeb S, Khurshid Z, Matinlinna JP, et al: Nanomodified peek dental implants: Bioactive composites and surface modification—a review. *Int J Dent* 2015;2015381759
31. Wiesli MG, Ozcan M: High-performance polymers and their potential application as medical and oral implant materials: a review. *Implant Dent* 2015;24:448-457
32. Najeeb S, Zafar MS, Khurshid Z, et al: Applications of polyetheretherketone (PEEK) in oral implantology and prosthodontics. *J Prosthodont Res* 2016;60:12-19
33. Han KH, Lee JY, Shin SW: Implant- and tooth-supported fixed prostheses using a high-performance polymer (Pekkton) framework. *Int J Prosthodont* 2016;29:451-454

34. Alexakou E, Damanaki M, Zoidis P, Bakiri E, Mouzis N, Smidt G, et al. PEEK high performance polymers: a review of properties and clinical applications in prosthodontics and restorative dentistry. *Eur J Prosthodont Restor Dent*. 2019;27(3):113–21.
35. Papathanasiou I, Kamposiora P, Papavasiliou G, Ferrari M. The use of PEEK in digital prosthodontics: A narrative review. *BMC Oral Health*. 2020 Aug 2;20(1):217.
36. Zoidis P, Papathanasiou I, Polyzois G. The Use of a Modified Poly-Ether-Ether-Ketone (PEEK) as an Alternative Framework Material for Removable Dental Prostheses. A Clinical Report. *J Prosthodont*. 2016 Oct; 25(7):580-584.
37. Zoidis P. The All-on-4 modified polyetheretherketone treatment approach: A clinical report. *J Prosthet Dent* 2018;119:516–521.
38. Emera RM, Altonbary GY, Elbashir SA. Comparison between all zirconia, all PEEK, and zirconia-PEEK telescopic attachments for two implants retained mandibular complete overdentures: in vitro stress analysis study. *J Dent Implant*. 2019;9:24–9.
39. Benli M, Eker Gümüř B, Kahraman Y, Gökçen-Rohlig B, Evliođlu G, Huck O. Surface roughness and wear behavior of occlusal splint materials made of contemporary and high-performance polymers. *Odontology*. 2020; 108(2):240–50.
40. Schwitalla A, Müller WD. PEEK dental implants: a review of the literature. *J Oral Implantol*. 2013;39:743–9.
41. Kaleli N, Sarac D, Külünk S, Öztürk Ö. Effect of different restorative crown and customized abutment materials on stress distribution in single implants and peripheral bone: a three-dimensional finite element analysis study. *J Prosthet Dent*. 2018;119(3):437–45.
42. Beretta M, Poli PP, Pieriboni S, Tansella S, Manfredini M, Ciccü M, et al. Periimplant soft tissue conditioning by means of customized healing abutment: a randomized controlled clinical trial. *Materials (Basel)*. 2019; 12(18):3041.
43. Mangano F, Mangano C, Margiani B, Admakin O. Combining intraoral and face scans for the design and fabrication of computer-assisted design/ computer-assisted manufacturing (CAD/CAM) polyether-ether-ketone (PEEK) implant-supported bars for maxillary overdentures. *Scanning*. 2019;2019:4274715.
44. Spies BC, Petsch M, Kohal RJ, Beuer F. Digital production of a zirconia, implant-supported removable prosthesis with an individual Bar attachment milled from polyether ether ketone: a case history report. *Int J Prosthodont*. 2018;31(5):471–4.
45. Zoidis P. Polyetheretherketone Overlay Prosthesis over High Noble Ball Attachments to Overcome Base Metal Sensitivity: A Clinical Report. *J Prosthodont*. 2018 Oct; 27(8):688-693.
46. Sharaf MY, Eskander A, Afify MA. Novel PEEK Retentive Elements versus Conventional Retentive Elements in Mandibular Overdentures: A Randomized Controlled Trial. *Int J Dent*. 2022 Feb 28;2022:6947756.
47. Ali Z, Baker S, Sereno N, Martin N. A Pilot Randomized Controlled Crossover Trial Comparing Early OHRQoL Outcomes of Cobalt-Chromium Versus PEEK Removable Partial Denture Frameworks. *Int J Prosthodont*. 2020;33(4):386-392.
48. Carneiro Pereira AL, Bezerra de Medeiros AK, de Sousa Santos K, Oliveira de Almeida É, Seabra Barbosa GA, da Fonte Porto Carreiro A. Accuracy of CAD-CAM systems for removable partial denture framework fabrication: A systematic review. *J Prosthet Dent*. 2021;125(2):241-248.
49. Negm EE, Aboutaleb FA, Alam-Eldein AM. Virtual Evaluation of the Accuracy of Fit and Trueness in Maxillary Poly (etheretherketone) Removable Partial Denture Frameworks Fabricated by Direct and Indirect CAD/CAM Techniques. *J Prosthodont*. 2019;28(7):804-810.
50. Muhsin SA, Wood DJ, Johnson A, et al. Effects of novel polyetheretherketone (PEEK) clasp design on retentive force at different tooth undercuts. *J Oral Dent Res*. 2018;5:13–25.
51. Costa-Palau S, Torrents-Nicolas J, Brufau-de Barberà M, Cabratosa-Termes J. Use of polyetheretherketone in the fabrication of a maxillary obturator prosthesis: a clinical report. *J Prosthet Dent*. 2014;112(3):680–2.
52. Harb IE, Abdel-Khalek EA, Hegazy SA. CAD/CAM constructed poly (etheretherketone) (PEEK) framework of Kennedy class I removable partial denture: a clinical report. *J Prosthodont*. 2019;28(2):e595–8.
53. Hada T, Suzuki T, Minakuchi S, Takahashi H. Reduction in maxillary complete denture deformation using framework material made by computer-aided design and manufacturing systems. *J Mech Behav Biomed Mater*. 2020;103: 103514.

54. Kortam, S. Metal versus Poly ether-ether ketone (PEEK) framework reinforcements for maxillary palateless ball retained implant overdentures. One year clinical and radiographic outcomes. *Egyptian Dental Journal*, 2020; 66 (3): 1817-1828.
55. Amaral CF, Gomes RS, Rodrigues Garcia RCM, Del Bel Cury AA. Stress distribution of single-implant-retained overdenture reinforced with a framework: A finite element analysis study. *J Prosthet Dent*. 2018;119(5):791-796.
56. ELshaboury SN, Mahanna FF, Ahmed WS, EL Waseef FA. Cobalt Chromium Vs. Peek for Reinforcing Single Implant Mandibular Overdentures: A Clinical Study of Strain Analysis. *J Dent Oral Sci*. 2020;2(3):1-12.
57. Amaral CF, Pinheiro MA, de Moraes M, Rodrigues Garcia RCM. Psychometric Analysis and Masticatory Efficiency of Elderly People with Single-Implant Overdentures. *Int J Oral Maxillofac Implants*. 2018;33(6):1383-1389.
58. DE Vico G, Ferraris F, Arcuri L, Guzzo F, Spinelli D. A novel workflow for computer guided implant surgery matching digital dental casts and CBCT scan. *Oral Implants*. 2016; 9(1):33-48.
59. Talwar N, Singh BP, Chand P, Pal US. Use of diagnostic and surgical stent: a simplified approach for implant placement. *J Indian Prosthodont Soc*. 2010;10(4):234-9.
60. Patil PG, Nimbalkar-Patil S: A radiographic measurement technique for crest bone changes related to dental implants. *J Prosthet Dent* 2015;113:350-351
61. Abdulhameed N, Roulet JF, Shen C: Acrylic reinforcement with off the shelf perforated metal plates. *Eur J Prosthodont Restor Dent* 2016;24:192-196.
62. Safaa, A., Mahanna, F., Hegazy, S. Comparison of Peri-implant Soft Tissue Changes and Retention of Zirconium Oxide Bar versus Metallic Bar Retaining Mandibular Poly- Ether- Ether- Ketone (PEEK) Overdenture. *Egyptian Dental Journal*, 2022; 68(2): 1695-1705.
63. El-Ok1 AB, Abou Neel EA. A 3-D Finite Element Analysis of a Single Implant Retained Overdenture Reinforced with Short Versus Long Frameworks. *Eur J Prosthodont Restor Dent*. 2021 May 28;29(2):103-111.
64. Malo P, de Araujo Nobre M, Moura Guedes C, Almeida R, Silva A, Sereno N et al. Short-term report of an ongoing prospective cohort study evaluating the outcome of full arch implant-supported fixed hybrid polyetheretherketoneacrylic resin prostheses and the All-on-Four concept. *Clin Implant Dent Relat Res*. 2018;20:692-702.
65. Singh S, Mishra SK, Chowdhary R. Patient satisfaction and crestal bone changes with one-piece and two-piece single implant-retained mandibular overdenture: A randomized controlled clinical study. *J Prosthodont Res*. 2022 Mar 23. doi: 10.2186/jpr.JPR\_D\_20\_00315. Epub ahead of print. PMID: 35321961.
66. Andreiotelli M, Att W, Strub JR. Prosthodontic complications with implant overdentures: a systematic literature review. *Int J Prosthodont*. 2010;23:195-203.
67. Marin DOM, Leite ARP, Oliveira Junior NM, Paleari AG, Pero AC, Compagnoni MA. Retention force and wear characteristics of three attachment systems after dislodging cycles. *Braz Dent J*. 2018;29:576-582.