

## A COMPARATIVE STUDY OF MARGINAL BONE LOSS USING THREE DIFFERENT ATTACHMENTS FOR TWO-IMPLANT SUPPORTED MANDIBULAR OVER DENTURE. RANDOMIZED CLINICAL TRIAL

Amr Salah El Din Gomaa\*<sup>ID</sup>, Inass AboElmagd\*\*<sup>ID</sup> and Ramy Moustafa Ali\*\*\*<sup>ID</sup>

### ABSTRACT

**Aim:** The purpose of this study was to compare the effect of using two different designs of magnet attachment (flat and dome) and ball and socket attachment on crestal bone around implant in implant –supported Mandibular Overdenture.

**Materials and methods:** Fifteen completely edentulous patients were randomly divided into three groups. Group I for two implants supported overdenture with flat magnetic attachment, Group II for two implants supported overdenture with dome magnetic attachment and Group III for two implants supported overdenture with ball and socket attachment. Implant fixtures were inserted surgically at the canine area. Each patient was recalled two months after implant insertion for superstructure placement. Marginal Bone loss around the implant were measured at 0, 3, 6 months and 12 months after over denture pickup and all data were gathered and tabulated.

**Results:** A statistically significant difference for bone resorption was showed among (3 m), (6 m) and (12 m) where ( $p<0.001$ ) for each attachment groups. By comparison for three groups at (3 m), (6 m) and (12 m) a statistically significant difference was showed among (Ball and socket) and each of (Dome magnet) and (Flat magnet) attachments where ( $p<0.001$ ) and no statistically significant difference was showed among (Dome magnet) and (Flat magnet) attachments.

**Conclusion:** The current study concluded that the dome magnet attachment and flat magnet attachment transmit less stress to the implants when compared to ball attachments resulting in reducing the crestal bone loss amount around the dental implants when used in implant supported mandibular over denture.

**KEYWORDS:** Implant Overdenture, flat magnet attachment, ball and socket attachments, CBCT, dome magnet attachment and marginal bone loss.

\* Associate professor of Removable Prosthodontics, Faculty of Dentistry- fayoum University

\*\* Department of oral and Maxillofacial radiology, Faculty of dentistry, Fayoum university, Fayoum, Egypt

\*\*\* Lecturer, Department of Removable Prosthodontics, Faculty of Dentistry, Fayoum University, Fayoum, Egypt.

## INTRODUCTION

Regarding academy of prosthodontics opinion any dental removable prosthesis that rests and covers one or more natural remaining teeth, natural tooth roots or implants is referred to as an overdenture.<sup>(1)</sup>

Patients with severely resorbed edentulous mandibular arch usually suffering with their conventional complete dentures. their main complains are reduction of idael retention and stability of their mandibular dentures, which directly affects aesthetics, chewing efficiency and speech, moreover reduction of denture stability will result in dragging of the denture over tissue during function result in tissue irritation and hyperplasia.<sup>(3)</sup>

The implant overdenture is considered the best treatment option when the patient has considerable alveolar bone resorption, poor implant distribution or alignments, unfavorable ridge relation, great interarch space or when finance limited the use of fixed prosthesis.<sup>(4)</sup>

No definitive contraindication has been defined to overdenture treatment, however, it has been recommended that certain systemic condition of the patients considered high risk factor for implant placement and also may increase failure rate.<sup>(3)</sup>

Usually the lower complete denture retention is considered an important question for the patient and the dentist as the resorption of alveolar ridge and many muscle attachments to the mandible. The treatment option of using oral implants does not always permit an adequate number of implants placement for fixed prosthesis construction due to insufficient anatomical alveolar bone height, health restrictions and financial limitations. Two dental implants placement in the cuspid regions anterior to the mental foramina on either side will increase the stability and retention of complete dentures in edentulous patients. Ball and socket attachments for implant-supported overdentures are more successful, provide better retention, stability for the

denture and increase comfort and confidence while speaking and masticating.<sup>(5)</sup>

The magnetic attachment is delivered as keeper and magnet. The magnet material is either aluminum-nickel-cobalt alloy, rare-earth alloy such as cobalt-samarium alloy or neodymium-iron-boron alloy or new laser-welded magnets which has high magnetic force and strength, usually dome and cylindrical shaped magnet is attached to the overdenture fitting surface while the keeper is a ferromagnetic metal ,screwed over the implant fixture moreover the magnetic attachment is dislodged simply by lateral force, that reduce stress that keep the implant out from damage. Many types of magnetic attachment are introduced for the clinical usage. Magnet flat type with thin disk form produce good cushion and retention force with a gap 0.4 mm between resin cap and magnet assembly produce effective shock-absorbing effect on the fixture of dental implant.<sup>(6)</sup>

With the help of the radiographic analysis, after abutment connection to the implants high rate of bone resorption occur. During normal functional loading minimal marginal bone changes observed. One of successful criteria for implant therapy include 0.5 mm marginal bone loss during healing period.<sup>(7)</sup>

Successful treatment of ISOD depends on the prosthetic space evaluation, At least 13–14 mm interarch space is needed for bar-supported overdentures, regarding ball attachment at least 10–12 mm is required and 8.5 mm for locator. The result of insufficient space includes inadequate occlusal vertical height, fracture of teeth near the attachments position, separation of the attachments from the denture and the prosthesis fracture.<sup>(8)</sup>

This study undertaken to compare between the marginal bone loss in implant- supported mandibular overdentures with three different attachment systems, i.e., ball-socket, dome shaped and flat shaped magnetic attachments.

## MATERIAL AND METHODS

Fifteen completely edentulous patients were selected from the Outpatient clinic, Prosthodontic Department, Faculty of Dentistry, Fayoum University with the following inclusion criteria: 1) All patients have atrophy of mandibular ridge, 2) healthy gingiva, 3) Sufficient bone height in the interforaminal area (at least 10 mm available bone height). Exclusion criteria include: 1) patients with radio therapy for head and neck, hepatic disease and bleeding disorders, 2) Patients with diabetes mellitus and osteoporosis that may affect implant osseointegration.

All patients signed informed consents and the study plan was approved by local ethical committee. The patients were randomly assigned into three groups. By generating a random number in excel spread sheet was given to each participant and the numbers were kept in sealed envelopes. A blind dental assistant randomly assigned the patients number into three groups using simple random method. Group I included five participants for two implants supported overdenture with flat magnetic attachment, Group II included five participants for two implants supported overdenture with dome magnetic attachment and Group III included five participants for two implants supported overdenture with ball and socket attachment.

Extra and intraoral examinations were carried out in conjunction with the necessary laboratory tests, such as a blood picture and blood glucose level. A preoperative panoramic radiograph (1:1) was used to rule out patients with remaining roots or atypical pathological conditions, and a diagnostic Cone Beam Computed Tomography (CBCT) image was taken with i-CAT to assess bone volume (width) at the intended implant site (canine region).\*

All of the processes of the acrylic complete denture construction were completed, starting with

the primary impression, final impressions, jaw relation, try-in for artificial teeth, and final delivery of the acrylic complete denture. The denture was copied into a clear acrylic resin model, which was then scanned using a CBCT scanner and the DICOM data was processed to create an STL file.

For each patient, standard CBCT scanning methods were used, with a standardized setting of 90 kV, 6.3mA, a 12 s exposure time, and size of voxel 0.2 mm. The radiologist who did the scan was the same. The generated CBCT was loaded into the implant planning software for virtual planning of the implant surgical guide\*\*.

The virtual implant was implanted in the most appropriate spot (at the carnie area) according to the surgical and prosthetic design using digital image segmentation. The planned virtual template was converted to STL files and printed on a three-dimensional printer\*\*\*. The guided surgical metal sleeves were manually pushed into the corresponding knot.

All patients should be given a broad range antibiotic \*\*\*\* 24 hours prior to surgery and non-steroidal anti-inflammatory analgesics \*\*\*\*\* every 12 hours following surgery for the next 5 days.

The surgical technique of implant (Tiologic, Dentaurem, Germany) size 3.4x13 mm insertion was done until completion of the osteotomy sites, then the platform was made using a counter sink drill at a speed of 1000 RPM and a torque of 30-45 N/cm, and The countersink drill's actual diameter is 0.1mm greater than the fixture platform's. In order for the top level of the fixture to be 0.5mm below the marginal crestal bone level, the countersink drilling depth was increased. The implant was threaded

\*\* Blue Sky Plan® V3, Blue Sky Bio, n® LLC, USA .

\*\*\* Form 1+, Form labs, USA.

\*\*\*\* Augmentin 1g- Beecham MUP.

\*\*\*\*\* Ibuprofen, Knoll, Ludwigshafen, Germany.

\* Planmeca promax 3D classic, Planmeca, Finland.

until the implant top flushes with the alveolar bone surface. (Fig 1&2)

After confirming Ossteointegration, two months after implant insertion, all cases were sorted randomly into three equal groups. An implant tissue supported mandibular overdenture with a flat magnetic attachment was given to Group I, an implant tissue supported mandibular overdenture with a dome magnetic attachment was given to Group II and an implant tissue supported mandibular overdenture with a ball and socket attachment was given to Group III.

For each group; fixture position was detected with the help of the surgical stent; a diagnostic probe was inserted through the hole of the surgical stent to make a bleeding point on the mucosa covering the proposed implant site.

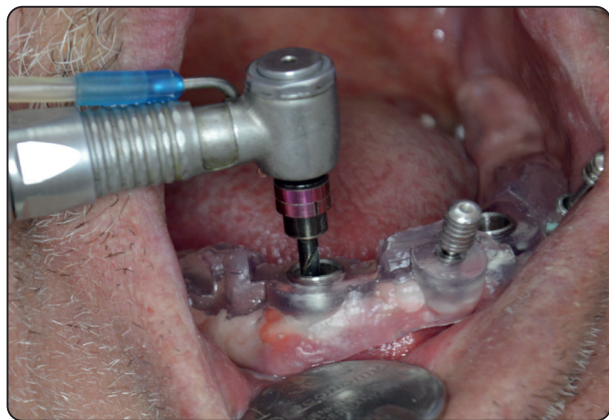

Fig. (1): Osteotomy preparation

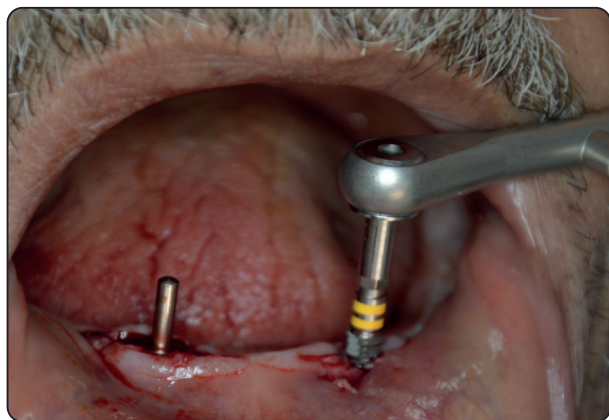


Fig. (2): Parallism between the two osteotomy

The implant covering screw was exposed in the oral cavity using a surgical punch, then the covering screw was unthreaded, the healing abutment was threaded into the implant and tightened well with a hex screw driver. After a healing period of 1 week the healing abutments were removed, and the field was thoroughly cleaned with sterile saline solution and then the mucosal thickness was assessed using graduated periodontal probe so that the attachments abutments with a proper collar height was chosen and then the abutment was threaded into the implant (figure 3,4&5).

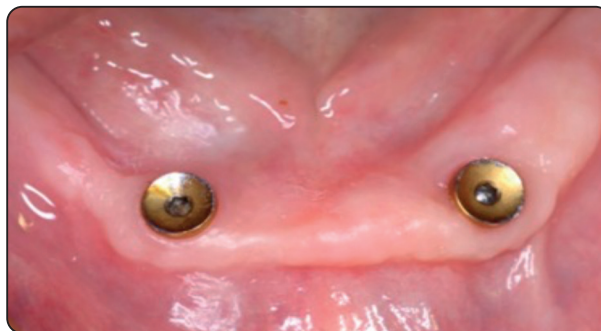


Fig. (3): flat magnet attachments

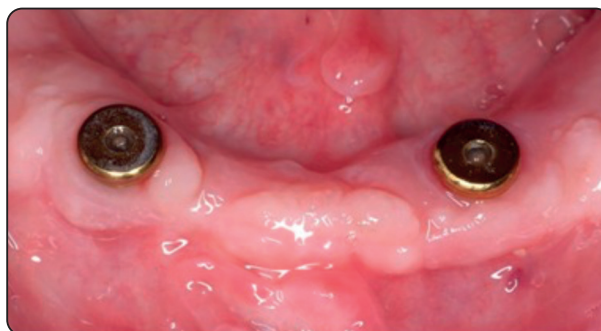

Fig. (4): dome magnet attachments

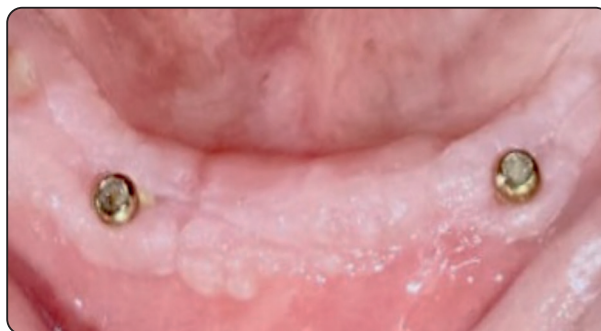

Fig. (5): ball and socket attachments

First the nylon ring was inserted on the attachment to block the under cuts and prevent the acrylic resin from entering this areas during pickup procedure, then the metal housing was inserted on the attachment above the nylon ring, then the place for the attachment was marked on the complete denture and then widened so that the metal housing fits smoothly and the complete denture can be inserted and removed without any interference with the metal housing.

Mix of chair side hard relining material\* was done then when the resin reach due stage, priming with the acrylic monomer to the prepared part in the complete denture then start packing the acrylic, place in the patient mouth and asked to close in centric occlusion firmly until polymerization had taken place then after setting of the acrylic resin, excess material was removed and then finishing and polishing were done. (Figure 6)

Patients in all groups received CBCT immediately after loading of the implant, 3 months, 6 months and 12 months after insertion of implant supported overdenture. Marginal bone level was evaluated for each implant. The attachment shoulder was selected as reference point, the measurements of the first bone contact mesially and distally was calculated from the CBCT using Invivo 5 software (version 5.3 Anatomage, San Jose, USA) were used for the assessment of crestal bone level, peri-implant bone quality and bone surrounding implant apices. The radiographs were compared with base line radiographs. The assessment of the marginal bone level at mesial and distal side of fixture on the radiographs is calculated. The amount of the alveolar bone resorption on mesial and distal sides of the implant was measured as follow: Average bone resorption = (Mesial bone resorption + Distal bone resorption /2). (Figure 7)

\* Reline Hard: Surrey precision dental. Southampton, Hampshire, UK.

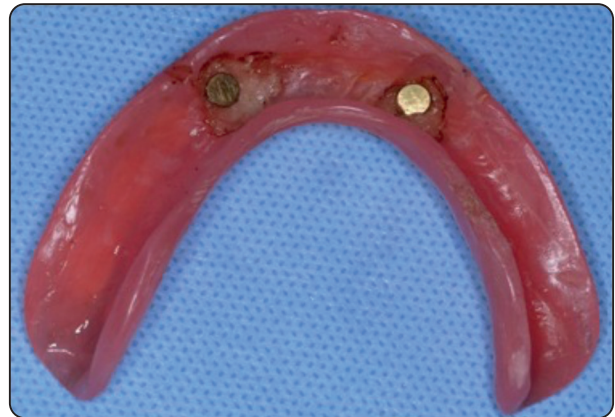

Fig. (6): Keeper in place

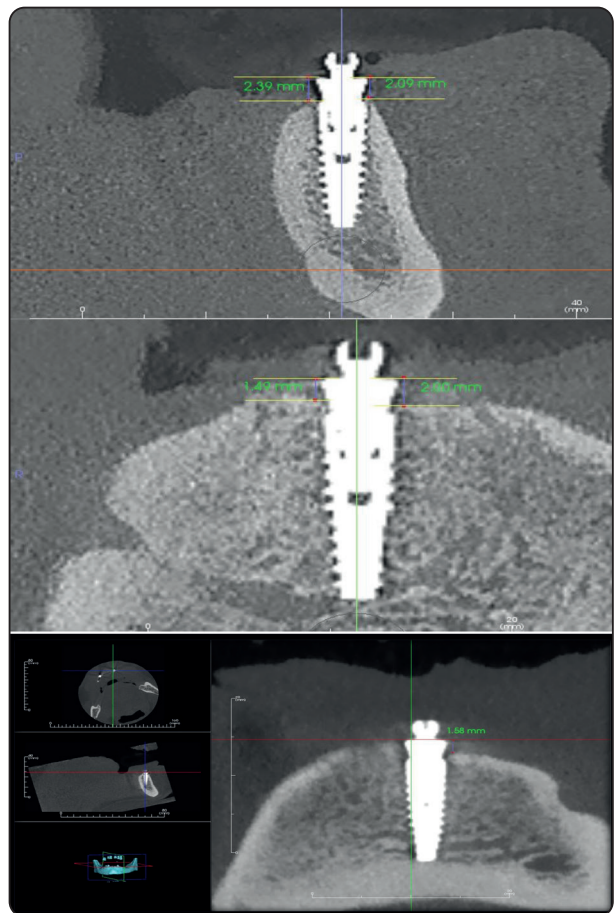


Fig. (7): Measurements of marginal bone loss

### Statistical analysis

Statistical analysis was done by IBM® SPSS® Statistics Version 20 for Windows. The mean and standard deviation of amount of Bone resorption over time where measured. The data were explored

for normality using Shapiro-Wilk tests, and showed parametric (normal) distribution. Repeated-measure ANOVA with Tukey post hoc test was used to compare between the three groups at the different time points. The significance level was set at  $P \leq 0.05$ .

## RESULTS

To differentiate between the three groups in related samples Paired sample t-test was used. One-way ANOVA followed by Tukey post hoc test was used to compare between more than two groups in non-related samples. Two-way ANOVA was used to test the interactions between different variables.

The significance level was adjusted at  $P \leq 0.05$ . Statistical analysis was done by IBM® SPSS® Statistics Version 20 for Windows

### Bone resorption in mm:

#### i) *Effect of time:*

##### A) **Dome magnet attachment:**

A statistically significant difference was showed among (Baseline), (3m), (6m) and (12m) where ( $p < 0.001$ ). Also, a statistically significant difference was showed among (3m) and each of (6m) and (12m) where ( $p < 0.001$ ).

A statistically significant difference was showed among (6m) and (12m) where ( $p < 0.001$ ).

##### B) **Flat magnet attachment:**

A statistically significant difference was showed among (Baseline), (3m), (6m) and (12m) where ( $p < 0.001$ ). Also, a statistically significant difference was showed among (3m) and each of (6m) and (12m) where ( $p < 0.001$ ).

A statistically significant difference was showed among (6m) and (12m) where ( $p < 0.001$ ).

##### C) **Ball and socket attachment:**

A statistically significant difference was showed among (Baseline), (3m), (6m) and (12m) where ( $p < 0.001$ ). Also, a statistically significant difference

was showed among (3m) and each of (6m) and (12m) where ( $p < 0.001$ ). A statistically significant difference was showed among (6m) and (12m) where ( $p < 0.001$ ).

#### ii) *Effect of groups:*

##### A) **Baseline:**

There wasn't statistically significant difference among (Dome magnet), (Flat magnet) and (Ball and socket) attachments where ( $p = 0.928$ ).

##### B) **After 3m:**

A statistically significant difference was showed among (Ball and socket) and each of (Dome magnet) and (Flat magnet) attachments where ( $p < 0.001$ ).

No statistically significant difference was showed among (Dome magnet) and (Flat magnet) attachments where ( $p = 0.927$ ).

##### C) **After 6m**

A statistically significant difference was showed among (Ball and socket) and each of (Dome magnet) and (Flat magnet) attachments where ( $p < 0.001$ ).

No statistically significant difference was showed among (Dome magnet) and (Flat magnet) attachments where ( $p = 0.932$ ).

##### D) **After 12m**

A statistically significant difference was showed among (Ball and socket) and each of (Dome magnet) and (Flat magnet) attachments where ( $p < 0.001$ ).

No statistically significant difference was showed among (Dome magnet) and (Flat magnet) attachments where ( $p = 0.403$ ).

### Two-way ANOVA:

In the table (2), Data shows the results of the Two-way ANOVA analysis of the different variables interaction. The results approved that different groups had a statistically significant effect. Also, time had a statistically significant effect. The interaction which happened among the three variables had a statistically significant effect.

TABLE (1) The mean, standard deviation (SD) values of bone height formation of different groups.

Variables	Bone height resorption						p-value
	Dome magnet attachment		Flat magnet attachment		Ball and socket attachment		
	Mean	SD	Mean	SD	Mean	SD	
Baseline	1.23	0.15	1.25	0.16	1.23	0.14	<b>0.928ns</b>
After 3m	1.56	0.26	1.60	0.16	2.28	0.17	<b>&lt;0.001*</b>
After 6m	1.96	0.18	1.94	0.13	2.63	0.10	<b>&lt;0.001*</b>
After 12m	2.23	0.16	2.30	0.09	2.84	0.07	<b>&lt;0.001*</b>
<i>p-value</i>	<b>&lt;0.001*</b>		<b>&lt;0.001*</b>		<b>&lt;0.001*</b>		

\*; significant ( $p < 0.05$ ) ns; non-significant ( $p > 0.05$ )

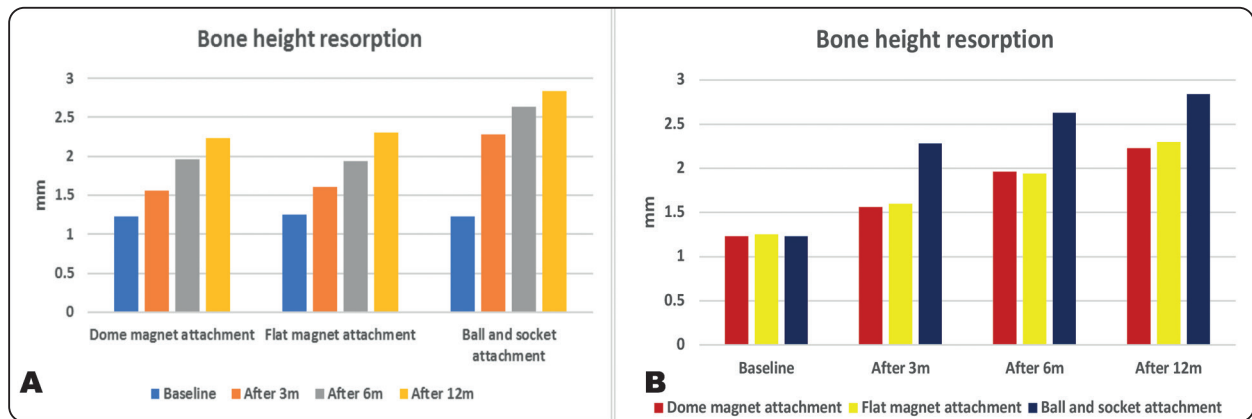


Fig. (8): Bar chart representing bone height resorption for different groups and different time periods

TABLE (2) Results of Two-way ANOVA for the effect of different variables.

Source	Type III Sum of Squares	df	Mean Square	F	Sig.
Corrected Model	26.796	11	2.436	101.804	0.000
Intercept	353.434	1	353.434	14770.366	0.000
Groups	4.986	2	2.493	104.177	0.000
Time	20.002	3	6.667	278.636	0.000
Groups * Time	1.809	6	0.301	12.597	0.000
Error	2.010	84	0.024		
Total	382.240	96			
Corrected Total	28.806	95			

df: degrees of freedom = (n-1), \* Significant at  $P \leq 0.05$

## DISCUSSION

Dental rehabilitation with traditional removable prosthesis for atrophic edentulous mandible may lead to a lot of problems to the patients: as there is no sufficient retention of the prosthesis, implant supported overdenture may provide a very satisfactory long term results.

An overdenture retained by one of the attachment systems linked to implants can be an effective, simple and less treatment in many edentulous cases.<sup>(9)</sup>

Denture retention and patient satisfaction can be improved by the magnet attachment<sup>(10&11)</sup>. Magnetic attachments in comparison to ball and socket attachments have the advantageous of being shorter in height and do not need a certain path of insertion, especially with minimal space between two arches or in abutments which isn't parallel to each other<sup>(12)</sup> or the presence of physical disabilities of the patients<sup>(13)</sup>.

For comfortable feeling and ease of cleaning, it has been noted that higher than 30% of dental patients go through the magnetic attachment. Meanwhile, Cheng et al. showed that masticatory efficiency, the satisfaction level and comfort level can be improved by using magnetic attachment.<sup>(10&11)</sup>

The ball and socket attachment result in higher marginal bone loss than dome-magnetic and flat-magnetic attachments, this may happen due to the difference in the transfer load mechanism of different attachments<sup>(14)</sup>.

The stress level of the dome-magnetic attachments is reduced by permitting the denture to move to a certain limit, while the ball type attachments result in higher marginal bone loss is more frequently occurred under loading with oblique manner than loading vertically around the implant<sup>(15)</sup>.

Ball attachments exhibit more marginal bone loss when compared with the flat-magnetic and dome-magnetic attachments; This is due to easy

lateral movement of two parts of magnetic attachments<sup>(16,17)</sup>.

Magnetic attachment with dome-shaped configuration has lower lateral stress compared to normal magnetic attachment. The dome-shaped has the advantageous of reducing the amount of lateral stresses which affect peri-implant bone by the allowance in the rotational movement effect, which may reduce the harmful loads towards the fixture of the implant<sup>(15)</sup>.

## CONCLUSION

The current study concluded that the dome magnet attachment and flat magnet attachment transmit less stress to the implants when compared to ball attachments resulting in reducing the amount of crestal bone loss around the implants when used in implant supported mandibular overdenture.

These results showed that the magnet attachment can be selected for two-implant supported overdentures should be done with certain caution.

## REFERENCES

1. Campbell SD, Cooper L, Craddock H, Hyde TP, Nattress B, Pavitt SH, Seymour DW. *J Prosthet Dent.*;118(3):273-280. (2017).
2. M.ELsayed, N.Agha, A.Habib. Retention and stability of Implant-Retained Mandibular Overdentures using Different Types of Resilient Attachments: An In Vitro Study, *Int.J.Oral Maxillofac.Implants*:10. 4544.(2016).
3. R.R. Regis, T.R. Cunha, M.P. Della Vecchia, A.B. Ribeiro, C.H. Silva Lovato, R.F. DeSouza, A randomised trial of a simplified method for complete denture fabrication: Patient perception and quality, *J.Oral Rehabil.* Doi:10.1111/joor.12063(2013).
4. Kutkut ,A. et al. A systemic review of studies comparing conventional complete denture and implant retained overdenture. *J Prosthodontics.Res.*62,1-9(2018).
5. Eunjee Lee and Soo-Yeon Shin The influence of the number and the type of magnetic attachment on the retention of mandibular mini implant overdenture *J Adv Prosthodontics*:14-21( 2017).



6. Narendra J Gutlapalli , Deepika M Reddy, Haritha Mikkilineni Implant-supported overdentures J N J Dent; 84(3):24-7(2013).
7. Ghozezi R, Alikhasi M, Siadat MR, Siadat H, Sorouri M. A radiographic comparison of progressive and conventional loading on crestal bone loss and density in single dental implants: A randomized controlled trial study. J Dent (Tehran) ;10:155–63 (2013).
8. Nitish Varshney, Sakshi Gupta, Sumit Aggarwal, Shalabh Kumar, M Sadish, and Mohsin Khan Hard and soft-tissue evaluation of bar-clip, ball-socket, and kerator attachments in mandibular implant overdenture treatment: An in vivo study J Indian Prosthodontics Soc ; 19(4): 296–306 (2019).
9. Kohnke P. Canonsburg, PA, Ansys Theory Reference Manual, Ansys Inc., a comparison between two low profile attachments for implant mandibular overdentures ;journal of genetic engineering and biotechnology 12(1):45-53(2014).
10. Ellis J. S., Burawi G., Walls A., Thomason J. M. Patient satisfaction with two designs of implant supported removable overdentures; ball attachment and magnets. Clinical Oral Implants Research. ;20(11):1293–1298. (2009)
11. Cheng T., Sun G., Huo J., He X., Wang Y., Ren Y.-F. Patient satisfaction and masticatory efficiency of single implant-retained mandibular overdentures using the stud and magnetic attachments. Journal of Dentistry. ;40(11):1018–1023. (2012).
12. Ceruti P., Bryant S. R., Lee J. H., MacEntee M. I. Magnet-retained implant-supported overdentures: review and 1-year clinical report. Journal of the Canadian Dental Association;76:p. a52. (2010).
13. Allen P. F., Ulhuq A., Kearney J. Strategic use of a new dental magnet system to retain partial and complete overdentures. European Journal of Prosthodontics and Restorative Dentistry;13(2):81–86. (2005)
14. Maeda Y., Yang T. C., Kinoshita Y. Development of a self-adjusting magnetic attachment for implant overdentures. International Journal of Prosthodontics ;24(3):241–243. (2011).
15. Aunmeungtong W., Khongkhunthian P., Rungsiyakull P. Stress and strain distribution in three different mini dental implant designs using in implant retained overdenture: a finite element analysis study. Journal of Oral Implantology. 2016;9(4):202–212. (2016).
16. Leem H.-W., Cho I.-H., Lee J.-H., Choi Y.-S. A study on the changes in attractive force of magnetic attachments for overdenture. Journal of Advanced Prosthodontics. ;8(1):9–15. (2016).
17. Yang T.-C., Maeda Y., Gonda T., Kotecha S. Attachment systems for implant overdenture: influence of implant inclination on retentive and lateral forces. Clinical Oral Implants Research. ;22(11):1315–1319. (2011).