

# PASSIVITY OF SCREW-RETAINED IMPLANT-SUPPORTED PEEK FRAMEWORKS USING SEGMENTED VERIFICATION JIGS VERSUS CONVENTIONAL JIGS-FREE TECHNIQUES UTILIZING OPEN-TRAY IMPRESSION PROCEDURES: 2 years clinical & radiographic outcomes

Original  
Article

*Mostafa Helmy Mostafa Ahmed , Enas Taha Ibrahim Darwish*

*Assistant Professor Prosthodontics Department-Faculty of Dentistry*

*Cairo University*

## ABSTRACT

**Purpose:** This comparative study aimed to assess if there was a difference in clinical & radiographic outcomes of a maxillary screw-retained implant-supported prosthesis constructed from PEEK regarding the effect of utilizing the segmented verification jig technique.

**Material and methods :** In this clinical investigation, fourteen patients with edentulous maxillary ridges carefully chosen having adequate amounts and qualities of bone. There were two groups of patients; Group I (seven patients) received an Implant-supported screw-retained full arch maxillary prosthesis with a delayed functional loading protocol utilizing 6 implants, where, an open-tray impression technique was applied and the prosthesis PEEK without utilizing verification jig, while Group II (seven patients) received same prosthesis BUT with segmented verification jig technique. The radiographic outcomes measured at the time of prosthesis insertion, 6 months, one year & two years, respectively & clinical outcome represented as patients' satisfaction measured utilizing a customized chart of the questionnaire (VAS).

**Results :** The several repetitions of the two groups were compared using the ANOVA test, which was also used to examine the changes over time within each group. Pair-wise comparisons made using Tukey's post-hoc test where the ANOVA test was significant. Clinical patients' satisfaction was measured using a visual analogue scale (VAS) and a separate t-test for a direct comparison of the two groups. Different intervals were significant for each group, with a p-value of 0.001.

**Conclusion:** Achieving optimal passivity of the PEEK framework claimed through segmented verification jig manuver developed an advantageous response in terms of radiography outcomes as well as patient satisfaction.

**Key Words:** Dental implant, Verification jigs, Screw-retained Prosthesis, Delayed functional loading, PEEK frameworks.

**Received:** 9 October 2022, **Accepted:** 12 December 2022.

**Corresponding Author:** Mostafa Helmy Mostafa Ahmed ,Associate Professor at prosthodontic partment-faculty of dentistry-cario universty , **Tel :** 0228123618, **Mobile:** 01001817812 , **E-mail:** mostafa.helmy@dentistry.cu.edu.eg  
**ISSN:** 2090-097X, July 2022, Vol. 13, No. 3

## INTRODUCTION

The advanced dental modality to restore an edentulous maxilla and improve oral rehabilitation is done through dental implants [1], however, many problems may be associated with implants treatment when such prosthesis doesn't fit probably in the implants or abutments leading to misfit of the prosthesis and marginal gap [2] eventually resulting in an unwelcome amount of tension at the bone-implant contact and between implant components, such as screw-joint connections [3- 4], even if it doesn't seem to prevent dental implants from osseointegrating if the framework isn't passive [5], complications include screw-loosening, screw-fracture, and occlusal errors become present as a result. [6- 8]

The achievement of passive fit is a crucial requirement for screw-retained implant prostheses, and all impression procedures lead to varying degrees of master cast inaccuracy [9], Additionally, due to material dimensional

variations and/or any errors in the casting process, equipment, and fabrication-related errors, the prosthesis may not fit properly during laboratory construction. [10]

A lot of medical professionals recommended employing verification jigs to increase the precision of the master cast. [11] According to numerous authors, prosthetic management with four or six implants and a fixed, screw-retained restoration is a workable approach. The all-on-four and all-on-six techniques reduce cantilever length by placing implants in the distal areas. The maxillary dental arch could be safely restored using these techniques. [12]

The most prevalent technique for implant-supported restorations is the usual use of metallic frameworks. The black metal framework, however, maintains its natural aesthetics. A new paradigm in the replacement of the all-ceramic framework for aesthetic purposes emerged recently. The PEEK (Bio-Hpp) framework material used in implant

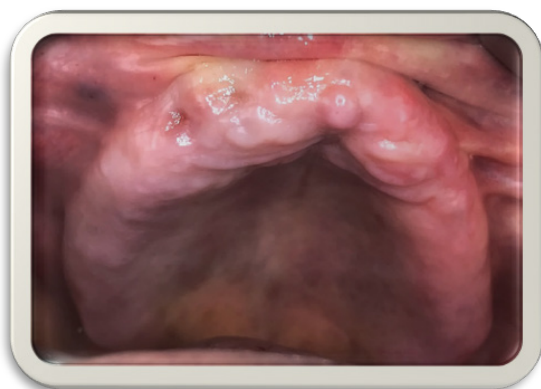restorations has various benefits; its elasticity modulus is resembling that of bone, reducing bone-related rotation during loading. Shock-absorbing, metal-free repair, reduced plaque buildup, and no corrosion are further benefits. [13]

In screw-retained implant-supported complete arch restorations, polymer-based frameworks using polyether-ether-ketone (PEEK) material have emerged as a reliable alternative. Additionally, the restoration of entire arch cases using prefabricated composite veneers enables an attractive result close to that of individual ceramic veneering. [14]

*The null hypothesis was that there will be no significant difference in outcomes between the two groups, over the whole investigation period.*

## MATERIAL AND METHODS

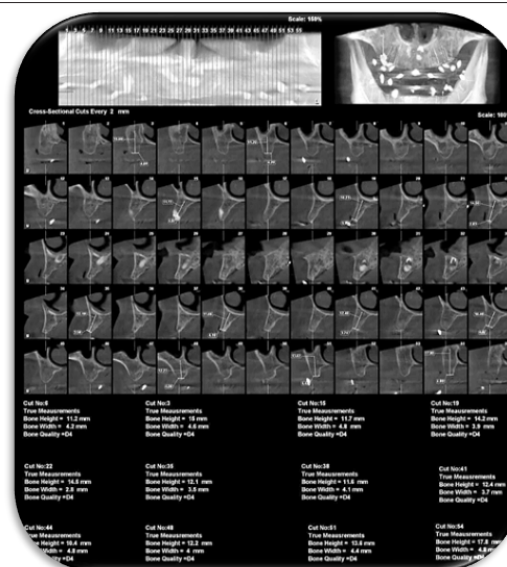
14 patients were chosen from Cairo University's Faculty of Oral and Dental Medicine's outpatient prosthodontic department clinic. All Patients were selected for the current study according to specified inclusion criteria; Ages ranged from 45-65 years with completely edentulous maxillary arches. (Figure 1)



**(Figure 1):** Patient with completely edentulous maxillary arches.

All patients went through diagnostic preoperative cone beam computer tomography (CBCT) to measure the height and width of the remaining alveolar bone anterior to the maxillary sinus. (Figure 2)

Patients exhibited maxillo-mandibular relationship Skeletal Angle's class I with normal occlusion and with good oral hygiene. Patients were also selected systematically free from any diseases that affect bone healing around the implants (e.g., uncontrolled diabetes or osteoporosis), and free from harmful habits such as smoking, clenching and bruxism finally the cooperative participants were recommended in this current study.



**(Figure 2):** Diagnostic preoperative cone beam computerized tomography (CBCT).

Patients exhibited maxillo-mandibular relationship Skeletal Angle's class I with normal occlusion and with good oral hygiene. Patients were also selected systematically free from any diseases that affect bone healing around the implants (e.g., uncontrolled diabetes or osteoporosis), and free from harmful habits such as smoking, clenching and bruxism finally the cooperative participants were recommended in this current study.

All patients were knowledgeable about the treatment plan and asked for approval on it with written consent forms according to the ethical principles stated in the Helsinki Declaration (<https://www.wma.net>) signed by the patient himself, as well as the principles of the Institute ethical committee-Cairo University.

All patients went through total maxillary rehabilitation by screw-retained prosthesis with six implants installed with PEEK (polyether ether ketone) framework, applying a delayed loading protocol.

### Construction of try-in maxillary denture

Upper and lower primary impressions were taken using alginate impression material\*, according to the manufacturer's instruction, then poured to obtain a diagnostic cast over which acrylic resin special trays were constructed.

casts were mounted on a simple hinge articulator aided by a Tentative inter-occlusal wax record. Subsequently, the occlusal relationship between the upper and lower teeth was thoroughly examined.

\*Cavex alginate, dust-free, high consistency, Holland.

Final impressions were made by two-step rubber base impression material\*, according to the manufacturer's instructions. The classic wax-wafer method was used to record the centric jaw relation after master casts were produced and made. The upper cast was mounted using a face bow record, while the lower cast was mounted using the recorded centric jaw relation record, both on a semi-adjustable articulator. Following the placement of the maxillary teeth, the Try-in stage was conducted as usual. Each patient's maxillary trial-denture base was duplicated, and radiographic stents were made from a radio-opaque substance.

Cone beam computed tomography scans (CBCT scans) were done through a cone beam CT machine\*\* (CBCT, I-CAT Vision). Where each patient was told to bite on some cotton to have their jaws separated far enough. Finally, a DICOM file of the final image was obtained. The final images were processed using image processing software (Blue-sky implant software) \*\*\*

It is important to note that all laboratory procedures were carried out in the same laboratory by the same dental technician. Pre-surgically, the patient was instructed to care about oral hygiene measures and take a prophylactic antibiotic preoperatively to control the infection. Amoxicillin-clavulanate 625 mg was prescribed 24 hours before the surgery as one tablet every 8 hours, and patients were asked to continue the antibiotic for one week after surgery to guard against any possible infection. Also, an anti-inflammatory and an analgesic drug were given. field block anesthesia\*\*\*\* was applied to minimize the bleeding as much as possible at the surgical site, A full-thickness mucoperiosteal flap was raised after a mid-crestal incision.

Each participant received 6 implants\*\*\*\*\* in the maxillary arch (placed in central incisors, canines & first molars regions Bilaterally), A pilot drill with a diameter of 2.3 mm, and a final drill with a diameter of 3.7 mm and a length of 11.5 mm was used to create the osteotomy sites for the 6 implants.

Using gentle finger pressure (self-tapping), the sterile implant was screwed into the desired location until resistance was encountered. The implant was adjusted to the ratchet wrench, the abutment was unscrewed from the implant fixture, and the screwing operation was then continued. When the implant is flush with the bone crest or preferably, 0.5 mm below the crestal bone level, the screwing procedure is stopped. Panoramic radiography images of the implants were acquired after placement to guarantee adequate alignment.

\*Panasil, Katzenbach, Germany.

\*\* CBCT, I-CAT Vision, CT Dent Ltd, UK.

\*\*\* Blue Sky Bio, LLC.

\*\*\*\* Ubestesin, 3M ESPE, Germany.

\*\*\*\*\* Mode Medikal Implant, İstanbul, Turkey.

### Post-surgical instructions

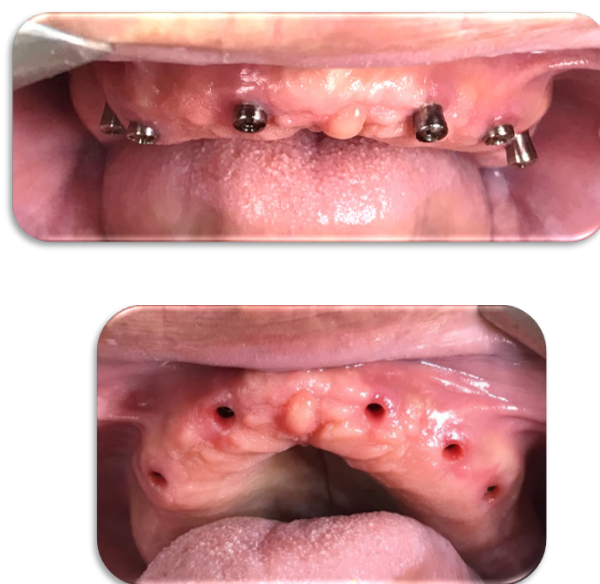The patients were given after surgery Diclofenac Sodium non-steroidal anti-inflammatory analgesic tablets\*\*\*\*\*. To relieve discomfort and swelling, it was administered as one pill, three times daily for three days. It was also advised that patients continue taking the previously prescribed antibiotic (Augmentin 1g) for 5-7 days. The following instructions were given to patients: a) Immediately after surgery, administer cold packs for 10 minutes at intervals of 10 minutes for 3-4 hours. b) To adhere to stringent oral hygiene guidelines.

### Second-stage surgery:

Six months after surgical implant installation, patients were checked to maintain oral hygiene measures and start the prosthetic phase of treatment.

A post-operative panoramic radiograph was done for the installed implants. The implants were relocated using the surgical template, and the implant cover screws were exposed by short crestal incisions under local anesthesia guided by the surgical stent.

The cover screws were loosened using the hex driver followed by an abutment connection. and healing abutments were installed for two weeks. (Figure 3)

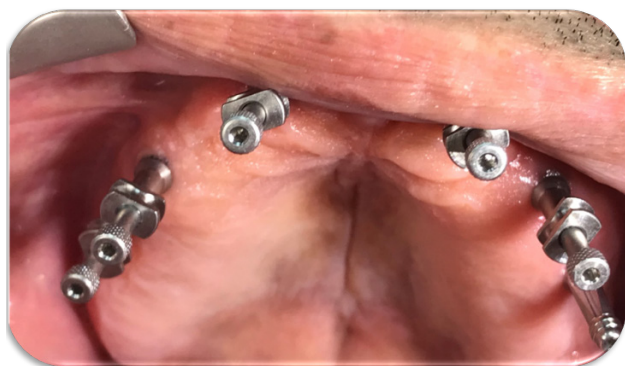

(Figure3): Healing abutments installation.

\*\*\*\*\* Voltaren, 75ml oral, NOVARTIS, Egypt.

**Restorative procedure:**


The healing abutments were unscrewed from the installed implants and transfer copings with long screws were screwed into them to take a single-step open-tray impression (implant-level impression). (Figure 4)



(Figure 4): Transfer copings with long screws.

In a plastic stock tray, holes were opened against the transfers and widened mesio-distally. Next, a single-step impression using Putty and light addition of silicon rubber foundation was taken \*, as follows: Rapid dryness of the surgical field was accomplished using pieces of gauze. Following the placement of the stock tray loaded with a putty rubber base impression material in the patient's mouth, a light-body impression material was injected around the implant necks and the transfer mounts.

After securing the tray and ensuring that everyone was seated properly, the open-tray imprint was made by manipulating the oral tissues as usual. The screwdriver was then used to remove those mounts from the implant fixtures once the entire set of the imprint material had been used. After the tray was taken out of the patient's mouth, the imprint was cleaned, dried, and examined for precision before being accurately enclosed with the transfer mounts in their proper positions. (Figure 5)



(Figure 5): Open-tray, single-step impression.

\* Panasil, Katzenbach, Germany.

**Patients grouping**

Group I, seven patients obtained an Implant-supported screw-retained full arch maxillary prosthesis with delayed functional loading protocol utilizing 6 implants, where an open-tray impression technique was applied Without utilizing verification jig during the construction of the prosthesis PEEK (polyether ether ketone) framework.

Group II, seven patients obtained an Implant-supported, screw-retained full arch maxillary prosthesis with delayed functional loading protocol utilizing 6 implants, where an open-tray impression technique was applied accompanied by segmented verification jig technique during construction of the prosthesis PEEK (polyether ether ketone) framework.

For Group I & Group II, the Single-step Open-tray impression was done with non-splinted transfer copings.

**Laboratory procedure**

In the laboratory, the impression surface surrounding the analogues was varnished with Vaseline, then a gingival mask\*\* was applied around the analogues using a plastic impression syringe loaded with it. Then the impression was poured utilizing extra-hard stone to obtain a master cast that enclosed the implant analogue part with attached abutments analogues were apparent from the cast.

A custom tray, and occlusions blocks (for Group I), and verification jigs were fabricated (for Group II) and placed inside the patient's mouth to evaluate VDO, CR, esthetics, phonetics.

**Verification jigs fabrication (for Group II)**

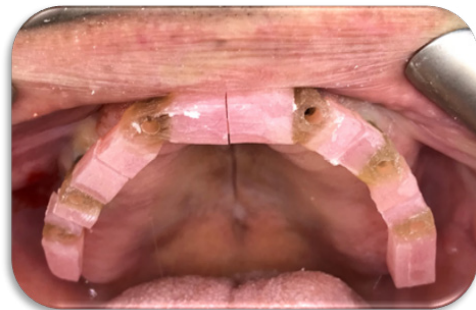
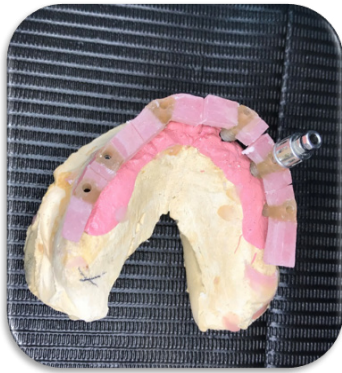Impression copings were placed on the master cast, connected to the implant analogues, and splinted with auto-polymerized acrylic resin\*\*\* by using un-waxed dental floss, after complete polymerization of the resin, the splint was finished and polished (Figure 6).

Then, sectioned using a fine disc into segmented verification jig and numbered on the master cast, each segment contains a titanium cylinder, and seated intra-orally onto the appropriate implant and tighten the guide pin. After leaving a gap that is around the thickness of a credit card, lute the parts together using an appropriate substance \*\*\*\*. (Figure 7)

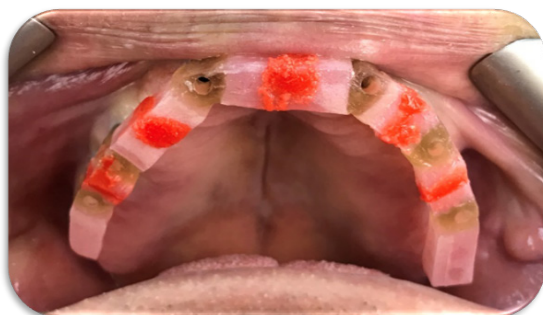
\*\* Xilgum, Lascod, Italy.

\*\*\* Pattern resin, GC America, Alsip, IL, USA.

\*\*\*\* DuraLay- Dentsply; Pattern Resin™, USA.



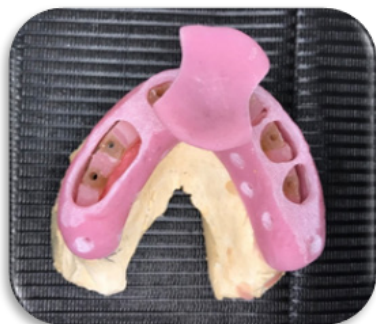(Figure 6): Segmented verification jig.



(Figure 7): Segmented verification jig luted intra-orally with low-shrinkage acrylic resin.

**Final impression procedure (for Group II)**

Check the custom impression tray\* for a proper fit (no contact with the jig or cylinders). (Figure 8) Take the final imprint with an open-tray approach using putty and light-body PVS material, being sure to inject the light-body PVS impression material underneath and around the jig.



(Figure 8): Custom impression tray with holes over the sectioned verification jig

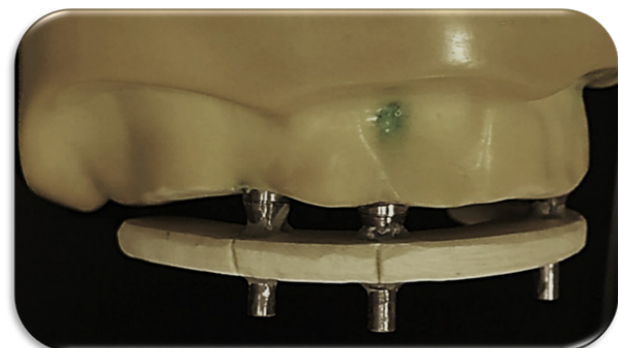
Seat the filled impression tray, ensuring the heads of the guide pins are exposed through the tray. Once the material has been set, remove the guide pins, and then remove the impression; Ensuring that, the verification jig was picked up in the impression. Then, inspect the impression for the required details & accuracy. (Figure 9) And finally, replace the healing abutments again.



(Figure 9): Final maxillary impression (for Group II).

**A continuous Glass fiber verification jig bar try-in: (for Group II)**

The master model was used to construct a glass fiber verification jig (Figure 10). The jig was made using ready-made arch form glass fiber shims\*\*. Six titanium cylinders were attached to the master model implants. The shim was perforated opposite to the 6 implants. The holes were made as wide as the diameter of the titanium cylinders with narrow gaps for the connecting resin material. Dual cure composite resin\*\*\* was used to attach the glass fiber shim to the titanium cylinders. The assembly was photocured using a laboratory light-cured chamber for 3 minutes.



(Figure 10): Glass fiber verification jig.

\* Moldano. Bayer Leverkusen, pekatray, Germany.

\*\* Trilor arch, Biolurin, Italy.

\*\*\* Ivoclar Vivadent, Switzerland.

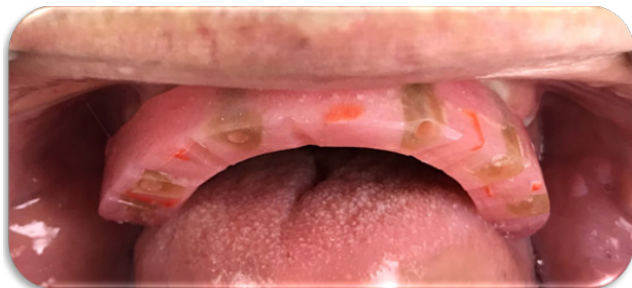Subsequently, the glass fiber jig was checked for passive seating on implants by verifying proper metal-to-metal contact at the interface between the titanium cylinder & the analogues. (Figure 11)



(Figure 11): Verification of proper metal-to-metal contact.

**Framework try-in (for both Groups)**

A precisely fabricated proprietary CAD/CAM PEEK (BIOHPP) material\* was used to create the final implant-supported prosthesis framework. Remove the healing abutments after obtaining the PEEK framework from the lab, then insert it within the patient's mouth. (Figure12), then verified the PEEK framework's passive fit, which is essential for the case's long-term success and could be done by using the single screw test as follows; Verify that each implant has a passive fit by tightening one screw (no lifting of the framework from any side- Single-screw test). For each implant, repeat the procedure after removing the screw. A final inter-occlusal record was made.

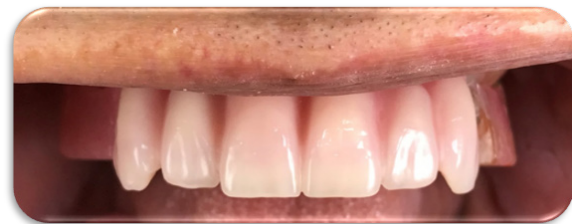

(Figure 12): Final Verification Intra-orally.

Remove the PEEK framework after ensuring passive fit, re-insert the healing abutments & send the case back to the lab so that the teeth can be set.

**Final try-in with teeth set (for both Groups)**

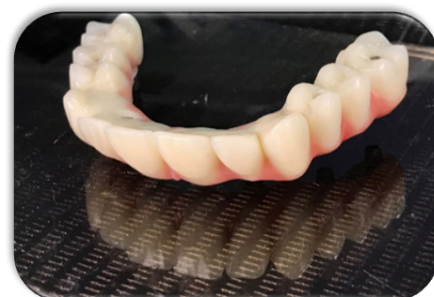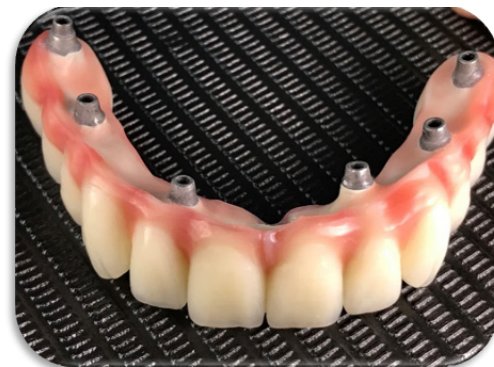Verification was done for the VDO, CR, occlusion, aesthetics, shade, tooth arrangement, phonetics, and midline. A spot grinder was used to eliminate any pressure spots that were found after using an articulating paper to look for them. Re-insert the healing abutments and send the final try-in back to the lab for processing into the final restoration once accurate verification was ensured. (Figure 13)



(Figure 13): Final try-in with teeth Intra-orally.

**Delivery of final screw-retained denture (for both Groups)**

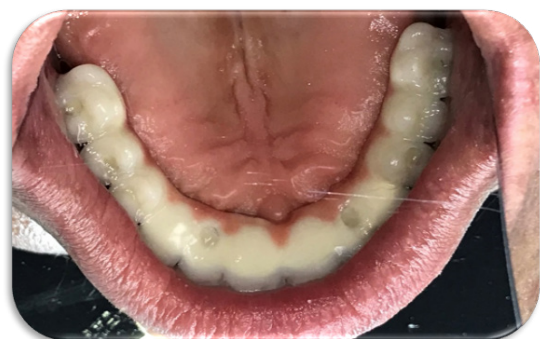The final prosthesis was placed on the supported implants after the healing abutments had been removed, and the prosthetic screws were manually tightened to the recommended torque by the manufacturer's instructions. (Figure 14)



(Figure 14): Final screw-retained maxillary prosthesis.

\* Bredent, Germany.

Screw holes were closed aesthetically, occlusion was confirmed, and any necessary adjustments were made. (Figure 15)



(Figure 15): Delivery of final screw-retained maxillary prosthesis.

A final CBCT was made for each patient, to verify prosthesis passivity radiographically. (Figure 16)

**Final adjustments and follow-up:**

Following denture insertion and instruction on how to remove it easily, patients were asked to maintain strict oral hygiene standards and to schedule a follow-up appointment every week for the first two months to address any necessary denture adjustments and/or occlusion refinements. Then, completing the follow-up periods till two years.

**Clinical & Radiographic evaluations for both groups were done. this included the following;**

**A-Patients' satisfaction (clinical outcomes):**

Patient satisfaction questionnaires were taken from both groups, based on a visual analogue scale (VAS), in which the patients gave their answers as a crossed mark

of the follow-up period, the interpretation of the satisfaction questionnaire for each patient was established at the time of insertion, six months, one year, and two years later.

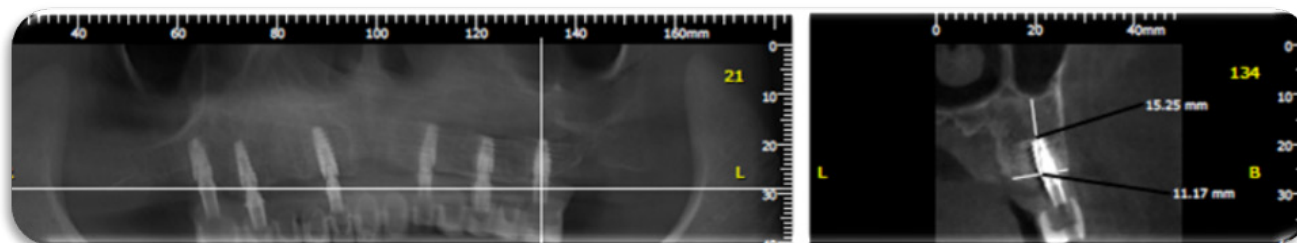
Questions were asked as follows: How do you find your prosthesis in general, how well does your prosthesis remain in place, how well can you eat with your prosthesis, how well can you talk with your prosthesis, and finally how do you find the appearance of your prosthesis? (Figure 17)

**B-Radiographic evaluation:**

Direct digital radiography utilizing the Digo-ra computerized system (Orion corporation, Soredex, Finland) was applied for making intraoral digital radiographic images to assess changes in the mesial and distal marginal bone height around the implants.

At the end of the follow-up period, the archival photographs of each patient were interpreted. At the time of implantation, six months, one year, and two years later, digital photographs of the implants were taken.

**Image Analysis:** The following was examined and assessed using the digital images: marginal measures of bone height (linear analysis) The following implant measurements were taken: the distance measured between the implant's shoulder and the alveolar ridge's crest, where a line parallel to the implant's long axis and tangential to the implant were drawn. We took, tabulated, and statistically examined the mean value of the mesial and distal values. The process was then repeated with additional implants, and the average of all implant measurements was used to calculate the mean bone height at that stage. The marginal bone height measurements rising indicates bone resorption.



(Figure 16): CBCT with the final prosthesis in place.

Question	Content
<b>Part 1: Scale from 1 (very bad) to 9 (excellent)</b>	
A	How do you find your prosthesis in general?
B	How well does your prosthesis remain in place?
C	How well can you eat with your prosthesis?
D	How well can you talk with your prosthesis?
E	How do you find the appearance of your prosthesis?

(Figure 17): Visual analogue scale (VAS).

**RESULTS**

**Sample Size Calculation:**

A study of a continuous response variable from independent control and experimental subjects was planned with 1 control(s) per experimental subject. In a previous study [14] the response within each subject group was normally distributed with a standard deviation of 0.08.

If the true difference in the experimental and control means is 0.13, we need to study 7 experimental subjects and 7 control subjects to be able to reject the null hypothesis that the population means of the experimental and control groups are equal with probability (power) 0.8. The Type I error probability associated with this null hypothesis test is 0.05.

**Regarding marginal bone height measurement**

Bone height change resembling bone resorption percentage was calculated among different time intervals for two years follow-ups according to the following formula

$$\frac{((\text{Bone Height at Base Line}) - (\text{Postoperative Bone Height}))}{((\text{Bone Height at Base Line}))} \times 100$$

Group I (patients who received screw-retained implants supported prosthesis Without verification jigs utilized) showed a gradual increase in bone resorption percentage starting at the insertion to six months, one year, and two years as (14.62 %±1.35), (31.18%±2.08) and (39.79%±3.87) respectively. While for Group II (patients who received screw-retained implants supported prosthesis with segmented verification jigs) there was also a gradual increase in bone resorption percentage starting at the insertion to six months, one year, and two years (13.49%±2.07), (22.79%±1.49) (28.92%±2.94) respectively. Using one-way analysis of variance (ANOVA) for each group followed by Tukey's post hoc test for multiple comparisons between different intervals, there was a significant difference between different intervals for each group as P-value < 0.001, as listed in **Table (I)**.

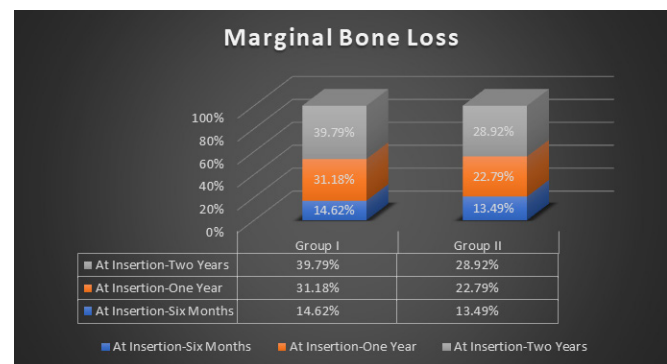
**Direct comparisons between Group I and Group II**

were performed using an independent t-test which revealed an insignificant higher value of group I (at insertion-six months) interval as P-value > 0.05. While there were significantly higher values of group I (at the insertion-one year) and (at insertion-two years) intervals as P-value < 0.0001, as listed in Table (I) & Figure (18).

**Table (1):** Multiple Comparisons of Marginal Bone Resorption among Two Years:

	Marginal Bone Resorption M%±SD		P-value
	Group I	Group II	
At Insertion- Six Months	14.62 %±1.35 A	13.49%±2.07 A	0.2479 (ns)
At Insertion- One Year	31.18%±2.08 B	22.79%±1.49 B	<0.0001*
At Insertion- Two Years	39.79%±3.87 C	28.92%±2.94 C	<0.0001*
P-value	<0.0001*	<0.0001*	

M%; Mean Percentage, SD; Standard Deviation, P; Probability Level Means with different superscript letters in the same column were significantly different using Tukey's post hoc test for multiple comparisons  
Ns; Insignificant different / \*; significantly different



**(Figure 18):** A histogram representing Marginal bone loss throughout Two years.

Regarding clinical patient satisfaction using (VAS) A general evaluation revealed gradually decreased values for both groups among insertion, six months, one-year, and two years intervals. For denture stability evaluation, there were decreased values for both groups among insertion, six months, one-year, and two years intervals. While for eating and talking evaluation, there were gradually increased values for both groups among insertion, six months, one-year, and two years intervals. Finally, for appearance evaluation, there were gradually decreased values for both groups among insertion, six months, one-year, and two years intervals, as listed in Table (II). Using an independent t-test for a direct comparison of clinical patient satisfaction between Group I and Group II, there were insignificant higher values of Group II in general evaluation except after two years which was significantly different as P-value < 0.05. For denture stability and eating

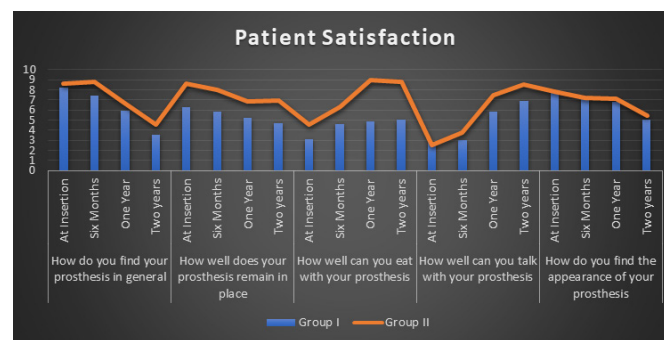


evaluation, there were higher significant values of Group II as P-value < 0.05. While regarding Speech evaluation, there were insignificant higher values of Group II except after one and two years which was significantly different as P-value < 0.05. Finally, for appearance evaluation, there were insignificant higher values of Group II as P-value > 0.05, as listed in Table (II) & Figure (19).

**Table (II):** Multiple Comparisons of Clinical Patient Satisfaction using (VAS) over Two Years:

		Group I M±SD	Group II M±SD	P-value
How do you find your prosthesis in general	At Insertion	8.2±1.35	8.6±2.95	0.7499 (ns)
	Six Months	7.4±2.5	8.75±3.09	0.3865(ns)
	One Year	5.9±1.37	6.7±2.08	0.4121(ns)
	Two years	3.51±0.84	4.56±1.04	0.0598*
How well does your prosthesis remain in place	At Insertion	6.3±1.57	8.64±1.89	0.0269*
	Six Months	5.8±0.97	7.95±2.37	0.0463*
	One Year	5.2±1.09	6.84±1.43	0.0327*
	Two years	4.7±1.02	6.97±1.13	0.0019*
How well can you eat with your prosthesis	At Insertion	3.12±0.48	4.55±0.91	0.0032*
	Six Months	4.62±0.18	6.28±2.01	0.05*
	One Year	4.88±0.27	8.92±1.55	<0.0001
	Two years	5.08±1.44	8.83±2.09	0.0021*
How well can you talk with your prosthesis	At Insertion	2.87±0.99	2.54±1.17	0.5794(ns)
	Six Months	3.01±0.53	3.76±0.78	0.0571(ns)
	One Year	5.88±1.18	7.47±1.14	0.0248*
	Two years	6.91±0.03	8.53±1.17	0.0033*
How do you find the appearance of your prosthesis	At Insertion	7.68±2.14	7.85±2.38	0.8906(ns)
	Six Months	7.06±1.98	7.23±1.77	0.8683(ns)
	One Year	6.84±0.72	7.11±0.81	0.5222(ns)
	Two years	5.09±0.73	5.47±0.65	0.324(ns)

M%; Mean Percentage, SD; Standard Deviation, P; Probability Level Means with different superscript letters in the same column were significantly different using Tukey's post hoc test for multiple comparisons  
Ns; Insignificant different / \*; significantly different



(Figure 19): A histogram representing Patients' Satisfaction.

## DISCUSSION

### Discussion of methodology

In this study, patient selection was carefully considered as it may affect the osseointegration of the implants and later after restoration insertion. These criteria might be biological or mechanical or both. [15] To prevent any variations in bone changes that would affect the results, patients' ages ranged from 45 to 65. Additionally, the patients chosen should be systemically free of any conditions that could affect osseointegration and bone healing surrounding the implants. [16]

To guarantee efficient primary stability of the implant at the time of its placement and to ensure that at least 1 mm thickness of bone remained buccal and lingual to the implant after its placement, bone quality and quantity were examined radiographically. [17]

To ensure the accuracy of implant placement in the three dimensions and to reduce any human interference elements that might alter the proper implant angulation, a computer-guided surgical stent was constructed [18]. The entire implants utilized had a conical internal connection at the implant-abutment interface and were two pieces, threaded, self-tapping, root-form implants that measured 11.5 mm in length and 3.7 mm in diameter. This implant design was employed to improve the contact area between the implant and the surrounding bone for better osseointegration as well as to ensure primary stability throughout the early healing period. [19] To prevent any metallic artifacts that might occur with CBCT, the osseointegration of implants was judged using a panoramic radiograph (due to the presence of multiple implants) [20]

Additionally, post-operative CBCT was done to make sure that the pre-operative planning was accurately duplicated. A hybrid prosthesis that is implant-supported, and screw-retained for maxillary rehabilitation was fabricated from PEEK material to protect the implants from overload and to provide more satisfactory aesthetic results. When the superstructure is supported by six well-distributed implants, the load distribution over the superstructure

(i.e., the prosthesis) became more advantageous. [21]

The probably distributed implants in both groups antero-posteriorly (AB distance) offered better clinical and radiographic results, as it might decrease the cantilever length, and increase occlusal scheme in the maxillary fixed implant-supported prosthesis, providing a better distribution of occlusal forces and hence, decreases the rate of bone resorption around the implants. [22]

After fabrication of the verification jigs on the master cast, it should be sectioned using a fine disc into a segmented verification jig to eliminate the effect of dimensional changes that might occur during the curing process. [23]

For each verification jig segment containing a titanium cylinder and replaced intra-orally, there should be a gap approximately the thickness of a credit card to fill the new material into them and prevent slippage of the low shrinkage acrylic material between the adjoining sections [24] During the final impression procedure, the light body PVS impression material should be injected under and around the jig to record the ridge and all anatomical landmarks for a full denture including full vestibular extensions [25] The cases were followed up for two years to ensure proper evaluation of patient satisfaction & radiographic parameters throughout a suitable study period. [26]

#### **Discussion of results**

The frequent remodelling process of the bone surrounding the implant may describe the considerable rise in mean bone height measures in both groups, which indicates higher crestal bone resorption in the first six months compared to those measurements from insertion to twelve months [27]. The average marginal bone loss from baseline to twelve months in the current study is seen as a small decrease within generally accepted limits for dental implants. [28]

None of the patients had any disturbing issues with the implant during their recall periods, and they all were strictly adherent to the oral hygiene recommendations. [29] Numerous studies concluded that the greater retention and durability of patients' implant-supported fixed prostheses had improved their quality of life. The statistically significant difference in patient satisfaction between the two groups throughout the clinical trial demonstrated how the proper placement & distribution of the implants would affect the quality of the obtained prosthesis. [30]

***The current clinical investigation's findings were inconsistent with the previously stated null hypothesis.***

#### **CONCLUSION:**

Within the limitation of this, concerning the relatively small sample size, it could be concluded that the clinical and radiographic outcomes of the implants-supporting screw-retained full arch superstructure through proper implant distribution results in a favorable response for completely edentulous maxillary arch, especially by utilizing a Bio-HPP material for the construction of the framework where it has a lower chipping rate, decrease of stress shield, metal-free and easily monitoring implant-abutment connection fit.

#### **CONFLICT OF INTEREST**

This clinical study was self-funded by the author, with no conflict of interest.

#### **REFERENCES**

- 1-Zarb GA, Albrektsson T.: Aspects of biomechanical considerations. In: Brånemark P-I, ed. Tissue-integrated prostheses: osseointegration in clinical dentistry-1. Chicago, IL: Quintessence Publishing, 2005:117–128.
- 2-Wicks RA, de Rijk WG, Windeler AS.: An evaluation of fit in osseointegrated implant components using torque/turn analysis. J Prosthodont 1994; 3:206–212.
- 3-Brunski JB.: Biomechanical factors affecting the bone-dental implant interface. Clin Mater, 2005; 10:153–201.
- 4- Ali Reza Pournasrollah, Ramin Negahdari, Ali Torab, Soheil Jannati Ataei.: Investigating the effect of abutment-implant connection type on abutment screw loosening in a dental implant system using the finite element method. December 2019, Journal of Dental Research, Dental Clinics, Dental Prospects 13(4):289-297
- 5- Gardner, T. N. & Mishra, S. The biomechanical environment of a bone fracture and its influence upon the morphology of healing. Med. Eng. Phys. 25, 455-464 (2003).
- 6-Ki-Young Lee, Kyung Su Shin, Ji-Hye Jung, Hye-Won Cho, Kyung-Hwan Kwon, and Yu-Lee Kim.: Clinical study on screw loosening in dental implant prostheses: a 6-year retrospective study. J Korean Assoc Oral Maxillofac. Surg. 2020 Apr 30; 46(2): 133–142.
- 7- Lee MY, Heo SJ, Park EJ, Park JM.: Comparative study on stress distribution around internal tapered connection implants according to fit of cement- and screw-retained prostheses. J Adv Prosthodont 2013; 5:312-318.

- 9- Bassant Sherif Gamal Eldi, Noha Helmy Nawar, Ahmed Mostafa Abdelfattah.: Accuracy of Different Impression Techniques on The Fit of Screw-Retained Bar Joining Two Interforaminal Implants. *Ain Shams Dental Journal*. Official Publication of Ain Shams Dental School March 2021•Vol.XXIV
- 10- Zarone F, Apicella A, Nicolais L, Aversa R, Sorrentino R: Mandibular flexure and stress build-up in mandibular full-arch fixed prostheses supported by osseointegrated implants. *Clin Oral Implants Res*.2003; 14(1): 103-114.
- 11- Carlo Ercoli DDS, Alessandro Geminiani DDS, Ph.D., Heeje Lee DDS.: The Influence of Verification Jig on Framework Fit for Non-segmented Fixed Implant-Supported Complete Denture First published: 16 December 2011.
12. Balkaya MC.: Investigation of the influence of different implant sizes and placement on stress distribution with 3-dimensional finite element analysis. *Implant dent* 2014;23(6): 716-722
- 13-Carl E Misch.: Mandibular Full-Arch Implant Fixed Prosthetic Options: In: Misch C.E. *Dental Implant Prosthetics*, Elsevier Mosby, St Louis, pp.,2005: 256-264.
- 14- Degidi M, Nardi D, Piattelli A.: Immediate rehabilitation of the edentulous mandible with a definitive prosthesis supported by an intraorally welded titanium bar. *Int J Oral Maxillofac Implants* 2009; 24(2) : 342-347
- 15-Emera, R., Abdel-Khalek, E.: Five-year Radiographic Changes of Residual Ridges under Maxillary Complete Denture and its Opposing Mandibular Two Implant-Retained Overdenture with Different Resilient Attachments. *Egyptian Dental Journal* 65(Issue 1 - January (Fixed Prosthodontics, Dental Materials, Conservative Dentistry & Endodontics): 2019;531-540. doi: 10.21608/edj.2019.72809
16. Wong N.Future Trends in Implant Dentistry: Digitally Guided Surgery and Prosthetics. *Dent Today* 2016; 35: 86-91.
- 17-Greco GD, Jansen WC, Landre Junior J, Seraidarian PI.: Stress analysis on the free-end distal extension of an implant-supported mandibular complete denture. *Braz Oral Res* 2009; 23(2): 182-189.
- 18-Kern JS, Kern T, Wolfart S, Heussen N.: A systematic review and meta-analysis of removable and fixed implant-supported prostheses in edentulous jaws: post-loading implant loss. *Clin Oral Implants Res*. 2016; 27(2): 174-195.
- 19-Vogl S, Stopper M, Hof M, Wegscheider WA, Lorenzoni M.: Immediate occlusal versus non-occlusal loading of implants: a randomized clinical pilot study. *Clin Implant Dent Relat Res* 2015;17(3): 589-597.
- 20-Strassburger C, Kerschbaum T, Heydecke G.: Influence of implant and conventional prostheses on satisfaction and quality of life: A literature review. Part 2: Qualitative analysis and evaluation of the studies. *Int J Prosthodont* 2006; 19(4): 339-348
- 21-Weinstein R, Agliardi E, Fabbro MD, Romeo D, Franchetti L.: Immediate rehabilitation of the extremely atrophic mandible with fixed full prosthesis supported by four implants. *Clin Implant Dent Relat Res* 2012; 14(3): 434-441.
- 22- Gehrke SA, da Silva Neto UT, Del Fabro M.: Does implant design affect implant primary stability? A Resonance Frequency Analysis based randomized split-mouth clinical trial. *J Oral Implantol*. 2015; 41(6): e241-246.
- 23-Gliardi E, Clerico M, Ciancio P, Massironi I.: Immediate loading of full-arch fixed prostheses supported by axial and tilted implants for the treatment of edentulous atrophic mandibles. *Quintessence Int* 2010; 41(4): 285-293.
- 24-Del Fabbro M, Ceresoli V.: The fate of marginal bone around axial vs. tilted implants: a systematic review. *Eur J Oral Implantol* .2014;(suppl 2): S171-189
- 25- Carlo Ercoli, DDS, Alessandro Geminiani, Changyong Feng, Heeje Lee.: The Influence of Verification Jig on Framework Fit for Non-segmented Fixed Implant-Supported. *Clinical Implant Dentistry and Related Research* 14 Suppl. 2011;1(s1): E188-95
- 26- Gallucci GO, Benic GI, Eckert SE, Papaspyridakos P, Schimmel M, et al.: Consensus statements and clinical recommendations for implant loading protocols. *Int J Oral Maxillofac Implants* 2014; 29(suppl): 287-290
27. Chiapasco M.: Early and immediate restoration and loading of implants in completely edentulous patients. *Int J Oral Maxillofac Implants* 2014; 19(suppl): 76-91.
28. Elsyad MA, Hammouda NI.: Expansion of mandibular knife-edge ridge and simultaneous implant placement to retain overdentures: One-year clinical and radiographic results of a prospective study. *Clin Implant Dent Relat Res*.2017; 19(1): 167-179
29. Al Helal A, Bader B, Kattadiyil MT, Garbacea A, Proussaefs P.: CAD-CAM implant-supported fixed complete dental prosthesis with titanium milled molars: A clinical report. *J Prosth Dent* 2017; 117: 463-469.
30. Gilardi E, Clerico M, Ciancio P, Massironi D.: Immediate loading of full-arch fixed prostheses supported by axial and tilted implants for the treatment of edentulous atrophic mandibles. *Quintessence Int*. 2010; 41(4): 285-293.