



Comparative Study of Some Natural Materials Versus Traditional Medicaments used for Pulp Treatment of Primary Teeth

Sara N. Hashem⁽¹⁾, Mervat I. Fawzy⁽²⁾ and Mohammed H. Mostafa⁽³⁾

Codex : 03/1901

azhardentj@azhar.edu.eg

http://adjg.journals.ekb.eg

DOI: 10.21608/adjg.2019.5230.1001

ABSTRACT

Purpose: To evaluate clinically, radiographically and histologically the postoperative success of Miswak, *Allium sativum* and *Nigella sativa* extracts use in pulpotomy procedures for primary teeth. **Materials and Method:** 92 Primary teeth found in 26 patients were selected according to inclusion criteria. In the first part of the study pulpotomy was accomplished in 20 participants having 80 teeth and depending on the type of radicular pulp medicament, the teeth were divided randomly and equally into four groups: Group I (Miswak group), Group II (*Nigella sativa* group), Group III (*Allium sativum* group), Group IV (formocresol group). Clinical follow up was done after 1, 3, and 6 months. Periapical radiographs also were taken at 3 and 6 months follow up visits only. In the second part of the study 12 primary molars planned for extraction due to orthodontic purpose were treated by pulpotomy procedure and then the teeth were grouped into four groups and then the teeth extracted after 2 months and were observed under light microscope. **Results:** No statistically significant difference between groups in the overall cumulative clinical or radiographic success at follow up visits. Histopathological examination revealed dentine bridge formation in primary molars treated with Miswak, *Nigella sativa* treated primary molars showed absence of odontoblastic layer, *Allium sativum* showed well organized odontoblastic layer and chronic inflammatory cellular infiltration, while formocresol specimens showed severe hyperemia and hyalinization of pulp stroma. **Conclusion:** Miswak, and *Allium sativum* can be considered as good natural alternatives to formocresol in primary molars pulpotomy, however *Nigella sativa* cannot be a suitable substitute to formocresol.

KEYWORDS

Allium sativum,
primary teeth, pulpotomy,
Miswak,
Nigella sativa

INTRODUCTION

Extensive dental decay in the primary teeth that progress to dental pulp remains a common problem in the pediatric dental practice⁽¹⁾. Lack of treatment for caries in primary teeth will often result in the

- Paper extracted from Doctor Thesis Titled “Comparative Study of Some Natural Materials Versus Traditional Medicaments used for Pulp Treatment of Primary Teeth”
- 1. Assistant Lecturer of Pedodontics and Oral Health, Faculty of Dental Medicine for Girls, AlAzhar University.
- 2. Professor of Endodontics, Faculty of Dental Medicine for Girls, AlAzhar University.
- 3. Associate Professor of Pedodontics and Oral Health, Faculty of Dental medicine for Girls, AlAzhar University.

premature loss of the primary teeth especially molars, which are at risk for the longest period. Premature loss of primary molars before normal time of shedding, can lead to loss of arch space; as the first permanent molars drift into the missing tooth spaces. The result can be crowding of the permanent teeth, the severity of which depends on the amount of lost space. Anterior teeth crowding affects aesthetics and may necessitate orthodontic treatment for correction. Pulp chamber anatomy in primary teeth approximates the surface shape of the crown more closely than in permanent teeth. The pulps of primary teeth are proportionally larger and the pulp horns extend closer to the outer surface of the cusps than in permanent teeth⁽²⁾.

The pulp protecting dentin thickness between the pulp chamber and the dentino-enamel junction is less than in permanent teeth, these factors increase the potential for pulp exposure from mechanical preparation or dental caries⁽³⁾. Preservation of the remaining vital portion of curiously exposed pulpal tissue in primary teeth, where the demand is to keep a functioning tooth in site, was one of the most frequent problems in pediatric dentistry⁽⁴⁾. To solve this problem vital pulp therapy was introduced, developed and classified according to treatment objectives into either pulp capping or pulpotomy⁽⁵⁾. Pulpotomy has become the dominating pulp therapy for the deciduous dentition, because of the complicated anatomy of the root canals in primary teeth, the proximity of the permanent tooth germ and the difficulties in finding a root-canal filling material compatible with physiological root resorption⁽⁶⁾.

The pulpotomy procedure is indicated when caries removal results in pulp exposure in a primary tooth with a normal pulp or reversible pulpitis or after a traumatic pulp exposure, the pulpotomy technique branches into the different types according to the medicaments used, the most common one is the formocresol pulpotomy⁽⁵⁾. Despite the high success rates of pulpotomy achieved by formocresol, concerns are raised regarding its toxicity.

Formaldehyde is believed to cause mutagenicity, cytotoxicity and carcinogenicity in children⁽⁷⁾. IARC (2004) classified formocresol as carcinogen that has potency to cause leukemia and nasopharyngeal carcinoma⁽⁸⁾. A demand for natural medicament to replace FC as a pulp dressing material became imperative. Some of the plants can be used for this purpose such as: Miswak, Nigella Sativa and Allium Sativum.

A previous study⁽⁹⁾ assessed the clinical and radiographic effect of Miswak extract and formocresol in the treatment of non-vital primary molars with 6 months follow up period. In addition, evaluated histologically the effect of Miswak extract and calcium hydroxide on vital pulps of first premolars undergoing extraction for orthodontic treatment. They concluded that Miswak extract is a biocompatible material that is compatible with vital human pulp tissue. It offers a good healing potential, leaving the remaining pulp tissue healthy and functioning.

Another study⁽¹⁰⁾ compared the histopathological pulp response to Nigella Sativa oil and formocresol in dogs. The results showed that NS specimens histologically revealed mild to moderate vasodilatation with few inflammatory cells and a continuous odontoblastic layer. On the other hand, FC specimens showed advanced inflammation with severe vasodilatation and inflammatory cell infiltration and degeneration. Thus, application of NS maintained the vitality of the pulp, which makes it a good pulpotomy agent in clinical practice.

MATERIALS AND METHODS

The present study was divided into two parts. The first part was to evaluate the effect of Miswak, Allium sativum and Nigella sativa in pulpotomy procedures for primary teeth clinically and radiographically. The second part was a histologic study to evaluate the effects of these materials on dental pulp of primary molars that were planned for extraction due to orthodontic purpose. In the first Part of the study 20 participants having 80 teeth were included that fulfilled the following criteria; ranging from

4-8 years old, patient and parent cooperation, absence of any systemic disease that can contraindicate pulp therapy, having at least four carious primary molars with nearly equal carious involvement that will possibly require pulpotomy. The selected teeth had the following criteria; restorable crown, no spontaneous pain, swelling or sinus, no pathologic mobility, no initially unsuccessful hemorrhage control.

Radiographically teeth should be without inter-radicular radiolucency, no loss of lamina dura, no widening in periodontal membrane space and no physiologic root resorption of more than one third the root.

In the second part of the study 12 primary molars were found in 6 systemically healthy participants that aged 8-10 years old each had two primary molars planned for extraction due to orthodontic purpose.

Preparation of Miswak (*Salvadora Persica*) extract

Salvadora persica chewing sticks (Siwak) were brought from Al-Madina Almonawara. To prepare the aqueous extract, *Salvadora Persica* chewing sticks were cut into small pieces and ground into a powder form, the powder was weighted into 100 gm and mixed with 1 Liter of sterile distilled water and allowed to soak for 48 hours. The mixture was then filtered using number 1 filter paper and the filtrate was evaporated in vacuum evaporator at 60°C. The extract was saved as a thick paste in a sterile bottle in the refrigerator until used. Before use, the extract was freshly reconstituted in sterile distilled water to a final concentration of 200mg/ml⁽¹¹⁾

***Nigella sativa* extract and *Allium sativum* extracts**

Both extracts were prepared by the manufacturer through cold maceration method with ratio dry herb /menstrum = 1/3, and the menstrum used was organic ethyl alcohol and vegetable palm glycerin (1:1)

Technique of vital pulpotomy

Teeth to be treated were locally anaesthetized using mepecaine. Patients were allowed to wait for 10 min before pulpotomy procedure was done,

rubber dam or cotton rolls were used to isolate the designated tooth. After caries removal with a sterile #330 high-speed pear-shaped carbide bur with air/water spray, access to a pulp chamber was detected with a probe, or if the roof of the pulp chamber was sufficiently thin to see the pulpal tissue. When the pulpal exposure was confirmed, the roof of the pulp chamber was removed with a sterile large high speed round bur #4 with water spray. Coronal pulp-amputation was achieved with a sterile sharp, large, spoon excavator and the access was refined with a sterile high speed fissure bur. Homeostasis was attained by placing small cotton pellet moistened in sterile saline with slight pressure for 2-3 minutes then it was removed. Excessive bleeding during pulp amputation or non-vital teeth were excluded from this study.

Sample Grouping

For the clinical and radiographic (first part) study, (depending on the type of radicular pulp medicament), the teeth were divided randomly and equally into four groups as follows: (Group I, Group II, Group III and Group IV).

Group I (*Miswak* group) (20 primary molar)

The pulp stumps of 20 primary teeth were dressed with a cotton pellet soaked with *Miswak* extract for 5 minutes. Then, pulp stumps of the teeth were dressed in zinc oxide powder mixed with few drops of eugenol to form reinforced zinc oxide eugenol paste, the mixture was compressed against the exposure site with a moist cotton pellet.

Group II (*Nigella Sativa* group) (20 primary molars)

The pulp stumps of 20 primary teeth were dressed with a cotton pellet damped with *Nigella sativa* extract for 5 min. Then, pulp stumps of teeth were dressed in zinc oxide powder mixed with few drops of eugenol to form reinforced zinc oxide eugenol paste, the mixture was compressed against the exposure site with a moist cotton pellet.

Group III (Allium Sativumgroup) (20 primary molars)

The pulp stumps of 20 primary teeth were dressed with a cotton pellet damped with Allium sativum extract for 5 min. Then, pulp stumps of teeth were dressed in zinc oxide powdermixed with few drops of eugenol to form reinforced zinc oxide eugenolpaste,the mixture was compressed against the exposure site with a moist cotton pellet.

Group IV (Formocresol group) (20 primary molars) (conventional agent of pulpotomy) positive control group

The pulp stumps of primary teeth were dressed with a cotton pellet damped with formocresol for 5 min. Then, pulp stumps of teeth were dressed in reinforcedzinc oxide eugenol oil paste, the mixture was compressed against the exposure site with a moist cotton pellet. After that, the teeth were restored with glass ionemer restoration and then with stainless steel crown. Patients were instructed to contact the investigator if any adverse signs or symptoms occurred between follow up visits.

Follow up:

The children were recalled for clinical examination after 1,3, and 6 months, for the presence of any signs and symptoms in the treated teeth. This clinical assessmentwas done by the primary investigator at each follow up visit, data were recorded in patient evaluation form.

Periapical radiographs also were taken for all treated teeth at 3and 6months followup visits only using the same standardized technique described before for preoperative radiographs. The radiographic outcome assessment was done by the primary investigator and one independent experienced radiologist who was blinded to the treatment.

Clinical evaluation criteria

Teeth showing the following criteria were considered as success; restoration is intact, no symptoms of pain, no swelling of pulpal origin, no fistula, no tenderness to percussion, no pathological mobility.

Radiographic evaluation criteria

Teeth showing the following criteria were considered as success; no internal resorption, no pathologic external resorption ,no interradicular radiolucency, no periapical radiolucency ,no widening of periodontal ligament space .

Histologic study

In the second part of the study 12 deep carious primary molars in 6 systemically free patients were used, they were previously planned for extraction due to orthodontic purposes.

After pulpotomy procedure had been performed as mentioned before (three teeth in each group), the treated teeth were extracted after 2 months and kept in 10% buffered formalin solution for minimum 24 hours and were decalcified in5% nitric acid for 3 weeks. Six-micrometer-thick sections were cut with a microtome in occlusogingival direction and stained with Hematoxylin and Eosin and viewed under light microscope.Each specimen was observed by well experienced pathologist for dentin bridge formation, odontoblastic layer integrity, pulp inflammation and pulp fibrosis .

Statistical analysis

Statistical analysis was then performed using a commercially available software program (SPSS 18; SPSS, Chicago, IL, USA).Descriptive statistics presented data as frequency and percentage. Chi square test was used for comparisons. One-way ANOVA was used to compare the mean age in different groups. The level of significance was set at $P < 0.05$.

RESULTS

No statistically significant difference between groups in the overall cumulative clinical success at 1, 3 or 6 months.Radiographic evaluation also showed no statistically significant difference between groups in the overall cumulative success at 3 and 6 months(Fig.1 & Table 1)

Histopathological examination revealed dentine bridge formation in a Hematoxylin& Eosin stained section of a primary molar treated with Miswak, also inflammatory cellular infiltration and well organized odontoblastic layer were founded. Nigella sativa treated primary molars showed empty areas in pulp space, absence of odontoblastic layer which indicates necrosis of pulp tissues. Also, dysrophic calcification was found. Allium sativum showed well organized odontoblastic layer and chronic inflammatory cellular infiltration, while formocresol specimens showed severe hyperemia hyalinization vacuolation of pulp stroma and scattered calcified areas.

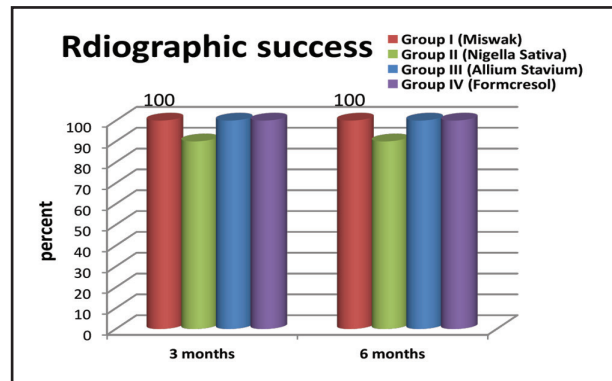


Fig. (1) Column chart showing percentage of radiographic success at 3 and 6 months in all groups.

Table (1) Radiographic evaluation at 6 months and significance of difference between groups (chi square test).

Radiographic evaluation	Group I Miswak		Group II Nigella Sativa		Group III Allium Sativum		Group IV Formocresol		X ²	P
	N (20)	%	N (20)	%	N 19	%	N 17	%		
Root resorption	0	0	0	0	0	0	0	0	0	1 ns
Internal root resorption	0	0	1	5	0	0	0	0	3.038	0.39 ns
Inter-radial resorption	0	0	0	0	0	0	0	0	0	1 ns
Widening of the PDL space	0	0	1	5	0	0	0	0	3.03	0.39 ns
Bone resorption	0	0	0	0	0	0	0	0	0	1 ns
Cumulative radio. success	20	100	18	90	20	100	20	100	6.15	0.104 ns

DISCUSSION

In Miswak group, all clinical signs of failure were absent at one and 3 months. However, after 6 months, one case lost the stainless-steel crown which considered failure in the treatment. The high percentage of clinical and radiographic success corroborates the results of other study which showed 94% clinical success rate for Miswak. However, they used Miswak in non-vital pulpotomy of primary molars ⁽¹²⁾. This high percentage of

success may be attributed to the anti-inflammatory, antibacterial potential of Miswak besides its stem cell proliferation ability which promote healing ⁽¹³⁾.

In Nigella sativa group, the overall clinical success was 100% at one and 3 months and 90% at 6 months. The overall radiographic success was 90% at 3 months and 6 months. These results are in disagreement with another previous study which reported 78.9% clinical success of and 82.2%

radiographic success of NS non-vital pulpotomy in primary molars⁽¹⁴⁾. This may be due to the current study was performed on vital pulpotomies which have much better prognosis and higher success rate than non-vital pulpotomies.

In Allium Sativum group, the overall cumulative clinical success was 95% at 1, 3 and 6 months and the overall radiographic success was 100% at 3 and 6 months. These results corroborate the results of another study which reported 90% clinical success in vital pulpotomy of primary molars⁽¹⁵⁾. The promising clinical outcome of primary molars pulpotomy performed with Allium Sativum can be explained on the bases that the oil was found to possess a potent antibacterial, analgesic and anti-inflammatory properties

Miswak group showed moderate inflammatory cellular infiltration and dilated blood vessels due to inflammatory reaction as well as intact odontoblastic layer and dentin bridge formation were seen. This could explain the high clinical and radiographic success rate of Miswak pulpotomy in the current study. The results of the present study are similar to another study which reported dentin bridge formation after Miswak pulpotomy, however, they used Miswak on sound premolars⁽¹²⁾.

CONCLUSIONS

Miswak, and Allium Sativum showed better clinical, radiographical and histological results compared to formocresol in primary molar pulpotomy so they can be considered as good natural alternatives to formocresol in primary molars pulpotomy.

- Miswak induced dentin bridge formation and can be considered as an agent for regenerative pulpotomy in primary molars.
- Nigella sativa showed better clinical results than formocresol in primary molar pulpotomy. However, radiographic evaluation was not as good as formocresol. Histologically its results were unsatisfactory. Thus, it cannot be a suitable substitute to formocresol.

REFERENCES

1. Farsi N, Alamoudi N, Balto K, Mushayt A. Success of mineral trioxide aggregate in pulpotomized primary molars. *J Clin Pediatr Dent* 2005; 29:307-11.
2. Davey KW. Effect of premature loss of primary molars on the anteroposterior position of. *J Dent Child* 1967; 34:383-94.
3. Dummett CO, Kopel HM. Pediatric endodontics. In: Ingle JI, Bakland LK, eds: *Endodontics*. 7th ed. chapter 17, 2010: 861-902.
4. Primosch RE, Glomb TA, Jerrell RG. Primary tooth pulp therapy as taught in predoctoral dental programs in United States. *Pediatr Dent*. 1997;19:118-22.
5. Hicks MJ, Barr ES, Flaitz CM. Formocresol pulpotomies in primary molars: A radiographic study in a pediatric dentistry practice. *J Pedod*. 1986;10:3-8.
6. Sabbarini J: Alternative Interventions to Formocresol as a Pulpotomy Medicament in Primary Dentition, *Sm Dent Magaz* 2008;8:15-24.
7. Lewis BB, Hestner SB. Formaldehyde in dentistry: a review of mutagenic and carcinogenic potential. *J Am Dent Assoc* 1981; 103: 429-34.
8. International Agency for Research on Cancer, WHO, Press Release No. 153, June 15, 2004.
9. Mahmoud SH, Elbeheri S, Farag M, Mahdy H, Ghali L. Comparative study of the effect of miswak extract versus formocresol and calcium hydroxide in treatment of vital and non vital teeth. Doctor thesis Suez canal University 2013.
10. Omar OM, Khattab NM, Khater DS. Nigella Sativa oil as a pulp medicament for pulpotomized teeth: a histopathological evaluation. *J Clin Pediatr Dent* 2012; 36: 335-42.
11. Parekh J, Karathia N, Chanda S. Screening of some traditionally used medicinal plants for potential antibacterial activity. *Indian J Pharm Sci* 2006; 68: 832-4.
12. Al-Othman A M, Ahmad F, Al-Orf S, Al-Murshed KS, Ariff Z. Effect of dietary supplementation of *Ellataria cardamun* and *Nigella sativa* on the toxicity of rancid corn oil in rats. *Int J Pharmacol* 2006; 2: 60-5.
13. Tabatabaei FS, Moezizadeh M, Javand F. Effects of extracts of *Salvadora persica* on proliferation and viability of human dental pulp stem cells. *J Conserv Dent*. 2015; 18: 315-20.
14. Omar O, Khattab N. An investigation on the relative efficacy of nigella sativa oil compared to formocresol as pulp medicament in non-vital primary molar pulpotomies. *EDJ* 2006; 52:169-77.
15. Baroudi K, Shukry GM, Raheel SA. Clinical and Radiographic Evaluation of Allium sativum Oil as a New Medicament for Vital Pulp Treatment of Primary Teeth. *J Int Oral Health*. 2014; 6: 32-6.