



## Clinical and Radiographic Assessment of Platelet Rich Fibrin Effect in One-Stage Dental Implant

Radwa M. Ismail<sup>(1)</sup>, Eatemad A. Shoreibah<sup>(2)</sup> and Mai S. Attia<sup>(3)</sup>

Codex : 02/1901

azhardentj@azhar.edu.eg

http://adjg.journals.ekb.eg

DOI: 10.21608/adjg.2019.5227.1002

### ABSTRACT

**Purpose:** The present study was conducted to evaluate the clinical and radiographic effect of Platelet Rich Fibrin (PRF) in one stage dental implants in an attempt to improve outcomes of dental implants.

**Material and methods:** This study was conducted on twelve (12) healthy patients that were randomly divided into two groups: Group A (control group) six (6) patients with one stage implant insertion without the use of platelet rich fibrin membrane ; Group B (Test group) six (6) patients with one stage implant insertion with the use of Platelet Rich Fibrin membrane. **Results:** Test group showed a highly significant increase in its bone density (P-value 0.009) after six months in comparison with control group after six months follow up. **Conclusion:** The use of platelet rich fibrin membrane in one stage implant insertion showed an improvement in peri-implant bone density which will affect implant stability and subsequent long implant survival.

### INTRODUCTION

Osseointegrated titanium dental implants become widely used as a successful treatment option for the restoration of both partial and fully edentulous patients in the last 25 years with consistent long-term results<sup>(1)</sup>. Percentage rate of implants survival is reported to be similar or even superior to traditional crowns, dentures or bridges<sup>(2)</sup>.

### KEYWORDS

Dental Implants,  
Platelet Rich Fibrin,  
Bone Density

- A paper extracted from Doctor Thesis titled “Clinical and Radiographic Assessment of Platelet Rich Fibrin Effect in One-Stage Dental Implant”
- 1. Dental Specialist at Galaa Teaching Hospital.
- 2. Professor of Oral Medicine, Periodontology, Oral Diagnosis and Dental Radiology Department, Faculty of Dental Medicine, Girls branch, Al-Azhar University.
- 3. Associate Professor of Oral Medicine, Periodontology, Oral Diagnosis and Dental Radiology Department, Faculty of Dental Medicine, Girls branch, Al-Azhar University.

One stage surgical protocol was proposed in 1988<sup>(3)</sup> as it offers several clinical advantages including less chair time per patient, avoiding second surgery, and simplified prosthetic procedures for temporary restorations<sup>(3,4)</sup>. Studies have reported that bone density is a main factor that affect both implant stability and osseointegration<sup>(5,6)</sup>, where osseointegration was defined as direct bone to metal interface without intervening connective tissue<sup>(7)</sup>.

Regarding wound healing around dental implants, it includes both bone and soft tissue. With implant site preparation and its insertion, blood vessels and bone structure injury will occur that will trigger hemostasis to stop such bleeding. This process ends up with blood clot formation that initiates immune-inflammatory response, followed by neovascularization and the transient fibrin-based structural matrix formation that serves as an osteoconductive medium. Osteoconduction phase at this point takes place by recruitment of osteogenic cells, osteoblasts then lay down bone on the old bone surface (distant osteogenesis) or on the implant surface itself (contact osteogenesis)<sup>(8)</sup>.

Several studies have reported that bone density is an essential factor that influence implant stability as it is a necessity to establish a mechanical rest, which is essential to avoid disturbance of both healing and osseointegration<sup>(9,10)</sup>. Also, peri-implant bone quality and quantity influence architecture of the overlying soft tissues<sup>(11)</sup>.

Since the discovery of platelets regenerative potentiality in 1974<sup>(12)</sup>, different techniques of autologous platelet concentrates preparations have been introduced to improve soft and hard tissue healing; <sup>(13)</sup> platelets Rich fibrin is one of these innovations<sup>(14)</sup>. PRF production protocol aims to collect the circulating stem cells, platelets and leukocytes in a fibrin clot with a definite composition and three-dimensional architecture. Although, platelets and leukocyte cytokines play an important part in the biology of this biomaterial, but the fibrin matrix supporting them definitely constitutes the influential element responsible for the actual therapeutic potential of PRF<sup>(15)</sup>.

Studies have demonstrated that PRF has a very significant slow sustained release of growth factors for at least 1 week<sup>(16,17)</sup> and up to 28 days which means that PRF could motivate its environment for sufficient time during wound healing<sup>(18,19)</sup>. Studies reported that PRF plays a significant role in improving bone healing and improving the quality of bone<sup>(20, 21)</sup>. Others reported that PRF can increase dental implants stability due to its effect on differentiation and proliferation of osteoblasts<sup>(22,23)</sup>.

An important tool in the evaluation of dental implants success and failure is the use of cone beam radiographs<sup>(24)</sup> and it was used in this study to determine bone density changes and to determine the presence of any radiolucency around dental Implants.

## MATERIAL AND METHOD

### Study design

This study was a randomized clinical trial on 12 patients selected from the out-patient clinic of Oral Medicine & Periodontology department, faculty of Dental Medicine for Girls, Al-Azhar University.

### Sample Size:

Sample size calculations achieved using <http://biomath.info/power> based on a previous study.<sup>(11)</sup> A total sample size of 12 patients (6 in each of the two groups) will be sufficient to detect the difference. Total numbers of patients were divided randomly in to two groups.

Group A (control group): 6 patients with one stage implant insertion without the use of Platelet Rich Fibrin membrane.

Group B (Test group): 6 patients with one stage implant insertion with the use of platelet rich fibrin membrane (PRF).

The patients were selected according to selected criteria (completely healed surgical site, presences of proper inter arch space for the placement of the

implant prosthetic part, bone density ranging from D2 to D3, non-smoker and non-pregnant women). The selected patients signed an informed consent explaining all the procedures to the patients including all benefits and side effects in simple and easy way, also the patients had the right for withdrawal at any time.

### **Surgical protocol:**

After local anesthesia administration, sulcular incisions around mesial and distal natural tooth with a crestal incision at the edentulous site were performed. Full thickness flap was elevated using mucoperiosteal elevator. Then implant osteotomy sites were prepared with the recommended sequence drilling according to implant system instruction. Drilling occur under copious internal irrigation with saline deep inside the bone to avoid over heating of bone over 47°C. Fixture is placed at a crestal position followed by screwing of a polished healing abutment, 2-4 mm in height to the implant body. Sutures were removed one week postoperatively. Antibiotics were described one day preoperatively and for 6 days after the surgery (Amoxicillin 500 mg 8hrs/7 days), 0.12% Chlorhexidine mouth washes were used a day pre-surgical for reduction of bacterial load to two weeks after the surgery twice per day.<sup>(25)</sup> Analgesic (Ibuprofen 600 mg tablets) was prescribed if needed.

### **Platelet rich fibrin preparation:**

Collecting of 10ml of blood from the patient in a plain tube without any anticoagulant and centrifuged for 10 minutes at 3,000 rpm. <sup>(18)</sup>PRF clot carried out from the tube using tissue forceps and left in a sterile cup for approximately 10 minutes to allow the release of the proper serum contained within then PRF separation from blood clot by using a lancet leaving the red-yellow interface. PRF membrane obtained by pressing the clot between two glass labs to get PRF membrane. <sup>(26)</sup>

### **Clinical evaluation:**

- Modified Gingival index (MGI) and Modified Plaque index (MPI) were recorded at 7, 30, 90 and 180 days for each patient around the healing abutment.
- Probing depth (PD): It was obtained by measuring the probing pocket per site around the implant. Probing depth is measured from the gingival margin to the base of the sulcus with less probing force than natural tooth. Probing depths were recorded at 1, 3 and 6 months for each patient around the healing abutment at a certain specific aspect (mesio buccal aspect) for all participants of this study using plastic periodontal probe.

### **Radiographic Assessment:**

Cone beam computed tomography (CBCT) was used twice before fixture placement and at the end of the study (after 6 months) to record bone density.

Bone Density: It was recorded from the sagittal view, the suitable implant size (diameter and length) for each recipient site was selected from the available data on CBCT and implants were drawn in the future recipient site. The total length of the implant was measured and then divided into three parts, representing the coronal, middle and apical thirds and those readings were recorded from mesial and distal aspect of drawn fixture. Measurements were taken from around approximately 2 mm in a parallel manner away from the implant fixture. Then those six readings were divided by six to get the mean value of bone density around each implant. The readings were recorded in Hounsfield Units (HU).

## **RESULTS**

### **Clinical evaluation results:**

Modified Gingival Index: Group B showed a lower mean MGI  $2.40 \pm 0.55$  than Group A which showed  $2.60 \pm 0.55$  at 7 days reading interval of time, however this different was of statistically

insignificant ( $P=0.580$ ). At the end of the study there was no difference between both groups.

**Modified Plaque Index:** showed no difference between both groups at all reading intervals of time from beginning of the study to the end of study

**Probing Depth:** showed a statistically non-significant difference ( $P\text{-value}=0.668$ ) between both groups at the end of the study.

### Radiographic assessment results:

#### Bone density:

Both groups (A&B) showed an increase in its bone density (before fixture placement and after 6 months of fixture placement) Group A showed increase in its density  $69.07 \pm 2.21$  throughout the study while group B increased  $172.96 \pm 4.77$  and the changes in the percentage of bone density between both reading before and after implant insertion were statistically with a highly significant difference ( $P\text{-value} 0.009$ ) (Fig 1).

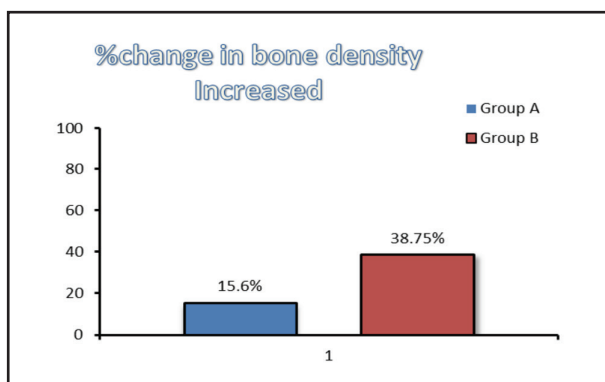


Fig. (1) % change of bone density of both groups throughout the study

### DISCUSSION

A criteria was concluded<sup>(24)</sup> to evaluate dental implants the success and failure that included clinical parameters (Modified Plaque Index, Modified Gingival index and probing depth) and Radiographic assessment. As regard, Modified Gingival index<sup>(27)</sup>, serves to describe and quantitate disease activity<sup>(28)</sup>. Also, Modified Plaque index<sup>(27)</sup> used to evaluate plaque accumulation around dental implants.

On the other hand, probing depth index is an important index for diagnosis of peri-implant disease. Probing is a suitable method to assess potential detrimental changes in the peri-implant environment and should be assessed every 3 to 4 months<sup>(29)</sup>.

In terms of clinical parameters (MGI, MPI and PD) in this study no significant difference observed between both groups at different intervals of time throughout the whole study, this could be attributed to adequate patient motivation and proper oral hygiene. This was in accordance with other studies<sup>(29,30)</sup>.

Regarding bone densities results both groups (A and B) showed a highly statistically significant increase. The increase in bone density might be due to alveolar bone compression by the implant body that was placed and this was in accordance with other studies<sup>(31,32)</sup>.

Group B showed highly significant increase in bone density in comparison with control group at the end of the study this may be due to presence of PRF membrane. This is in accordance with the result of other studies<sup>(21,30)</sup>. These results contributed to the fact that PRF can accelerate human osteoblast proliferation and stimulate strong differentiation of osteoblasts as proven by studies<sup>(33,34)</sup>.

Interestingly, a study on the effect of PRF on osteoblast's biologic characteristics was carried out, found that PRF is capable to initiate cell proliferation and increased the expression of alkaline phosphatase, collagen type I and Osteoprotegerin (OPG) which are a strong inducer of bone formation. They concluded that PRF enhance osteoblasts proliferation, differentiation and also osteoprotegerin expression<sup>(35)</sup>.

### CONCLUSION

The use of platelet rich fibrin membrane with one stage dental implant showed an improvement in bone density around dental implants maintenance of peri-implant soft health; which is a critical factor for implant stability, esthetic and long term implant prognosis.

## REFERENCES

- Palaska I, Phoebus T, Loannins V, Antonis and George M. Influence of placement depth and abutment connection pattern on bone remodeling around 1-stage implants: a prospective randomized controlled clinical trial. *Clin Oral Impl Res* 2016; 27:47-56.
- Buser D, Mericske-Stern R, Bernard J, Behneke A, Behneke N, Hirt H, Belser U et al. Long term evaluation of submerged ITI implants. Part1:8 year life table analysis of a prospective multicenter study with 2359 implants. *Clin Oral Implants Res* 1997;8:161-172.
- Daniel A, Schroeder C, Franz S and Niklaus P. The new concept of ITI hollow-cylinder and hollow screw implants; part 2. Clinical aspects, indications and early clinical results. *Int J Oral Maxillofac Implants* 1988; 3:173-181.
- Hui E, Chow J, Li D, Liu J, Wat P and Law H. Immediate provisional for single tooth implant placement with Branemark system: preliminary report. *Clin Implant Dent Relat Res* 2001; 3:79-86.
- Turkyilmaz I, Tumer C, Ozbek E and Tözüm T. Relations between the bone density values from computerized tomography, and implant stability parameters: a clinical study of 230 regular platform implants. *J Clin Periodontol*. 2007; 34:716-22.
- Ferhat A, Efe C and Omezli M. Is bone density or implant design more important in implant stress formation in patients with bruxism? *J. Biotech & Biotechn Equ* 2017; 31: 1221-1225.
- The Academy of Prosthodontics. The glossary of prosthodontics terms. *J Prosthet Dent* 1999; 81:48-110.
- Feller L, Chandran R, RAG Khammiss, Meyero R, Jadwat Y, Bouckaef M, Schechter I and Lemme J. Osseointegration: biological events in relation to characteristics of the implant surface. *SADJ* 2014; 69: 112 – 117. 26.
- Turkyilmaz I, Tumer C, Ozbek E and Tözüm T. Relations between the bone density values from computerized tomography, and implant stability parameters: a clinical study of 230 regular platform implants. *J Clin Periodontol*. 2007; 34:716-22.
- Ferhat A, Efe C and Omezli M. Is bone density or implant design more important in implant stress formation in patients with bruxism? *J Biotech & Biotechno Equ* 2017; 31: 1221-1225.
- Priyanka B, Manu R and Mohaneesh B. Effect of Platelet Rich Fibrin (PRF) on Peri-implant Soft Tissue and Crestal Bone in One-Stage Implant Placement: A Randomized Controlled Trial. *J Clin Diagn Res* 2015; 9: 18–21.
- Ross R, Glomset J, Kariya B and Harker L. A platelet-dependent serum factor that stimulates the proliferation of arterial smooth muscle cells in vitro. *Proc Natl Acad Sci U S A* 1974;71:1207-10
- Shobha P and Aditi T. Platelet Concentrates: Past, Present and Future. *J Maxillofac Oral Surg* 2011; 10: 45–49.
- Choukroun F, Adda C and Schoeffler A. PRF: The opportunity in perio-implantology: The PRF. *Imp dontie* 2001; 42: 55-62.
- Toffler M, Toscano N, Holtzclaw D, Corso M, Dohan Ehrenfest D. Introducing Choukroun's platelet rich fibrin (PRF) to the reconstructive surgery milieu. *J Implant Clin Adv Dent*. 2009; 1:21–30.
- Dohan D, Choukroun J, Diss A, Dohan S, Dohan A, Mouhyi J et al. Platelet-rich fibrin (PRF): a second-generation platelet concentrate. Part I: technological concepts and evolution. *Oral Surg Oral Med Oral Pathol Oral Radiol Endod*. 2006; 101:e37–44.
- Dohan E, De Peppo G, Doglioli P and Sammartino G. Slow release of growth factors and thrombospondin-1 in Choukroun's platelet-rich fibrin (PRF): a gold standard to achieve for all surgical platelet concentrates technologies. *Gro F* 2009; 27:63–69.
- He L, Lin Y, Hu X, Zhang Y and Wu H. A comparative study of platelet-rich fibrin (PRF) and platelet-rich plasma (PRP) on the effect of proliferation and differentiation of rat osteoblasts in vitro. *Oral Surg Oral Med Oral Pathol Oral Radiol Endod* 2009; 108:707–713.
- Yu Y, Kang C, Shinji K and Shohei K. Stability of Platelet-rich Fibrin in Vivo: Histological Study in Rats. *J of Oral T Eng* 2016;14: 83-90.
- Kotsakis G, Boufidou F, Hinrichs J, Prasad H, Rohrer M and Tosios K. Extraction Socket Management Utilizing Platelet Rich Fibrin: A Proof-of-Principle Study of the “Accelerated-Early Implant Placement” Concept. *J Oral Implantol* 2016; 42:164-8.
- Dimofte A, Forna D, Costan V and Popescu E. The value of platelet rich fibrin in bone regeneration following tooth extraction. *R J of Oral Reh*2017; 9: 5-10.
- Oncu E and Alaaddinoglu E. The effect of platelet-rich fibrin on implant stability,Clinical Trial. *Int J Oral Maxillofac Imp* 2015; 30: 578-82.
- Tabrizi R, Arabion H and Karagah T. Does platelet-rich fibrin increase the stability of implants in the posterior of the maxilla? A split-mouth randomized clinical trial. *Int J Oral Maxillofac Surg* 2018; 47:672-675.

24. Salvi G and Lang N. Diagnostic parameters for monitoring peri-implant conditions. *Int J Oral Maxillofac Imp*2004;19:116–27.
25. Abraham H, Philip J, Kruppa J, Jain A and Krishnan C. Use of Chlorhexidine in Implant Dentistry. *Biomed Pharmacol J* 2015;8:1-3.
26. Van Hinsbergh, Collen A and Koolwijk k. Role of fibrin matrix in Angiogenesis. *Ann N Y Acad Sci* 2001; 936:426-437.
27. Mombelli A, Van Oosten M, Schurch E and Land N. The microbiota associated with successful or failing osseointegrated titanium implants. *Oral Mic Im* 1987; 2:145-151.
28. Sebastian G. Current status of indices of gingivitis. *J of clin period* 1986; 13: 375–378.
29. Minkle G, Vivek G, Vishal A and Bhargavi A. Implant Maintenance: A Clinical Update. *International Scholarly Research Notices* 2014; 2014 :1-8.
30. Shaimaa A, Sherif S, Ahmed M and Adham A. Study of the effect of the combination of platelet-rich fibrin (prf) and allogeneous bone graft around immediate implants. *Alex Dent J* 2017; 42: 127-134.
31. Yassir E, Sun W, Li S, Mengqing X and Cheng Y. Feasibility of CBCT in Evaluating Bone Density of Dental Implant Placement Sites. *Research & Reviews: J of Dent Sc* 2017; 5:87-91.
32. Barunawaty Y. Assessment of the increased calcification of the jaw bone with CT-Scan after dental implant placement. *Imag Sci Dent* 2011; 41: 59–62.
33. Tsai C, Shen S, Zhao J and Chang Y. Platelet-rich fibrin modulates cell proliferation of human periodontally related cells in vitro. *J Dent Sci* 2009; 4:130-135.
34. Dohan D, Diss A, Odin G, Doglioli P, Hippolyte M and Charrier J. In vitro effects of Choukroun's PRF (platelet-rich fibrin) on human gingival fibroblasts, dermal prekeratinocytes, preadipocytes, and maxillofacial osteoblasts in primary cultures. *Oral Surg Oral Med Oral Pathol Oral Radiol Endod* 2009; 108: 341-352.
35. Sun X, Zhou Y, Zhao J, Zheng L and Yang T. The effect of platelet-rich fibrin on biologic characteristics of osteoblasts. *Shanghai Kou Qiang Yi Xue* 2015; 24:61-4.