

Laparoscopic Tube Cystotomy as a New Trend for Treatment of Obstructive Urolithiasis in Small Ruminants

Mohamed Gomaa*, Nefissa H. Mekkawy, Mahmoud Abdel Maboud, Fathy D. El Seddawy and Ahmed Monir

Surgery, Anesthesia and Radiology Department, Faculty of Veterinary Medicine, Zagazig University, 44511, Egypt

Article History: Received: 4/11/2015 Received in revised form: 30/11/2015 Accepted: 16/12/2015

Abstract

The current study was planned to clarify the benefit from using laparoscopic tube cystotomy in treatment of obstructive urolithiasis especially in the cases that do not respond to urethral process amputation. For this purpose, 14 small ruminant cases were selected from 20 animals with obstructive urolithiasis. Another six cases that responded to urethral process amputation were also included. The disease was diagnosed based on clinical and ultrasonographic examinations. Laparoscopic tube cystotomy was performed by creating a diversion of urine from the urethra and voiding the urine temporarily from a foley catheter inserted inside the urinary bladder. In conclusion, this technique proved to be feasible in rams and bucks and can be used as an alternative to the open conventional tube cystotomy in cases of urine retention syndrome providing a minimal invasive tissue trauma and regaining the normal urination pathway in all treated cases.

Key words: Laparoscopy, Cystotomy, Small Ruminants, Urolithiasis

Introduction

Obstructive urolithiasis is a common disease of males, particularly castrated small ruminants, which often indicates the need for surgical procedure on the urinary system [1]. Various surgical techniques have been described in order to deal with obstructive urolithiasis, namely the urethral process amputation, penis amputation, perineal urethrostomy, tube cystotomy and urinary bladder marsupialization [2-6]. Laparoscopy offers a minimally invasive route to evaluate the abdominal cavity, assess abdominal organs and tissues and obtain a definitive diagnosis in a variety of diseases [7,8]. Surgical tube cystotomy has shown good success rate for the resolution of this disease in ruminants by creating a diversion of urine from the urethra, allowing time for urethritis to subside and the calculi to pass or dissolve [9-14]. Laparoscopic implantation of a urinary catheter in rams was previously performed successfully and was considered an alternative to tube cystotomy performed by laparotomy [15]. In sheep and goats, the determination of

free fluid within the abdomen, as well as visualizing the bladder by abdominal ultrasound, may be useful for the diagnosis and prognosis of this disease [16,17]. Therefore, the current study was planned to prove the value of laparoscopic tube cystotomy in the treatment of obstructive urolithiasis in small ruminants.

Material and Methods

A total of 20 animals (14 bucks and 6 rams) with urine retention admitted to the Surgery Department, Faculty of Veterinary Medicine, Zagazig University, Egypt during the period from 2012 till 2014 were included in the study. Their ages ranged from 6 to 18 months. These cases were subjected to thorough clinical and ultrasonographic examination using Esaote My Lab™ one vet (The Netherlands) 3.5/ 5MHz trans-abdominal transducer and 6 MHz linear transrectal transducer.

*Corresponding author e-mail: (Gomaasurgeon@yahoo.com), Surgery, Anesthesia and Radiology Department, Faculty of Veterinary Medicine, Zagazig University, 44511, Egypt.

The animals were six rams with obstructive urolithiasis, two of them responded well to urethral process amputation and four were subjected to laparoscopic tube cystotomy. Out of ten castrated bucks with obstructive urolithiasis and intact bladder, three responded well to urethral process amputation, while, seven were subjected to laparoscopic tube cystotomy. In addition, among the four non castrated bucks with obstructive urolithiasis and intact bladder, one responded well to urethral process amputation, while, three were subjected to laparoscopic tube cystotomy.

Blood urea nitrogen and creatinine levels were estimated in the serum of the diseased animals before and after laparoscopic surgical intervention using test kits. Furthermore urine analysis was applied on urine samples that collected aseptically from the bladder using Combi[®] 10 strips (Macherey- Nagel, Germany) to evaluate pH, specific gravity and blood concentration.

Laparoscopic tube cystotomy was performed using a surgical hydraulic table to provide the trendelenburg position of the animal during laparoscopic surgery with the head lower and the body on a 20° incline. The animals were under tranquilization using xylazine (Rompun[®]) in a dose of (0.05 mg/kg BW in bucks and 0.2 mg/kg BW in rams) I/M and local infiltration anaesthesia using

lidocaine 2% applied as 1 ml to each 1 cm wound length.

The ventral aspect of the abdomen was prepared for aseptic surgery. The telescope was attached to a xenon light source using a light guide cable, and then an endoscopic video camera was connected to the eye piece of the telescope allowing the image to be viewed on a monitor (Fig. 1A, B, C and F). A five mm stab incision was made at a point midway between the umbilicus and preputial orifice or 2 cm caudal to the umbilicus and slightly to the right for introduction of veress needle (Fig. 1E).

The abdominal wall was elevated using towel clamps then the veress needle was inserted perpendicular to the surface of the abdominal wall then directed caudo-lateral to avoid injury of the spleen (Fig. 2A). The hub of the veress needle was then attached to insufflations tube which has been attached to automatic gas insufflators (CO₂). Pneumoperitonium was established with a flow rate of 2L/min until a constant abdominal pressure of 13 mmHg was obtained. The intra-abdominal pressure was temporarily elevated to 16-18 mmHg and then reduced to 12-14 mmHg. The trocar-cannula unit with a 5 mm diameter (Fig.1D) was held with the base against the palm of the right hand and the index finger extended along the shaft of the trocar (Fig. 2B).

Table 1: Changes of serum urea and creatinine level in obstructive urolithiasis in rams and bucks

| | Animal species | Normal range* | Before treatment | 10 days after treatment | P-value |
|------------------|----------------|---------------|------------------|-------------------------|---------|
| Serum Urea mg/dl | Ram | 8-20 | 53.50±6.40 | 15.96±1.25 | <0.000 |
| | Buck | 10-20 | 55.3±1.4 | 12.3±0.4 | <0.000 |
| Creatinine mg/dl | Ram | 1.2-1.9 | 2.86±0.65 | 1.35±0.15 | 0.039 |
| | Buck | 1.2-1.82 | 2.3±0.05 | 1.40±0.05 | 0.039 |

* The normal ranged data had been reported by Pugh [43]

The trocar was inserted in twisting manner till penetration of the abdominal wall during which the sudden loss of resistance could be felt. The gas hose was removed from the veress needle and attached to the cannula to maintain the pneumoperitoneum. A straight 0° laparoscope with a 5 mm diameter and 60 cm

length was inserted through the primary cannula into the abdominal cavity. A second 5-mm portal site was selected in the left paramedian area.

The insertion of the second trocar- cannula unit was performed under the guide of the laparoscope to avoid injury of the internal

structures (Fig. 2C). The percutaneous insertion of 16-20 Fr. foley catheter using a metal stylet was performed in the caudal aspect of the right paramedian area (Fig. 2D,E,F and G).

Once the catheter was within the urinary bladder, the balloon was filled with 10 ml of sterile physiologic saline solution (injected with a syringe), and the inserted cannula was removed. The bladder was emptied by aspiration of urine. At the end of the laparoscopic procedure the whole abdomen was examined to detect any injury or bleeding.

The capnoperitoneum was deflated by opening the valve of the trocars, which were then removed. Portal sites were closed (muscle layer) with absorbable suture material in an interrupted horizontal mattress pattern and skin with non absorbable suture material by cross mattress suture pattern.

The extra-abdominal portion of the urinary catheter was fixed to the skin with a Chinese finger-trap ligature or simple interrupted suture pattern using silk and the catheter was left open. After surgery, each animal received tetanus antitoxin (1500 international units, SC), systemic antibiotic ampicillin in a dose of 15 mg /kg body weight /8hours/5 days and systemic anti-inflammatory as flunixin

meglumine in a dose of 4.4mg/ kg/ intramuscular/d. for three successive days.

Additionally, 10 gm of ammonium chloride dissolved in 400 ml of water were administered by mouth daily for one week [18,19]. Intermittent plugging of the foley catheter 4 hours/ day was done. The time of plugging was then periodically increased in relation to the animal tolerance till attaining the proper result (normal urination).

Abdominal ultrasonographic examination was performed before removal of the foley catheter to evaluate the condition of the internal organs, to detect if there was any leakage from the urinary bladder to the abdominal cavity, and to ensure that the foley catheter remains patent inside the lumen of the urinary bladder. Removal of the urinary catheter was performed 2-3 days after the animal started urination through the normal pathway.

Statistical Analysis

The statistical significance between collected laboratory data means was compared using Student's t-test; and (p <0.05) was considered significant. All data are presented as means ± standard deviation (SD) of the means. All tests were performed using the computer program SPSS, Inc. version 22 (IBM Corp. 2013, Armonk, NY).

Table 2: Changes recorded in urine sample from rams and bucks suffered from urine retention before and 10 days after treatment

| Item* | Before treatment | 10 days after treatment |
|------------------|-------------------------|--------------------------------|
| Color | Dark red | Straw yellow |
| PH | Ranged (8-9) | Ranged from (7.5-8) |
| Specific gravity | 1.005- 1.020 | 1.015- 1.020 |
| Blood | (++++) | (+) |
| Clarity | Turbid and viscous | clear |
| Odour | Bad offensive odour | Urinefrous odour |

*All items were with same value and/or range in rams and bucks.

Results

Ultrasonographic examination

Trans-abdominal ultrasonographic examination of the cases with urine retention revealed a distended bladder with anechoic urine and sometimes contained hyperechoic debris represented salts that appeared as multiple, tiny, uniformly distributed echoes. In some cases, hypoechoic masses attached to the wall of urinary bladder or freely movable in urine as inflammatory masses or blood clots were noted.

Trans-rectal examination showed a distended bladder and the full contour of the urinary bladder could not be detected. The proximal part of the pelvic urethra (neck of the bladder) was dilated in all animals with a diameter ranged from 1.33 to 2.3 cm (Fig. 3A).

Surgical intervention

Amputation of the urethral process

Amputation of the urethral process was performed as a first surgical attempt dealing with rams and bucks with obstructive urolithiasis with intact bladder. Six animals

urinated normally after this procedure, while re-obstruction was recorded in 14 animals which needed another approach.

Laparoscopic intervention

A laparoscopic tube cystotomy was successfully performed in 14 animals. Excellent access and visibility of the urinary bladder was achieved by the use of the previously described portal sites and trendlenburg (head and body down) position.

The urinary bladder was severely dilated, extended from the pelvic to the abdominal cavity with a tense and congested wall (Fig.2D). The dilation and tense bladder wall made the insertion of the urinary catheter through the wall much easier than that with an empty bladder.

Postoperative assessment

In the fourteen animals subjected to laparoscopic cystotomy, no complications were detected during or after laparoscopic surgical intervention. Urination through the urinary catheter was observed in all animals.

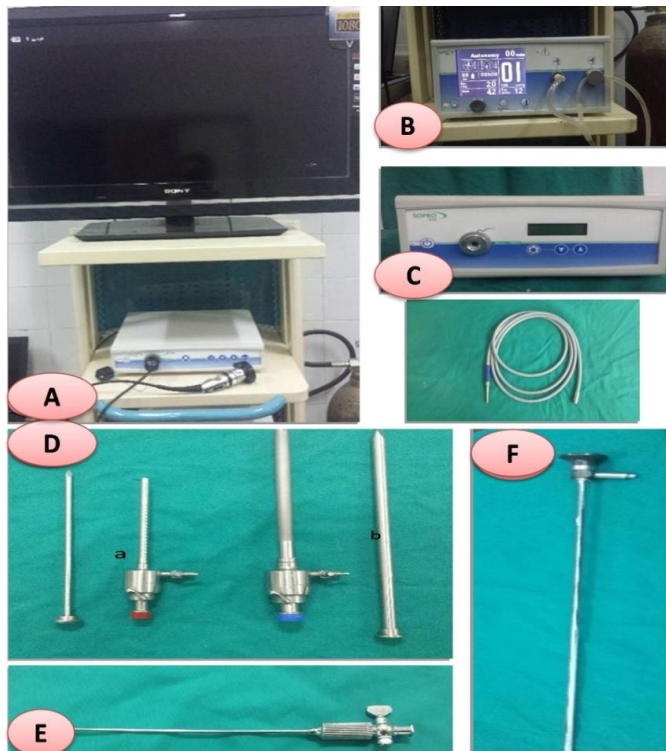


Figure 1: A laparoscopic camera connected to a camera control unit which in turn connected to a 42 inch colored Sony LCD monitor (A). Laparoscopic automatic insufflator together with co2 gas cylinder (B). A 100 watt xenon light source with flexible optic fiber light cable (C). Laparoscopic trocar and cannula unit, (a) 5.5mm cannula and its trocar (b) 11mm cannula and its trocar (D). Insufflation (Veress) needle provided with insufflator valve (E). 0° light angle, 5 mm diameter laparoscopic telescope (F).

Follow up information, via phone contact or periodic visiting, about the health condition of the animals and the time when the animals started urination through normal pathway, revealed that each animal had a good appetite and no clinical signs of abdominal pain were reported.

Ultrasonographic examination was performed during the periodic visiting of the cases, no leakage from the urinary bladder to the abdominal cavity was observed and the urinary catheter was patent inside the lumen of the urinary bladder (Fig. 3B).

Concerning the daily administration of ammonium chloride salts to all clinical cases, the time after surgery until urine was observed flowing from the normal urethra ranged from 3

to 14 days post-surgery and showed sometimes mild hematuria (Fig. 3C), then the urinary catheter was deflated and removed. Recurrence of urolithiasis was not recorded in treated animals.

Biochemical analysis

A significant elevation of both serum urea nitrogen and creatinine in the case of obstructive urolithiasis before interference in comparison to that after interference (Table 1).

Urine analysis

The urine of rams and bucks with obstructive urolithiasis had a dark yellow to dark red color with offensive odor. Chemical analysis of urine revealed the presence of protein urea and hematuria (Table 2).

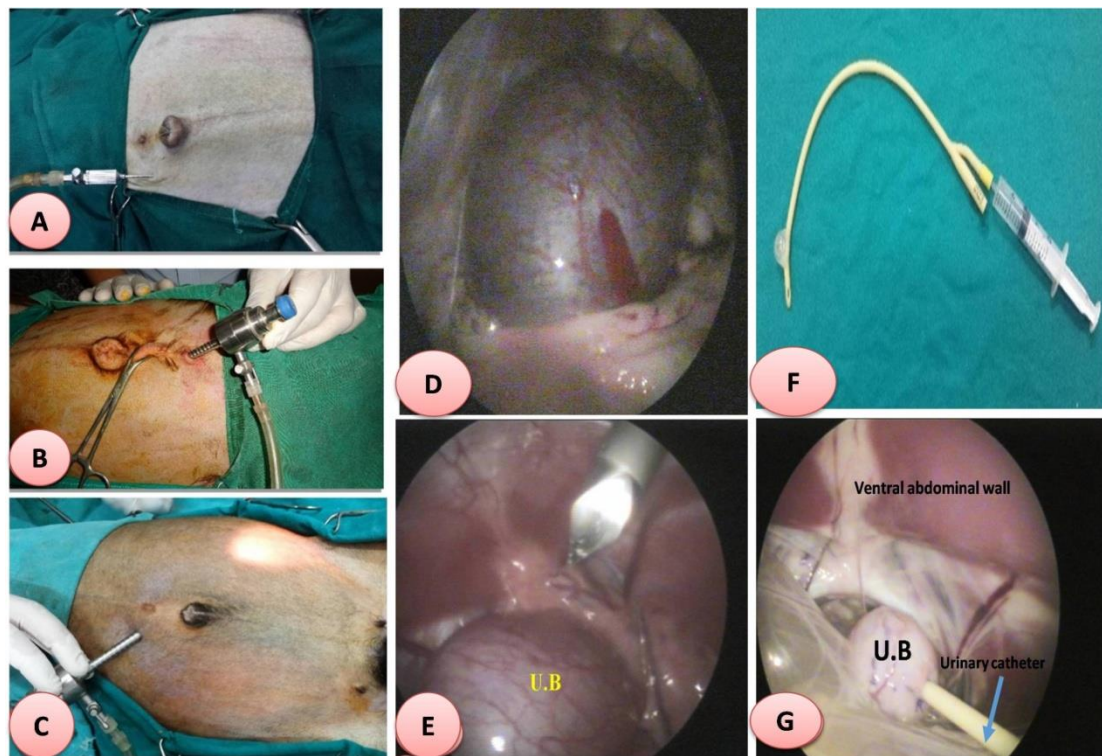


Figure 2: Showing the hub of the veress needle connected to insufflation tube (A). Primary port placement with connection to insufflation tube (B). Trans-illumination of the abdominal wall to detect the proper seat for the second trocar (C). A laparoscopic view showing a severely distended bladder with congested wall (D). Insertion of the second trocar- cannula unit under the guide of laparoscope (E). A 20 Fr. foley catheter with inflated balloon with normal saline (F). Showing the urinary bladder with foley catheter inside the abdominal cavity (G).

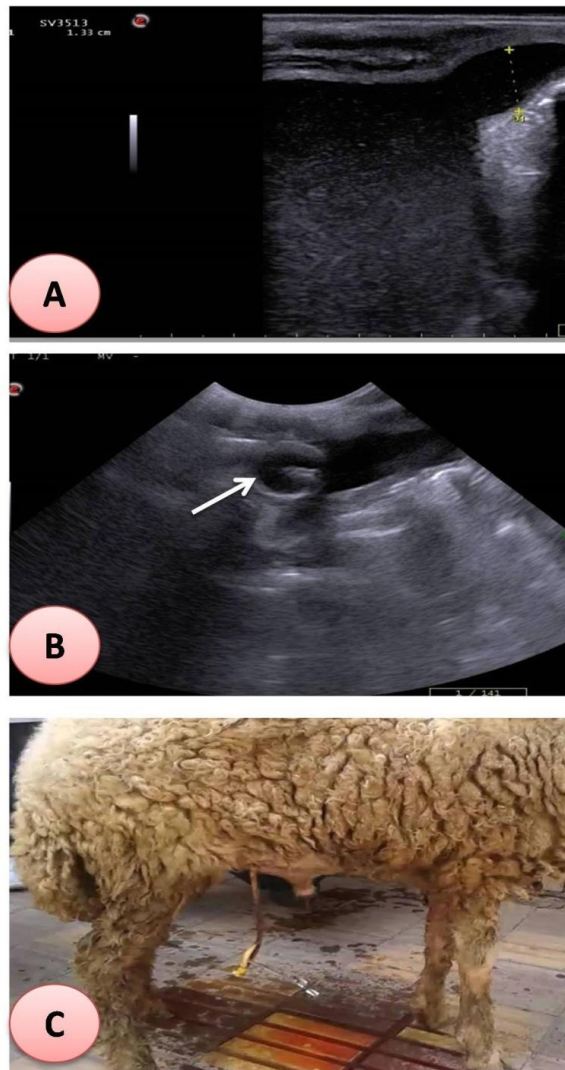


Figure 3: Showing trans-rectal ultrasonographic examination showing a distended bladder and the proximal part of the pelvic urethra was dilated with a diameter of 1.33cm (A). Trans-abdominal ultrasonographic examination showing the balloon of the urinary catheter (arrow) inside the lumen of the bladder without any leakage in the abdominal cavity (B). A treated ram with urinary catheter imbedded in the urinary bladder, and normal urination from urethral opening was recorded after 10 days from laparoscopic tube cystotomy and showed mild hematuria (C).

Discussion

In the present study, laparoscopic tube cystotomy was the surgical intervention of choice in order to deal with cases of obstructive urolithiasis in small ruminants. This procedure establishes urinary diversion allowing time for the inflammation of the lower urinary tract to subside and for the calculi to dissolve [10,11,13,18,20-22].

The over distention of the urinary bladder in cases of obstructive urolithiasis facilitate the insertion of foley catheter through the bladder wall as the wall become thin and more tensed.

Percutaneous technique was used for the insertion of the urinary catheter as a minimal invasive method resulting a good outcome [19,23].

In this study, foley catheters ranged from 16- 20 Fr. was preferred because they enabled the animal to push any blood clot without any straining. Moreover, foley catheters reduced the possibility of occlusion by any debris within the bladder and allowed any remains of urinary calculi to pass through [3,13,19,22].

Ultrasonography was used as a diagnostic tool in cases with urine retention. In cases of obstructive urolithiasis with intact bladder the urinary bladder appeared as anechoic distended spherical structure [17,24-26].

Hypoechoic masses were observed inside the urinary bladder in rams and bucks suffered from urine retention which were attached to the bladder wall or free in the lumen as inflammatory masses or blood clots accumulated inside the lumen of the urinary bladder. It was attributed to presence of inflammation in the urethra and urinary bladder and due to accumulation of blood clots accompanied the obstructive urolithiasis [17,24,27,28].

Pelvic urethra at the neck of bladder appeared trans-rectally dilated with anechoic urine in cases with obstructive urolithiasis with intact bladder, the diameter of which ranged from 1.33-2.3 cm. This observation coincided with that reported by others [24,26,29-31]. Post-operative care through exposure of the calculi to acidified urine by daily administration of ammonium chloride per os, was believed to play an assisting role in dissolving the calculi, reducing its size and density. Subsequently, regaining the normal urination pathway, keeping the integrity of the urethra and preserving the breeding potential of the animal [9,18,32,33]. In this study the time taken for a steady stream of urine to be observed from the normal pathway ranged from 3 to 14 days with daily administration of ammonium chloride as a urine acidifier, a similar result was recorded by others [19,23].

The removal of the urinary catheter was performed without any surgical intervention 24-48 hours after a steady stream of urine was observed during normal urination while the catheter was temporarily occluded from outside to ensure complete clearance of the urethra. This protocol was also used in earlier studies [9,13]. Concerning the ultrasonographic evaluation which was performed after treatment, the foley catheter was patent in the lumen of the urinary bladder without any displacement and no leakage from the urinary bladder was detected. Thus indicating good

short term outcome after tube cystotomy for the treatment of cases of urine retention. This result coincided with the finding of Ewoldt *et al.* [13].

The urine analysis in the present study revealed dark yellow to dark red color with offensive odor. The presence of proteinuria and hematuria was observed by biochemical analysis. This could be attributed to the inflammatory reaction of the urinary tract accompanied by urine retention [30,34-36]. There was a significant increase in the serum urea nitrogen in rams and bucks suffering from complete urine retention [26,31,36-39]. The increase in the serum urea nitrogen might be attributed to the obstruction of the urinary tract which is called post-renal azotemia. This is due to that the serum urea nitrogen normally passively diffused from the peritubular interstitium related to urine flow rate. The impaired ability to pass urine causes back pressure which in turn increases the back diffusion of urea [40-42].

Conclusion

In conclusion, the present study revealed that laparoscopic tube cystotomy in treatment of obstructive urolithiasis proved to be feasible in rams and bucks and can be used as an alternative to the open conventional tube cystotomy in cases of urine retention syndrome providing a minimal invasive tissue trauma with good results.

Conflict of interest

The authors declare that they have no conflict of interest.

References

- [1] Van Metre, D.C.; House, J.K.; Smith, B.P.; George, L.W.; Angelos, S.M.; Angelos, J.A. and Fecteau, G. (1996): Obstructive urolithiasis in ruminants: medical treatment and urethral surgery. *Compend Contin Educ Pract Vet*, 18: 317-327.
- [2] Ragab, G.A. and Saif, M.M. (1997): Urolithiasis in bull and buffalo bull calves in Beni-Suef governorate. Part I surgical management. *Sci. Cong. Egyptian Society for cattle disease*, 7-9 Dec., Assiut, Egypt.

- [3] Van Metre, D. (2004): Urolithiasis. In: Farm Animal Surgery, Eds. Fubini, S.L. and Ducharme, N.G. Saunders, W.B., New York, pp. 534-547.
- [4] Abdel-Fattah, M. and Sedeek, A.M. (2005): Dorsal versus ventral urethrotomy technique for treatment of obstructive urolithiasis in cattle calves. *Assiut Vet Med J*, 51 (106): 198-209.
- [5] Weaver, D.A.; Jean, G.St. and Steiner, A. (2005): Urolithiasis: Bovine surgery and lameness. 2nd Ed. Iowa, Blackwell Publishing. pp: 175-180.
- [6] Radostits, O.M.; Gay, C.C.; Hinchcliff, K.W. and Constable, P.D. (2007): Diseases of the Urinary System. In *Veterinary Medicine, A textbook of the diseases of cattle, sheep, pigs. Goats and horses*. 10th ed., Bailliere, Tindall, London, Philadelphia, Sydney, Tokyo, Toronto.
- [7] Higgs, P.J.; Chua, H.L. and Smith, A.R. (2005): Long term review of laparoscopic sacrocolpopexy. *BJOG*, 112 (8): 1134-1138.
- [8] Webb, C.B. (2008): Feline laparoscopy for gastrointestinal disease. *Top Companion Anim Med*, 23 (4):193-199.
- [9] Rakestraw, P.C.; Fubini, S.L.; Gilbert, R.O. and Ward, J.O. (1995): Tube cystostomy for treatment of obstructive urolithiasis in small ruminants. *Vet Surg*, 24: 498-505.
- [10] Palmer, J.L.; Dykes, N.L.; Love, K. and Fubini, S.L. (1998): Contrast radiography of the lower urinary tract in the management of obstructive urolithiasis in small ruminants and swine. *Vet Radiol Ultrasound*, 39: 175-180.
- [11] Iselin, U.; Lischer, C.J.; Braun, U. and Steiner, A. (2001): Cystostomy with and without temporary implantation of an urinary balloon catheter for treatment of obstructive urolithiasis in small ruminants: a retrospective study. *Vet Med Austria*, 88: 39-45.
- [12] Stratton-Phelps, M. and House, J.K. (2004): Effect of a commercial anion dietary supplement on acid-base balance, urine volume, and urinary ion excretion in male goats fed oat or grass hay diets. *Am J Vet Res*, 65: 1391-1397.
- [13] Ewoldt, J.M.; Anderson, D.E.; Miesner, M.D. and Saville, W.J. (2006): Short and long-term outcome and factors predicting survival after surgical tube cystostomy for treatment of obstructive urolithiasis in small ruminants. *Vet Surg*, 35: 417-422.
- [14] Van Metre, D.C. and Fubini, S.L. (2006): Ovine and caprine urolithiasis: another piece of the puzzle. *Vet Surg*, 35: 413-416.
- [15] Franz, S.; Dadak, A.M.; Schoeffmann, G.; Coppens, P.; Khol, J.L.; Baumgartner, W. and Dupre, G. (2008): Laparoscopic-assisted implantation of a prepubic-urinary catheter in male sheep. *J Am Vet Med Assoc*, 232: 1857-1867.
- [16] Monaghan, M.L. and Boy, M.G. (1990): Diseases of the renal system – ruminant renal system. In; SMITH. B. P.; *Large Animal Internal Medicine*. Mosby, USA, pp. 895-899.
- [17] Gomaa, M. (2005): Ultrasonographic examination of the abdomen in sheep and goats. M.V.Sc Thesis, Veterinary Surgery, Fac Vet Med, Zagazig Uni.
- [18] Cockcroft, P.D. (1993): Dissolution of obstructive urethral uroliths in a ram. *Vet Rec*, 132 (19): 486.
- [19] Sheih, I.S. (2007): Advanced studies on urinary disorders treated by surgical approach in some ruminants. PhD Thesis, Veterinary Surgery, Fac Vet Med, Zagazig Uni.
- [20] Bostedt, D. and Dedie, K. (1996): Harnwege. In: Bostedt D., Dedie K. (eds.): *Schaf- und Ziegenkrankheiten*. Ulmer, Stuttgart, pp: 617.
- [21] Pearce, S.G.; Dearo, A.C.; Howard, B.E. and Brisson, B.A. (2003): Management of obstructive urolithiasis and concurrent urethral rupture in a goat. *Aust Vet J*, 81: 268-270.

- [22] Fortier, L.A.; Gregg, A.J.; Erb, H.N. and Fubini, S.L. (2004): Caprine obstructive urolithiasis: requirement for 2nd surgical intervention and mortality after percutaneous tube cystostomy, surgical tube cystostomy, or urinary bladder marsupialization. *Vet Surg*, 33: 661-667.
- [23] Fazili, M.R.; Malik, H.U.; Bhattacharyya, H.K.; Buchoo, B.A.; Moulvi, B.A. and Makhdoomi, D.M. (2010): Minimally invasive surgical tube cystotomy for treating obstructive urolithiasis in small ruminants with an intact urinary bladder. *Vet Rec*, 166 (17): 528-531.
- [24] Braun, U.; Schefer, U. and Föhn, J. (1992): Urinary tract ultrasonography in normal rams and in rams with obstructive urolithiasis. *Can Vet J*, 33: 654-659.
- [25] Finn-Bodner, S.T. (1995): The urinary bladder chapter 12. In practical veterinary ultrasound by Cartee, R.E.; Selcer, B.A.; Hudson, J.A.; Finn-Bodner, S.T., Johnson, P.L. and Marish, K.W. Williams and Wilkins, USA. 200-235.
- [26] Scott, P.R. (2000): Ultrasonography of the urinary tract in male sheep with urethral obstruction. *In Practice*, 22 (6): 329-334.
- [27] Johanston, G.R.; Walter, P.A. and Feeney, D.A. (1986): Radiographic and ultrasonic feature of uroliths and other urinary tract filling defects. *Vet Clinical North Am of Small Animal Practice*, 16: 261-292.
- [28] Torad, F.A. (2005): Comparative studies on abdominal radiography and ultrasonography in pet animals. PhD Thesis, Veterinary Surgery, Fac Vet Med, Cairo Uni.
- [29] Hafez, A.M. and S.A. El-Khodery, 2001. Ultrasonography of health and diseased urinary system in sheep. Proceeding of the 2nd International Scientific Congress, April 8-9, Mansoura University, Rome and Sasiri Universities, Italy, pp: 445-458.
- [30] Scott, P.R.; Sargison, N.D. and Wilson, D. (2001): Ultrasonographic findings of urinary retention caused by vaginal stricture following dystocia in a ewe. *Vet Rec*, 10: 315-316.
- [31] Gouda, S. M. (2006): Clinical, biochemical and ultrasonographic studies on some urinary diseases in small ruminants. M.V.Sc Thesis, Internal Medicine, Fac Vet Med, Zagazig Uni.
- [32] Blood, D.C.; Radostitis, O.M. and Gay, C.C. (1995): Diseases of urinary system. In: veterinary medicine. A text book of the diseases of Cattle, sheep, pigs, goats and horses 8th Ed. p156-240. London, Bailliere, Tindall, Philadelphia, Sydney, Tokyo, Toronto.
- [33] Rakestraw, P.C., Fubini, S.L., Gilbert, R.O., Ward, J.O. (1995): Tube cystostomy for treatment of obstructive urolithiasis in small ruminants. *Vet Surgery*, 24 (6): 498-505.
- [34] Kaneko, J.J.; Harvey, J.W. and Bruss, M.L. (1997): Clinical biochemistry of domestic animals, 5th Ed, Academic press, London. P: 486.
- [35] Morin, D.E. and Badertscher, R.R. (1990): Ultrasonographic diagnosis of obstructive uropathy in a caprine doe, *J Am Vet Med Assoc*, 197(3):378-380.
- [36] Radostitis, O.M.; Gay, C.C.; Blood, D.C. and Hincheliff, K.W. (2003): Veterinary Medicine. A text book for the disease of cattle, sheep, pigs, goats and horses. 10th Ed., Bailliere Tindall, London: P: 479-500.
- [37] Tsuchiya, R. and Sato, M. (1990): Uremic changes included by experimental urinary retention in goats. *Nihon Juigake Zasshi*, 52(1): 113-119.
- [38] Badawi, A.M. (2000): Prevalent surgical affection of urogenital system in small ruminants. M.V.Sc Thesis, Veterinary Surgery, Fac Vet Med, Benha Uni.
- [39] Anderson, D.E. (2005): Urolithiasis in small ruminants MS, Diploma ACVS college of veterinary medicine, The Ohio State University.
- [40] Mekkawy, N.H.M. (1981): Experimental rupture of caprine urinary bladder with

- special study to metabolic changes. PH.D. Thesis, Veterinary Surgery. Fac Vet Med, Zagazig Uni.
- [41] Willard, M.D; Tvedten, H and Turnwald, G.H. (1999): Small animal clinical diagnosis by laboratory methods, W.B, Saunders Company; Philadelphia. P: 90-147.
- [42] Meyer, D.J. and Harvey, J.M. (2004): Veterinary laboratory medicine interpretation and diagnosis, 3rd Ed, Saunders, U.S.A.
- [43] Pugh, D.G. (2002): Sheep and Goat Medicine. Saunders Company. p: 452.

الملخص العربي

استخدام منظار البطن لزراعة الانبوب المؤقت داخل المثانة البولية كاتجاه جديد لعلاج الاحتباس البولي في المجرى البولي الصغيرة

محمد جمعة ، نفيسة مكاوي ، محمود عبد المعبود ، فتحى السداوى ، أحمد منير
قسم الجراحة والتخدير والأشعة- كلية الطب البيطري- جامعة الزقازيق- مصر

أعدت هذه الدراسة لتوضيح مدى الفائدة من استخدام منظار البطن لزراعة الانبوب المؤقت داخل المثانة البولية لعلاج الاحتباس البولي في ذكور المجرى البولي الصغيرة والتي لم تستجب لقطع الزائده الاحليلية واجريت الدراسة الحالية على ١٤ حيوان من اجمالى ٢٠ حيوان يعانى من الاحتباس البولي بينما استجابت ٦ حيوانات لعملية قطع الزائده الاحليلية وقد تم تشخيص المرض اكلينيكيًا وبالموجات فوق الصوتية. وقد أجريت بالمنظار وتغيير مجرى البول بشكل مؤقت باستخدام قسطرة فولي وإدراجها داخل المثانة البولية. اثبتت الدراسة امكانيه استخدام منظار البطن لزراعة الانبوب المؤقت داخل المثانة البولية في ذكور المجرى البولي الصغيرة باقل تأثير ممكن على حيوية الحيوان والحفاظ على سلامة مجرى البول وكانت هذه الطريقة مجديه وبديلة عن الجراحه التقليديه مع امكانية التبول بصورة طبيعية من مجرى البول فى جميع الحيوانات المعالجة.