

EUGENOL AMELIORATES PATHOGENIC FEATURES IN EXPERIMENTAL MODEL OF NAFLD IN RATS

BY

Maryam Hany Fawzi Azab Prof. Dr. Abtahal El Demerdash Zaki Dr. Noha Mohamed Said
Abdel Azim Dr. Doaa Mokhtar El Sherbiny

FROM

Demonstrator, Department of Drugs and Toxicology, Faculty of Pharmacy, Egyptian-
Russian University

Professor and Head of Drugs and Toxicology Department, Faculty of Pharmacy, Ain
Shams University

Lecturer, Department of Drugs and Toxicology, Faculty of Pharmacy, Egyptian-Russian
University

Lecturer, Department of Drugs and Toxicology, Faculty of Pharmacy, Ain Shams
University

Abstract:

Background: Nonalcoholic fatty liver disease (NAFLD) is emerging one of the major causes of chronic liver damage that includes a wide spectrum of liver injury ranging from steatosis to steatohepatitis evolving to fibrosis.

Aim: This study was designed to evaluate the possible effect of EUG on NAFLD induced by high fat cholesterol diet.

Methods: Rats were fed either normal rat chow diet (control) or high fat cholesterol diet and both received olive oil (10 mg/kg) for eight weeks to induce NAFLD model. Eugenol (10 mg/kg) was administrated to rats by oral intubation 3 times weekly for 8 weeks.

Results: Our results showed that EUG significantly ameliorated the histopathological lesions induced by HFCD. Furthermore, HFCD induced a significant elevation in liver enzymes (alanine aminotransferase (ALT) and aspartate aminotransferase (AST)). This was significantly attenuated by EUG co-treatment.

Conclusion: These findings indicate that EUG possess es a marked role in modulation of NAFLD.

Key words: eugenol; NAFLD.

Introduction:

Non-alcoholic fatty liver disease (NAFLD) is the hepatic manifestation of the metabolic syndrome. It represents a spectrum of disease, ranging from simple steatosis to steatohepatitis through to fibrosis and cirrhosis (**Than and Newsome, 2015**). Currently, NAFLD is recognized as the most common form of liver disease worldwide affecting between 25-30% of the general population. Frequently, it has been associated with obesity, type 2 diabetes mellitus, hyperlipidemia, and insulin resistance (**Berlanga et al., 2014**).

NAFLD hallmark is the excessive hepatic accumulation that results from an imbalance between lipid availability and lipid removal (Arguello *et al.*, 2015). Once the energy expenditure is less than energy intake, lipid overload can be found in organs such as adipose tissue organs (Shulman, 2014). As a consequence of excess lipid contents that spill over from the dysfunctional adipose tissue, ectopic lipid deposition in liver would occur (Stienstra *et al.*, 2010). This flux in particular is a major determinant of accumulation of hepatic and lipoprotein fat in NAFLD that induce marked liver injury (Loria *et al.*, 2008).

The effective therapy for NAFLD has not been established, but there are many proposed strategies and agents used for liver support (Yogalakshmi *et al.*, 2010). Nowadays, renewed attention to alternative medicines and natural therapies has stimulated new wave of research to look for more efficacious agents with lesser side effects. Eugenol (4-allyl-2-methoxyphenol) is a naturally occurring phenolic compound extracted from clove, basil, cinnamon and nutmeg (Yogalakshmi *et al.*, 2010). It has been used as: a fragrant and favoring agent (Nuchuchua *et al.*, 2009), in dentistry as a filling material and a pulp capping agent or as a neuroprotective (Kabuto *et al.*, 2007) and antibacterial (Kalemba and Kunicka, 2003). The hepatoprotective potentials of eugenol include anti-inflammatory, antioxidant (Jirovetz *et al.*, 2006) and anti-hyperglycemic effects (Srinivasan *et al.*, 2014). The present study was designed to evaluate the possible protective effect of EUG on NAFLD induced by high fat cholesterol diet (HFCD).

Materials and methods:

Drugs and chemicals:

Eugenol was purchased from Sigma Chemical Co. (USA) and dissolved in olive oil. Cholesterol, casein, and methionine were purchased from Medico pharm Co., for Pharmaceutical and Medicine (Cairo, Egypt). Vitamin mixture and mineral mixture were obtained from Misr feed additives company (Egypt). All other chemicals were of the highest available commercial grade.

Animals:

Forty male albino rats weighed 150–180 g were obtained from Nile Co. for pharmaceutical and chemical industries (Egypt). The normal chow was acquired from Meladco for Animal Food (Egypt). Pellets and tap water were provided ad libitum. Temperature was maintained at 25 °C. Rats were allowed at least 1 week to acclimatize to the lab conditions. The study protocol was approved by the Ethical Committee, Faculty of Pharmacy, Ain Shams University, Egypt.

Experimental design:

White albino rats were randomly divided into four groups (n = 10): group (1) fed normal rat chow diet and given olive oil (10mg/kg) orally 3 times weekly for 8 weeks and is considered as control group. Group (2) fed HFCD diet and given olive oil (10 mg/kg) orally 3 times weekly for 8 weeks and is considered as HFCD group. Group (3) fed high-HFCD diet and given EUG (10mg/kg) orally 3 times weekly for 8 weeks and is considered

as HFCD+EUG group. Group (4) fed normal rat chow diet and given EUG (10mg/kg) orally 3 times weekly for 8 weeks and is considered as EUG only group.

The high-fat high-cholesterol diet contained per 100 g, 58 gm rat show diet, 5 gm sucrose, 18 gm butter, 10 gm corn oil, 1 gm cholesterol, 5 gm casein, 0.2 gm methionine, 0.8 gm vitamins (vitamin mixture), and 2 gm minerals (mineral mixture).

After 8 weeks, fasting blood samples were collected from the retro orbital venous plexus, allowed to clot and serum was separated by centrifugation at 3000g for 15 min for biochemical assessment. Rats were then sacrificed; liver tissues were dissected out and washed with ice-cold saline. Then, parts from liver were fixed in 10% buffered formaldehyde for histopathological examination.

Biochemical analysis:

Serums alanine aminotransferase (ALT) and aspartate aminotransferase (AST), were determined by spectrophotometric method using commercially available kits (Teco Diagnostics, C.A., USA), and the results were expressed as IU/L.

Histopathological examination

For light microscopy, liver specimens were taken from the different lobes and fixed in 10% formalin and processed for paraffin sections of 4 μ m thickness. Sections were stained with hematoxylin and eosin (H & E) and evaluated under light microscope.

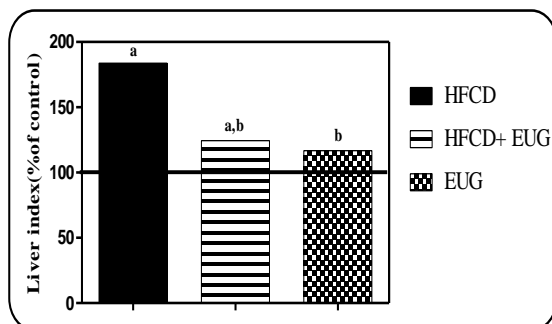
Statistical analysis

All data are expressed as mean \pm SD. Statistical analysis differences among groups were analyzed by one-way analysis of variance (ANOVA) followed by Tukey Kramer test as a post hoc test. Differences were considered significant at $p < 0.05$. All analyses were performed using InStat version 3 software package. Graphs were sketched using Graph Pad prism (ISI® software, USA) version 5 software.

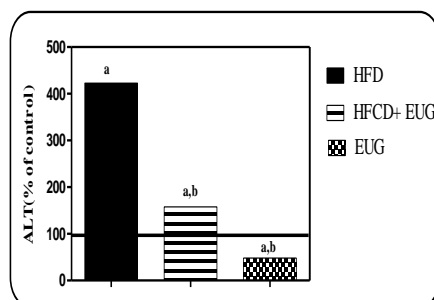
Results

Effect of Eugenol on liver index and liver enzymes

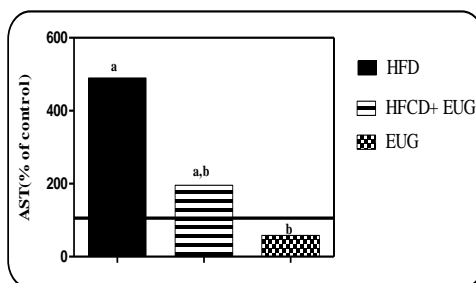
Body weight was monitored throughout the feeding period. After 8 weeks, there was significant increase in liver index ratio in HFCD group by 86% as compared to the control group. On the contrary, co-treatment with EUG significantly decreased the liver index by 30% as compared to HFCD group (Fig.1). Similarly, ALT and AST significantly increased in HFCD group by 3 folds as compared to the control group. EUG co-treated rats showed significant decrease in ALT and AST by 65 and 62%, respectively, as compared to HFCD group (Fig.2), (Fig 3), respectively.

Figure 1: Effect of EUG on liver index in rats fed HFCD :**Fig (1).Effect of EUG on liver index in rats fed HFCD.**

Rats were fed HFCD diet for 8 weeks, HFCD+ EUG, and EUG groups received EUG (10mg/kg) orally 3times weekly for 8 weeks .Data are represented as mean \pm S.D. (n=10). a, or b : significant difference from control, or HFCD groups, respectively at $p < 0.05$ using ANOVA followed by Tukey–Kramer as a post-hoc test.

Figure 2: Effect of EUG on serum level of ALT in rats fed HFCD :**Fig.(2): Effect of EUG on serum level of ALT in rats in rats fed HFCD.**

Rats were fed HFCD diet for 8 weeks, HFCD+ EUG, and EUG groups received EUG (10mg/kg) orally 3times weekly for 8 weeks. Data are represented as mean \pm S.D. (n=10). a, or b : significant difference from control, or HFCD groups, respectively at $p < 0.05$ using ANOVA followed by Tukey–Kramer as a post-hoc test.

Figure 3: Effect of EUG on serum level of AST in rats fed HFCD :**Fig.(3): Effect of EUG on serum level of AST in rats in rats fed HFCD.**

Rats were fed HFCD diet for 8 weeks, HFCD+ EUG, and EUG groups received EUG (10mg/kg) orally 3times weekly for 8 weeks .Data are represented as mean \pm S.D. (n=10). a, or b : significant difference from control, or HFCD groups, respectively at $p < 0.05$ using ANOVA followed by Tukey–Kramer as a post-hoc test.

Liver histopathological assessment

Rats fed normal chow diet showed normal hepatic architecture. Rats fed with HFCD diet showed liver steatosis, lobular inflammation, hepatocellular ballooning in diffuse manner all over the hepatocytes as nuclear pyknosis in the hepatocytes surrounding and adjacent the dilated central vein. HFCD+EUG group showed little congestion in the central vein with mild degeneration in hepatocytes (Fig4).

Figure4: Histopathological examination of liver using H&E stain

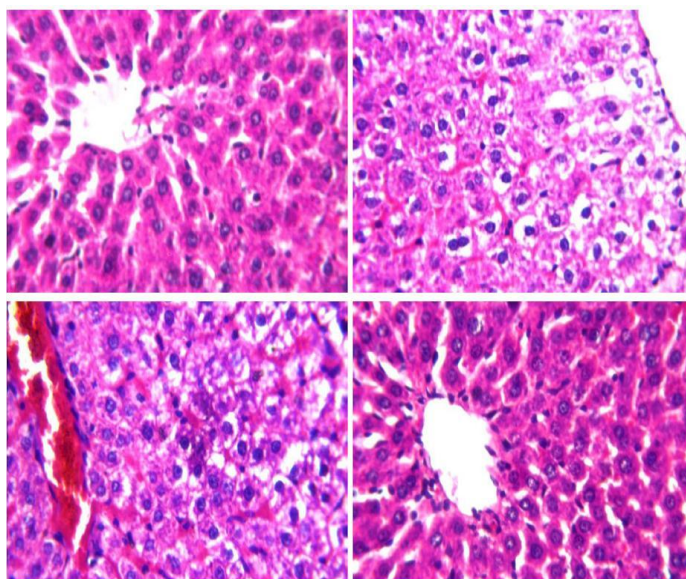


Fig. (4): *Photomicrographs of liver sections stained by haematoxylin and eosin ($\times 80$).*

A: section taken from rat in the control showing normal histological structure of the central vein (CV) and surrounding hepatocytes. **B:** section taken from rat in the HFCD group showing liver steatosis, lobular inflammation, hepatocellular ballooning in diffuse manner all over the hepatocytes. **C:** section taken from rat in HFCD+EUG group showing little congestion in the central vein with mild degeneration in hepatocytes. **D:** section taken from rat in EUG only group showing normal histological structure.

Discussion

NAFLD is a major health public issue due to its high prevalence and it is considered one of the major causes of chronic liver damage (Tilg and Moschen, 2008) . . Recently, EUG is of interest for many recent researchers because of its broad range of pharmacological and biological activities (Jo *et al.*, 2014). It has been used as anti-

inflammatory agent (**Huang et al., 2015**), anti-hyperglycemic agent (**Jeong et al., 2014**), and anti-oxidant agent (**Gulcin, 2011**). The present study was designed to assess the potential protective effect of EUG on IR in NAFLD model in rats.

In the present study, by feeding rats HFCD diet for 8 weeks, rat model of NASH, namely steatosis, was established in HFCD group, as indicated by significant elevation of plasma

ALT and AST activities which reproduce marked liver injury. These results are in alignment with previous study (**Yogalakshmi et al., 2010**). On the contrary, co-treatment with EUG showed significant decrease in hepatic enzyme levels. Our results were supported by previous study (**Srinivasan et al., 2014**).

An ideal animal model should display hepatic histopathologic and pathophysiologic features associated with NASH (**Hebbard and George, 2011**). In our model, increase in fat intake showed liver steatosis, lobular inflammation, hepatocellular ballooning in diffuse manner all over the hepatocytes. These results are in alignment with previous studies (**Xu et al., 2010; Takahashi et al., 2012**). On the other hand, EUG co-treatment ameliorated these changes. Our results are supported by previous study (**Venkadeswaran et al., 2014**).

Conclusion

In conclusion, EUG co-treatment significantly ameliorates NAFLD by modulating liver enzymes (ALT&AST) levels. Furthermore, histopathological results supported the hepatoprotective role of EUG against HFCD. The results of this study make EUG a promising dietary supplement to improve NAFLD.

REFERENCES

- Arguello G, Balboa E, Arrese M and Zanlungo S (2015)**. Recent insights on the role of cholesterol in non-alcoholic fatty liver disease. *Biochimica et Biophysica Acta (BBA)-Molecular Basis of Disease* **1852**(9): 1765-1778.
- Berlanga A, Guiu-Jurado E, Porrás JA and Auguet T (2014)**. Molecular pathways in non-alcoholic fatty liver disease. *Clinical and Experimental Gastroenterology* **7**: 221-239.
- Gulcin I (2011)**. Antioxidant activity of eugenol: a structure-activity relationship study. *Journal of Medicinal Food* **14**(9): 975-985.
- Hebbard L and George J (2011)**. Animal models of nonalcoholic fatty liver disease. *Nature Reviews. Gastroenterology and Hepatology* **8**(1): 35-44.
- Huang X, Liu Y, Lu Y and Ma C (2015)**. Anti-inflammatory effects of eugenol on lipopolysaccharide-induced inflammatory reaction in acute lung injury via regulating inflammation and redox status. *International Immunopharmacology* **26**(1): 265-271.
- Jeong KJ, Quan H-Y, Jo HK, Kim GW and Chung SH (2014)**. Effects of eugenol on hepatic glucose production and AMPK signaling pathway in hepatocytes and C57BL/6J mice. *Fitoterapia* **93**: 150-162.

- Jirovetz L, Buchbauer G, Stoilova I, Stoyanova A, Krastanov A and Schmidt E (2006).** Chemical composition and antioxidant properties of clove leaf essential oil. *Journal of Agricultural and Food Chemistry* **54**(17): 6303-6307.
- Jo HK, Kim GW, Jeong KJ, Do YK and Chung SH (2014).** Eugenol ameliorates hepatic steatosis and fibrosis by down-regulating SREBP1 gene expression via AMPK-mTOR-p70S6K signaling pathway. *Biological and Pharmaceutical Bulletin* **37**(8): 1341-1351.
- Kabuto H, Tada M and Kohno M (2007).** Eugenol [2-methoxy-4-(2-propenyl) phenol] prevents 6-hydroxydopamine-induced dopamine depression and lipid peroxidation inductivity in mouse striatum. *Biological and Pharmaceutical Bulletin* **30**(3): 423-427.
- Kalemba D and Kunicka A (2003).** Antibacterial and antifungal properties of essential oils. *Current Medicinal Chemistry* **10**(10): 813-829.
- Loria P, Lonardo A and Targher G (2008).** Is liver fat detrimental to vessels?: intersections in the pathogenesis of NAFLD and atherosclerosis. *Clinical Science* **115**(1): 1-12.
- Nuchuchua O, Saesoo S, Sramala I, Puttipipatkachorn S, Soottitantawat A and Ruktanonchai U (2009).** Physicochemical investigation and molecular modeling of cyclodextrin complexation mechanism with eugenol. *Food Research International* **42**(8): 1178-1185.
- Shulman GI (2014).** Ectopic fat in insulin resistance, dyslipidemia, and cardiometabolic disease. *New England Journal of Medicine* **371**(12): 1131-1141.
- Srinivasan S, Sathish G, Jayanthi M, Muthukumaran J, Muruganathan U and Ramachandran V (2014).** Ameliorating effect of eugenol on hyperglycemia by attenuating the key enzymes of glucose metabolism in streptozotocin-induced diabetic rats. *Molecular and Cellular Biochemistry* **385**(1-2): 159-168.
- Stienstra R, Saudale F, Duval C, Keshtkar S, Groener JE, van Rooijen N, et al. (2010).** Kupffer cells promote hepatic steatosis via interleukin-1 β -dependent suppression of peroxisome proliferator-activated receptor α activity. *Hepatology* **51**(2): 511-522.
- Takahashi Y, Soejima Y and Fukusato T (2012).** Animal models of nonalcoholic fatty liver disease/nonalcoholic steatohepatitis. *World Journal of Gastroenterology* **18**(19): 2300-2308.
- Than NN and Newsome PN (2015).** A concise review of non-alcoholic fatty liver disease. *Atherosclerosis* **239**(1): 192-202.
- Tilg H and Moschen AR (2008).** Insulin resistance, inflammation, and non-alcoholic fatty liver disease. *Trends in Endocrinology and Metabolism: TEM* **19**(10): 371-379.
- Venkadeswaran K, Muralidharan AR, Annadurai T, Ruban VV, Sundararajan M, Anandhi R, et al. (2014).** Antihypercholesterolemic and antioxidative potential

of an extract of the plant, Piper betle, and its active constituent, eugenol, in triton WR-1339-Induced hypercholesterolemia in experimental rats. *Evidence-Based Complementary and Alternative Medicine* 2014.

Xu ZJ, Fan JG, Ding XD, Qiao L and Wang GL (2010). Characterization of high-fat, diet-induced, non-alcoholic steatohepatitis with fibrosis in rats. *Digestive diseases and Sciences* 55(4): 931-940.

Yogalakshmi B, Viswanathan P and Anuradha CV (2010). Investigation of antioxidant, anti-inflammatory and DNA-protective properties of eugenol in thioacetamide-induced liver injury in rats. *Toxicology* 268(3): 204-212.

اليوجينول يحسن الخصائص المرضية في نموذج تجريبي للكبد الدهني غير الكحولي في الجرذان للسادة الدكتورة

مريم هانى فوزى عزب أ.د/ ابتهاج الدمرداش ذكى د/ نهى محمد سعيد عبد العظيم د/ دعاء مختار الشربيني

من

معيدة بقسم الأدوية والسموم- كلية الصيدلة الجامعة المصرية الروسية
أستاذ ورئيس قسم الأدوية والسموم - كلية الصيدلة-جامعة عين شمس
مدرس بقسم الأدوية والسموم- كلية الصيدلة- الجامعة المصرية الروسية
مدرس بقسم الأدوية والسموم- كلية الصيدلة-جامعة عين شمس

المقدمة:

مرض الكبد الدهني غير الكحولي يمثل طائفة من الأمراض، تبدأ بتشم كبدى بسيط مرورا بالتهاب الكبد الدهني وتصل إلى تندب وتليف الكبد و يتميز بتراكم الدهون فى خلايا الكبد و كثيرا ما يرتبط مع السمنة،داء السكرى ،فرط شحميات الدم، ومقاومة الإنسولين .

أهداف الدراسة :

الغرض من هذه الدراسة هو التحقق من التأثير المحتمل لليوجينول فى الكبد الدهني غير الكحولى .

التصميم التجريبي :

لقد تم توزيع الجرذان عشوائيا إلى أربع مجموعات حيث تلقت المجموعة الأولى من الجرذان حمية الطعام الطبيعي لمدة ثمانية أسابيع و تعتبر المجموعة الضابطة و تلقت المجموعة الثانية من الجرذان النظام الغذائى عالى الدهون و الكوليسترول لمدة ثمانية أسابيع و تعتبر مجموعة الكبد الدهني غير الكحولى و تلقت المجموعة الثالثة من الجرذان نظام غذائى عالى الدهون و الكوليسترول مع اليوجينول (١٠ مجم /كجم) عن طريق الفم لمدة ثمانية أسابيع و تعتبر مجموعة الكبد الدهني غير الكحولى المعالجة باليوجينول . و تلقت المجموعة الرابعة من الجرذان حمية الطعام الطبيعي مع اليوجينول (١٠ مجم /كجم) عن طريق الفم لمدة ثمانية أسابيع و تعتبر المجموعة المعالجة باليوجينول فقط.

الأستنتاج النهائى :

لقد أثبتت النتائج أن لليوجينول القدرة على تحسين مرض الكبد الدهني غير الكحولى من خلال تحسين الخصائص المرضية التي تم إحداثها بواسطة نظام غذائى عالى الدهون و الكوليسترول ومن خلال تحسين وظائف الكبد (الأنين ترانسفير و اسبرتات ترانسفير).