

## Short-Term Evaluation of Immediate Breast Reconstruction with Latissimus Dorsi Flap after Mastectomy

Ashraf Farok Abader, Gamal Fawzy Samaan\*, Ahmed Adel Ain Shoka, Yasmine Hany El-Zoheiry

Department of General Surgery, Faculty of Medicine – Ain Shams University, Egypt

\*Corresponding author: Gamal Fawzy, Mobile: (+20) 01220495554, E-Mail: dr.gamalfawzy@yahoo.com

### ABSTRACT

**Background:** The patient will have psychological benefits with immediate breast reconstruction, including reduced emotions of physical mutilation and impaired femininity, shorter surgical times, and lower costs. It simplifies the rebuilding process for the surgeon and enhances cosmetic outcomes.

**Objective:** This result was conducted to do short-term evaluation for breast reconstruction in breast cancer patients.

**Patients and Methods:** Our study was conducted on 40 patients diagnosed with breast cancer who underwent mastectomy followed by immediate breast reconstruction with latissimus dorsi (LT) myocutaneous flap.

**Results:** According to the information that is now available, immediate breast reconstruction is both oncologically safe and had no detrimental effects on the recurrence rate or the ability to identify and treat recurrences after a precise surgical dissection. Therefore, in virtually all situations when breast reconstruction is intended, using quick rebuilding of the breast is seen to be the best course of action. The most successful and efficient way of reconstruction was found to be LD flap surgery. Despite the significant skin pockets, the LD flap produced extremely good aesthetic results and symmetry in our patients in the shortest amount of time.

**Conclusion:** It was found that the use of LD flap is reliable and versatile method of breast reconstruction. It gives adequate tissues that obviates the use of prosthesis, and gives excellent satisfactory aesthetic results, with good matching and better quality of life.

**Keywords:** Latissimus dorsi, Modified radical mastectomy, Nipple areolar complex, Nipple sparing mastectomy.

### INTRODUCTION

The most prevalent type of cancer, breast cancer is also the second most common reason for death from cancer. The loss of a breast may significantly harm a woman's perception of her body and sense of beauty because a woman's breasts are the primary emblem of her femininity <sup>(1)</sup>.

Despite developments in conservative surgery, mastectomy is frequently the suggested surgical course of action. These include patients refusing breast conservative surgeries (BCS), recurrence after BCS, inadequate safety margin in breast conservative procedures, multifocal, multicentric tumours, centrally placed or locally progressed tumours, and multifocal, multicentric tumours <sup>(2)</sup>.

Breast renovation after mastectomy has grown in importance as a component of breast cancer patients' care throughout the past century. Breast reconstruction was first developed to lessen chest wall abnormalities and mastectomy-related problems. However, it is now understood that rebuilding can also enhance patients' psycho-social wellbeing and quality of life. Breast reconstruction's main objective is to restore shape and symmetry by addressing the anatomical defect while maintaining the patient's safety and health <sup>(3)</sup>.

Breast reconstruction that is performed immediately after a mastectomy is known as "immediate reconstruction," whereas delayed reconstruction is performed months or years afterwards. With quick repair, the aesthetic outcome, psychological impact, and cost of breast reconstruction are all improved. The fact that the mastectomy and reconstruction were performed together as opposed to as two separate procedures resulted in a reduction in

operating room time and inpatient hospital days, which contributed to the rapid reconstruction's overall cheaper cost. Immediate breast reconstruction has been proven to be oncologically safe in terms of local recurrence and survival. It doesn't affect adjuvant therapy and doesn't raise the likelihood of local or regional recurrence <sup>(4)</sup>.

Skin sparing mastectomy, Nipple areola sparing mastectomy, and skin sparing mastectomy include breast tissue removal techniques for quick breast reconstruction. The latissimus dorsi myocutaneous flap reconstruction produces in a breast with ptosis and projection while retaining the natural consistency and feel of normal tissue. Keeping the natural skin envelope helps with breast shaping during reconstruction. Due to the enormous surface area of the muscle, this flap offers sufficient mass for rebuilding <sup>(5)</sup>.

Seroma, hematoma, infection, hypertrophic scarring, partial flap necrosis, skin loss, locoregional recurrence, and dissatisfaction are among the complications of breast reconstruction <sup>(6)</sup>.

Through a multidisciplinary team approach, this study intended to prospectively measure general and aesthetic satisfaction, evaluate the influence on quality of life, and investigate the oncologic safety, cosmetic result, and technical viability of rapid breast reconstruction.

### PATIENTS AND METHODS

#### Patients

Our study was conducted on 40 patients diagnosed with breast cancer who underwent mastectomy followed by immediate breast reconstruction with

latissimus dorsi myocutaneous flap. These patients were enrolled in a combined prospective study and had a retrospectively gathered outcome analysis at the Department of Surgery Ain-Shams University Hospitals. Our patients were operated upon from January 2016 to January 2017 with minimal follow up of 12 months. A detailed evaluation programme was meticulously designed to ensure that each patient follows a disciplined regimen. All patients were assessed both before and after surgery.

The evaluation included patient's quality of life, patient satisfaction, oncology safety and wound complications. The satisfaction was measured according to scale to test the satisfaction level for each parameter of breast reconstruction. Prior to surgery and a year following reconstruction, all women were required to complete a questionnaire. Following surgery, all patients were monitored for 4-6 weeks to look for any signs of complications and to evaluate the cosmetic results.

**Inclusion criteria:** Patients with operable breast cancer, patients with multifocal tumours, multicentric, patients with centrally located tumours and patients with inadequate safety margin in breast conservative surgeries (BCS) or recurrence after BCS.

**Exclusion criteria:** Patients with systemic metastasis, patients unfit for surgery according to American Society of Anesthesiologists (ASA III, IV or V) and patients with advanced systemic disease.

#### **Methods:**

All patients were subjected to preoperative assessment, full clinical history, full clinical examination, full labs and radiological examination and preoperative photography.

**Intraoperative assessment:** 40 cases were operated upon by mastectomy where surgery options included modified radical mastectomy, skin-sparing mastectomy, and nipple-areola complex-sparing mastectomy.

#### **Preoperative marking was done for all the patients:**

Prior to surgery, the patient is marked standing up. A line for the circum-areolar incision in skin-sparing mastectomy was created, a line for the inframammary or circum-areolar incision in nipple-saving mastectomy, and a line for the elliptical incision in MRM were made. Skin ellipse on the donor location (back) was planned.

#### **Operative techniques:**

**Mastectomy:** In the majority of our cases, skin-sparing mastectomy (SSM) was done via a circum-areolar incision, and the NAC and breast tissue were removed by elevating the skin flaps. The inframammary fold remained intact. Skin-sparing mastectomy and preservation of the nipple-areolar complex are combined in nipple sparing mastectomy. The skin's ellipse was captured using modified radical mastectomy (MRM).

The clavicle is elevated superiorly, the latissimus dorsi anterior border laterally, the sternal border medially, and the rectus muscle attachment inferiorly. The breast is then removed from the superomedial to the inferolateral borders via the pectoralis major fascia. The skin envelope was filled in after a mastectomy utilising an immediate breast reconstruction method. The thoracodorsal vessels and the anterior LD muscle were also discovered. The patient was placed in the lateral decubitus posture for the LD flap harvest. In the back, a skin incision was made, and the muscle was accessed by cutting through the subcutaneous tissue.

The muscle flap must then be fully released and elevated from its origin. Detach the muscle's superior border from the scapula's tip after the muscle has fully reflected. The vascular pedicle of the muscle is seen as it is dissected in the direction of the axilla. Some surgeons perform thoracodorsal nerve transects to reduce muscle mass and avoid recurrent muscular contractions. After the LD flap has been fully lifted, focus was shifted to build a tunnel to the breast defect. The pectoralis major muscle is detached from its rib-based origin and sewn to the superior side of the latissimus dorsi muscle or directly to the mastectomy skin flap to create a natural, drooping breast. On its inferior aspect, the latissimus dorsi muscle is sutured to the rectus abdominis muscle, and on its lateral aspect, it is sutured to the serratus anterior muscle. This is how a submuscular pocket is formed.

**Postoperative assessment:** All patients underwent periodic postoperative follow-up evaluations beginning 4-6 weeks following surgery in proportion to time scale (1,6,12, and 18 months), including physical examinations and breast imaging to look for any signs of local or loco-regional recurrence and distant metastases. To evaluate the procedure's oncologic safety, seroma, hematoma, and infection at the donor site, as well as fat necrosis. The patients' post-surgery images were captured.

**Assessment of cosmetic outcomes** by three different groups: the patients, a medical panel (breast surgeon and breast clinic nurse).

Utilizing the breast- questionnaire, the patient's perspective is evaluated. The domains of health-related (HR), quality of life (QoL), and patient satisfaction make up the breast-conceptual Q's framework. Physical, psychological, and sexual well-being are all parts of HR-QoL.

Questions on emotional well-being, self-confidence, resemblance to other women, and beauty are all part of the psychosocial well-being domain.

Questions pertaining to neck, upper back, shoulder, arm, rib, chest muscle, and back problems, difficulty raising or moving the arms, tightness, soreness, pains, length of the back scar, and arm weakness are all included in the domain of the chest and back's physical well-being.

Also, patient satisfaction includes breast satisfaction, which includes breast attractiveness and clothes and bra fit. Pleasure with the treatment and the overall result.

By reviewing the images and evaluating the symmetry, inframammary line, projection, ptosis, and scarring, the operating surgeon also evaluated the results after the event. A scale from I to IV was used to determine the degree of satisfaction for each breast reconstruction parameter.

The following were the patients' and medical panel's estimates of the symmetry of the nipple and breast based on the Harris scale: Skin distortion that is good to minimum with retraction, edoema, or an absent nipple-areolar complex, fair to severe distortion with significant hyperpigmentation and bad to visible distortion with edoema. Excellent to perfect symmetry with no visible skin alteration distortion.

**Ethical approval:** After explaining the whole scope of the procedure, its benefits and drawbacks, realistic expectations, and all potential intra-operative, early post-operative, and late post-operative issues to each patient, Ain Shams University Ethics Committee granted its clearance. Throughout the course of the trial, the same surgical team performed all surgeries. This study's findings were used to evaluate breast reconstruction in breast cancer patients over the short-term. The declaration of Helsinki for human beings, which is the international medical association's code of ethics, was followed during the conduct of this study.

**Statistical Analysis**

Statistical package for Social Science was used to review, code, tabulate, and introduce the acquired data to a computer (SPSS 20). Data were given, and the type of data gathered for each parameter was appropriately analysed. For numerical data, the mean ± standard deviation (SD), and range were used. The statistical significance of the difference between two means assessed twice for the same research group was evaluated using a paired t-test.  $P \leq 0.05$  was regarded as significant.

**RESULTS**

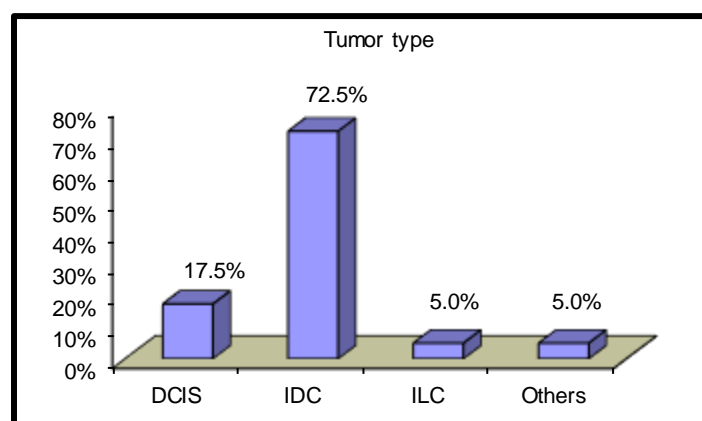
Table (1) showed that this study includes forty female patients with a mean age of 41 years (range from 28- 60 years) who underwent immediate reconstruction with latissimus dorsi flap. From those 40 patients, 35 patients (87.5%) were premenopausal and 5 patients (12.5%) were postmenopausal. 14 patients (35%) with positive family history of breast cancer. All of them had no medical problems except 7 patients (17.5%) had diabetic and 10 patients (25%) hypertensive and obese. 2 patients (5%) with history of smoking. All the patients' body weights ranged from 55 -104 kg with mean weight 78 kg.

**Table (1):** Sociodemographic data.

		<b>Total no. = 40</b>
Age (Years)	Mean ± SD	41.43 ± 8.69
	Range	28 – 60
Weight (kg)	Mean ± SD	78.85 ± 13.76
	Range	55 – 104
Height (cm)	Mean ± SD	161.28 ± 7.14
	Range	153 – 182
BMI (kg/m <sup>2</sup> )	Mean ± SD	30.40 ± 5.39
	Range	20 – 37
Occupation	House wife	22 (55.0%)
	Employed	18 (45.0%)
Marital state	Married	27 (67.5%)
	Single	13 (32.5%)
Smoking	Yes	2 (5.0%)
	No	38 (95.0%)
Family history	Yes	14 (35.0%)
	No	26 (65.0%)
Menopausal	Premenopausal	35 (87.5%)
	Postmenopausal	5 (12.5%)

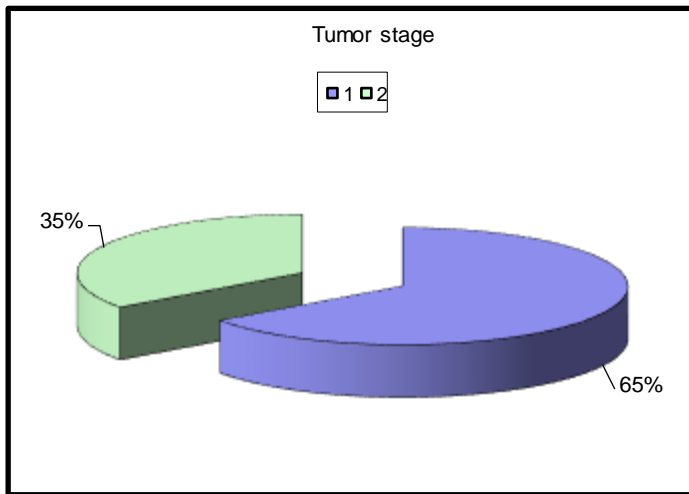
**Pathology results**

29 patients (72.5%), by the histological evaluation of biopsies, had stage II and stage III breast cancer had invasive duct carcinoma, 7 patients (17.5%) had DCIS, 2 patients (5%) had invasive lobular carcinoma, and 2 patients (5%) had others (Figure 1).



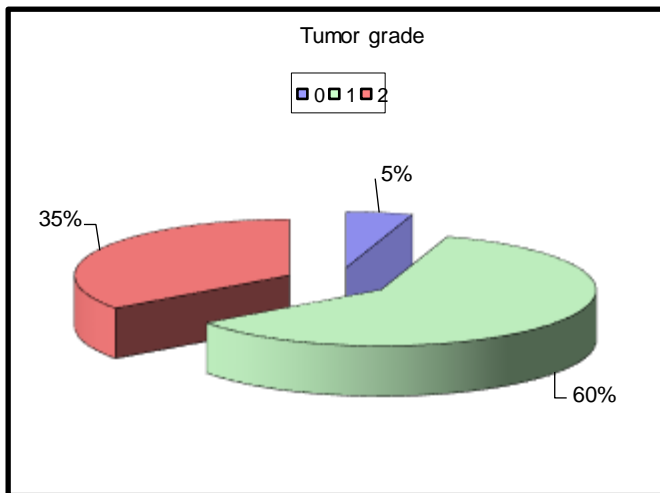
**Figure (1):** Tumor type.

After the staging (TNM) of the patients that had undergone immediate reconstructions, Stage I (T1N0) included 26 patients with an overall incidence 65% and stage II (T1N1, T2N0 and T2N1) included 14 patients with an overall incidence 35% (Figure 2).



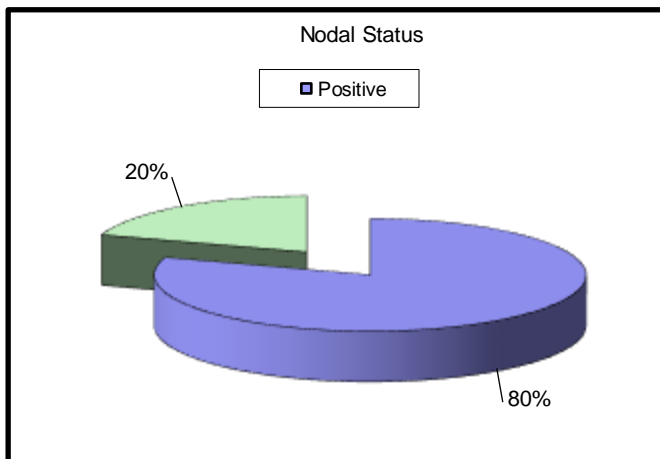
**Figure (2):** Tumor stage.

2 patients (5%) Grade I, 24 patients (60%) Grade II and 14 patients (35%). Grade III tumor (Figure 3).



**Figure (3):** Tumor grade.

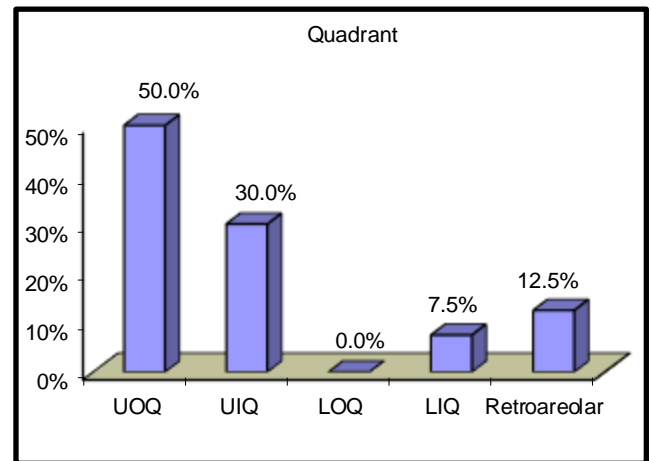
The mean tumor size was 3.6 cm (range, 2 -5 cm). Axillary lymph nodes were found to be negative for tumor metastases in 8 patients (20%) compared to positive nodes in 32 patients (80%) (Figure 4).



**Figure (4):** Nodal status.

Post mastectomy radiation was given to 26 patients (65%) with 4 axillary lymph node metastases

(N2). Five patients had multi-centricity found in them. Excision margins varied from 1.2 to 7 cm. Margin was negative for all patients. The most common quadrant to be affected is the upper outer quadrant (UOQ) seen in 20 patients of the studied group (50%). While the UIQ was 12 patients (30%), LIQ was 3 patients (7.5%), retro-areolar was 5 patients (12.5%), no patients in LOQ (Figure 5).



**Figure (5):** Quadrant.

**Operative time**

Operative time ranged from 4 hours up to 5 hours and 30 minutes with a mean of 4.5 hours. There were 9 patients (22.5%) of modified radical mastectomy (MRM), 21 patients (52.5%) of skin-sparing mastectomy (SSM), and 10 patients (25%) of nipple-sparing mastectomy (NSM). The mean blood loss was (520cc) in the LD flap, 8 patients (20%) received blood transfusion. The hospital stay ranged from 2-4 days with a mean of 3 days.

**Oncologic results**

Tamoxifen was given as adjuvant hormonal treatment to 31 patients (or 77.5%). Adjuvant chemotherapy, which included cyclophosphamide, methotrexate, and fluorouracil, was given to 21 patients (52.5%). For 12 patients, postoperative chemotherapy began at the scheduled time. Due to partial flap necrosis and fat necrosis, the start of treatment was delayed in 9 patients. Neoadjuvant chemotherapy was administered to 17 patients (42.5%).

Only two patients (5%) in the study group displayed local recurrence, which became apparent during follow-up after a year. She presented with a small nodule and showed no signs of regional or systemic recurrence. A true cut biopsy was performed, and its histopathological analysis revealed that it was fat necrosis, which was treated with local excision and postoperative radiotherapy.

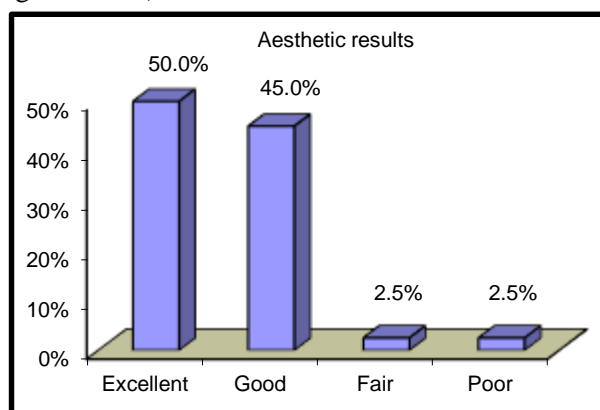
A 50-year-old lady who had undergone SSM for invasive ductal carcinoma experienced a second occurrence of local recurrence. Six months following surgery, the patient had an ipsilateral axillary

recurrence with false-negative sentinel lymph nodes. At the time of this follow-up, the patient was still alive and clear of disease progression after undergoing postoperative chemotherapy and radiation therapy.

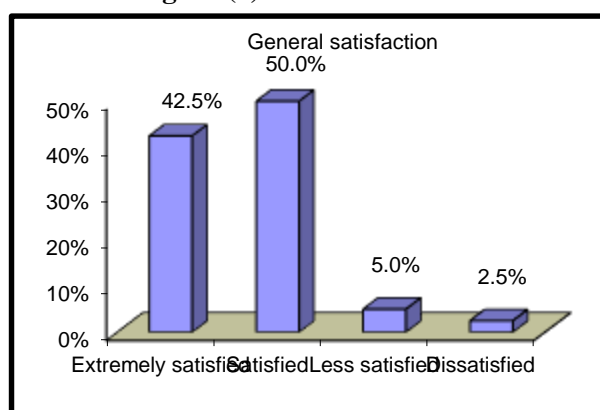
In one case (2.5%), distant mets were found in the form of a lung nodule and liver metastasis. The overall breast cancer-specific survival rate was 2.5% since there was just one patient who died from cancer.

**Cosmetic results**

35 patients understand the concept of breast reconstruction after mastectomy, while 5 patients are completely unaware of the concept. A questionnaire was administered to 40 patients with breast cancer, and the results were as follows: 20 patients (50%) showed excellent aesthetic results and 17 patients (42.5%) were extremely satisfied with the general operational result, 20 patients (50%) were satisfied with the cosmetic result, 18 patients (45%) had good aesthetic outcome, 1 patient (2.5%) had fair aesthetic outcome and 2 patients (5%) were less satisfied and only 1 patients (2.5%) showed poor aesthetic result and 1 patient (2.5%) was dissatisfied (Figures 6 & 7).



**Figure (6):** Aesthetic results.



**Figure (7):** General satisfaction.

Two patients had anxiety or despair in the first three months after surgery. One patient utilised tranquillizers, while another needed further psychological care in six weeks. During the first several weeks following surgery, all patients abstained from employment. Within six weeks of surgery, all but

10 patients were back at their previous vocational level. 20 patients reported general satisfaction with the reconstructive technique during the extended post-operative period (>3 months). Thirty patients embraced the new breast as an integral part of their bodies, and 25 patients considered the final outcome exceeded their initial expectations. In 31 cases, both breasts were almost symmetrical, and in 9 cases, ptosis of the healthy breast was seen (Table 2).

**Table (2):** Cosmetic outcome

		No.	%
General satisfaction	Extremely satisfied	17	42.5%
	Satisfied	20	50.0%
	Less satisfied	2	5.0%
	Dissatisfied	1	2.5%
Aesthetic results	Excellent	20	50.0%
	Good	18	45.0%
	Fair	1	2.5%
	Poor	1	2.5%
Symmetrical	Yes	31	77.5%
	No	9	22.5%
Anxiety or depression	Yes	2	5.0%
	No	38	95.0%
Need psychological support	Yes	3	7.5%
	No	37	92.5%
	No	39	97.5%

**Complication:**

30 patients passed uneventful course, only 10 patients had complications. Early postoperative complication occurred in 10 patients including partial flap necrosis of the distal part of the skin envelope in 3 patients, and was controlled by the removal of dead tissues. Following conservative therapy, the conditions of 3 patients who had superficial skin flap necrosis in the form of mottling transitory colour changes had improved. Hematoma in 3 patient (7.5%), fat necrosis in 3 patient (7.5%) and donor site seroma in 31 patient (77.5%) and was managed conservatively with complete recovery within 3 weeks. Late complications included hypertrophic scar in 2 patients (5%) and shoulder and anterior chest wall pain in 20 patients (50%). 2 Patients had wound infection, one of them treated conservatively by antibiotic and the second treated by antibiotic, drainage, follow-up and secondary suture. One patient received a skin flap repair of her areola and nipple as part of the second stage of her breast surgery (Figure 8).

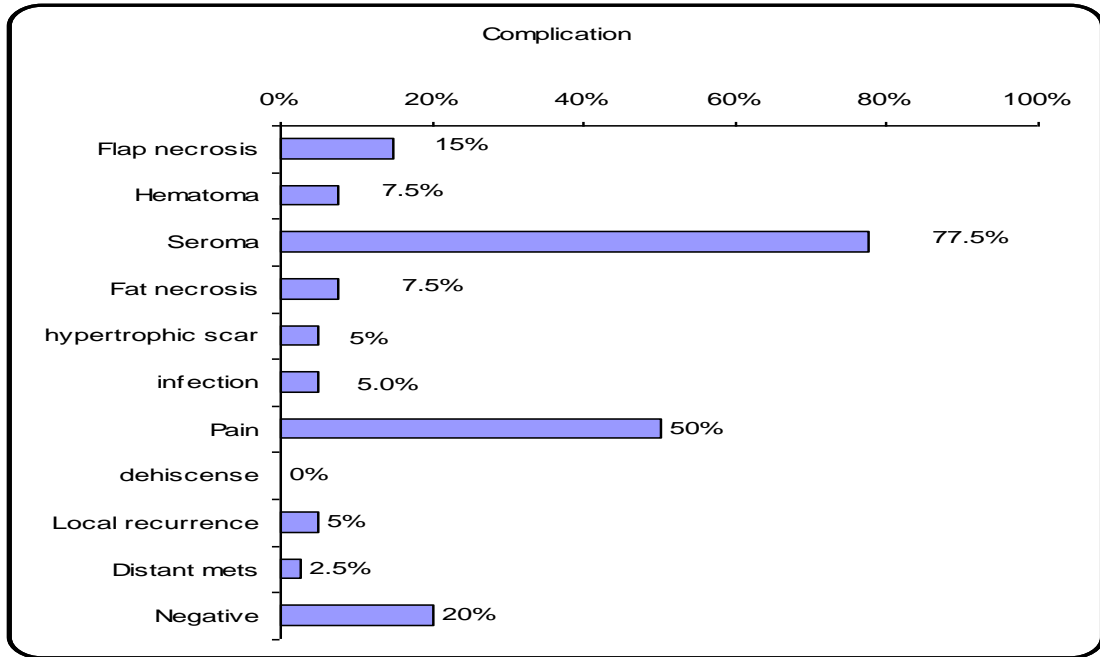


Figure (8): Complication.

### Questionnaire for patients for their opinion about immediate breast reconstruction

استبيان عن رأي المرضى عن اعادة بناء الثدي

الاسم: .....

السن: .....

العمل: .....

الحالة الاجتماعية: .....

عدد الاولاد: .....

سبب استئصال الثدي: .....

مدة المتابعة بعد العملية: .....

بدء علاج كيمواوى بعد العملية: بمدة: ..... ولمدة: .....

بدء علاج اشعاعى بعد العملية: بمدة: ..... ولمدة: .....

بدء علاج هرمونى بعد العملية: بمدة: ..... ولمدة: .....

هل أثرت العملية على الحالة الاجتماعية؟ نعم: ..... لا: ..... كيف: .....

هل أثرت العملية على الحالة النفسية؟ نعم: ..... لا: ..... كيف: .....

هل أثرت العملية على الحالة الصحية؟ نعم: ..... لا: ..... كيف: .....

هل أثرت العملية على العلاقة الزوجية؟

نعم: ..... لا: ..... كيف: .....

هل تعلمين ان هناك عمليات لاعادة بناء الثدي؟ نعم: ..... لا: ..

كيف توصلتى لذلك: .....

## DISCUSSION

The most important emblem of a woman's femininity is her breasts. Immediate breast reconstruction seeks to restore shape and symmetry by fixing the anatomical problem while safeguarding the patient's wellbeing<sup>(3)</sup>.

The advent of skin-sparing mastectomy, which provides aesthetic benefits without compromising the oncological prognosis, has made immediate reconstruction easier<sup>(7)</sup>.

Our study was conducted on 40 patients diagnosed with breast cancer who underwent mastectomy followed by immediate breast reconstruction with latissimus dorsi myocutaneous flap. This study was conducted to do short-term evaluation for breast reconstruction in breast cancer patients. We compared our final results with the results of previously published studies in order to know where we stand and to achieve a solid base for patient selection and safety.

The mean age of our participants was 41 years (range from 28-60 years) and the operative time ranged from 4 hours up to 5 hours and 30 minutes with a mean of 4.5 hours depending on the breast size.

Recently, no significant difference in local recurrence was seen between 1,104 patients with SSM and IBR and 2,635 patients with conventional mastectomies without reconstruction in a meta-analysis of nine trials involving 3,739 participants. According to **Sandelin et al.**<sup>(8)</sup> retrospective review of 203 patients who were followed up for a long time, 13 patients (6.4%) had LRRs, and 7 of them were still living. Therefore, even in women with LRR, IBR does not compromise the oncological result. Even if the patient has an LRR, systemic illness rather than local recurrence is more important for survival.

Only two patients (5%) in the study group displayed local recurrence, which became apparent during follow-up after a year. She presented with a small nodule and showed no signs of regional or systemic recurrence. A true cut biopsy was performed, and its histopathological analysis revealed that it was fat necrosis, which was treated with local excision and postoperative radiotherapy.

The second case of local recurrence involved a 50-year-old woman who had undergone SSM for invasive ductal carcinoma. Six months after the surgery, the patient experienced ipsilateral axillary recurrence along with false-negative sentinel lymph nodes. The patient underwent postoperative chemotherapy and radiation therapy and is still alive and free of disease progression at the time of this follow-up. According to **Taylor et al.**<sup>(9)</sup> IBR does not significantly delay the discovery of recurrent illness or the start of adjuvant chemotherapy, nor does it have a negative impact on the disease-free state or overall survival.

**Ho et al.**<sup>(10)</sup> 30 NSSM specimens' skin and subcutaneous tissue underwent histological investigations, and it was discovered that 23% (7 of 30) of the instances involved skin flaps other than the NAC. The affected skin was located right above the tumour in five of the instances.

Adjuvant chemotherapy did not significantly increase the likelihood of surgical complications, according to a research by **Caffo et al.**<sup>(11)</sup> involving 166 patients. **Roy et al.**<sup>(12)</sup> assessment of 111 instances showed the treatment to be safe because no sequelae that may have been life-threatening were found.

In one case (2.5%), distant mets were found in the form of a lung nodule and liver metastasis. The overall breast cancer-specific survival rate was 2.5% since there was just one patient who died from cancer. The primary problems in our investigation happened early in the monitoring period.

Only 31 people experienced flap complications, and this woman was obese, diabetic, and hypertensive, so she also had health issues. She also has a chest wall tight scar from radiation treatment. All of these elements help to cause problems like ischaemia and flap sloughing.

Early postoperative complications, such as partial flap necrosis of the distal region of the skin envelope in 3 patients, occurred in 10 patients and were treated by debridement of dead tissues. 3 patients had superficial skin flap necrosis visible as mottling transitory colour changes, and their condition improved as a result of conservative care.

**Kroll et al.**<sup>(13)</sup> contrasted his latissimus dorsi flap to implant and TRAM reconstructive experiences. When he used the latissimus dorsi flap vs expander with implant reconstruction, they noticed that complications and reconstructive failure were substantially fewer and on par with those seen with TRAM surgeries.

**Alderman et al.**<sup>(14)</sup> demonstrated that immediate reconstructions have considerably higher total and severe complication rates in a prospective cohort analysis of 326 patients.

**Salberg et al.**<sup>(15)</sup> revealed a low (3.9%) risk of total problems, including infection, skin necrosis, and hematoma. However, the likelihood of postoperative complications may also be influenced by the surgeon's skill conducting IBR. According to a prospective study by **Yang et al.**<sup>(16)</sup>, patients who underwent immediate breast reconstruction with latissimus dorsi flap within a year experienced a return of shoulder strength and range of motion to pre-surgical baseline values, even though functional disability and quality of life associated with the flap procedure remained below baseline (as measured by the disabilities of the arm, shoulder and hand [DASH] questionnaire and the physical component of the Quality of Life Index).

There was a dearth of research on breast reconstruction results and patient satisfaction. One of the rare studies that addresses the satisfaction outcomes and objective aesthetic outcomes for patients who have had mastectomy with immediate LD flap reconstruction is the one we conducted.

20 patients (50%) had excellent aesthetic results, 17 patients (42.5%) were very satisfied with the overall operational result, 20 patients (50%) were satisfied with the cosmetic result, 18 patients (45%) had good aesthetic results, 1 patient (2.5%) had fair aesthetic results, and 2 patients (5%) were less satisfied, while only 1 patient (2.5%) had poor aesthetic results and 1 patient (2.5%) was dissatisfied. The relative morbidity, scar, and worry about complications were the primary sources of discontent. According to studies, patients' aesthetic satisfaction following breast reconstruction was most influenced by the attainment of breast symmetry. We wholeheartedly concur and have once more reaffirmed how crucial it is for our series to achieve breast symmetry.

According to **Cocquyt et al.** <sup>(17)</sup>, patients who have IBR have superior aesthetic results than those who undergo breast-conserving surgery (BCS). Furthermore, **Ueda et al.** <sup>(18)</sup> compared to BCS, SSM and NAC-sparing, SSM with IBR provide a comparable objective aesthetic results, patient satisfaction, and a positive body image after the mastectomy. In patients for whom mastectomy is unavoidable for a lady with tiny breasts, SSM with IBR may be the best solution to breast preservation. SSM may produce a better aesthetic result than traditional mastectomy. More than 90% of patients who received latissimus dorsi reconstruction, according to a review of 170 patients by **Moore and Farrell** <sup>(19)</sup>, were happy with the outcomes and would suggest the treatment to other patients. Physician reviewers agreed that 80% of patients had adequate size and form in comparison with the opposite breast.

When fast breast reconstruction was compared to delayed breast reconstruction, the former had reduced postoperative psychological morbidity. Following quick repair, **Noone et al.** <sup>(20)</sup> observed enhanced self-image and decreased psychological anguish.

**Dean et al.** <sup>(21)</sup> showed that fast rebuilding had considerable psychological advantages over delayed reconstruction in another non-randomized trial. Women who underwent rapid or early reconstruction (less than a year after mastectomy) had considerably lower levels of remembered distress related to the mastectomy than women who underwent delayed reconstruction, according to **Schain et al.** <sup>(22)</sup> research. Still, the procedure needs to be studied in a wider scale of patients and to be followed up for a longer period of time for accurate assessment.

## CONCLUSION

It was found that the use of LD flap is reliable and versatile method of breast reconstruction. It gives adequate tissues that obviates the use of prosthesis, and gives excellent satisfactory aesthetic results, with good matching and better quality of life.

**Financial support and sponsorship:** Nil.

**Conflict of interest:** Nil.

## REFERENCES

1. **Chwalczyńska A, Woźniewski M, Rozek-Mróż K et al. (2004):** Quality of life in women after mastectomy. *Wiadomosci lekarskie*, 57 (5-6): 212-6.
2. **Elder E, Brandberg Y, Björklund T et al. (2005):** Quality of life and patient satisfaction in breast cancer patients after immediate breast reconstruction: a prospective study. *The Breast*, 14 (3): 201-8.
3. **Hu E, Alderman A (2007):** Breast reconstruction. *Surgical Clinics of North America*, 87: 453- 467.
4. **Chevray P (2008):** Timing of Breast Reconstruction: Immediate versus Delayed. *Cancer Journal*, 14 (4): 223-229.
5. **Malata C, McIntosh S and Pumshotham A (2000):** Immediate breast reconstruction after mastectomy for cancer *British Journal of Surgery*, 87: 1455-1472.
6. **Burgic M, Bruant-Rodier C, Wilk A et al. (2010):** Complications following autologous latissimus flap breast reconstruction. *Bosnian Journal of Basic Medical Sciences*, 10 (1): 65.
7. **Rusby J, Waters R, Nightingale P et al. (2010):** Immediate breast reconstruction after mastectomy: what are the long-term prospects? *The Annals of the Royal College of Surgeons of England*, 92 (3): 193-7.
8. **Sandelin K, Wickman M, Billgren A (2004):** Oncological outcome after immediate breast reconstruction for invasive breast cancer: a long-term study. *The Breast*, 13: 210-218.
9. **Taylor G, Ashton M, Rozen W (2008):** Defining the role for autologous breast reconstruction after mastectomy: social and oncologic implications. *Clin Breast Cancer*, 8: 134-42.
10. **Ho C, Mak C, Lau Y et al. (2003):** Skin involvement in invasive breast carcinoma: safety of skin-sparing mastectomy. *Ann Surg Oncol.*, 10: 102-7.
11. **Caffo O, Cazzoli D, Scalet A et al. (2000):** Concurrent adjuvant chemotherapy and immediate breast reconstruction with skin expanders after mastectomy for breast cancer. *Breast Cancer Res Treat.*, 60 (3): 267-75.
12. **Roy M, Shrotia S, Holcombe C et al. (1998):** Complications of latissimus dorsi myocutaneous flap breast reconstruction. *Eur J Surg Oncol.*, 24 (3): 162-5.
13. **Kroll S, Schusterman M, Tadjalli H et al. (1997):** Risk of recurrence after treatment of early breast cancer with skin-sparing mastectomy. *Ann Surg Oncol.*, 4: 193-7.
14. **Alderman A, Wilkins E, Kim H et al. (2002):** Complications in postmastectomy breast reconstruction: two-year results of the Michigan breast reconstruction outcome study. *Plast Reconstr Surg.*, 109: 2265-74.



15. **Salzberg C, Ashikari R, Kelemen P *et al.* (2008):** Subcutaneous mastectomy and immediate reconstruction for prevention of breast cancer for high-risk patients. *Breast Cancer*, 15: 185–191.
16. **Yang E, Park W, Seo K *et al.* (2010):** Longitudinal change of treatment-related upper limb dysfunction and its impact on late dysfunction in breast cancer survivors: a prospective cohort study. *J Surg Oncol.*, 101: 84-91.
17. **Cocquyt V, Blondeel P, Depypere H *et al.* (2003):** Better cosmetic results and comparable quality of life after skin-sparing mastectomy and immediate autologous breast reconstruction compared to breast conservative treatment. *Br J Plast Surg.*, 56 (5): 462-70.
18. **Ueda S, Tamaki Y, Yano K *et al.* (2008):** Cosmetic outcome and patient satisfaction after skin-sparing mastectomy for breast cancer with immediate reconstruction of the breast. *Surgery*, 143 (3): 414-25.
19. **Moore T, Farrell L (1992):** LD Latissimus dorsi myocutaneous flap for breast reconstruction: Long-term results. *Plast Reconstr Surg.*, 89: 666–672.
20. **Noone R, Murphy J, Spear S *et al.* (1985):** A 6-year experience with immediate reconstruction after mastectomy for cancer. *Plastic and Reconstructive Surgery*, 76 (2): 258-269.
21. **Dean C, Chetty U, Forrest A (1983):** Effects of immediate breast reconstruction on psychosocial morbidity after mastectomy. *The Lancet*, 321: 459-462.
22. **Schain W, Wellisch D, Landsverk L *et al.* (1985):** A study of psychological factors in women undergoing immediate versus delayed breast reconstruction. *Am Psychiatry*, 142: 40–46.