

Parotidectomy with Autologous Free Dermal Fat Graft: Functional and cosmetic Improvement

Wael Mohamed Abdelgawad Hamed*, Hassan Mohamed khalaf, Waleed Mohamed Allam,
Khalil Taha Abo Rokba, Eslam Atef Abdelmoneim Sharara, Mohamed Elsaid Aboelnadar AbdelAty
Damanhur Medical National Institute, Elbehiera, Egypt

Corresponding author: Wael Mohamed Abdelgawad Hamed, Tel: 01223004249, Email: waeldoc80@gmail.com

ABSTRACT

Background: Significant morbidity is caused by facial asymmetry and Frey's syndrome, which are long-term consequences of parotid surgery resulting from the removal of parotid tissue. The free dermal-fat-facial graft (DFFG) is one of these techniques, though its use is seldom recorded in medical literature.

Objective: The aim of the current study is to investigate the effectiveness of free DFFG in rebuilding parotidectomy deficits at the Damanhur Medical National Institute (DMNI) in Elbehiera, Egypt.

Patients and methods: A total of 15 patients at DMNI in Elbehiera, Egypt, had primary parotidectomy and rapid repair with autologous belly DFFG by the same surgeon. Between 2020 and 2021, prospective data collection was done. Patients completed two postoperative outcomes surveys.

Results: Of the studied patients, 14 had benign lesions and 1 malignant lesion. Up to 13 (86.6 %) patients reported perfect facial symmetry, 1 (6.7%) shows slight hollowness, and 1 (6.7%) had mild fullness; none reported notable hollowness or fullness. Only 2 (13.3%) had minor symptoms, 1 (6.7%) had devastating symptoms, and 12 (80%) did not have Frey's syndrome. All patients answered a second questionnaire on the transplant donor site. Up to 12 (80%) were happy or extremely satisfied with the donor site's aesthetic appearance, and 14 (93.3%) reported no pain at the donor site. Donor site symptoms were not reported.

Conclusion: For most patients, autologous DFFG restored face cosmeses and avoided Frey's syndrome.

Keywords: Parotidectomy, Facial contour, Frey's syndrome, Free dermal fat graft, Case series, Damanhur Medical National Institute.

INTRODUCTION

Popular long-term consequences of parotidectomy include facial asymmetry and Frey's syndrome due to parotid tissue loss ⁽¹⁾.

Interposition of graft among skin flap and time bed can stop these complications because the graft acts as barrier stopping abnormal innervation of skin sweat glands by auriculotemporal nerve cells though adding bulk to time bed, thereby compensating for void left by parotidectomy ⁽²⁾.

It is difficult to assess incidence of Frey's syndrome since numerous studied cases are unaware of their symptoms or do not report them. Objective minor's exam is exceedingly difficult to administer and quantify ⁽³⁾. In lack of interposition grafting, incidence of Frey's syndrome ranges from 43% to 100% clinically, and from 2% to 62% subjectively, based on symptoms like unilateral hyperhidrosis, and flushing in response to stimuli ⁽⁴⁾. It has been shown that interposition grafting significantly reduces both objective and subjective incidence of Frey's syndrome ⁽⁵⁾.

Interposition grafting techniques include the sternomastoid muscle (SM) flap, the platysmal flap, and the sub-superficial musculoaponeurotic system flap ⁽³⁾.

Each treatment has its own advantages and disadvantages. SM flap is adequately vascularized and does not need an extra skin incision; nonetheless, it is linked with risk of facial nerve (FN) and spinal accessory nerve (SAN) injury, as well as SM atrophy. Temporoparietal fascial flap demands longer incision and is related with an increased risk of FN damage,

alopecia, and zygomatic fullness ⁽⁶⁾.

Additionally, it does not offer sufficient bulk for deep abnormalities. Allogenic human dermis does not need extra surgical place; nonetheless, it is costly and is linked to rise in length of suction drainage, incidence of sialoceles, and salivary fistula development ⁽⁷⁾.

Similarly, synthetic implantable materials like vicryl and expanded polytetrafluoroethylene mesh are linked with an improved incidence of sialoceles and implant extrusion ⁽¹⁾. Fat grafts, which were first described in 1893, were shown to be efficient in retaining face aesthetic ⁽⁸⁾.

Utilizing fat as a reconstruction material offers several benefits, including resistance to infection, pliability, absence of a foreign body response, and the ability to adapt face development and growth in children ⁽⁹⁾.

Abdominal free fat grafting, which is found to be successful in filling head and neck faults, containing parotidectomy flaws, across a variety of surgical approaches, is one of the fat autograft reconstruction strategies with the strongest documentation ⁽¹⁰⁾.

However, the resorption rate of free fat grafts is uncertain and considerable. The addition of dermis to free fat graft can facilitate the revascularization of transplanted fat, hence reducing resorption ⁽¹¹⁾.

In this study we are recording on parotidectomy flaws reconstructed mainly with autologous abdominal free DFFG and their outcomes in our institute (Damanhur Medical National Institute), Elbehiera, Egypt.

PATIENTS AND METHODS

Medical records of studied cases that underwent parotidectomy and immediate reconstruction with DFFG during 2020 and 2021 were collected prospectively. Same surgeon conducted all surgeries using same method.

Studied cases with recurrent parotid tumors or previous parotid radiation were not eligible. With facial nerve preservation, both superficial and total parotidectomies were done.

Chart review was carried out in order to gather missing data from prospective. Sociodemographic data, neoplasm size and final pathologic characterization of resected neoplasm, hyperhidrosis, gustatory neuralgia, and morbidities at abdominal graft donor place were among data collected.

METHODS

Studied cases were asked to complete two questionnaires by phone or in person to evaluate their satisfaction with cosmetic and functional results of reconstruction. Although these questionnaires have not been validated, they are used in literature for case series. To prevent interpretation bias by handling

surgeons, studied cases evaluated their own cosmeses using five-point Likert scale.

Surgical Technique

Immediate after parotidectomy and determination of size of resected specimen, DFFG is collected from abdomen; typically, suprapubic region or left lower quadrant is utilized. On the donor site, an elliptical region equivalent to size of defect is traced out. In situ de-epithelialization is performed while maintaining the dermis.

For suitable thickness, incisions are then made into dermis and underlying adipose tissue. Graft including dermis and subcutaneous fat is then extracted, and trimmed to fit defect's size. As graft will usually experience degree of resorption postoperatively, it is harvested 20% to 30% bigger than the parotidectomies specimen. Graft is then put in parotid bed with dermis on superficial side, and a three-zero vicryl suture is used to sew dermis onto SMAS (Figure 1). This permits accurate location of graft, limiting migration and preserving SMAS's continuity. The elevated skin flap from the parotidectomy is then sutured back in place, concealing DFFG.

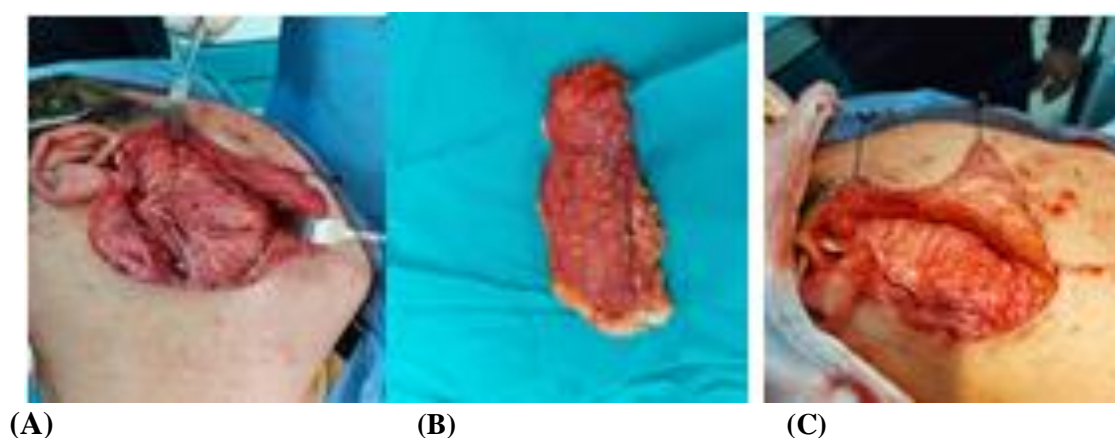


Figure (1): Intraoperative photos for abdominal dermal fat graft. (A) operative bed after superficial parotidectomy showing FN. (B) dermal fat graft harvested from lower abdomen. (C) After fixation of dermal abdominal fat graft in the operative bed.

Figure 1 showed studied male case who underwent right superficial parotidectomy for pleomorphic adenoma.

Ethical Approval:

This study was ethically approved by the Institutional Review Board of Damanhur Medical National Institute. Written informed consent was obtained from all participants. This study was executed according to the code of ethics of the World Medical Association (Declaration of Helsinki) for studies on humans.

Statistical analysis

The collected data were introduced and statistically analyzed by utilizing the Statistical Package for Social Sciences (SPSS) version 20 for windows. Qualitative data were defined as numbers and percentages. Quantitative data were tested for normality by Kolmogorov-Smirnov test. Normal distribution of variables was described as means and standard deviation (SD).

RESULTS

Survey outcomes were collected, tabulated, and presented in **Tables 1 and 2**. Each of the 15 patients was seen at a surveillance visit or contacted by phone to complete the survey.

Table 1: Reported symptoms according to the participants of the study.

Item	Opinion	No (Percent)
Facial contour	Symmetric	13 (86.6)
	Operated side mildly hollow	1 (6.7)
	Operated side noticeably hollow	0 (0)
	Operated side mildly too full	1 (6.7)
	Operated side noticeably too full	0 (0)
	Total	15 (100)
Gustatory neuralgia	Not at all	14 (93.3)
	Yes, not making complications	1 (6.7)
	Yes, sometimes complication	0 (0)
	Yes, always complication	0 (0)
	Total	15 (100)
Facial flushing	Not at all	13 (86.6)
	Yes, not making complications	1 (6.7)
	Yes, occasionally complication	1 (6.7)
	Yes, always complication	0 (0)
	Total	15 (100)
Frey's syndrome	Not at all	12 (80)
	Yes, sometimes problem	1 (6.7)
	Yes, always problem	0 (0)
	Yes, not causing any problems	2 (13.3)
	Total	15 (100)

The 2nd questionnaire addressed result of abdominal graft donor place (Table 2).

Table 2: Reported result measures and distribution concerning graft donor place, according to the participants of the study.

Item	Opinion	No (Percent)
Cosmetic presence of graft donor place satisfaction	Very satisfied	6 (40)
	Satisfied	6 (40)
	Dissatisfied	0 (0)
	Very dissatisfied	0 (0)
	Total	12 (80)
Concerned about cosmetic outcomes of graft donor place	Not at all	12 (80)
	Yes, mildly	2 (13.3)
	Yes, moderately	1 (6.7)
	Yes, extremely	0 (0)
	Total	15 (100)
Pain at graft donor place	Not at all	14 (93.3)
	Yes, mildly	1 (6.7)
	Yes, moderately	0 (0)
	Yes, extremely	0 (0)
	Total	15 (100)
Any side effects from graft donor place	Yes, what symptoms do you have?	0 (0)
	No	15 (100)
	Total	15 (100)

Table 3 summarizes sociodemographic data, types of surgery, and tumor/specimen volume of the 15 studied cases. Up to 14 studied cases had superficial parotidectomy and 1 had total parotidectomy with FN preservation. Only one patient with malignant neoplasm received postoperative radiotherapy.

Table 3: Sociodemographic data, types of surgery, and tumor/specimen volume of studied patients.

Variable	Number	%
Men	10	66.7%
Women	5	33.3%
Mean years old	43.4 years	
Mean follow up	11 months	
Surgery and tumor features	Number	%
Lateral parotidectomy with FN spared	14	93.3
Total parotidectomy with FN spared	1	6.7
Mean specimen volume (SD) ml	45.65 (SD 44.6)	
Mean tumor volume (SD) ml	13.36 (SD 12.8)	

DISCUSSION

Studied cases that had parotidectomy and prompt repair with autologous abdominal free DFFG had good aesthetic and functional outcomes.

DFFG is robust, readily harvested with a size and thickness that can be modified to fit the defect and has low morbidity at the donor place. It fills preauricular void and functions as mechanical barrier against abnormal reinnervation that is the reason for Frey's syndrome.

In this investigation, rate of malignancy was 6.7% (1/15). In addition, comparable distributions of final pathology findings are described in literature; with pleomorphic adenoma being prevalent parotid gland tumour, like was case for 93.3% of studied cases in our research.

Frequencies of Frey's syndrome and facial symmetry discovered in research are close to those observed in DFFG literature.

In this research, aesthetic dissatisfaction and subjective morbidity rates were minimal, with 86.7% of studied cases reporting symmetric facial shape, 80% having no signs of Frey's syndrome, 86.7% not suffering facial flushing, and 93.3% not experiencing gustatory neuralgia.

Honeybrook et al. ⁽¹⁰⁾ evaluated effectiveness of free DFFG in 62 studied cases, containing 22 parotid reconstructions, for the repair of head and neck abnormalities.

According to their research, 98.3% of patients did not develop Frey's syndrome and 81.2% (26/32) of patients were happy with the aesthetic outcomes.

Baum et al. ⁽¹²⁾ observed no subjective occurrence of Frey's syndrome in 19 studied cases after parotidectomy, containing 17 superficial and 2 total parotidectomies with DFFG reconstruction. They documented ten percent risk of persistent over correction of parotid defect resulting in fullness and a 10% (2/19) rate of permanent under correction resulting in hollowness of surgical defect.

Harada et al. ⁽¹³⁾ in patients who had superficial parotidectomy for benign disease with DFFG restoration, there was an observed 14% prevalence of subjective Frey's syndrome and 14% prevalence of overcorrection of surgical deficiency.

Davis et al. ⁽¹⁴⁾ stated that 33% of their studied cases who had DFFG repair needed a second treatment or had unsatisfactory aesthetic outcomes. This series demonstrates a greater percentage of total parotidectomies (20/54) and malignant pathology than earlier studies employing DFFG for parotid abnormalities. This can affect prevalence of Frey's syndrome and the cosmetic results.

Perceived incidence of Frey's syndrome and facial asymmetry can rise like size of lesion and amount of parotidectomy rises.

Witt, ⁽¹⁵⁾ and **Baek et al.** ⁽¹⁶⁾ determined that occurrence of Frey's syndrome without repair is 47% for

whole parotidectomies, 17% for superficial parotidectomies, and 3% for extracapsular dissections.

Cohort indicated a favorable studied case-reported result for the abdominal graft donor place; common of studied cases were delighted with aesthetic look (80%), were not concerned by the cosmetic appearance (80%) and did not experience any pain at graft donor place (80%).

Honeybrook et al. ⁽¹⁰⁾ described no complications at abdominal graft donor place, and all studied cases were pleased with aesthetic outcomes at the donor place.

Baum et al. ⁽¹²⁾ observed hypertrophic scar, hypoesthesia, itching, recurring pain, and hypersensitivity in 16% of studied cases. **Chan et al.** ⁽¹⁷⁾ did not record complications at abdominal graft donor place. None of our studied cases had any of these symptoms. 1 studied case who complained of pain at graft donor place mentioned skin stretching during specific physical movements.

Studied cases who described being merely pleased, as opposed to very satisfied, and studied cases who described being upset by aesthetic outcomes remarked on scar's size and pigmentation.

Resorption of graft is primary worry when free DFFG is utilized for reconstruction. Resorption may result in face asymmetry and poor aesthetic quality. It is hypothesized that dermal fat grafts have a higher survival rate than free fat grafts because intact dermal circulatory plexus can promote adipocyte survival. Free fat and dermal-fascia-fat were evaluated in animal research; it was shown that dermal-fascia-fat graft underwent higher angiogenesis and collagen production than the other groups ⁽¹⁾.

Chandarana et al. ⁽¹⁸⁾ investigated DFFG survival at 1 and 6 months after restoration of parotidectomy defect with or without platelet-rich plasma solution. In control group of the study by **Dulguerov et al.** ⁽¹⁹⁾ the resorption rate ranged from 66% to 82%, while it was 30% to 66% in platelet-rich plasma group. Grafts were regularly overcorrected by 20% to 30%, which we think contributed to fact that nobody in series observed any pronounced hollowness or fullness.

In addition to resorption, free DFFG is associated with fat liquefaction leading to seroma, and wound dehiscence. Free DFFG reconstruction has been documented to have varying rates of problems.

Baum et al. ⁽¹²⁾ found a 21% (4/19) complication rate; 2 hematomas and 2 seromas. **Harada et al.** ⁽¹³⁾ described no issues, but **Chandarana et al.** ⁽¹⁸⁾ described a 12.5% seroma-related problem rate.

Historically, there has been reluctance to restore parotidectomy deficits for malignant disease because malignant glands may need postoperative radiation, which can negate functional and aesthetic advantages of transplant. Study, one out of fifteen individuals with malignant pathology got postoperative radiation, which

had no influence on incidence of Frey's syndrome and face shape.

Further cause of reluctance to rebuild parotidectomy defects for malignant disease is that postoperative monitoring can be impeded by graft, since any nodularity and mass of graft may be mistaken for recurrence on clinical examination. DFFG does not appear to interfere with imaging-based postoperative monitoring.

In this investigation, the occurrence or lack of concomitant illnesses like smoking, diabetes, and vascular diseases was not evaluated. As they can hinder neovascularization and tissue integration, these comorbidities may affect the efficacy of DFFG. In the research by **Honeybrook *et al.*** ⁽¹⁰⁾, 2 out of every 3 studied cases with post-operative problems had concomitant diseases.

CONCLUSION

Immediate autologous abdominal free flap reconstruction of post-parotidectomy defects DFFG maintains facial cosmeses, inhibits Frey's syndrome, and reduces risks associated with secondary reconstruction. This surgical method is simple and tailored to size of defect, with little postoperative problem and donor place morbidity.

DECLARATIONS

- **Consent for publication:** I attest that all authors have agreed to submit the work.
- **Availability of data and material:** Available
- **Competing interests:** None
- **Funding:** No fund
- **Conflicts of interest:** no conflicts of interest.

REFERENCES

1. **Mianroodi A, Mohtashami S, Romero N *et al.* (2021):** Autologous Free Dermal-Fat-Fascial Graft for Parotidectomy Defects: A Case Series. *Annals of Otolaryngology, Rhinology & Laryngology*, 130(10):1171-80.
2. **Ye L, Cao Y, Yang W *et al.* (2019):** Graft interposition for preventing Frey's syndrome in patients undergoing parotidectomy. doi: 10.1002/14651858.CD012323.pub2
3. **Mantelakis A, Lafford G, Lee C *et al.* (2021):** Frey's Syndrome: A Review of Aetiology and Treatment. *Cureus*, 13:12.
4. **Angelos M, Lafford G, Woo L *et al.* (2021):** Frey's Syndrome: A Review of Aetiology and Treatment. <https://europepmc.org/articles/PMC8638782>
5. **Le Linn Y, Khoo M, Sultana R *et al.* (2021):** Comparison of the use of allogenic acellular dermal matrix on rates of Frey syndrome post parotidectomy—A systematic review and meta-analysis. *Oral Surgery, Oral Medicine, Oral Pathology and Oral Radiology*, 134(1):49-56. doi: 10.1016/j.oooo.2021.12.123.
6. **David A, Seth R, Knott P (2021):** Facial reanimation and reconstruction of the radical parotidectomy. *Facial Plastic Surgery Clinics*, 29(3):405-14.
7. **Choi J, Park S, Rha E *et al.* (2019):** Acellular dermal matrix (Insuregraf) in the prevention of Frey's syndrome and surgical site depression after parotidectomy. *Archives of Craniofacial Surgery*, 20(3):176-80.
8. **Issa S, Jameel M (2020):** Free Dermal Fat Graft for Reconstruction of Soft Tissue Defects in the Maxillofacial Region. *Craniomaxillofacial Trauma & Reconstruction*, 13(4):260-6.
9. **Moy J, Wax M, Loyo M (2021):** Soft Tissue Reconstruction of Parotidectomy Defect. *Otolaryngologic Clinics of North America*, 54(3):567-81.
10. **Honeybrook A, Athavale S, Rangarajan S *et al.* (2017):** Free dermal fat graft reconstruction of the head and neck: an alternate reconstructive option. *American Journal of Otolaryngology*, 38(3):291-6.
11. **Pellitteri P (2018):** Prevention of Frey syndrome. *Operative Techniques in Otolaryngology-Head and Neck Surgery*, 29(3):177-84.
12. **Baum S, Pfortner R, Ladwein F *et al.* (2016):** Use of dermis-fat grafts in the prevention of Frey's syndrome after parotidectomy. *Journal of Cranio-Maxillofacial Surgery*, 44(3):301-8.
13. **Harada T, Inoue T, Harashina T *et al.* (1993):** Dermis-fat graft after parotidectomy to prevent Frey's syndrome and the concave deformity. *Annals of Plastic Surgery*, 31(5):450-2.
14. **Davis R, Guida R, Cook T (1995):** Autologous free dermal fat graft: reconstruction of facial contour defects. *Archives of Otolaryngology-Head & Neck Surgery*, 121(1):95-100.
15. **Witt R (2002):** The significance of the margin in parotid surgery for pleomorphic adenoma. *The Laryngoscope*, 112(12):2141-54.
16. **Baek C, Chung M, Jeong H *et al.* (2009):** Questionnaire evaluation of sequelae over 5 years after parotidectomy for benign diseases. *Journal of Plastic, Reconstructive & Aesthetic Surgery*, 62(5):633-8.
17. **Chan L, Barakate M, Havas T (2014):** Free fat grafting in superficial parotid surgery to prevent Frey's syndrome and improve aesthetic outcome. *The Journal of Laryngology & Otolaryngology*, 128(S1):S44-S49.
18. **Chandarana S, Fung K, Franklin J *et al.* (2009):** Effect of autologous platelet adhesives on dermal fat graft resorption following reconstruction of a superficial parotidectomy defect: a double-blinded prospective trial. *Head & Neck*, 31(4):521-30.
19. **Dulguerov P, Quinodoz D, Cosendai G *et al.* (1999):** Prevention of Frey syndrome during parotidectomy. *Archives of Otolaryngology-Head & Neck Surgery*, 125(8):833-9.