

## Bronchial Artery Embolization Procedure for Treatment of Hemoptysis Caused by Cavitory Lung Lesions

Ahmed Mostafa Mohamed, Ahmed El Shimy, Norhan Abozeid Ahmed Abdelaziz,  
Nourhan Mohammed Hossam El Din\*

Department of Radiodiagnosis, Faculty of Medicine, Ain Shams University, Cairo, Egypt

\*Corresponding author: Nourhan Mohammed Hossam El Din, Mobile: (+20) 01152045672,

E-mail: nor\_hossam23@yahoo.com

### ABSTRACT

**Background:** Embolization of the bronchial artery is one of the non-surgical successful measures to treat hemoptysis without surgery.

**Aim of the Work:** To evaluate the technique, efficacy, and safety of Bronchial Artery Embolization (BAE) in patients with hemoptysis due to cavitory lung lesions.

**Patients and Methods:** This study was a reconstructive (retrospective and prospective) cohort study and included 20 candidates who presented with hemoptysis due to cavitory lung lesions and were refractory to the supportive treatment measures during the period between March 2021 and September 2021. The study population was referred from the Chest Department to Interventional Radiology Unit, at Ain Shams University Hospitals.

**Results:** Massive hemoptysis was seen in 15 patients and recurrent mild-moderate in 5 patients. On imaging, cavitory lesions were seen on the left side in 8 patients, the right side in 8 patients, and bilateral involvement in 4 patients. Bronchiectatic changes were the predominant pathology seen in 6 patients. Immediate success was achieved in 20 patients, while recurrence within one month was noted in 4 patients. 13 patients reported experiencing minor problems like chest pain, but no serious ones like spinal cord ischemia.

**Conclusion:** When a patient has hemoptysis, BAE is a standard technique that is both safe and effective with a very low complication rate.

**Keywords:** Computed Tomography; Hemoptysis; Bronchial artery embolization; Trans-arterial Embolization.

### INTRODUCTION

Bleeding from the lower respiratory tract is known as hemoptysis. It can range in severity from a little spotting to a hemorrhage that poses a serious threat to life. Mild (50 mL/24 hr), moderate (50-300 mL/24 hr), and severe (> 300 mL/24 hr) hemoptysis are the three categories <sup>(1)</sup>.

The most significant causes of hemoptysis related to bleeding from bronchial arteries are bronchiectasis, tuberculosis, arteriovenous malformations, chronic bronchitis, malignancy, cavitory lung lesions, and fungus infection. If the etiology is unknown, cryptogenic hemoptysis is the diagnosis <sup>(2)</sup>. Although bronchoscopy and computed tomography (CT) is crucial for determining the source and location of bleeding, the angiography approach is very crucial since it is both diagnostic and therapeutic <sup>(3)</sup>. Cavitory lung lesions, which can include lung abscesses, aspergillosis, and post-TB sequelae, accounted for 25% of instances of hemoptysis <sup>(4)</sup>.

Massive hemoptysis has been successfully treated using bronchial artery embolization (BAE), which has been proven to be both safe and efficient. At the one-year follow-up, the recurrence rate after BAE can reach 57.5%, particularly in some instances of cavitory lesions. Cavitory lesions and aspergilloma are thought to have the highest recurrence rates <sup>(5)</sup>.

Since the last decade of the twentieth century; Trans-arterial Embolization (TAE) has emerged as a very important treatment modality and a gold standard in the management of various kinds of bleeding all over the body for example, Cerebral, Upper, and Lower GIT,

Urinary and genital bleeding as well as Hemoptysis. TAE in general and BAE specifically are minimally invasive procedures that can be done under local anesthesia in emergency outpatient. These procedures are gaining wide acceptance in all guidelines being safe and effective treatment with highly successful both technically and clinically with markedly fewer complications compared with surgical treatment options <sup>(1)</sup>.

Given its excellent early success rate and relatively low risk to the often used alternative medicinal and surgical therapies, bronchial artery embolization has become a common treatment for severe hemoptysis <sup>(6)</sup>.

The work aimed to evaluate the technique, efficacy, and safety of bronchial artery embolization in patients with hemoptysis due to cavitory lung lesions and referred to the Interventional Radiology Unit, Ain Shams University Hospitals.

### PATIENTS AND METHODS

The current study was a reconstructive (retrospective and prospective) cohort study that included 20 subjects suffering from hemoptysis as a complication of cavitory lung lesion and not responding to the routine medical supportive measures from March 2021 to September 2021. The candidates were referred by the chest department to Interventional Radiology Unit, at Ain Shams University Hospitals.

### **Inclusion criteria:**

1. Patients have hemoptysis with CT scan findings of cavitory lung lesions after patient stabilization.
2. No sex predilection.
3. Age >18 years.

### **Exclusion criteria:**

1. Patients with hemoptysis due to pulmonary artery causes e.g., pulmonary embolism.
2. Hemoptysis due to platelet disorders or thrombocytopenia.
3. Traumatic hemoptysis.
4. Presence of solid contraindications to angiography (Pregnant females, Patients with elevated kidney functions (GFR<30), patients allergic to contrast) unless life-threatening hemoptysis where the procedure is done under proper preparation and consenting.

### **Embolization of the bronchial artery procedure:**

#### **A. Patient preparation:**

- Accurate history collection and thorough clinical evaluation.
- Evaluation of imaging data, including fibro-optic bronchoscopy findings and results of chest radiography, CT chest, and CT angiography, if available, prior to the procedure.
- A laboratory study including tests for the complete blood count, the coagulation profile, and kidney function.
- A thorough examination of the imaging process with written informed consent that includes the indication, results, and any problems.

### **Methods:**

Decisions regarding the best course of therapy and the function of embolization were carried out according to the results of the CT chest and CT angiography performed before the bronchial artery embolization process for detecting the cavitory lesions. Plans should cover the selection of an access channel, a guide catheter, a microcatheter and microwire, an embolic agent, and the target vessels that were treated.

- **Vascular access phase:** This step entails inserting a 6F arterial introducer at the right femoral artery while the patient is under local anesthetic or, in certain circumstances, depending on the patient's clinical condition, complete anesthesia.
- **Bronchial angiography:** Bronchial arteries cannulation was done by using a 5 F Cobra Catheter that was maneuvered over a hydrophilic 0.35 F guide wire.
- To analyze and sort the angiographic design pattern that predisposes to hemoptysis, to evaluate the vessel's shape at the tip, and to detect the existence of vasospasm or vascular dissection

near the tip, under fluoroscopy, a gentle injection of the full syringe of contrast is administered.

- **Micro catheter access phase:** A micro-catheter was co-axially directed to a point where an embolic substance might be provided to the target lesion after a stable guide catheter position is reached.
  - **Embolization phase:** Various embolic agents, including Embosphere about (500-700 Mm) Microspheres, PVA-particles also Gel foam, and pushable coils were administered using microcatheters to eliminate vascular blush.
- B. Post-procedural precautions/medications:**
- Hemostasis should be obtained by proper manual compression technique to the puncture site.
  - Bed rest for six hours to decrease the risk of puncture site bleeding.
  - Analgesics and broad-spectrum antibiotics.

#### **1- Risks and complications:**

- Transient chest pain and dysphagia.
- Contrast media hypersensitivity.
- Hematoma at the puncture site.
- Spinal cord ischemia causes paraplegia or paraparesis, either temporary or permanent.
- Radiation exposure.

#### **2- Procedural outcomes:**

The post-procedural result was assessed on some levels, including technical and clinical advancement. Control angiographies were examined for ultimate obliteration as a technique to evaluate the technical success of BAE.

Clinically, one month following the procedure, the candidates' symptoms were revised to detect new hemoptysis, the need for another embolization session, and the stability of the bleeding cessation. The following categories were used to categorize complications: (1) Major complications that need an extended hospital stay or have long-lasting negative effects, like ischemia of the spinal cord. (2) Minor issues that could be resolved the same day of admission or that might be self-limiting. To the ethics committee, no significant negative occurrences were recorded during our trial.

### **Ethical approval:**

**An acceptance from the ethical committee of the Radiology Department and the ethical committee of the Faculty of Medicine - Ain Shams University and NHTMRI was obtained to use the data stored on PACS with the patient's consent to perform lung ultrasound. During this investigation, the Declaration of Helsinki for Human Beings, the international medical association's code of ethics, was observed.**

### **Statistical analysis**

Statistical Package for Social Sciences (SPSS) version 25 was used to code, process, and analyze the obtained data. The mean, SD, and median (IQR), range

formats were used to express quantitative data. The type of data collected for each parameter was suitably analyzed when the data were provided.

**RESULTS**

**Demographics:** A total of 20 patients presented with hemoptysis with radiological evidence of cavitory lung lesion referred to the interventional radiology unit, Ain Shams university hospitals for bronchial artery embolization were included in the study.

The ages of the studied population ranged between 19- 72 years, with a mean of 46.9 years ( $\pm 16.11$ ). Gender: The male-to-female ratio in the research sample was 65% to 35%, respectively (**Table 1**).

**Table (1):** Distribution of ages and sexes in our research

		Mean / N	SD / %	Median (IQR)	Range
<b>Age</b>		46.90	16.11	48 (32 - 62.5)	(19 - 72)
<b>Sex</b>	<b>Male</b>	13	65.0%		
	<b>Female</b>	7	35.0%		

In our study population, instances involving the left upper lung lobe made up nearly 25% of all cases. Pathologies with a focus were more common than those with a dispersed focus (**Table 2**).

**Table (2):** Distribution of lung pathology:

		N	%
<b>Distribution of lung pathology</b>	<b>Diffuse (Bilateral)</b>	4	20.0%
	<b>Right upper lobe</b>	2	10.0%
	<b>Right middle lobe</b>	1	5.0%
	<b>Right lower lobe</b>	3	15.0%
	<b>Right lower and middle lobes</b>	1	5.0%
	<b>Right Lung</b>	1	5.0%
	<b>Left Upper lobe</b>	5	25.0%
	<b>Left lower lobe</b>	3	15.0%

The most typical bronchial configurations were right ICBT and left bronchial artery (30% & 19.2%, respectively). Three individuals had non-bronchial supply coming from the left subclavian artery, right internal mammary artery, and right phrenic artery (**Table 3**).

**Table (3):** Number of problematic arteries detected during catheter angiography in the patients under study.

<b>Pathologic al arteries</b>		N	%
<b>Bronchial vessels</b>	<b>Common bronchial trunk</b>	2	7.7 %
	<b>Left bronchial artery</b>	7	30 %
	<b>Intercostal arteries</b>	5	19.2%
	<b>Right ICBT</b>	5	19.2%
	<b>Right bronchial artery</b>	4	15.4 %
<b>Non bronchial arteries</b>	<b>Inferior phrenic</b>	1	3.8 %
	<b>Left subclavian artery and its branches</b>	1	3.8 %
	<b>Right internal mammary artery</b>	1	3.8 %

**Table 4** shows the clinical results of BAE, which was done on 20 patients. In our study, 100% of patients saw immediate success, but 20% experienced recurrence within one month.

**Table (4):** Clinical outcomes

<b>Clinical outcomes</b>	N	%
<b>Immediate clinical success</b>	20	100
<b>Recurrence within one month</b>	4	20
<b>The necessity of another embolization session</b>	3	15

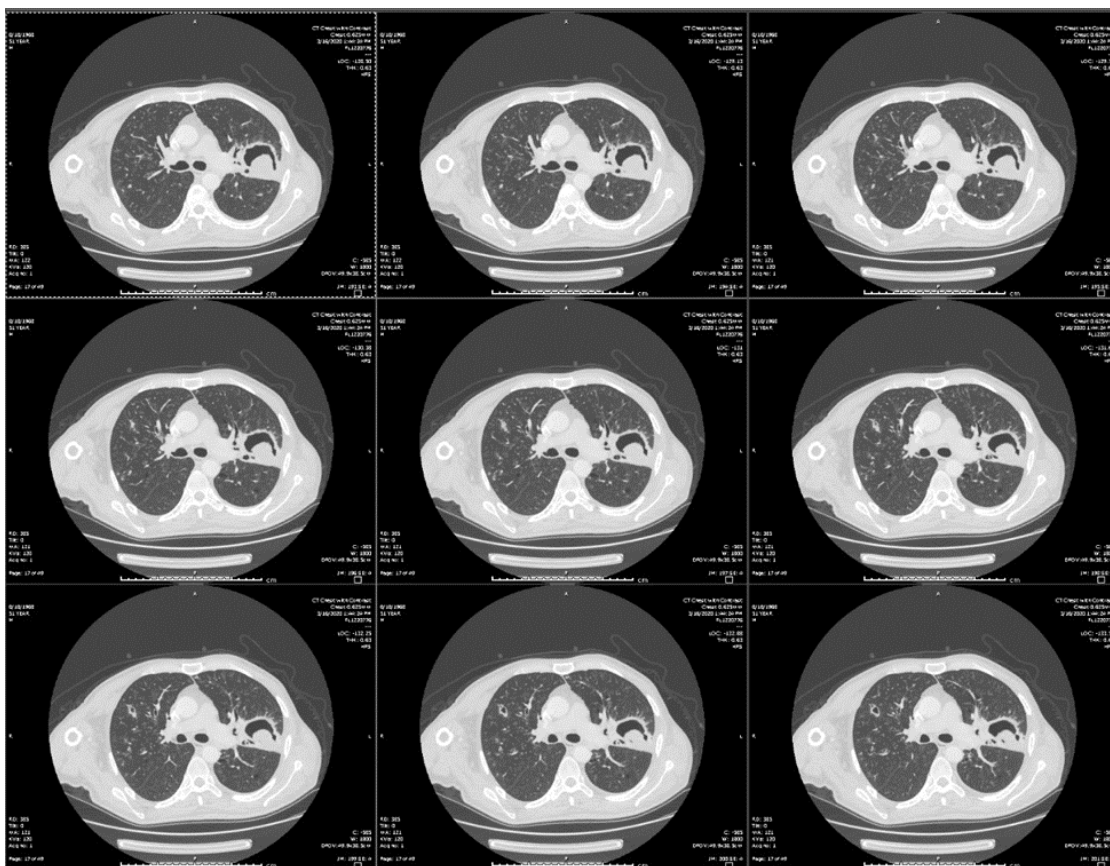
**Table 4** lists the procedure's potential problems. 65% of patients experienced minor problems; two suffered post-procedural dysphagia, and another patient had a localized hematoma that was treated for 30 minutes with enough compression. Eight patients were treated with heavy analgesics and non-steroidal anti-inflammatory drugs for their prolonged, severe pain, which necessitated their stay for the night. But there was no significant difficulty.

**Table (4):** Post-embolization complication

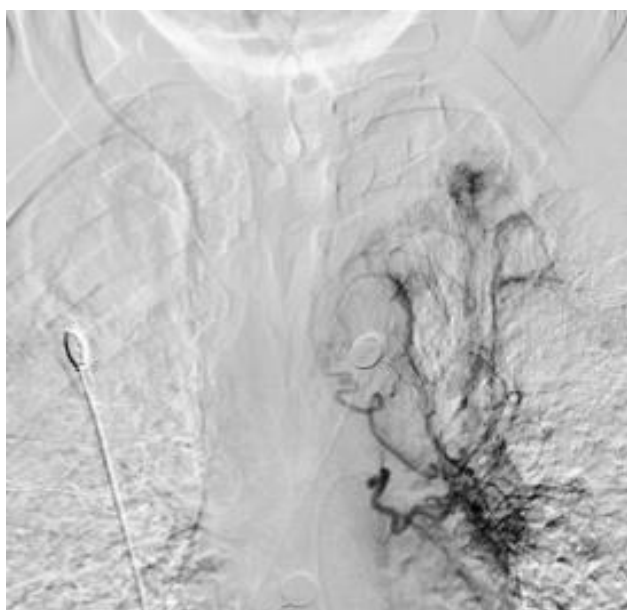
<b>Minor complication</b>	N	%
<b>Chest pain</b>	8	40%
<b>Dysphagia</b>	2	10%
<b>Puncture site hematoma</b>	1	5%
<b>Contrast allergy</b>	0	0%
<b>Major complication</b>		
<b>Spinal cord ischemia</b>	0	0%
<b>Refluxing embolic agent in the thoracic aorta</b>	0	0%

**CASE 1**

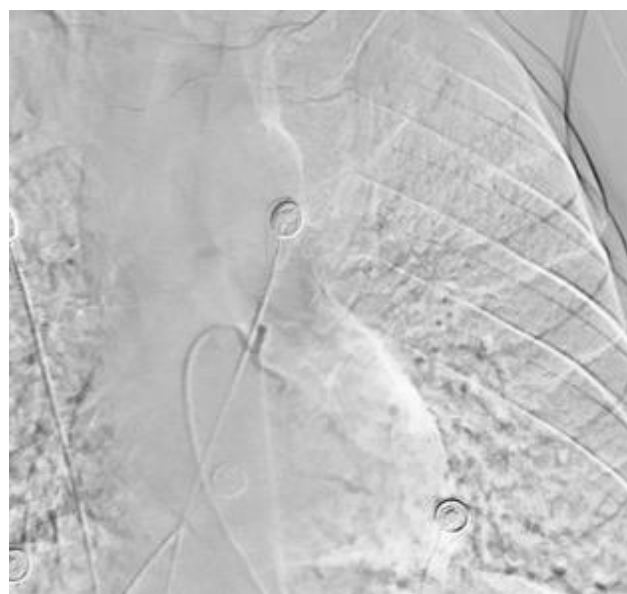A 51-year-old male patient presented with recurrent episodes of hemoptysis over the last two weeks after the failure of conservative medical treatment referred to our Angio unit for embolization.



**Figure (1):** CT revealed multiple scattered cavitating lesions, the largest cavitary lesion is seen at the posterior segment of the left upper lobe with thickened wall denoting active infection.



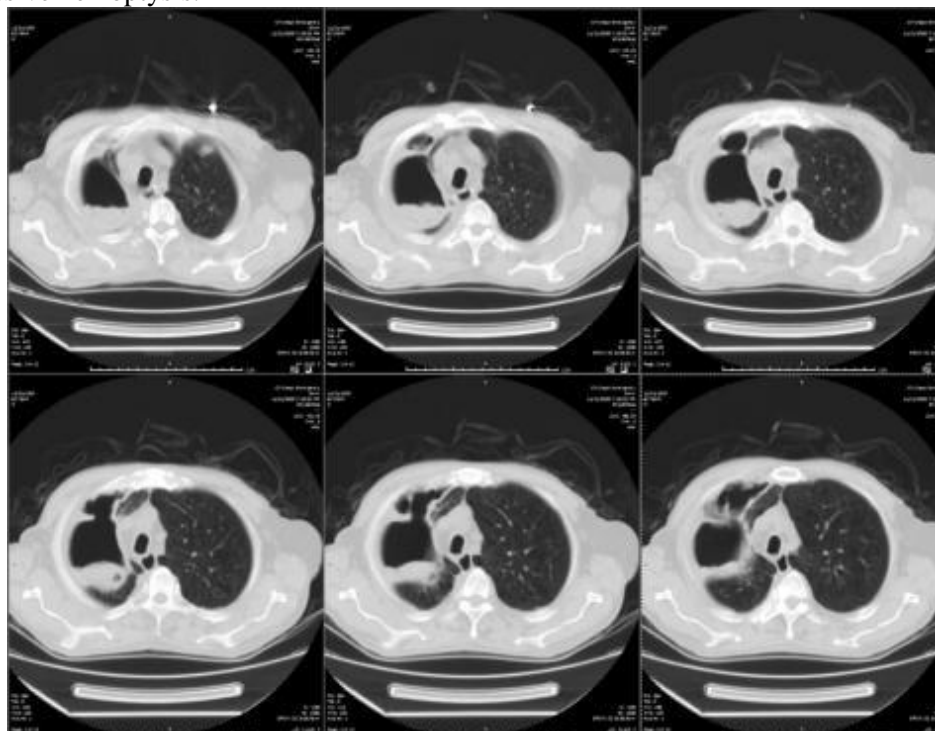
**Figure (2):** Digital subtraction angiography (DSA) demonstrates parenchymal hypervascularity and left bronchial artery tortuosity



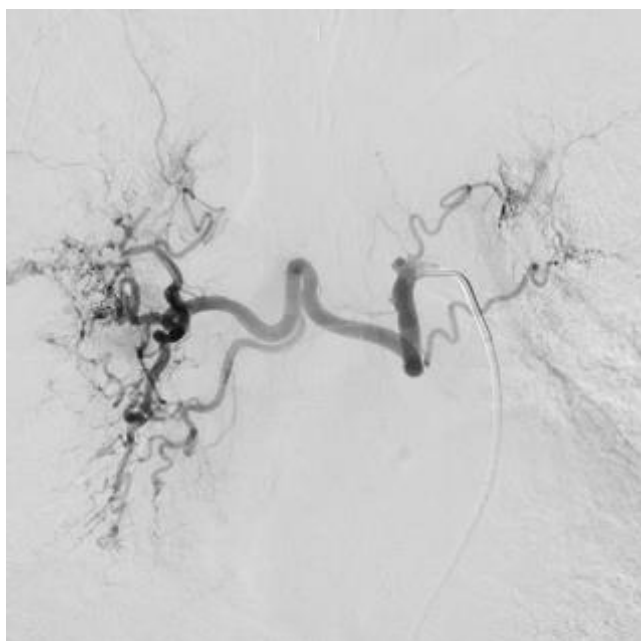**Figure (3):** Following occlusion with Embosphere, a post-embolization angiography showed complete elimination of previously detected flush and stasis in the left bronchial artery (500- 700 Mm). During the follow-up, no more hemoptysis attacks were seen.

## **CASE 2**

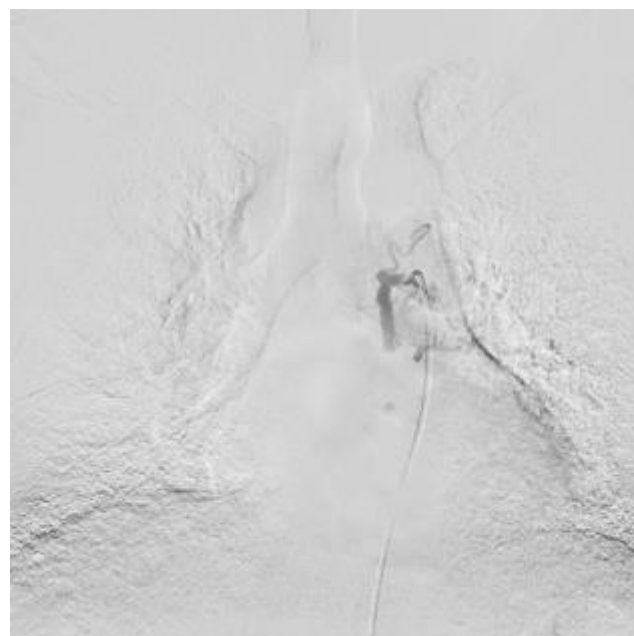
A 60-year-old male with apical right lung cavitory lesion due to old TB with superadding aspergillosis infection, presented with massive hemoptysis.



**Figure (1):** Axial chest CT lung window revealed a right apical cavitory lung lesion with an area of soft tissue density which likely represents the aspergilloma.



**Figure (2):** DSA revealed a common trunk hypertrophied with tortuous right bronchial artery and left bronchial artery with distal hypervascularity.



**Figure (3):** The common bronchial trunk's previously detected blush and contrast stasis completely vanished, according to a post-embolization angiography.

## DISCUSSION

Massive hemoptysis that is left untreated can be fatal, with a death rate of more than 50%. In the majority of patients, bronchial circulation is the primary cause of significant hemoptysis. The therapy of recurring and/or significant hemoptysis is thought to be beneficial when using BAE, a non-invasive procedure <sup>(7)</sup>.

Initially, control of massive hemoptysis was the main application of BAE. To enhance the patient's quality of life, it is increasingly utilized in moderate hemoptysis and recurring mild hemoptysis <sup>(6)</sup>.

This study's objective was to appraise the safety and effectiveness of BAE for treating hemoptysis in patients with cavitory lung lesions, which are one of the most frequent causes of the condition.

Hemoptysis severity is described using a variety of terms. Massive hemoptysis was defined in our study as coughing up more than 300 ml of blood each day. Nearly all of our patients (75%) had significant hemoptysis when they arrived, and several of them required an immediate BAA and embolization.

On the contrary, moderate hemoptysis represented the majority of patients according to **Bhalla et al.** <sup>(6)</sup>.

### Regarding pulmonary pathology:

According to **Soares Pires et al.** <sup>(8)</sup>, 30% of the patients in our research had bronchiectasis, which was the primary related pulmonary illness.

15% of the patients we examined were cavitory lesions caused by post-TB infection. According to **Shigemura et al.** <sup>(9)</sup>, the most typical cause of significant hemoptysis in their investigation was pulmonary tuberculosis.

According to **Bhalla et al.** <sup>(6)</sup>, 20% of patients had an aspergilloma inside an already-existing cavity.

Only one patient (5% of the total) in our research had cancer. That was almost identical to **Dabó et al.** <sup>(10)</sup> who reported that only (2.3%) of the patients who had BAA for embolization developed lung cancer. On the other hand, according to **Mohamed et al.** <sup>(11)</sup>, lung cancer was the most often reported cause of hemoptysis in patients (46%)

Only one patient (5%) in our analysis exhibited complex cavitory lesion-related cystic fibrosis bronchiectasis. However, **Pathak et al.** <sup>(12)</sup> showed that cystic fibrosis bronchiectasis was the most frequent cause of hemoptysis in (42%) of patients.

This difference is primarily caused by the small sample size in our study who met the inclusion criteria for cavitory lung lesions, and it may also be related to differences in the study population's makeup when the study started, and regional variations in the prevalence of pulmonary tuberculosis and lung malignancy. Therefore, more extensive research is required in our region.

In our investigation, the LBA was the primary source of hemoptysis in 30% of patients, the right bronchial arteries in 19.2% of cases, the common trunk

of both BAs in 7.7%, and the right bronchial arteries in 15.4% of cases. In our investigation, bronchial arteries hypertrophy and dilatation were the most prevalent catheter angiographic findings and were shown in (85%) of patients, whereas **Anuradha et al.** <sup>(13)</sup> identified them in (72%) of patients. In contrast to the current results, which were (15%), **Kervancioglu et al.** <sup>(2)</sup> had observed bronchial artery dilatation in (53%) while they noticed that bronchial-to-pulmonary shunting was present in (26%) of patients.

15% of our patients had systemic collaterals that were not bronchial. On the other hand, 50% of the patients in the **Dabó et al.** <sup>(10)</sup> study had non-bronchial systematic collateral.

Additionally, it has been proposed that BAE results are influenced by the properties of embolic agents. Patients with hemoptysis have undergone selective bronchial and non-bronchial systemic embolization of the arteries using a range of embolic agents, including PVA, coils, gel foams, and microspheres. Each material has unique qualities as well as benefits and drawbacks. We were unable to compare other embolic agents since PVA was by far the most extensively utilized embolic agent in our study.

According to a comprehensive study, between 70 and 99% of BAE patients had rapid clinical success (defined as the cessation of bleeding within 24 hours following BAE or the same hospitalization) <sup>(14)</sup>.

All of our patients saw instant success, which is consistent with our findings. For the immediate management of hemoptysis following BAE, two retrospective studies<sup>(15, 16)</sup> demonstrated a success rate of 96.0%.

Nevertheless, recurring hemoptysis persisted as a significant issue despite what appeared to be substantial bronchial artery embolization.

**Panda et al.** <sup>(1)</sup> defined hemoptysis recurrence rate as substantial hemoptysis that occurs after discharge and necessitates either hospital admission, medical care, or repeat intervention after BAE and ranges from 9.8 to 57.5%.

Following **Shao et al.** <sup>(17)</sup> who observed that 18% of patients experienced a recurrence of bleeding. Four of the 20 patients in our research (20%) experienced a recurrence of hemoptysis one month after BAE.

**Elhusseiny et al.** <sup>(7)</sup> found that the recurrence rate of hemoptysis was (44%) in patients. According to **Kathuria et al.** <sup>(14)</sup>, angiographic findings such as the existence of non-bronchial systemic collaterals, bronchopulmonary shunting, and insufficient initial embolization are all linked to significant recurrence rates. Bleeding that returns after two weeks of bronchial artery embolization are typically caused by insufficient embolization, which results from failing to thoroughly investigate all problematic veins or failing to embolize all arteries, including the collaterals of non-bronchial systemic arteries.

Various causes of hemoptysis, including pulmonary tuberculosis, lung malignancy, bronchiectasis, and aspergillosis, are linked to a higher likelihood of hemoptysis recurrence, claim multiple studies<sup>(18,19)</sup>. In addition, compared to individuals with bronchiectasis, chronic TB patients exhibited more extensive NBSA blood supply and higher recurrence rates.

In our analysis, there was no evidence of a statistically significant link between the etiology and recurrence.

Technical advancements (super-selective method) and increased use of suitable embolic materials have led to a progressive decline in the complication rate for BAE over time.

In our study, BAE problems were minimal. The most frequent symptom was chest pain, which was experienced by 40% of patients and was self-limited with conservative treatment. Next in frequency was dysphagia, which was experienced by 10% of patients and was caused by embolization of the abnormal arteries connecting the esophageal and bronchial arteries. One patient (5%) experienced a puncture site hematoma that was successfully treated with sufficient compression.

Transverse myelitis, bronchial infarction, esophagogastric fistula, ischemic colitis, temporary cortical blindness, and stroke are among the most serious side effects. The most serious of these unintended consequences is anterior spinal cord ischemia brought on by the unintentional embolization of a spinal artery. Numerous research reported major issues, however, our investigation did not find any. This is most likely a result of the use of super-selective embolization, particularly in our study's linkages between bronchial arteries and spinal arteries. According to **Brown and Ray**<sup>(20)</sup>, the incidence of spinal artery ischemia from BAE is reported to range from 1.4% to 6.5%.

In contrast to the prior study **Knott-Craig et al.**<sup>(21)</sup> which indicated fatality rates of 9–38% as a result of major hemoptysis, no deaths were observed in our investigation. In a series that included several patients with advanced carcinomas, the highest percentage of 38% was noted.

## CONCLUSION

- BAE is a tried-and-true method for treating patients with hemoptysis that poses a life-threatening hazard. It is also utilized in situations of mild to severe hemoptysis that recurs, especially when medical treatment is ineffective.
- The more prevalent use of bronchial artery embolization has changed how life-threatening hemoptysis is managed and how far it has improved quality of life. In the acute environment, BAE is thought to provide an alternative to surgical resection. Following BAE, the incidence of

recurrence is still significant. As a result, while BAE is a useful therapeutic tool, surgical therapy is still the only option in some situations, such as aspergilloma, which has a high frequency of recurrence but in contrast, BAE provides a low fatality rate.

## REFERENCES

1. **Panda A, Bhalla A, Goyal A (2017):** Bronchial artery embolization in hemoptysis: A systematic review. *Diagnostic and Interventional Radiology*, 23(4): 307–317.
2. **Kervancioglu S, Bayram N, Gelebek Yilmaz F et al. (2015):** Radiological findings and outcomes of bronchial artery embolization in cryptogenic hemoptysis. *Journal of Korean Medical Science*, 30(5): 591–597.
3. **Gupta A, Sands M, Chauhan N (2018):** Massive hemoptysis in pulmonary infections: Bronchial artery embolization. *Journal of Thoracic Disease*, 10(I): 3458–3464.
4. **Abdurrahman L, Ibrahim A, Mohammad S et al. (2021):** Bronchial artery embolization as a therapeutic strategy for management of massive hemoptysis. *Ain Shams Medical Journal*, 72(3): 417–431.
5. **Yang Q, Cheng Luo L, Wei H et al. (2022):** Dual-vessel intervention treatment for massive hemoptysis caused by lung cavitary lesions. *European Journal of Radiology*, 154: 110448. <https://doi.org/10.1016/j.ejrad.2022.110448>
6. **Bhalla A, Kandasamy D, Veedu P et al. (2015):** A retrospective analysis of 334 cases of hemoptysis treated by bronchial artery embolization. *Oman Medical Journal*, 30(2): 119–128.
7. **Elhousseiny M, Abd-Elhafez S, Amer T et al. (2017):** Bronchial artery embolization in the management of hemoptysis: Safety and efficacy. *Egyptian Journal of Chest Diseases and Tuberculosis. The Egyptian Society of Chest Diseases and Tuberculosis*, 66(4): 723–728.
8. **Soares Pires F, Teixeira N, Coelho F, Damas C. (2011):** Hemoptysis--etiology, evaluation, and treatment in a university hospital. *Rev Port Pneumol.*, 17(1):7-14. doi:10.1016/s2173-5115(11)70004-5
9. **Shigemura N, Wan I, Yu S et al. (2009):** Multidisciplinary Management of Life-Threatening Massive Hemoptysis: A 10-Year Experience. *Annals of Thoracic Surgery*, 87(3): 849–853.
10. **Dabó H, Gomes R, Marinho A et al. (2016):** Bronchial artery embolization in the management of hemoptysis - A retrospective analysis in a tertiary university hospital. *Revista Portuguesa de Pneumologia*, 22(1): 34–38.
11. **Mohamed S, Mousa E, Hamed A et al. (2016):** Utility of multidetector row computed tomography in the management of hemoptysis: An experience from Upper Egypt. *Egyptian Journal of Chest Diseases and Tuberculosis. The Egyptian Society of Chest Diseases and Tuberculosis*, 65(1): 331–340.
12. **Pathak V, Stavas J, Ford H et al. (2016):** Long-term outcomes of the bronchial artery embolization are diagnosis dependent. *Lung India*, 33(1): 3–8.
13. **Anuradha C, Shyamkumar N, Vinu M et al. (2012):** Outcomes of bronchial artery embolization for life-threatening hemoptysis due to tuberculosis and post-

- tuberculosis sequelae. *Diagn Interv Radiol.*, 18(1):96-101.
14. **Kathuria H, Hollingsworth H, Vilvendhan R *et al.* (2020):** Management of life-threatening hemoptysis. *Journal of Intensive Care*, 20: 1–9.
  15. **Cornalba G, Vella A, Barbosa F *et al.* (2013):** Bronchial and nonbronchial systemic artery embolization in managing hemoptysis: 31 years of experience. *Radiologia Medica*, 118(7): 1171–1183.
  16. **Dave B, Sharma A, Kalva S *et al.* (2011):** Nine-year single-center experience with transcatheter arterial embolization for hemoptysis: Medium-term outcomes. *Vascular and Endovascular Surgery*, 45(3): 258–268.
  17. **Shao H, Wu J, Wu Q *et al.* (2015):** Bronchial artery embolization for hemoptysis: A retrospective observational study of 344 patients. *Chinese Medical Journal*, 128(1): 58–62.
  18. **Fruchter O, Schneer S, Rusanov V *et al.* (2015):** Bronchial artery embolization for massive hemoptysis: Long-term follow-up. *Asian Cardiovascular and Thoracic Annals*, 23(1): 55–60.
  19. **Ramírez Mejía A, Méndez Montero J, Vásquez-Caicedo M *et al.* (2016):** Radiological Evaluation and Endovascular Treatment of Hemoptysis. *Current Problems in Diagnostic Radiology*, 45(3): 215–224.
  20. **Brown A, Ray C (2012):** Anterior spinal cord infarction following bronchial artery embolization. *Seminars in Interventional Radiology*, 29(3): 241–244.
  21. **Knott-Craig C, Oostuizen J, Rossouw G *et al.* (1993):** Management and prognosis of massive hemoptysis: Recent experience with 120 patients. *Journal of Thoracic and Cardiovascular Surgery*, 105(3): 394–397.