

Mesenteric Thrombosis as a Complication of COVID-19 Infection: A Systematic Review with Meta-Analysis

MOHAMMED Sh. KHALIFA, M.D.*; MASHHOUR Gh.M. OSMAN, M.Sc.** and
ASHRAF F. ABADEER, M.D.***

The Department of General Surgery, Faculties of Medicine, Ain Shams & Cairo** Universities*

Abstract

Background: Coronaviruses derive their name from the Latin word “corona” meaning crown. The name refers to the unique appearance of the virus under an electron microscope as round particles with a rim of projections resembling the solar corona. They are enveloped, positive-sense, single-stranded RNA viruses which were first isolated from humans in 1965.

Although this disease affects mainly the respiratory system, other organs may be involved, usually due to coagulation disturbances that lead to a high rate of thrombotic complications.

In this regard, deep vein thrombosis has been reported in up to 25-50% of COVID-19 patients requiring intensive care, with mortality rates being as high as 30-40%. Although less frequent, other thrombotic events such as intestinal, cerebral, and peripheral limb thrombosis have been reported, usually in critical patients.

Concerning intestinal damage, the prothrombotic effects of the virus rise the incidence of mesenteric ischemia from a mere 0.09-0.2% in the general population to 1.9-3.8% in patients with COVID-19. Furthermore, complement activation through the alternative and lectin pathways results in endothelial injury and arteriolar thrombosis. Hence, it is believed that micro vascular changes, rather than major embolic events, play a central role in intestinal damage. It is important to note that venous thromboembolic complications are generally more common than arterial thrombosis.

In Mesenteric ischemia, the time lag between onset of symptom to treatment is crucial for good outcome. The optimal time for intervention is initial 12 hours from symptom onset, when it is possible to perform vascular surgery effectively without requiring intestinal resection.

However, patients with COVID-19 often present late and treatment of respiratory symptoms is given precedence over abdominal symptoms.

Mucosal ischemia may further induce massive spread of virus from bowel epithelium leading to vasoplegic shock after surgery.

Correspondence to: Dr. Mohammed Sh. Khalifa,
The Department of General Surgery, Faculty of Medicine,
Ain Shams University

Aim of Work: To investigate the prevalence and outcomes of COVID-19 patients with digestive thrombo-embolic events. And outline the preventive measures which can avoid this complication.

Key Words: *Blood coagulation – Corona Virus Disease 2019 – COVID-19 – Hypercoagulability – Mesenteric ischemia – Superior mesenteric artery (SMA) thrombosis – COVID-19 pneumonia – Bowel ischemia.*

Introduction

ON January 7, 2020, a novel coronavirus was isolated and named as severe acute respiratory syndrome coronavirus 2 (SARS-CoV-2) by the International Committee on Taxonomy of Viruses (ICTV) in the wake of an outbreak of pneumonia of unknown cause in Wuhan City, China. This pneumonia was called Coronavirus Disease 2019 (COVID-19) by the World Health Organization (WHO) on February 11, 2020.

As of this writing, the COVID-19 outbreak has become a pandemic that is threatening global health, undermining the global economy, and destabilizing societies across the world [1].

The coronavirus disease 2019 (COVID-19) pandemic, caused by the severe acute respiratory syndrome coronavirus 2 (SARS-CoV-2), has spread over more than 200 countries worldwide [2].

It is well established that most patients with COVID-19 have fever along with respiratory signs and symptoms, such as cough and dyspnea. To date, there is some uncertainty about the prevalence of extra pulmonary symptoms, such as those arising from the gastrointestinal tract.

The prothrombotic effects of the virus may be directly related to its structure. It is known that the membrane of SARS-CoV-2 contains a Spike protein (protein S) which binds to the angiotensin-

converting enzyme 2 (ACE2) receptor located on the membrane of host cells. ACE2 is most abundant in the lungs, intestine, oral mucosa, liver, and endothelium [3].

The superior mesenteric artery (SMA) is a single central vessel with a vulnerable terminal vascular zone. In around 85% of the cases, the functional terminal vascular zone of the SMA that runs from the central collateral blood supply to the mobile convolutions of the small intestine is affected. The initial clinical stage of AMI is characterized by the sudden onset of strong, spasmodic abdominal pain; after 3-6h, this phase is followed by a painless interval due to the damage of the intramural pain receptors as a result of prolonged hypoperfusion [4].

An acute complete circulatory disruption of the intestine leads to irreversible mucosal ischemia with leukocyte infiltration and formation of oxygen radicals within 6h. The collapse of the mucosal barrier further contributes to bacterial translocation and gangrene of the intestinal wall. In addition, bacterial infiltration leads to peritonitis, ileus, sepsis, and multiorgan failure [5].

The mortality rate rises from 0 to 10% in cases with immediate treatment, to 50% in those with delays of 6-12h, and 80-100% with delays of more than 24h after the onset of symptoms. Clinical signs of peritonitis, any evidence of intestinal gangrene, central occlusion of the SMA, or failure of endovascular options require an immediate surgical treatment [6].

The goal of treatment is to obtain arterial reperfusion before intestinal resection. Therefore, surgeons either need to be trained in techniques of embolectomy and reconstruction of visceral arteries or a vascular surgeon has to be consulted [7].

Subjects and Methods

Study design:

This study designed to follow the Preferred Reporting Items for Systematic Reviews and Meta-analyses (PRISMA) reporting guidelines. Databases (Pub Med, Embase, Google scholar, Who) were searched for all studies and national projects discussing the prevalence and outcomes of COVID-19 patients with digestive symptoms and mesenteric ischemia in all countries using keywords: Blood coagulation; Corona Virus Disease 2019; COVID-19, hypercoagulability, mesenteric ischemia, Superior mesenteric artery (SMA) thrombosis, COVID-19 pneumonia, and bowel ischemia. The search was limited to articles published in 2020 and 2021.

We carried out thorough additional search of the reference lists of the extracted articles to find out other potentially relevant articles. Duplicates were removed.

Eligibility criteria:

Our inclusion criteria included case reports or series involving patients with confirmed COVID-19 infection on a real-time reverse transcription-polymerase chain reaction (RT-PCR) diagnosed with mesenteric ischemia on imaging/surgery/biopsy, who underwent at least one abdominal CT scan. Other inclusion criteria were articles published in English, studies conducted on humans, and with extractable full text without any restriction applied to country of research. We excluded reviews, expert opinions, editorials, patients with presumed COVID-19 infection (without RT-PCR confirmation), and preprints. The titles and the abstracts of the included studies were screened by two independent reviewers based on the above criteria and any disagreements were resolved either by mutual consensus or by the senior author, if needed.

Assessment of quality of study:

All the studies were rated for their quality according to the National Institutes of Health (NIH) Quality Assessment Tool for Case Series Studies and cross-sectional studies.

Due to rarity of this entity, most of the included studies were either case reports or very small series of patients.

The standard tools used were:

- *Observational studies:* New-Castle Ottawa Scale.
- *Systematic Reviews/Meta-Analysis:* AMSTAR Checklist Case.
- *Reports and Case Series:* Joanna Briggs Institute Checklist.

Data extraction and quality assessment:

After thorough scrutiny of full texts of the articles included in the initial review based on the inclusion criteria, we shortlisted the final list of the articles to be included in the systematic review. Further, data extraction was done by two independent reviewers from the full text of the articles into a Microsoft Excel database using the following fields: Author, country, number of patients, demographics, clinical presentation, abdominal CT findings, details of treatment, and follow-up. For extracting the relevant granular data, we used various subfields like serum levels of acute phase reactants, type of bowel wall involvement, and distribution of the abdominal CT findings across

various segments of bowel and types of vessels involved. We also extracted the laparotomy and histopathological findings in the included studies to compare with imaging findings. Any discrepancies were resolved by mutual consensus. The following data from each study also were extracted such as; name of the first author, study country, study design, course of the disease (such as ICU admission), and outcome.

Furthermore, a series of imaging findings from included studies were added (formal permissions

obtained from the copyright holder). Quality of the included studies were assessed using the National Institutes of Health (NIH) quality assessment tool for case series/reports and the modified version of the Newcastle-Ottawa Quality Scale (NOS) for cohort studies.

Exclusion criteria:

Studies which were just molecular reports, studies that reported laboratory results as percentages and commentaries were excluded.

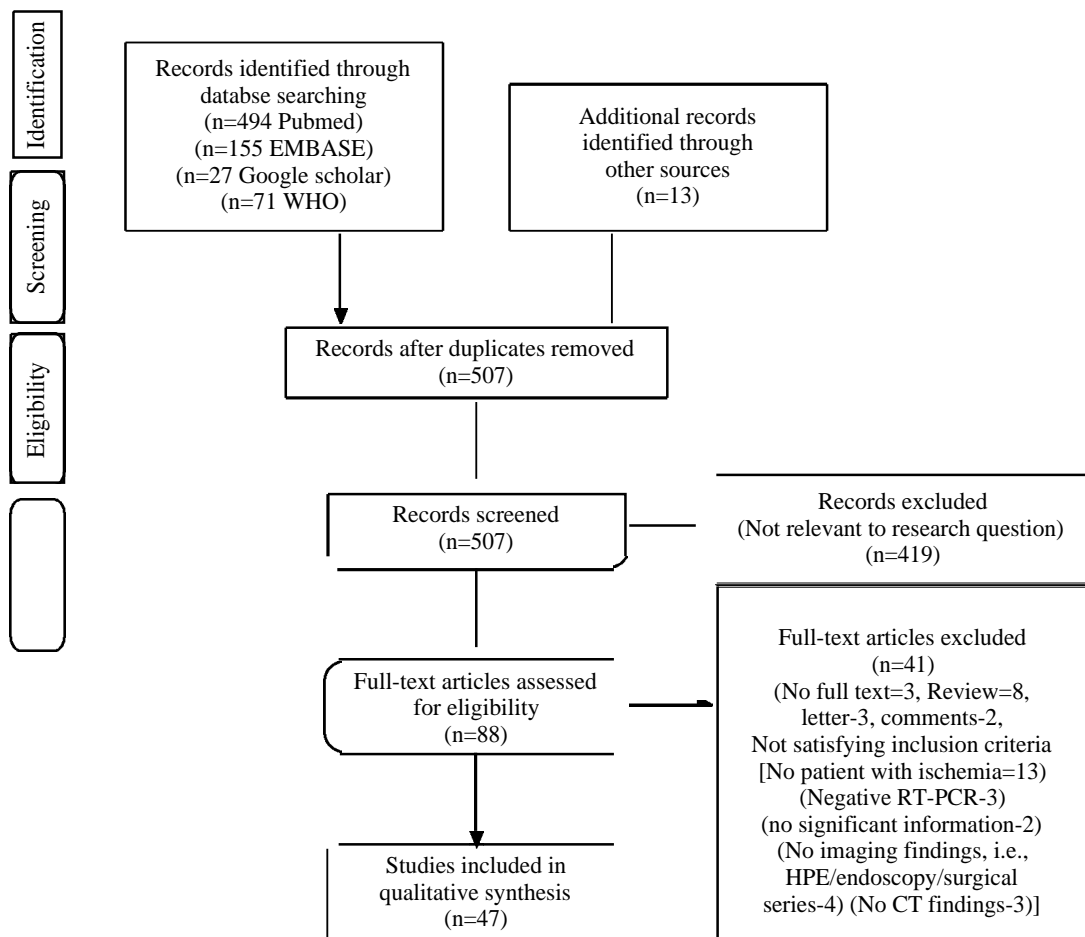


Fig. (1): PRISMA 2009 flow chart describing the study selection process for the systematic review (Moher et al., 2009).

Statistical analysis:

Cochran, Chi-square test, and I^2 were used to assess heterogeneity amongst studies.

A fixed-effects model was used when $I^2 < 50\%$, and when $I^2 > 50\%$, a random-effects model was selected. The fixed-model assumed that the population effect sizes will be the same for all studies.

In contrast the random-effects model will attempt to generalize findings beyond the included studies by assuming that the selected studies were random samples from a larger population. If there is a statistical heterogeneity amongst the results, a further sensitivity analysis was conducted to determine the source of heterogeneity. After significant clinical heterogeneity were excluded, the

randomized effects model was used for meta-analysis. When $p < 0.05$ the result was considered statistically significant (2-sided). All data were analyzed using the STAT 15 software (IBM, NY, USA).

The pooled log transformed rates of events and Wald 95% confidence intervals were estimated using DerSimonian and Laird random effects model. Freeman-Tukey double arcsine transformation or logistic-normal random-effects model was used as needed for continuity correction in order to ensure that studies with zero events were not excluded from the meta-analysis. To evaluate whether TE (thromboembolic) increases the risk of mortality among patients with COVID-19, we estimated pooled Mantel-Haenszel odds ratios (OR) for mortality using a random effects model. In this comparative analysis, patients with COVID-19 who developed TE were compared with those who did not develop TE using studies that reported mortality in the two groups of interest. Heterogeneity among studies was quantified with the I^2 statistic, with $I^2 > 50\%$ (p -value < 0.05) considered to indicate significant heterogeneity among studies. Given the significant heterogeneity between the included studies, random effects models were used throughout. Publication bias and small study effects was assessed with visual inspection of funnel plots and formally testing with Egger test. All analyses were performed using STATA version 16.1 statistical software (StataCorp LLC, College Station, Tex). The meta, metaprop and metaprop-one commands of Stata were used as appropriate.

Results

Characteristics of the studies:

Five hundred and seven unique articles were identified after initial search of the four data bases. Out of these, 88 articles met the criteria for full-text review after initial screening. After scrutiny of these 88 articles, 47 articles which met the inclusion criteria qualified to be included in the final analysis. The demographic information about the population is given in Table (1).

In 47 studies, a total of 75 patients underwent abdominal CT scans, excluding the follow-up scans which are described later. Most of the studies were case reports (Supplementary Table 1). The methodologic quality of the studies, which was assessed using the NIH (National institutes of health) Quality Assessment Tool for Case Series/Reports, was fair for most of the studies indicating limited and low-quality data available in the literature pertaining to abdominal CT.

Major imaging findings on abdominal CT:

Abdominal pain was the most common presenting symptom. The duration between positive RT-PCR and abdominal symptom onset (range 0 to 48 days) varied widely across the studies. Small bowel ischemia (41/75; 46.67%) was the most prevalent abdominal CT finding in patients with mesenteric ischemia. This was followed by large bowel ischemia (ischemic colitis) in 37.3% (28/75), arterial thrombi in 25% (17/68), and venous involvement in 20.6% (13/63). The less common findings were solid organ ischemia (12/63; 19%), ascites (8/45; 17.7%), pneumoperitoneum (6/53; 11.3%), and gastric ischemia (1/75; 1.3%) (Table 2). Among the patients who had identifiable bowel abnormalities on CT, non-occlusive mesenteric ischemia (NOMI) (36/53; 67.9%) was the most common pattern. Mural thickening and bowel wall edema were seen in 50.9% patients (27/53). While bowel hypoperfusion and dilatation were seen in 20.7% (11/53) each, pneumatosis and signs of perforation in the bowel wall were seen in 16.9% (9/53) and 11.3% (6/53), respectively. Mucosal hyperenhancement and small intestinal obstruction were rare findings (1 patient each).

Distribution of bowel ischemia:

Radiological signs of bowel ischemia, when present, were most commonly seen in the ileum and colon with equal frequency (17/53; 32.07% each), followed by the jejunum (7/53; 13.2%). Most studies did not specify the segment of the ileum or colon involved. Among the ones which described segmental involvement, distal ileum and ascending colon were more commonly involved than proximal ileum and descending colon, respectively. Involvement of cecum and rectum was rare.

Distribution of arterial and venous thrombi:

Among the studies which described the distribution of arterial thrombi in patients with imaging features of AMI, superior mesenteric artery (SMA) (17/68; 24.9%) was most commonly involved, followed by aorta (6/68; 8.8%). Concomitant lower limb arterial thrombus was seen in 2 patients (5.4%). Among the aortic segments, descending thoracic aorta (DTA) was most commonly involved. Venous thrombi, when present, were seen most commonly in the superior mesenteric vein (SMV) (9/63; 14.3%), followed by the portal vein (PV) (6/63; 9.5%). Inferior vena cava (IVC) (3/63; 4.7%), inferior mesenteric vein (IMV), and splenic vein (2/63; 3.1% each) were less commonly involved. Concomitant lower limb DVT was seen in 1 patient (1/37; 2.7%).

Table (1): Overview of the included studies and the demographic profile of the population.

First author	Country of study	Number of patients with mesenteric ischemi	Male	Female	Mean age (Y)	Comorbidity
Varshney et al.	India	1	0	1	50	N
Krothapalli et al.	USA	1	0	1	76	DM; HTN; CAD
Abdelmohsen et al.	Kuwait	2	1	1	60	N
Kinjo et al.	Japan	2	1	1	56	N
Shaikh et al.	USA	1	1	0	73	DM; HTN
Bannazadeh et al.	USA	1	1	0	55	HTN; Grave's disease
Amaravathi et al.	India	1	1	0	45	N
Mir et al.	Iran	2	1	1	60	DM; HTN
Mahruqi et al.	Oman	2	2	0	51	N
Goodfellow et al.	UK	1	0	1	36	Post-Roux-en-Y Gastric Bypass
Tirumani et al.	USA	2	1	1	55	N
Abeysekara et al.	UK	1	1	0	42	Chronic Hepatitis B
Qayed et al.	USA	2	2	0	61	N
Lazaro et al.	Spain	1	1	0	53	DM; Type 2 Hypercholesterolemia
Costanzi et al.	Italy	1	0	1	62	N
Karna et al.	India	1	1	0	61	DM; HTN
Rodriguez- Nakamura et al.	Mexico	2	1	1	45	Untreated vitiligo; Obesity, previous VP shunt
Osilli et al.	UK	1	1	0	75	DM, Diverticular disease
Sehhat et al.	Iran	1	1	0	77	HTN
Chiu et al.	USA	1	0	1	46	Stage 4 CKD
Singh et al.	USA	1	1	0	82	DM; HTN
Almeida Vargas et al.	Spain	3	3	0	66	HTN; DM, Dyslipidemia, Obesity, COPD
Lari et al.	Kuwait	1	1	0	38	N
Fan et al.	Singapore	1	1	0	30	N
English et al.	UK	1	1	0	40	Obesity
Norsa et al.	Italy	7	4	3	73	N
Mitchell et al.	USA	1	1	0	69	N
Norsa et al.	Italy	1	1	0	62	Obesity, HTN, DM, Cirrhosis
Bianco et al.	Italy	1	1	0	59	HTN
Chan et al.	USA	1	1	0	73	HTN, CKD
Ignat et al.	France	3	2	1	50	HTN, Obesity, DM Chronic bronchitis, COPD, postcardiac transplant
Azouz et al.	France	1	1	0	56	N
Bhayana et al.	USA	13	9	4	55	N
Cheung et al.	USA	1	1	0	56	HTN
Dinoto et al.	Italy	1	0	1	84	DM, HTN, renal failure, gastric ulcer disease
Macedo et al.	Brazil	1	1	0	53	N
Beccara et al.	Italy	1	1	0	52	N
Gartland et al.	USA	1	1	0	42	Type 2 DM
Vulliamy et al.	London	1	1	0	75	N
Farina et al.	Italy	1	1	0	70	N
Besutti et al.	Italy	1	1	0	72	HTN, DM, CKD
Dane et al.	USA	1	1	0	46	N
Olson et al.	USA	2	1	1	51	DM
Seeliger et al.	France	1	1	0	56	N
Neto et al.	Brazil	1	0	1	80	HTN, CAD
Hoyo et al.	Spain	1	0	1	61	DM
Pang et al.	Singapore	1	1	0	30	N

DM : Diabetes mellitus.

HTN: Hypertension.

CAD: Coronary artery disease.

CKD: Chronic kidney Disease.

Involvement of other organs and other uncommon imaging findings:

Splenic infarct (8/64; 12.5%) was the most common associated imaging finding in COVID-19 patients with mesenteric ischemia, followed by renal infarct and mesenteric edema (4/64; 6.25% each). Various other rare imaging findings included associated pulmonary thromboembolism, portal venous gas, portal cavernoma, necrotizing pancreatitis, and myocardial infarct.

Serum levels of acute phase reactants in COVID-19 patients with mesenteric ischemia:

There was wide heterogeneity in the studies reporting various acute phase reactants. Pooled incidences as well as final outcomes in these patients are described. D-dimer was most commonly raised serum acute phase reactant (34/35; 97.1%), followed by C-reactive protein (CRP, 19/24;79.2%) and serum leukocyte count (17/24; 70.8%). In those with elevated D-dimer levels, death and discharges were seen with equal frequency (16/34; 47%),

when described. In patients who had elevated CRP, final outcome of death was seen in 57.9% (11/19) and discharge in 42.1% (8/19).

Treatment and outcomes in patients with mesenteric ischemia:

Table (2) describes the frequency of treatment provided and the final outcomes, when described across the included studies. Most patients received surgical treatment (41/63; 65.07%), followed by conservative medical management (19/63; 30.15%). Only 3 patients underwent endovascular management (3/63; 4.76%). Among those who received surgical treatment, 20 (55.5%) patients got discharged, whereas 12 (33.3%) patients died. Among those who received medical management, equal number of patients died or got discharged (7/14; 50%). As far as the composite outcomes are concerned, out of a total of 56 patients in whom outcomes were reported, 24 (24/56; 42.8%) patients died, 28 (28/56; 50%) patients got discharged, and 4 (4/56; 7.1%) patients were hospitalized at the time of reporting.

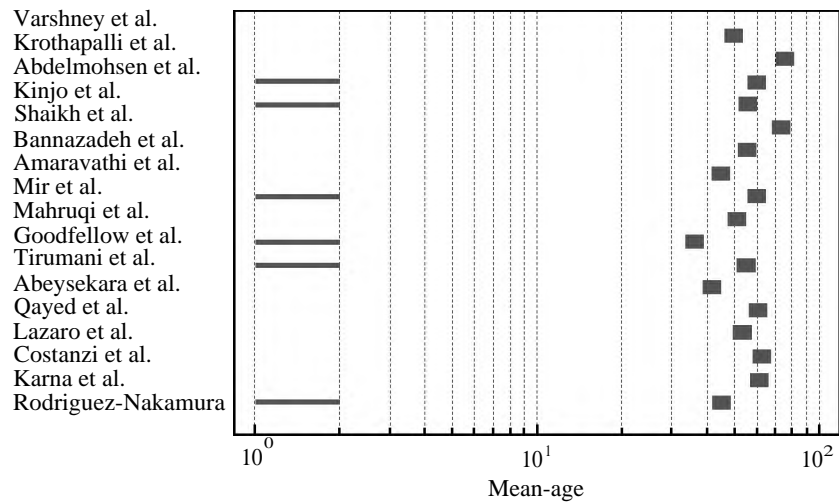


Fig. (2): Mean age of Mesenteric vascular thrombosis patients with COVID-19.

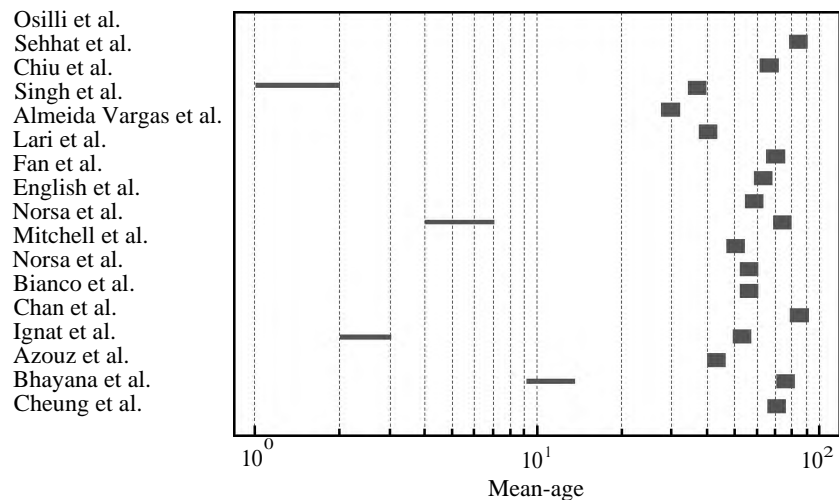


Fig. (3): Mean age of Mesenteric vascular thrombosis patients with COVID-19.

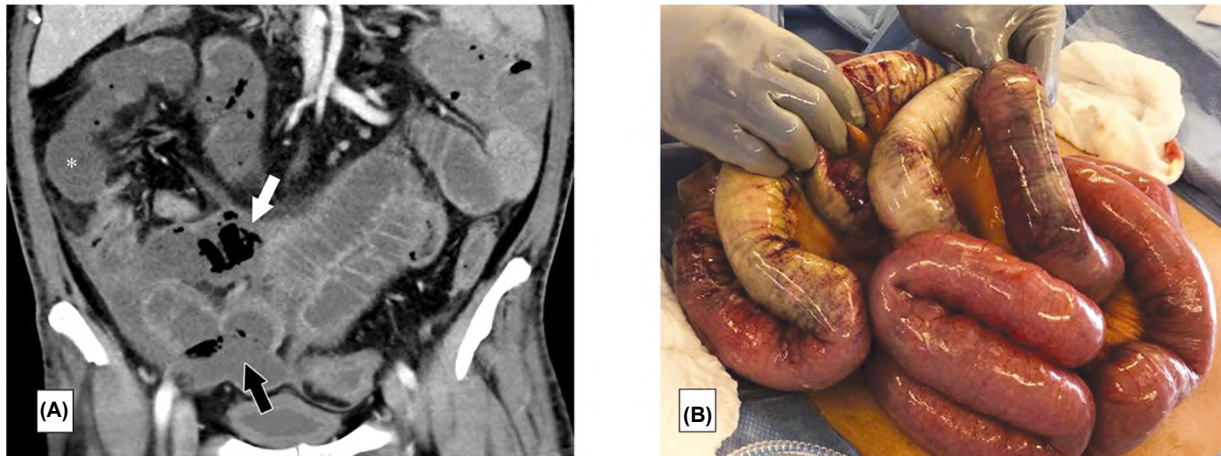


Fig. (4): (A): Coronal contrast-enhanced abdominal CT image in a 47-year-old man with abdominal tenderness shows typical findings of mesenteric ischemia and infarction, including pneumatosis intestinalis (white arrow) and non-enhancing bowel. Frank discontinuity of a thickened loop of small bowel in the pelvis (black arrow) is in keeping with perforation. (B): These findings are confirmed at laparotomy, with the additional observation of an atypical yellow discoloration of the bowel (Bhayana et al., 2020).

Laparotomy and histopathological findings:

Laparotomy findings were described in 31 patients. All the patients with diagnosis of mesenteric ischemia on imaging showed signs of bowel ischemia on laparotomy ranging from bowel necrosis, gangrene, and distension to pallor and yellowish discoloration. SMA thrombus was seen at laparotomy in 2 patients, who also had the same finding on CT. Signs of bowel perforation were seen in 6 patients at laparotomy, 5 of whom had such signs on imaging like pneumoperitoneum and abdominal collections.

All the patients, radiologically diagnosed with mesenteric ischemia, showed various signs of bowel wall ischemia ranging from bowel wall necrosis, inflammation, or hemorrhages. Of note, 6 patients were seen to have microvascular thrombi, all of whom had no major vascular abnormalities

on imaging. Arterial thrombus was seen in 2 patients, who were also seen to have arterial (SMA) thrombus on imaging. Mesenteric venous thrombus was seen in 5 patients, 4 of whom were seen to have mesenteric venous abnormality on imaging.

Findings on follow-up abdominal CT:

The studies which described findings on follow-up CT are detailed in Table (3). 4 studies showed signs of progression. While 1 study with ascending colon involvement at baseline showed with progressive involvement of descending colon on follow-up, 1 study with only SMV and PV thrombus at baseline showed frank bowel infarction at follow-up. 1 study with spleno-portal thrombosis at baseline developed liver, mesenteric, and splenic ischemia at follow-up. A patient treated endovascularly for SMA thrombus showed fully patent SMA at follow-up.

Table (2): Management and outcomes of patients with mesenteric ischemia across various studies.

Treatment received	n (n/total number of patients in whom treatment was reported)	Outcomes (n/total number of patients in whom outcome was reported)
Surgical	41 (41/63; 65.07%)	Death=12/36 (33.3%) Discharged=20/36 (55.5%) Hospitalized at the time of reported=4/36 (11.1%)
Conservative (including medical)	19 (19/63; 30.15%)	Death=7/14 (50%)
Endovascular	3 (3/63; 4.76%)	Discharged=7/14 (50%) Hospitalized at the time of reported=1/1 (100%)

Table (3): Follow-up of abdominal CT findings in cases where abdominal CT was repeated.

Study	Number of patients	Baseline CT finding	Duration of follow-up abdominal CT	Follow-up abdominal CT findings
Shaikh et al.	1	- Mild dilatation of the right colon with diffuse wall thickening	NR	- Dilatation of the distal transverse and descending colon, wall thickening, pericolicoinfiltrative changes
Abeysekara et al.	1	- Acute portal vein and SMV thrombus and bowel edema	6 weeks	- Chronic PV thrombosis, retracted, collateralization and resolution of intestinal edema
Fan et al.	1	- SMV thrombosis and small intestine dilatation	17 days	- Decrease in SMV thrombus, progress to small bowel obstruction
Ignat et al.	1	- SMV and portal vein thrombosis and no sign of ischemia	Day 5	- Bowel infarction in the first bowel loop
Dinoto et al.	1	- SMA occlusion	24-hour post endovascular treatment	- SMA patency
Hoyo et al.	1	- Hepatic vein, spleno-portal axis thrombosis	NR	- Liver, mesenteric and splenic ischemia
Pang et al.	1	- SMV thrombosis, mural thickening of bowel loops	NR	- Dilated proximal small bowel

NR: Not reported. SMV: Superior mesenteric vein.

Discussion

This endothelial damage increases the formation of procoagulant factors like factor VIII, von Willibrand factor secreted by the Weibel Palade bodies, and fibrinogen. The hypercoagulable state in COVID-19 can cause thrombosis of small mesenteric vessels and bowel ischaemia. This mucosal ischemia can lead to a considerable spread of the virus from the bowel to other organ systems causing a rapid clinical deterioration in the patient's condition. Venous thromboembolism is more commonly observed than arterial thrombosis in patients with COVID-19 [10,11].

Lastly, patients with severe COVID-19 pneumonia might require vasopressors like norepinephrine and high-dose epinephrine to treat shock and hemodynamic instability. The resulting vasoconstriction and decreased mesenteric blood circulation can lead to non-occlusive mesenteric ischemia [13].

Dane et al. reported that solid organ infarction in COVID-19 patients follows vasculature patterns and may result from microthrombi. Among the cases of bowel ischemia in the setting of COVID-19 in our systematic review, the most common non-thrombotic radiologic findings were bowel wall unenhancement (which is a specific sign for ischemia) and bowel wall thickening (which is probably the more sensitive sign of ischemia) [14].

Microvascular thrombosis, non-occlusive mesenteric ischemia, and gross arterial and venous

thrombosis have been suspected as culprits for fatal bowel wall necrosis [16].

In recent studies, it has been suggested that all hospitalized COVID-19 patients should undergo routine coagulation profile monitoring and thromboembolism prophylaxis. Contrast-enhanced abdominopelvic CT scan has a pivotal role in the early diagnosis of ischemic bowel disease. It should be considered in any cases of COVID-19 with prominent GI signs and symptoms, especially those admitted in ICU [17].

In our studied population, CT scan results revealed one patient with short segment bowel edema and diffuse wall thickening involving a single loop, concerning for One recent meta-analysis of 47 studies with 10,890 patients estimated a pooled prevalence of diarrhea to be 7.7%; nausea/vomiting, 7.8%; and abdominal pain, 2.7%. The study also pooled the prevalence of diarrhea among studies from countries other than China only and found the prevalence of diarrhea in non-China studies to be higher, with a pooled prevalence of 18.3% [19].

Overall, our results are also in keeping with those of previous studies. It has in fact been reported that coagulation is activated and accelerated in response to several infections because this mechanism may enhance the physiological response. Coagulation has also an immune function, which can be hence considered another line of defense against severe infections [20].

Limitations:

The major limitations of our study include the small sample size and reporting bias (probability of reporting severe cases). Also, since the data are extremely heterogeneous in terms of quality of methodology, data availability, and imaging findings, the results of this study should be interpreted with caution and only in appropriate clinical context. Presence of different types of scanners, parameters of acquisition, and the experience of the radiologists may have induced some heterogeneity in the reported abdominal CT findings. However, we believe that this would not have impacted the common imaging findings in our study.

Conclusion:

In Conclusion, despite the limited number of cases, we believe these cases to be significant additions and may aid further research. Presentations such as these are relatively rare. We believe Covid-19 plays a vital role in thromboembolic disease and warrants a high index of suspicion regardless of predisposing factors. A registry would need to be set up and further high-level studies need to be carried out, to underline the etiology and treatment recommendations.

The growing awareness and understanding of thrombotic complications in patients with SARS-CoV-2 infection will contribute to a more rigorous approach resulting in the earlier detection of such events and reducing the mortality rate associated with the disorder.

Macrovascular arterial/venous thrombosis can be depicted in almost half of COVID-19 patients with bowel ischemia. Overall mortality in COVID-19 patients with GI ischemia and radiologically evident mesenteric ischemia was 38% and 40%, retrospectively. Although many attributing factors are considered in the pathogenesis of bowel ischemia, factors such as hypercoagulable state, non-occlusive mesenteric ischemia, and microvascular thrombosis constitute the underlying pathology in the majority of COVID-19 patients with GI ischemic presentation.

References

- 1- LMOHSEN M.A., ALKANDARI B.M., RAZEK A.A., TOBAR A.M., GUPTA V.K. and ELSEBAIE N.: Abdominal computed tomography angiography and venography in evaluation of hemorrhagic and thrombotic lesions in hospitalized COVID-19 patients. *Clinical Imaging*, 79: 12-9, 2021.
- 2- ABEYSEKERA K.W., KARTESZI H., CLARK A. and GORDON F.H.: Spontaneous portomesenteric thrombosis in a non-cirrhotic patient with SARS-CoV-2 infection. *BMJ Case Reports CP*, 13 (12): e238906, 2020.
- 3- ABOU-ISMAIL M.Y., DIAMOND A., KAPOOR S., ARAFAH Y. and NAYAK L.: The hypercoagulable state in COVID-19: Incidence, pathophysiology, and management. *Thrombosis Research*, 194: 101-15, 2020.
- 4- ACOSTA S.: Mesenteric ischemia: *Curr. Opin. Crit. Care* [Internet], 21 (2): 171-8, 2015.
- 5- AL MAHRUQI G., STEPHEN E., ABDELHEDY I. and AL WAHAIBI K.: Our early experience with mesenteric ischemia in COVID-19 positive patients. *Annals of Vascular Surgery*, 73: 129-32, 2021.
- 6- AL SHUKRY S.: Spontaneous perforation of the colon: clinical review of five episodes in four patients. *Oman Medical Journal*, 24 (2): 137-141, 2009.
- 7- ALMEIDA A., VALENTÍ V., SANCHEZ JUSTICIA C., MARTÍNEZ REGUEIRA F., MARTI-CRUCHAGA P., LUJAN J., ALISEDA D., ESTEBAN S., CIENFUEGOS J.A. and ROTELLAR F.: Severe colon ischemia in patients with severe coronavirus-19 (COVID-19). *Rev. Esp. Enferm Dig.*, 112 (10): 784-7, 2020.
- 8- AMARAVATHI U., BALAMURUGAN N., PILLAI V.M. and AYYAN S.M.: Superior mesenteric arterial and venous thrombosis in COVID-19. *The Journal of Emergency Medicine*, 60 (5): e103-7, 2021.
- 9- AZOUZ E., YANG S., MONNIER-CHOLLEY L. and ARRIVÉ L.: Systemic arterial thrombosis and acute mesenteric ischemia in a patient with COVID-19. *Intensive Care Medicine*, 46 (7): 1464-5, 2020.
- 10- BACKER J.A., KLINKENBERG D. and WALLINGA J.: Incubation period of 2019 novel coronavirus (2019-nCoV) infections among travellers from Wuhan, China, 20-28 January 2020. *Euro Surveill*, 25 (5): 2000062, 2020.
- 11- BANNAZADEH M., TASSIOPOULOS A. and KOULLIAS G.: Acute superior mesenteric artery thrombosis seven days after discharge for novel coronavirus pneumonia. *Journal of Vascular Surgery Cases, Innovations and Techniques*, 7 (3): 586-8, 2021.
- 12- BECCARA L., PACIONI C., PONTON S., FRANCAVILLA S. and CUZZOLI A.: Arterial mesenteric thrombosis as a complication of SARS-CoV-2 infection. *European Journal of Case Reports in Internal Medicine*, 7 (5), 2020.
- 13- BESUTTI G., BONACINI R., IOTTI V., MARINI G., RIVA N., DOLCI G., MAIORANA M., SPAGGIARI L., MONELLI F., LIGABUE G. and GUARALDI G.: Abdominal visceral infarction in 3 patients with COVID-19. *Emerging Infectious Diseases*, 26 (8): 1926-8, 2020.
- 14- BIANCO F., RANIERI A.J., PATERNITI G., PATA F. and GALLO G.: Acute intestinal ischemia in a patient with COVID-19. *Techniques in Coloproctology*, 24 (11): 1217-8, 2020.
- 15- CHAN K.H., LIM S.L., DAMATI A., MARUBOYINA S.P., BONDILI L., HANOUD A.A. and SLIM J.: Coronavirus disease 2019 (COVID-19) and ischemic colitis: An under-recognized complication. *The American Journal of Emergency Medicine*, 38 (12): 2758-e1, 2020.
- 16- CHEUNG K.S., HUNG I.F., CHAN P.P., LUNG K.C., TSO E., LIU R., NG Y.Y., CHU M.Y., CHUNG T.W., TAM A.R. and YIP C.C.: Gastrointestinal manifestations of SARS-CoV-2 infection and virus load in fecal samples from a Hong Kong cohort: Systematic review and meta-analysis. *Gastroenterology*, 159 (1): 81-95, 2020.

- 17- CHEUNG S., QUIWA J.C., PILLAI A., ONWU C., THARAYIL Z.J. and GUPTA R.: Superior mesenteric artery thrombosis and acute intestinal ischemia as a consequence of COVID-19 infection. *The American Journal of Case Reports*, 21: e925753-1, 2020.
- 18- CHIU C.Y., SARWAL A., MON A.M., TAN Y.E. and SHAH V.: Gastrointestinal: COVID-19 related ischemic bowel disease. *J. Gastroenterol. Hepatol.*, 850, 2021.
- 19- CORRÊANETO I.J., VIANA K.F., SILVA M.B., SILVA L.M., OLIVEIRA G.D., CECCHINI A.R., ROLIM A.S. and ROBLES L.: Perforated acute abdomen in a patient with COVID-19: An atypical manifestation of the disease. *Journal of Coloproctology (Rio de Janeiro)*, 40: 269-72, 2020.
- 20- COSTANZI A., MONTELEONE M., CONFALONIERI M., COLLETTI G., FRATTARUOLO C. and FINGERHUT A.: Late Bowel Ischemia and Colovaginal Fistula after Low Anterior Resection in a COVID-19 Patient. *Chirurgia (Bucur)*, 115 (5): 677-80, 2020.
- 21- DEL HOYO J., LÓPEZ-MUÑOZ P., FERNÁNDEZ-DE LA VARGA M., GARRIDO-MARÍN A., VALERO-PÉREZ E., PRIETO M. and AGUILERA V.: Hepatobiliary and Pancreatic: A fatal case of extensive splanchnic vein thrombosis in a patient with Covid-19. *Journal of Gastroenterology and Hepatology*, 35 (11): 1853, 2020.
- 22- DINOTO E., FERLITO F., LA MARCA M.A., MIRABELLA D., BAJARDI G. and PECORARO F.: Staged acute mesenteric and peripheral ischemia treatment in COVID-19 patient: Case report. *International Journal of Surgery Case Reports*, 84: 106105, 2021.
- 23- DRAKOS P., VOLTEAS P., CLERI N.A., ALKADAA L.N., ASENCIO A.A., OGANOV A., PRYOR A., TALAMINI M., RUBANO J., BANNAZADEH M. and MIKELL C.B.: Acute gastrointestinal injury and feeding intolerance as prognostic factors in critically ill COVID-19 patients. *Journal of Gastrointestinal Surgery*, 26 (1): 181-90, 2022.
- 24- ENGLISH W. and BANERJEE S.: Coagulopathy and mesenteric ischaemia in severe SARS-CoV-2 infection. *ANZ J. Surg.*, 90 (9): 1826, 2020.
- 25- FAN B.E., CHANG C.C., TEO C.H. and YAP E.S.: COVID-19 coagulopathy with superior mesenteric vein thrombosis complicated by an ischaemic bowel. *Hämostaseologie*, 40 (05): 592-3, 2020.
- 26- FARINA D., RONDI P., BOTTURI E., RENZULLI M., BORGHESI A., GUELFI D. and RAVANELLI M.: Gastrointestinal: Bowel ischemia in a suspected coronavirus disease (COVID-19) patient. *Journal of gastroenterology and hepatology*, 36 (1): 41-41, 2021.
- 27- GNANAPANDITHAN K. and FEUERSTADT P.: Mesenteric ischemia. *Current Gastroenterology Reports*, 22 (4): 1-2, 2020.
- 28- GOODFELLOW M., COURTNEY M., UPADHYAY Y., MARSH R. and MAHAWAR K.: Mesenteric venous thrombosis due to coronavirus in a post Roux-en-Y gastric bypass patient: A case report. *Obesity Surgery*, 31 (5): 2308-10, 2021.
- 29- GÖRLINGER K., DIRKMANN D., GANDHI A. and SIMIONI P.: COVID-19 associated coagulopathy and inflammatory response: What do we know already and what are the knowledge gaps?. *Anesthesia and Analgesia*, 131 (5): 1324-1333, 2020.
- 30- HAEMATOLOGY T.L.: COVID-19 coagulopathy: An evolving story. *The Lancet. Haematology*, 7 (6): e425, 2020.
- 31- HAN H., YANG L., LIU R., LIU F., WU K.L., LI J., LIU X.H. and ZHU C.L.: Prominent changes in blood coagulation of patients with SARS-CoV-2 infection. *Clinical Chemistry and Laboratory Medicine (CCLM)*, 58 (7): 1116-20, 2020.
- 32- HE F., DENG Y. and LI W.: Coronavirus disease 2019: What we know? *J Med Virol [Internet]*, 92 (7): 719-25, 2020.
- 33- HELMS J., TACQUARD C., SEVERAC F., LEONARD-LORANT I., OHANA M., DELABRANCHE X., MERDJI H., CLERE-JEHL R., SCHENCK M., FAGOT GANDET F. and FAFI-KREMER S.: High risk of thrombosis in patients with severe SARS-CoV-2 infection: A multicenter prospective cohort study. *Intensive Care Medicine*, 46 (6): 1089-98, 2020.
- 34- IGNAT M., PHILOUZE G., AUSSENAC-BELLE L., FAUCHER V., COLLANGE O., MUTTER D. and PESSAUX P.: Small bowel ischemia and SARS-CoV-2 infection: An underdiagnosed distinct clinical entity. *Surgery*, 168 (1): 14-6, 2020.
- 35- KARNA S.T., PANDA R., MAURYA A.P. and KUMARI S.: Superior mesenteric artery thrombosis in COVID-19 pneumonia: An underestimated diagnosis-first case report in Asia. *Indian Journal of Surgery*, 82 (6): 1235-7, 2020.
- 36- KESHAVARZ P., RAFIEE F., KAVANDI H., GOUDARZI S., HEIDARI F. and GHOLAMREZANEZHAD A.: Ischemic gastrointestinal complications of COVID-19: A systematic review on imaging presentation. *Clinical imaging*, 73: 86-95, 2021.
- 37- KINJO T., HOKAMA A., NAKAMURA H., MIYAGI K., HIGURE Y., OTSUKI M., NISHIYAMA N., NAKAMATSU M., KINJO T., TATEYAMA M. and FUJITA J.: Case report: Ischemic enterocolitis associated with coronavirus disease 2019: Two case reports and a review of the literature. *The American Journal of Tropical Medicine and Hygiene*, 104 (5): 1655, 2021.
- 38- KROTHAPALLI N. and JACOB J.: A rare case of acute mesenteric ischemia in the setting of COVID-19 infection. *Cureus*, 13 (3), 2021.
- 39- KÜHN F., SCHIERGENS T.S. and KLAR E.: Acute Mesenteric Ischemia. *Visc Med [Internet]*, 36 (4): 256-63, 2020.
- 40- KUNUTSOR S.K. and LAUKKANEN J.A.: Incidence of venous and arterial thromboembolic complications in COVID-19: A systematic review and meta-analysis. *Thrombosis Research*, 196: 27-30, 2020.
- 41- LARI E., LARI A., ALQINAI S., ABDULRASOUL M., ALSAFRAN S., AMEER A. and AL-SABAH S.: Severe ischemic complications in Covid-19-A case series. *International Journal of Surgery Case Reports*, 75: 131-5, 2020.
- 42- LÁZARO P.G., MENESES A.L., DEL VAL ZABALLOS F. and RIVAS A.M.: Ischemic colitis and short bowel disease due to coronavirus disease 2019 (COVID 19). *Clinical nutrition ESPEN*, 40: 406-7, 2020.
- 43- LI Q., GUAN X., WU P., WANG X., ZHOU L., TONG Y., REN R., LEUNG K.S., LAU E.H., WONG J.Y. and

- XING X.: Early transmission dynamics in Wuhan, China, of novel coronavirus-infected pneumonia. *New England Journal of Medicine*, 382 (13): 1199-1207, 2020.
- 44- LINTON N.M., KOBAYASHI T. and YANG Y.: Incubation period and other epidemiological characteristics of 2019 novel Coronavirus infections with right truncation: A statistical analysis of publicly available case data. *J. Clin. Med.*, 9 (02): E538-E538, 2020.
- 45- LU R., ZHAO X. and LI J.: Genomic characterisation and epidemiology of 2019 novel coronavirus: Implications for virus origins and receptor binding *Lancet*, 395 (10224): 565-574, 2020.
- 46- MACEDO V.S., MOREIRA G.B., ALBUQUERQUE A.C., OLIVEIRA S.C., ESMERALDO M.A. and BARBOSA F.C.: Late mesenteric ischemia after Sars-Cov-2 infection: Case report. *Jornal Vascular Brasileiro*, 20, 2021.
- 47- MAO R., QIU Y., HE J.S., TAN J.Y., LI X.H., LIANG J., SHEN J., ZHU L.R., CHEN Y., IACUCCI M. and NG S.C.: Manifestations and prognosis of gastrointestinal and liver involvement in patients with COVID-19: A systematic review and meta-analysis. *The lancet Gastroenterology & Hepatology*, 5 (7): 667-78, 2020.
- 48- MIESBACH W. and MAKRIS M.: COVID-19: Coagulopathy, risk of thrombosis, and the rationale for anticoagulation. *Clinical and applied thrombosis/hemostasis*, 26: 21-34, 2020.
- 49- MITCHELL J.M., RAKHEJA D. and GOPAL P.: SARS-CoV-2-related hypercoagulable state leading to ischemic enteritis secondary to superior mesenteric artery thrombosis. *Clinical Gastroenterology and Hepatology*, 19 (11): e111, 2021.
- 50- MOHER D., LIBERATI A., TETZLAFF J., ALTMAN D.G. and PRISMA GROUP*: Preferred reporting items for systematic reviews and meta-analyses: The PRISMA statement. *Annals of Internal Medicine*, 151 (4): 264-9, 2009.
- 51- NEPOGODIEV D., BHANGU A., GLASBEY J.C., LI E., OMAR O.M., SIMOES J.F., ABBOTT T.E., ALSER O., ARNAUD A.P., BANKHEAD-KENDALL B.K. and BREEN K.A.: Mortality and pulmonary complications in patients undergoing surgery with perioperative SARS-CoV-2 infection: An international cohort study. *The Lancet*, 396 (10243): 27-38, 2020.
- 52- NORSAL L., BONAFFINI P.A., INDRIOLO A., VALLE C., SONZOGNI A. and SIRONI S.: Poor outcome of intestinal ischemic manifestations of COVID-19. *Gastroenterology*, 159 (4): 1595-7, 2020.
- 53- OJHA V., MANI A., MUKHERJEE A., KUMAR S. and JAGIA P.: Mesenteric ischemia in patients with COVID-19: an updated systematic review of abdominal CT findings in 75 patients. *Abdominal Radiology*, 1-38, 2021.
- 54- OLSON M.C., LUBNER M.G., MENIAS C.O., MELLNICK V.M., GETTLE L.M., KIM D.H., ELSAYES K.M. and PICKHARDT P.J.: Radiographics update: Venous thrombosis and hypercoagulability in the abdomen and pelvis-findings in COVID-19. *Radiographics*, 40 (5): E24, 2020.
- 55- OSILLI D., PAVLOVICA J., MANE R., IBRAHIM M., BOUHELAL A. and JACOB S.: Case reports: Mild COVID-19 infection and acute arterial thrombosis. *Journal of Surgical Case Reports*, 2020 (9): rjaa343, 2020.
- 56- PARK M., COOK A.R., LIM J.T., SUN Y. and DICKENS B.L.: A systematic review of COVID-19 epidemiology based on current evidence. *Journal of Clinical Medicine*, 9 (4): 967, 2020.
- 57- PARRY A.H., WANI A.H. and YASEEN M.: Acute mesenteric ischemia in severe coronavirus-19 (COVID-19): Possible mechanisms and diagnostic pathway. *Academic Radiology*, 27 (8): 1190, 2020.
- 58- QAYED E., DESHPANDE A.R. and ELMUNZER B.J.: Low Incidence of Severe Gastrointestinal Complications in COVID-19 Patients Admitted to the Intensive Care Unit: A Large, Multicenter Study. *Gastroenterology*, 160 (4): 1403-5, 2021.
- 59- RODRIGUEZ-NAKAMURA R.M., GONZALEZ-CALATAYUD M. and MARTINEZ A.R.: Acute mesenteric thrombosis in two patients with COVID-19. Two cases report and literature review. *International Journal of Surgery Case Reports*, 76: 409-14, 2020.
- 60- SEELIGER B., PHILOUZE G., BENOTMANE I., MUTTER D. and PESSAUX P.: Is the severe acute respiratory syndrome coronavirus 2 (SARS-CoV-2) present intraperitoneally in patients with coronavirus disease 2019 (COVID-19) infection undergoing emergency operations?. *Surgery*, 168 (2): 220-1, 2020.
- 61- SEELIGER B., PHILOUZE G., CHERKAOUI Z., FELLI E., MUTTER D. and PESSAUX P.: Acute abdomen in patients with SARS-CoV-2 infection or co-infection. *Langenbeck's Archives of Surgery*, 405 (6): 861-6, 2020.
- 62- SEHHAT S., TALEBZADEH H., HAKAMIFARD A., MELALI H., SHABIB S., RAHMATI A. and LARKI-HARCHEGANI A.: Acute mesenteric ischemia in a patient with COVID-19: A case report. *Archives of Iranian Medicine*, 23 (9): 639-43, 2020.
- 63- SHAHID F., ALI S.M., SALEEM S., SHAHID U., KARIM N., LATIF E. and ZAROUR A.: Acute mesenteric ischemia due to COVID-19: A case report. *Open Access Journal of Surgery*, 12 (2), 2020.
- 64- SHAIKH D.H., PATEL H., MAKKER J., BADIPATLA K. and CHILIMURI S.: Colonic ileus, distension, and ischemia due to COVID-19-related colitis: A case report and literature review. *Cureus*, 13 (2): e13236, 2021.
- 65- SINGH B., MECHINENI A., KAUR P., AJDIR N., MAROULES M., SHAMOON F. and BIKKINA M.: Acute intestinal ischemia in a patient with COVID-19 infection. *The Korean Journal of Gastroenterology*, 76 (3): 164-6, 2020.
- 66- SULTAN S., ALTAYAR O., SIDDIQUE S.M., DAVITKOV P., FEUERSTEIN J.D., LIM J.K., FALCK-YTTER Y., EL-SERAG H.B. and INSTITUTE A.G.: AGA institute rapid review of the gastrointestinal and liver manifestations of COVID-19, meta-analysis of international data, and recommendations for the consultative management of patients with COVID-19. *Gastroenterology*, 159 (1): 320-34, 2020.
- 67- VARSHNEY R., BANSAL N., KHANDURI A., GUPTA J. and GUPTA R.: Colonic gangrene: A sequela of coronavirus disease 2019. *Cureus*, 13 (4), 2021.

تجلطات الأوردة والشرايين المساريقية كمضاعفات في مرضى فيروس كورونا : دراسة منهجية وتحليل بعدى للدراسات الإكلينيكية

في يناير ٢٠٢٠ تم التعرف على فيروس كورونا جديد في أعقاب تفشى التهاب رئوى مجهول السبب بوهان بالصين وتم تسميته مرض كورونا ١٩ من قبل منظمة الصحة العالمية.

لقد انتشر وباء مرض كورونا في أكثر من ٢٠٠ دولة في مختلف أنحاء العالم، وعلى الرغم من أن المرض يؤثر بشكل رئيسى على الجهاز التنفسي إلا أن أعضاء أخرى قد تتأثر بسبب اضطرابات التخثر المصاحبة للمرض، وفي هذا الصدد أبلغ عن حدوث تجلط داخل الوريد العميق فى ما يصل من ٢٥ إلى ٥٠ بالمائة من مرضى كورونا المحتاجين للرعاية المركزة، وعلى الرغم من أنه أقل تواتراً فقد تم الإبلاغ عن تجلطات بأماكن أخرى مثل الأمعاء والمخ والأطراف عادة فى الحالات الحرجة.

وفيما يتعلق بالاضرار المعوية فإن تأثيرات التجلط الناجمة عن الفيروس تؤدي إلى ارتفاع معدل الإصابة بتجلطات أووعية مساريقاً الأمعاء فى مرضى كورونا، ومن المهم ملاحظة أن مضاعفات التجلط الوريدية للمساريقا أكثر شيوعاً من الشريانية، كما أن التغيرات التي تحدث بسبب الإصابة على مستوى الأوعية الدقيقة تلعب دوراً مركزياً فى تلف الأمعاء وحدث إقفار دموى لمساريقا الأمعاء.

إن الفارق الزمني بين بداية الأعراض إلى العلاج بالنسبة لحالات الإقفار الدموى للأمعاء الناجم عن تجلطات مساريقا الأمعاء هو أمر حاسم للنتيجة الجيدة، والوقت الأمثل للتدخل هو ١٢ ساعة من بداية ظهور الأعراض عندها يكون من الممكن إجراء جراحة للأوعية الدموية بشكل فعال دون أن يتطلب ذلك استئصال الأمعاء، وعليه ينبغي الاشتباه فى حدوث جلطة بأوعية المساريقا إذا كان المريض يعاني من انتفاخ بالبطن وألم مع وجود نقص بعدد الصفائح الدموية وارتفاع نسب دلالات الالتهاب.

إن الإقفار الدموى الحاد للمساريقا الناجم عن تجلط أووعية المساريقا مشكلة مصحوبة بارتفاع معدل الوفيات ولذا فإن الاكتشاف المبكر والعلاج بالوقت المناسب أمر أساسى.

اختبارات الدم للحالات والتي هى من أدوات البحث والفحص غير محده أو كاشفة للمشكلة، أما الأشعة المقطعية التصويرية للأوعية فهى الاختبار الأمثل لإجراء التشخيص.